fishes

MDPI

Article

Dietary Selenium-Rich *Lactobacillus plantarum* Alleviates Cadmium-Induced Oxidative Stress and Inflammation in *Bulatmai barbel Luciobarbus capito*

Qing Zhang [1,2,†], Xinchi Shang [1,2,†], Longwu Geng [1,2], Xinghua Che [1,2], Haijun Wei [1,2], Shizhan Tang [1,2] and Wei Xu [1,2,*]

[1] Key Open Laboratory of Cold Water Fish Germplasm Resources and Breeding of Heilongjiang Province, Heilongjiang River Fisheries Research Institute, Chinese Academy of Fishery Sciences, Harbin 150070, China
[2] Engineering Technology Research Center of Saline-Alkaline Water Fisheries (Harbin), Chinese Academy of Fishery Sciences, Harbin 150070, China
* Correspondence: xuwei@hrfri.ac.cn
† These authors contributed equally to this work.

Abstract: Cadmium (Cd) poses a great threat to the breeding of aquatic economic animals. The present study aimed to explain the antagonistic effects of selenium-enriched *Lactobacillus plantarum* (SL) on Cd toxicity through the expression of oxidative and inflammatory factors. A total of 225 *Bulatmai barbel Luciobarbus capito* (*L. capito*) were divided into 3 groups, namely, the control group, the Cd group (Cd, 0.05 mg·L^{-1}), and the SL + Cd group (Cd, 0.05 mg·L^{-1}; Nano Se, 5 mg·kg^{-1}; *L. plantarum*, 10^5 CFU·g^{-1}). The experiment lasted for 28 d, Sampling at 14 and 28 d, respectively. The results showed that Cd exposure caused obvious pathological damage to the liver and kidney, and the serum parameter ALT increased significantly ($p < 0.05$). In the Cd group, the concentration of Cd in the kidney was significantly increased ($p < 0.05$), and the activities of catalase (CAT), superoxide dismutase (SOD), and glutathione peroxidase (GSH-Px) in the kidney and gill were significantly decreased; malonaldehyde (MDA) increased significantly ($p < 0.05$) Then the mRNA expression levels in the kidney and liver were measured. Cd exposure significantly decreased the mRNA expressions of *SOD*, *CAT*, *GSH-Px*, *HO-1*, *I-κBα*, and *Nrf2* ($p < 0.05$). The Cd-treated group showed significantly increased *NF-kBp65*, *TGF-β*, *IL-8*, *IL-1*, *Keap1*, and *TNF-α* expression levels. SL significantly alleviated the changes in the above indicators. The results of this study suggest that SL can trigger the Nrf2 signalling pathway and NF-kB signalling pathway to alleviate Cd toxicity. SL might be a potential drug for the treatment of Cd poisoning.

Keywords: Se-enriched *Lactobacillus plantarum*; Cadmium; *Luciobarbus capito*; Oxidative stress; Inflammatory reaction; Bioaccumulation

check for updates

Citation: Zhang, Q.; Shang, X.; Geng, L.; Che, X.; Wei, H.; Tang, S.; Xu, W. Dietary Selenium-Rich *Lactobacillus plantarum* Alleviates Cadmium-Induced Oxidative Stress and Inflammation in *Bulatmai barbel Luciobarbus capito*. *Fishes* **2023**, *8*, 136. https://doi.org/10.3390/fishes8030136

Academic Editor: Bernardo Baldisserotto

Received: 12 January 2023
Revised: 12 February 2023
Accepted: 24 February 2023
Published: 27 February 2023

Copyright: © 2023 by the authors. Licensee MDPI, Basel, Switzerland. This article is an open access article distributed under the terms and conditions of the Creative Commons Attribution (CC BY) license (https://creativecommons.org/licenses/by/4.0/).

1. Introduction

Heavy metal contamination is a severe challenge facing humans and aquatic animals because it has an unknown biological role and exerts sustained toxicity at low concentrations [1,2]. Cadmium (Cd) is widely used in agriculture and industry and is inevitably released into natural waters, causing water pollution [3]. The major sources of Cd contamination in water are batteries, electroplating, pigments, plastics, industrial effluents, phosphate fertilizers, and cigarette smoke [4,5].

Cd enters the fish body via gill, skin penetration, and the food chain [6–8]. Cd is a nonbiodegradable inorganic chemical that mostly accumulates in the kidney, gill, and liver [9]. The main target organs of Cd are the liver and kidney; Cd entering the body is first stored in the liver and then reaches the kidney through blood circulation, causing continuous damage to the liver and kidney [10]. It was found that the damage of Cd to kidney tissue mainly manifested in glomerular atrophy and space expansion, and the

damage to liver tissue mainly manifested in cell degeneration, intracellular vacuolization, and pyknosis [11,12]. As a nonessential biological element, Cd at low levels can cause widespread harm to humans and animals, resulting in oxidative stress, DNA damage, and hepatonephrotoxicity [13,14]. Therefore, it is necessary to develop a safe and efficient antidote.

The nanoselenium synthesized by probiotics has the characteristics of easy absorption and high safety. Selenium (Se) exists in the active centre of the antioxidant enzymes glutathione peroxidase (GSH-Px) and thioredoxin reductase (TrxR) in the form of selenocysteine [15]. A se-enriched diet enhances the antioxidant capacity of the liver and kidney in mice to resist the toxicity of low concentrations of Cd [16]. Se increases the expression of selenoprotein genes and reduces Cd toxicity by inhibiting the expression of inflammatory factors in the chicken kidney [17]. In vitro experiments have shown that *L. plantarum* has the ability to remove Cd [18]. In vivo experiments also showed that it promoted the excretion of heavy metals in the body. Oral administration of *Luciobarbus capito* (*L. plantarum*) *CCFM8661* promotes the excretion of Cd by regulating the enterohepatic circulation of bile acids (BAs), reducing intestinal motility disorders, and protecting the intestinal barrier in mice [19–21]. Recently, we characterized the morphology of nano selenium particles and clarified their influence on the intestinal microbiome [22]. However, it cannot be determined whether intestinal microorganisms indirectly alleviate Cd toxicity, directly play a role at the genetic level, or both, which needs further verification. Therefore, this study started with inflammation- and oxidation-related genes to explore the protective effect of SL.

2. Materials and Methods

2.1. Preparation of Selenium-Enriched L. plantarum and Feed

The production of selenium-enriched *L. plantarum* and feed was performed according to our previous research [22].

2.2. Experimental Feed and Conditions

L. capito (75.40 ± 0.88 g) were obtained from Hulan Test Station, Heilongjiang River Fisheries Research Institute, Harbin, Heilongjiang Province, China. The commercial feed of Tianjin Aonong Biotechnology Co., Ltd. was used as the basal diet, and the composition of the feed was 35% crude protein, 4.0% crude fat, and 15% ash. Before the exposure trial, in order to adapt to the laboratory conditions, the fish were kept under laboratory conditions for 14 d. The fish were fed a basal diet twice daily (09:00 and 17:00) at a rate of 2% of body weight. During culture, the dissolved oxygen was 6.32 ± 0.12 mg·L^{-1}, and the water temperature was 23 ± 2 °C, with light: dark = 13:11 h.

2.3. Experimental Design and Experimental Diets

A total of 225 fish were randomly divided into 3 groups with 3 replicates each (25 fish per tank) and kept in 200-L tempered glass tanks with Cd (0.05 mg·L^{-1}) and/or dietary SL (including Se 5 mg·kg^{-1} and *L. plantarum* 10^5 CFU·g^{-1}). The groups received treatments as follows: control group, Cd, (Cd, 0.05 mg·L^{-1}), and SL+Cd, (Cd, 0.05 mg·L^{-1}, Nano Se, 5 mg·kg^{-1} and *L. plantarum* 10^5 CFU·g^{-1}). The settings for Se and Cd concentrations refer to previous studies [23,24]. The experiment lasted for 28 d. The control group received the same amount of sterile water, and all food was stored at 4 °C for subsequent experiments. To maintain the activity of *L. plantarum*, the food was fed within 2 d. In addition, the water was replaced once a day with half a tank of water, and Cd was added according to the experimental concentration to maintain the concentration of Cd in the water.

2.4. Sample Collection

The fish were fasted for a day before sample collection. At 14 and 28 d, 9 fish had tissue samples collected and were randomly selected from each tank. The fish were euthanized with sodium mesylate 222 (300 mg·L^{-1}; Sigma, MO, USA). The kidney, gill, and liver were collected, frozen in liquid nitrogen, and stored at −80 °C.

2.5. Histopathological Studies

Liver and kidney were fixed with tissue fixative (Meilun Biotechnology Co., Ltd., Dalian, China), and then a histopathological examination was performed. The fixed tissue samples were embedded in paraffin, and paraffin sections were made with a continuous microtome and stained with HE. Finally, histopathological changes were observed under an optical microscope (Olympus BX53, Tokyo, Japan).

2.6. Antioxidant Response Analysis

Superoxide dismutase (SOD), catalase (CAT), glutathione peroxidase (GSH-Px), and malondialdehyde (MDA) were measured in tissues. Dipalanine aminotransferase (ALT) was measured in serum. The above indicators are measured using the commercially available ELISA kit (Nanjing Jiancheng Bioengineering Research Institute, Jiangsu, China) and according to the recommendations of the manufacturer.

2.7. Cd and Se Accumulation

The kidneys were sampled from each group to observe the Cd and Se concentrations at 14 d. The measurement method refers to that of Qin et al. [25]. The sample (0.5 g) was transferred to a PTFE (polytetrafluoroethylene) vessel, HNO_3 and ultrapure water were added, and it was digested with a MarXpress microwave closure system (CEM, North Carolina, NC, USA). Then, the concentrations of Se and Cd in the kidney were determined with an Agilent 7500cx ICP–MS (Agilent Technologies, Santa Clara, CA, USA).

2.8. Reverse-Transcriptase Real-Time PCR (RT–PCR)

Total RNA was extracted from the liver and kidney using the Simply P Total RNA Extraction Kit (Bioer Technology Co., Ltd., Hangzhou, China) according to the instructions, followed by agarose gel electrophoresis. Then, the quality of the RNA was identified by an 8-channel micro-UV–vis spectrophotometer (Gene Company Limited, Hong Kong, China), and the OD260/280 was in the range of 1.8–2.1. One microlitre of total RNA was used for reverse transcription of cDNA using the PrimeScript™ RT reagent Kit with gDNA Eraser (Takara Biomedical Technology Co., Ltd., Kyoto, Japan) for quantitative real-time PCR (qRT-PCR) according to the instructions. qRT-PCRs were performed on a QuantStudio 6 Real-Time PCR System. The primer sequences used for gene expression analysis are shown in Table 1. The relative expression was analysed according to the $2^{-\Delta\Delta CT}$ method.

Table 1. Primers used for qPCR.

	Forward	Reverse
SOD	CGCACTTCAACCCTTACA	ACTTTCCTCATTGCCTCC
CAT	GAAGTTCTACACCGATGAGG	CCAGAAATCCCAAACCAT
GSH-Px	GAGGCACAACAGTCAGGGATTA	GTTCACTTCCAGCTTCTCCAGA
Nrf2	TTCCCGCTGGTTTACCTTAC	CGTTTCTTCTGCTTGTCTTT
Keap-1	GCTCTTCGGAAACCCCT	GCCCCAAGCCCACTACA
HO-1	TCAGCCCATCTACTTCCCTCA	GGCAGGCACTGTTACTCTCT
TGF-β	TTGGGACTTGTGCTCTAT	AGTTCTGCTGGGATGTTT
IL-8	ATGAGTCTTAGAGGTCTGGGT	ACAGTGAGGGCTAGGAGGG
IL-1	ACCAGCTGGATTTGTCAGAAG	ACATACTGAATTGAACTTTG
TNFα	GGTGATGGTGTCGAGGAGGAA	TGTCATCCTTTCTGCTCTGGTT
NF-kBP65	GGCAGGTGGCGATAGTGTT	CATTCCTTCAGTTCTCTTGCG
IkBa	TCTTGCCATTATTCACGAGG	TGTTACCACAGTCATCCACCA
b-actin	TGAAGATCCTGACCGAGCGT	GGAAGAAGAGGCAGCGGTTC

2.9. Statistical Analysis

Data are expressed as the mean ± standard deviation (SD) for each group. The differences in the means among the groups were analysed using one-way analysis of variance (ANOVA), and multiple comparisons were performed using Duncan's method

with the data analysis software SPSS 20 (SPSS, Chicago, IL, USA). $p < 0.05$ indicated statistical significance.

3. Results

3.1. Histopathological Study

Under a light microscope, the control group showed normal renal structures (Figure 1a). In the Cd group, the glomeruli were atrophied, and large gaps were observed; the epithelium of the renal tubules was thin, exfoliated, and dissolved, and the nucleus disappeared (Figure 1c). The above histopathological changes were alleviated in the SL+Cd treatment group (Figure 1b). The hepatocytes in the control group were closely arranged, the cell membrane was clearly visible, and the nucleus was clearly visible in the middle (Figure 1d). In the Cd group, some liver nuclei disintegrated and disappeared, and pyknosis occurred. Hepatocyte necrosis was observed. The boundaries of the hepatocytes were vague. Bleeding was observed, and a large number of cells were vacuolated (Figure 1f). After feeding SL, the above pathological changes were alleviated, some cells exhibited vacuolization, the nucleus was clearly visible, and the boundary of the cell membrane was slightly clear (Figure 1e).

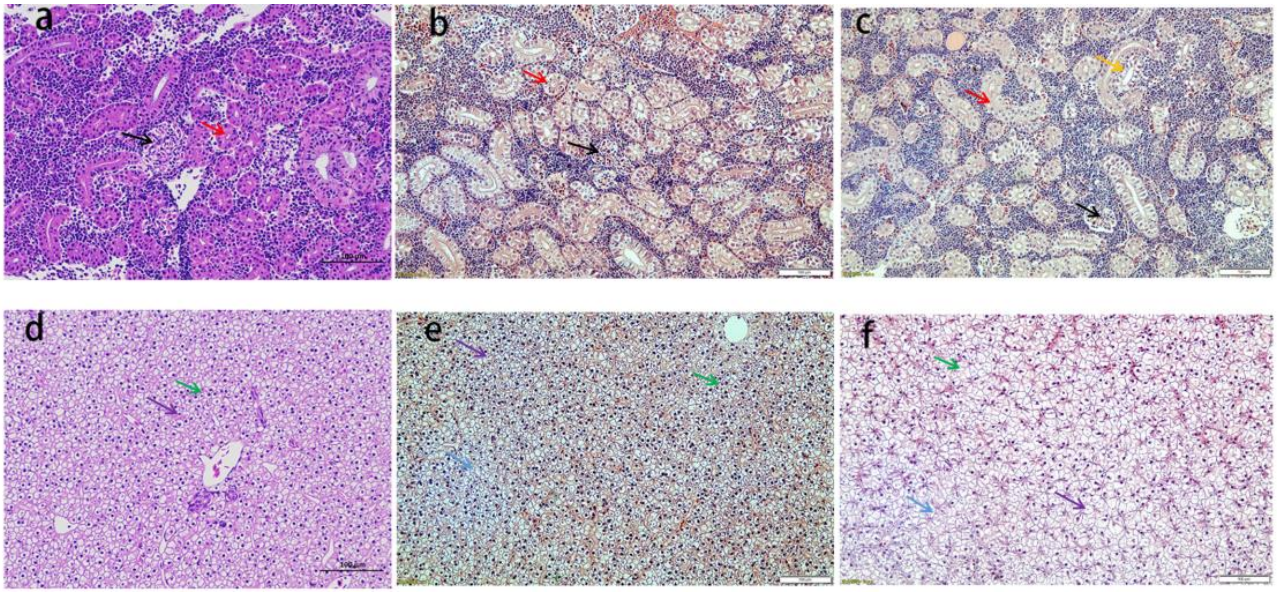

Figure 1. The histopathological analysis in kidney and liver. Note: kidney, control group (**a**); SL + Cd group (**b**); Cd group (**c**); liver, control group (**d**); SL + Cd group (**e**); Cd group (**f**). The red and yellow arrows point to the proximal convoluted tubules, and the black arrows point to the glomeruli. The green arrow points to the border of hepatocytes, the blue arrow points to the vacuolization of hepatocytes, and the purple arrow points to the hepatocyte nuclear pyknosis (HE staining, magnification 200×).

3.2. Hepatic Markers

The serum biochemical parameter results are shown in Figure 2. At 14 and 28 d, Cd stress caused a significant increase in AST ($p < 0.05$). Compared with the Cd group, SL significantly reduced the elevation of AST ($p < 0.05$).

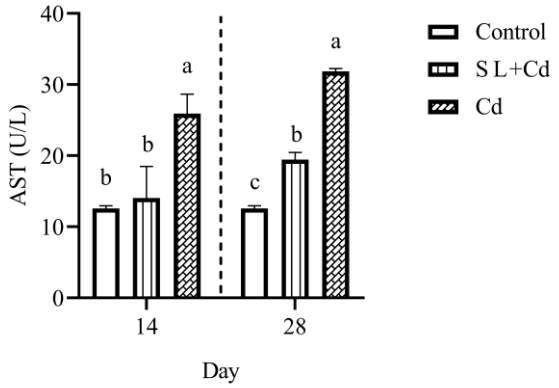

Figure 2. Effects of SL and/or Cd on serum parameters of *L. capito*. The data were expressed as mean ± SD. Different letters represented significant differences ($p < 0.05$), and the same letter represented non-significant difference ($p > 0.05$).

3.3. Cd and Se Concentrations

The Se concentration in the kidney was significantly increased in the SL group in comparison with the control and Cd groups ($p < 0.05$), and there was no significant difference between the control group and the Cd group ($p > 0.05$). The Cd concentration in the kidney was significantly increased in the Cd group compared with the control group and SL group ($p < 0.05$), but the Cd concentration was significantly decreased in the SL group compared with the Cd group ($p < 0.05$) (Figure 3).

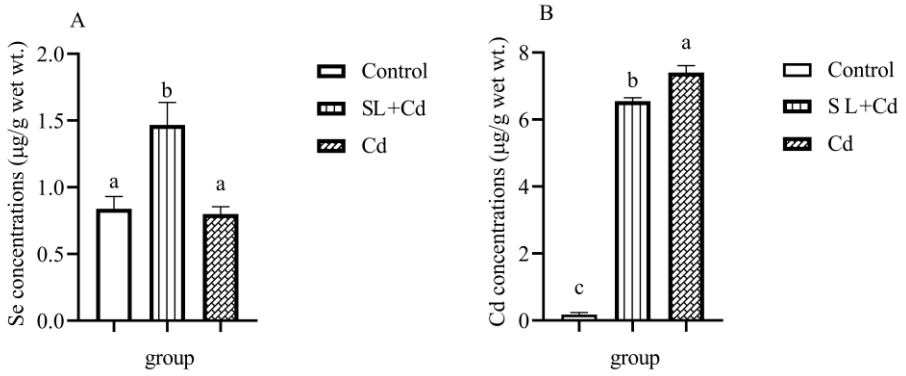

Figure 3. The concentrations of Se (**A**) and Cd (**B**) in the kidney of *L. capito* treated with Cd and/or SL. The data were expressed as mean ± SD. Different letters represented significant differences ($p < 0.05$), and the same letter represented non-significant difference ($p > 0.05$).

3.4. Antioxidant Responses

The results obtained showed that, compared to the control group, the activities of CAT, SOD, and GSH-Px were significantly decreased in the Cd-treated group ($p < 0.05$). However, the MDA content was significantly increased at 14 d and 28 d in the kidney and gill ($p < 0.05$). The activities of CAT, SOD, and GSH-Px in the SL + Cd group were significantly increased, and there was a significant reduction in MDA levels compared with the Cd-treated group in the kidney and gill ($p < 0.05$) (Figures 4 and 5).

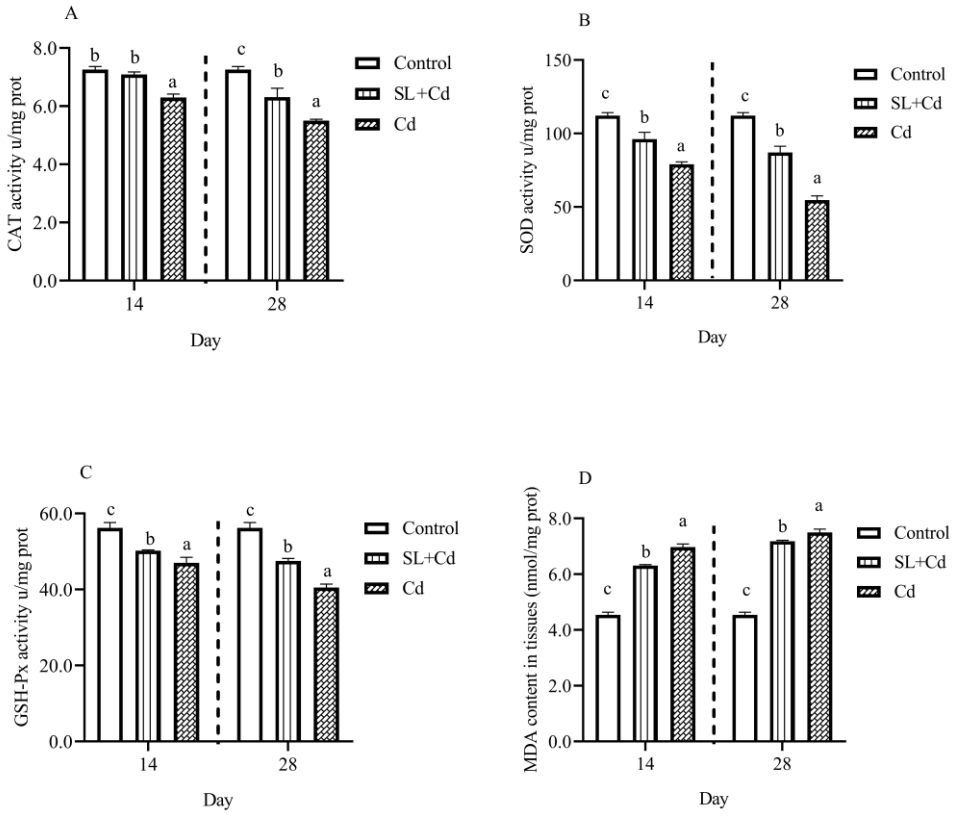

Figure 4. Effects of Cd and/or SL on CAT (**A**), SOD (**B**), GSH-Px (**C**), and MDA (**D**) activities in the kidney of *L. capito*. The data were expressed as mean ± SD. Different letters represented significant differences ($p < 0.05$), and the same letter represented non-significant difference ($p > 0.05$).

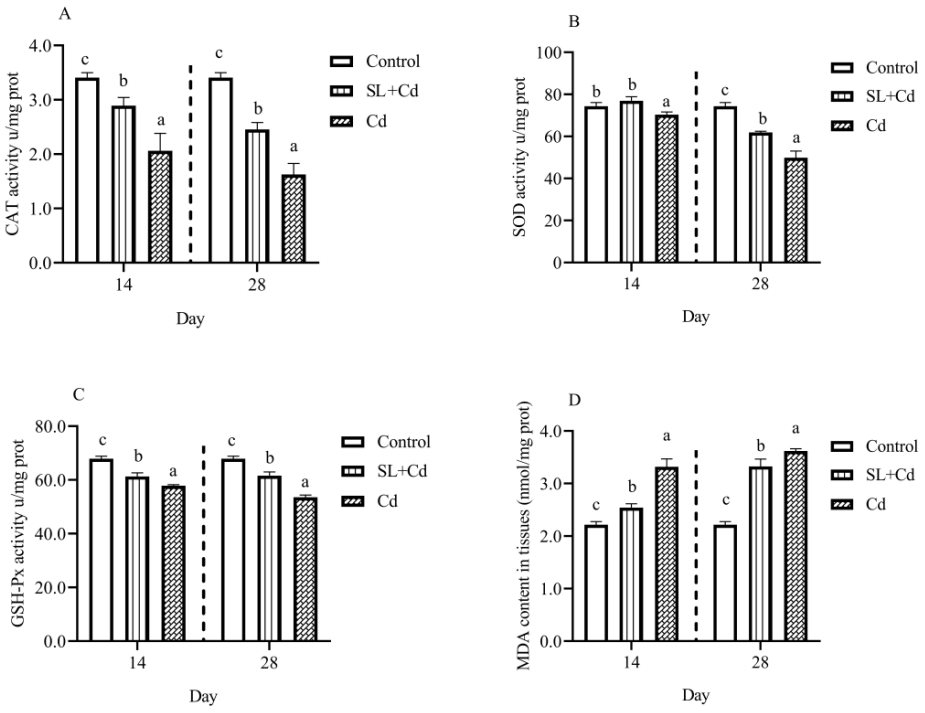

Figure 5. Effects of Cd and/or SL on CAT (**A**), SOD (**B**), GSH-Px (**C**), and MDA (**D**) activities in the gill of *L. capito*. The data were expressed as mean ± SD. Different letters represented significant differences ($p < 0.05$), and the same letter represented non-significant difference ($p > 0.05$).

3.5. Antioxidant-Related Gene Expression

On the 28th day, the mRNA expression levels of *SOD*, *CAT*, *GSH-Px*, *HO-1*, *Keap1*, and *Nrf2* in the kidney and liver tissues of *L. capito* are shown in Figure 6. Compared with the control group, Cd exposure significantly downregulated the mRNA expressions of *SOD*, *CAT*, *GSH-PX*, *HO-1*, and *Nrf2* but upregulated the mRNA expression of *Keap1* ($p < 0.05$). Compared with the Cd group, feeding SL significantly increased the mRNA expression levels of *SOD*, *CAT*, *GSH-Px*, *HO-1*, and *Nrf2* but decreased the mRNA expression level of *Keap1* under Cd stress ($p < 0.05$).

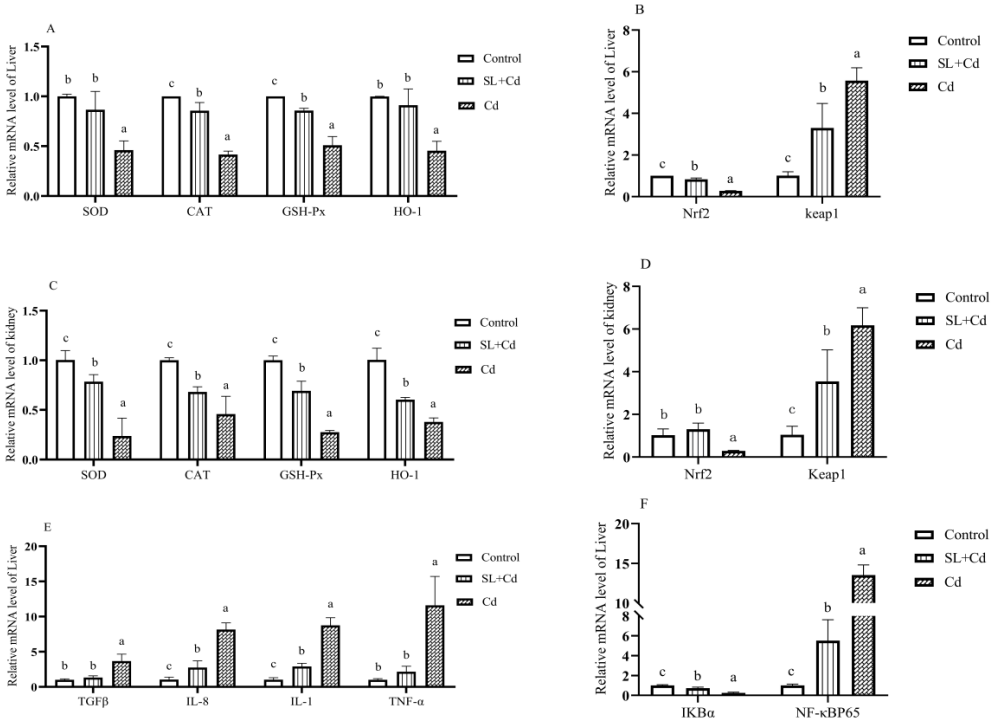

Figure 6. Effects of SL and/or Cd on the mRNA level of *SOD*, *CAT*, *GSH-Px*, *HO-1*, *Nrf2*, and *Keap1* in the kidney and liver of *L. capito* (**A**–**F**). The data were expressed as mean ± SD. Different letters represented significant differences ($p < 0.05$), and the same letter represented non-significant difference ($p > 0.05$).

The mRNA expressions of *TGF-β*, *IL-8*, *IL-1*, *TNF-α*, *NF-kBP65,* and *IkBa* in the liver tissues of *L. capito* are shown in Figure 6. Compared with the control group, Cd exposure significantly upregulated the mRNA expressions of *TGF-β*, *IL-8*, *IL-1*, *TNF-α*, and *NF-kBP65* but downregulated the mRNA expression of *IkBα* ($p < 0.05$). Compared with the Cd group, feeding selenium-enriched *L. plantarum* significantly decreased the mRNA expression levels of *TGF-β*, *IL-8*, *IL-1*, *TNF-α*, *and NF-kBP65* but increased the mRNA expression level of *IkBα* under Cd stress ($p < 0.05$).

4. Discussion

Since many chemical factories are built near the water, aquaculture water is inevitably polluted by various harmful heavy metals, and high levels of heavy metal accumulation have been found in aquatic animals due to bioaccumulation [26]. In this study, the Cd concentration in the kidney was significantly increased in the Cd group. The kidney is one of the main organs for metallothionein (MT) and metal retention, and Cd tends to accumulate in the kidney in the form of Cd metallothionein complexes filtered by the glomerulus, reabsorbed by proximal tubular cells via endocytosis, and degraded by proteases to release Cd, which may lead to Cd accumulation in the kidney [26,27]. After feeding with the SL diet, the accumulation of Cd in the SL + Cd group was significantly decreased compared with that in the Cd group. Se reduced the accumulation of Cd in the

kidney and liver by increasing the affinity of Cd for high-molecular-weight proteins (such as MT), and when the affinity gradually weakens, it may reduce the accumulation of Cd in tissues [24]. Se also forms complexes with Cd, inhibiting the accumulation of Cd [28]. *L. plantarum CCFM8610* promotes bile acid synthesis and bile glutathione excretion in the liver of mice, and Cd is excreted into the intestine with bile. *L. plantarum CCFM8610* entering the gut binds to Cd and is excreted in the faeces, thereby reducing the accumulation of Cd in the kidney and liver [19]. SL reduced Cd accumulation mainly in the following ways: sequestration of Cd into biologically inert complexes, Cd adsorption by *L. plantarum,* or via the action of Se-dependent antioxidant enzymes.

Oxidative stress occurs when the antioxidant system and reactive oxygen species are out of balance [29]. The enzymatic antioxidant defence system consisting of CAT, SOD, and GSH-Px plays an indispensable role in scavenging ROS and preventing lipid peroxidation (LPO). SOD is an important defence enzyme that catalyses the conversion of superoxide anion radicals to H_2O_2 and molecular oxygen, thereby preventing superoxide-induced damage, and CAT and GSH-Px metabolize H_2O_2 into water [1,13]. Cd causes the production of reactive oxygen species (ROS), which in turn damages cells and results in apoptosis [30]. Cd decreased the levels of SOD, GSH-Px, and T-AOC and increased the content of MDA in the liver and kidney of mice [16]. Our results showed that, compared to the control group, the activities of CAT, SOD, and GSH-Px were significantly decreased in the Cd-treated group of kidney and gill. Due to the strong interaction of Cd with the metal-binding moieties (Cu, Zn, and Mn) of SOD, it may be responsible for the decrease in SOD activity [31]. Cd binds to the cysteine of glutathione (GSH), leading to the inactivation of GSH-Px and therefore failing to metabolize H_2O_2 to water [1]. The reduction of CAT, SOD, and GSH-Px means that the fish are subjected to severe oxidative stress, which in turn leads to a large accumulation of H_2O_2. SOD, CAT, GSH-Px, and GSH were significantly decreased by Cd, but Se treatment significantly alleviated the changes in antioxidant levels [32]. Oral administration of *L. plantarum CCFM8610* alleviated the Cd-induced reduction in the activities of CAT, SOD, GSH, and GSH-Px and decreased the content of MDA [10]. The results from our study showed that supplementation with SL in feed can significantly increase the activities of CAT, SOD, and GSH-Px. Treatment with Se alleviates oxidative stress in rat kidney tissues by Cd, mainly by reducing MDA levels and increasing the activities of GSH-Px and TrxR [33]. Se is a form of selenocysteine in the active centres of antioxidant proteins (GSH-Px and TrxR) and is involved in regulating the redox state of cells [34]. Se or *L. plantarum* diets had the ability to enhance the activity of the body's antioxidant enzymes [10,35]. Compared with the cadmium group, the level of antioxidant enzymes in the SL + Cd group was significantly increased. MDA is the product of LPO in organisms. When animal cells undergo oxidative stress, LPO occurs, and the determination of MDA is widely used as an indicator of lipid peroxidation. Our finding was consistent with previous research results showing that Cd exposure resulted in increased MDA content in the kidney and gill [32]. Increased MDA content means high levels of LPO in the fish, and high levels of LPO may lead to tissue oxidative damage. However, the MDA content was significantly decreased after feeding with SL. In conclusion, SL alleviated the oxidative damage of Cd stress by increasing the level of antioxidant enzymes and reducing the content of MDA.

Prolonged and persistent absorption of heavy metals leads to inflammation and oxidative stress. NF-kB is an important regulator of inflammation and is involved in the expression of a large number of genes related to inflammation, immune response, and so on. Tissues are induced to produce inflammation and pathological damage under the stress of chemical sources. In the present study, Cd stress caused the glomerular atrophy space to become larger; for renal tubular epithelial cells, it resulted in sloughing, lysis, nuclear disappearance, hepatocyte nuclear disintegration, disappearance, nuclear pyknosis, hepatocellular necrosis, blurred boundaries of hepatocytes, inflammatory cell infiltration, and massive cellular vacuolization. This significantly increased renal NF-kBp65, TGF-β, IL-8, IL-1, and TNF-α relative expression, and SL supplementation significantly

alleviated the increase in the above indicators. Studies have shown that Cd causes hepatic and renal oxidative stress and inflammation in mice and leads to pathological damage in tissues [11,23]. Elboshy M E et al. found that Cd significantly increased the relative expressions of IL-1β, TNFα, IL-6, and IL-10 in mouse liver [32]. TNFα is an activator of the NF-kB signalling pathway, and Cd may activate TNF α and further the inflammatory response [36]. NF-kB controls the expression of proinflammatory cytokines and chemokines (IL-1α, IL-1β, IL-2, IL-6, IL-8, and TNF-α) in this signalling pathway and plays an important role in regulating inflammation [36]. Therefore, we speculated that inhibiting the expression of TNF α may alleviate the NF-κB-induced inflammatory response [37]. Aluminium (Al) has been reported to potentially cause inflammatory bowel disease (IBD), and some therapeutic approaches to IBD have also focused on inhibiting TNF α functionally [38,39]. In addition, Se antagonizes heavy metals, alleviating inflammation and oxidative stress. Studies have shown that selenium alleviates the expression of the inflammatory factors NF-kBp65, TNF-α, TGF-β, IL-8, and IL-1 induced by mercury (Hg) in the carp spleen and kidney [40]. In addition, the serum AST in the SL+CD group decreased significantly compared with that in the Cd group, further indicating that Se decreased liver damage. The results of the present study illustrate that Se has a protective effect on the inflammatory response induced by Cd in *L. capito*.

Nrf2 is a major regulator of the oxidative stress response, inhibiting ROS production and regulating the transcription of downstream target genes [41]. *Keap1* is a homodimer protein that binds to Cul3/Rbx1, leading to ubiquitination and degradation of *Nrf2* [42]. *HO-1* is an antioxidant gene present in the kidney that decomposes the prooxidant heme, thereby producing antioxidant metabolites [43]. When oxidative stress exists for a long time, the redox balance is broken, exceeding the body's tolerance capacity, resulting in tissue damage and apoptosis, and *Nrf2* is inhibited [44,45]. It has been reported that the expression of *Nrf2* and *HO-1* was inhibited, and the expression of *Keap1* was upregulated in the liver of mice caused by Cd [23]. Zhao et al. found that Cd inhibits the Nrf2 signalling pathway in pig myocardium and reduces the expression of Nrf2 and its downstream target genes NQO1, SOD1, SOD2, CAT, and GSH-Px1 [41]. In this study, Cd stress reduced the expression of Nrf2 and its downstream genes SOD, CAT, GSH Px, and HO-1 in the liver and kidney, and SL alleviated the decline in these indicators. Se is a strong antioxidant. *L. plantarum* has also been reported to improve the antioxidant level of the body. Some studies have shown that Se and *L. plantarum* can reduce Cd toxicity [10,32]. Su et al. (2021) reported that Cd inhibited the expression of the antioxidant genes *Nrf2* and *GSH-Px* in the liver of mice, and this inhibitory effect disappeared after feeding Se-enriched rice [16]. Zhang et al. (2017) reported that Se alleviated Cd-induced inhibition of the *Nrf2-HO-1* system in chicken hepatocytes [46]. Se alleviated the pulmonary toxicity of tacrolimus by upregulating the expression of *HO-1* [47]. Oral and intraperitoneal administration of Cd both caused oxidative stress in the liver and kidney of mice, leading to a decline in GSH, GSH-Px, SOD, and CAT activities, while *L. plantarum* CCFM8610 significantly alleviated oxidative stress in the body [10]. Se protects kidney tissues from Cd toxicity by upregulating the expression of most selenoprotein genes (such as GPx1, GPx2, GPx3, and GPx4) [17]. TGF-β1 is an oxidant, and TGF-β1 inhibits mouse hepatocytes and pancreas β expression levels of SOD, GSH-Px and CAT mRNA in cells [48]. Meanwhile, TGF-β1 can promote the expression of NF-kB [49]. This is similar to our results in that TGF-β decreased the expression levels of SOD, CAT, and GSH-Px and finally resulted in the activities of the corresponding antioxidant enzymes. It also promoted the expression of NF-kB and its downstream genes. Taken together, our results suggest that SL can alleviate the Cd toxicity of *L. capito* from both antioxidative and anti-inflammatory aspects. On the one hand, triggering the Nrf2-HO-1 system promoted the expression of antioxidant genes and selenoprotein genes and supplemented antioxidant enzymes with Cd consumption. On the other hand, it alleviates inflammation by inhibiting the activation of the NF-kB signalling pathway.

5. Conclusions

The results of this study confirm that SL has a protective effect against long-term Cd poisoning of *L. capito*. SL can reduce Cd accumulation in the kidney, alleviate oxidative stress and inflammatory reactions in the liver, kidney, and gill, and reduce liver and kidney tissue damage. We demonstrated that SL can protect against Cd-induced oxidative stress and inflammation. The next research will elaborate on the mechanism of SL against Cd toxicity at the protein level, with a view to making it a food additive and applying it in aquaculture in the future.

Author Contributions: Q.Z. and X.S. writing—review and editing, conceptualization, software, data curation; W.X. writing—review and editing, methodology, data curation; L.G. and S.T. data curation, investigation; H.W. and X.C. investigation. All authors have read and agreed to the published version of the manuscript.

Funding: The work was supported by National Key Research and Development Project (2020YFD0900402, 2019YFD0900405); Central Public-interest Scientific Institution Basal Research Fund (2020ZX0103, 2020TD56); The Heilongjiang Province Natural Science Foundation of China (LH2019C088); Central Public-interest Scientific Institution Basal Research Fund, CAFS (NO. 2020TD31).

Institutional Review Board Statement: The study was approved by the Heilongjiang River Fisheries Research Institute Application for Laboratory Animal Welfare and Ethical review (protocol code 20210815-001, approved on 15 August 2021).

Data Availability Statement: The data presented in this study are available on request from the corresponding author.

Acknowledgments: We would like to thank all of the students in our team for their help with the collection of samples.

Conflicts of Interest: The authors declare no conflict of interest.

References

1. Ognjanovic, B.I.; Markovic, S.D.; Ethordevic, N.Z.; Trbojevic, I.S.; Stajn, A.S.; Saicic, Z.S. Cadmium-induced lipid peroxidation and changes in antioxidant defense system in the rat testes: Protective role of coenzyme Q(10) and vitamin E. *Reprod. Toxicol.* **2010**, *29*, 191–197. [CrossRef]
2. Zhao, L.; Zhao, J.L.; Bai, Z.; Du, J.; Shi, Y.; Wang, Y.; Wang, Y.; Liu, Y.; Yu, Z.; Li, M.Y. Polysaccharide from dandelion enriched nutritional composition, antioxidant capacity, and inhibited bioaccumulation and inflammation in Channa asiatica under hexavalent chromium exposure. *Int. J. Biol. Macromol.* **2022**, *201*, 557–568. [CrossRef]
3. Kumar, N.; Kumar, V.; Panwar, R.; Ram, C. Efficacy of indigenous probiotic *Lactobacillus strains* to reduce cadmium bioaccessibility—An in vitro digestion model. *Environ. Sci. Pollut. Res.* **2017**, *24*, 1241–1250. [CrossRef]
4. Wuana, R.A.; Okieimen, F.E. Heavy metals in contaminated soils: A review of sources, chemistry, risks and best available strategies for remediation. *Int. Sch. Res. Not.* **2011**, *2011*, 402647. [CrossRef]
5. Stohs, S.J.; Bagchi, D. Oxidative mechanisms in the toxicity of metal ions. *Free Radic. Biol. Med.* **1995**, *18*, 321–336. [CrossRef]
6. Pourang, N.; Richardson, C.A.; Mortazavi, M.S. Heavy metal concentrations in the soft tissues of swan mussel (*Anodonta cygnea*) and surficial sediments from Anzali wetland, Iran. *Environ. Monit. Assess.* **2010**, *163*, 195–213. [CrossRef] [PubMed]
7. Shirriff, C.S.; Heikkila, J.J. Characterization of cadmium chloride-induced BiP accumulation in *Xenopus laevis* A6 kidney epithelial cells. *Comp. Biochem. Physiol. C Toxicol. Pharmacol.* **2017**, *191*, 117–128. [CrossRef] [PubMed]
8. Ordiano-Flores, A.; Galvan-Magana, F.; Sanchez-Gonzalez, A.; Paez-Osuna, F. Evidence for Interrupted Biomagnification of Cadmium in Billfish Food Chain Based on Stable Carbon and Nitrogen Isotopes from Southwestern of Gulf of California. *Biol. Trace Elem. Res.* **2020**, *195*, 215–225. [CrossRef]
9. Yeo, W.J.; Ahn, H.J.; Hwang, I.U.; Lee, K.H.; Han, K.N. Cadmium Accumulation and mRNA Expression Associated with Detoxification in Various Organs of Black Seabream (*Acanthopagrus schlegelii*) Exposed to Cadmium-contaminated Diet. *Ocean Sci. J.* **2020**, *55*, 373–382. [CrossRef]
10. Zhai, Q.; Wang, G.; Zhao, J.; Liu, X.; Narbad, A.; Chen, Y.Q.; Zhang, H.; Tian, F.; Chen, W. Protective effects of *Lactobacillus plantarum CCFM8610* against chronic cadmium toxicity in mice indicate routes of protection besides intestinal sequestration. *Appl. Environ. Microbiol.* **2014**, *80*, 4063–4071. [CrossRef]
11. Jihen, E.H.; Imed, M.; Fatima, H.; Abdelhamid, K. Protective effects of selenium (Se) and zinc (Zn) on cadmium (Cd) toxicity in the liver and kidney of the rat: Histology and Cd accumulation. *Food Chem. Toxicol.* **2008**, *46*, 3522–3527. [CrossRef]
12. Pari, L.; Shagirtha, K. Hesperetin protects against oxidative stress related hepatic dysfunction by cadmium in rats. *Exp. Toxicol. Pathol.* **2012**, *64*, 513–520. [CrossRef] [PubMed]

13. Waisberg, M.; Joseph, P.; Hale, B.; Beyersmann, D. Molecular and cellular mechanisms of cadmium carcinogenesis. *Toxicology* **2003**, *192*, 95–117. [CrossRef]
14. Seif, M.M.; Madboli, A.N.; Marrez, D.A.; Aboulthana, W.M.K. Hepato-Renal protective Effects of Egyptian Purslane Extract against Experimental Cadmium Toxicity in Rats with Special Emphasis on the Functional and Histopathological Changes. *Toxicol. Rep.* **2019**, *6*, 625–631. [CrossRef] [PubMed]
15. Kieliszek, M.; Blazejak, S. Selenium: Significance, and outlook for supplementation. *Nutrition* **2013**, *29*, 713–718. [CrossRef] [PubMed]
16. Su, Y.; Li, L.; Farooq, M.U.; Huang, X.; Zheng, T.D.; Zhang, Y.J.; Ei, H.H.; Panhwar, F.H.; Tang, Z.C.; Zeng, R.; et al. Rescue effects of Se-enriched rice on physiological and biochemical characteristics in cadmium poisoning mice. *Environ. Sci. Pollut. Res.* **2021**, *28*, 20023–20033. [CrossRef] [PubMed]
17. Wang, X.; Bao, R.; Fu, J. The Antagonistic Effect of Selenium on Cadmium-Induced Damage and mRNA Levels of Selenoprotein Genes and Inflammatory Factors in Chicken Kidney Tissue. *Biol. Trace Elem. Res.* **2018**, *181*, 331–339. [CrossRef] [PubMed]
18. Kirillova, A.V.; Danilushkina, A.A.; Irisov, D.S.; Bruslik, N.L.; Fakhrullin, R.F.; Zakharov, Y.A.; Bukhmin, V.S.; Yarullina, D.R. Assessment of Resistance and Bioremediation Ability of *Lactobacillus Strains* to Lead and Cadmium. *Int. J. Microbiol.* **2017**, *2017*, 9869145. [CrossRef]
19. Zhai, Q.X.; Liu, Y.; Wang, C.; Zhao, J.X.; Zhang, H.; Tian, F.W.; Lee, Y.K.; Chen, W. Increased Cadmium Excretion due to Oral Administration of *Lactobacillus plantarum* Strains by Regulating Enterohepatic Circulation in Mice. *J. Agric. Food Chem.* **2019**, *67*, 3956–3965. [CrossRef]
20. Liu, Y.; Wu, J.P.; Xiao, Y.; Liu, Q.; Yu, L.L.; Tian, F.W.; Zhao, J.X.; Zhang, H.; Chen, W.; Zhai, Q.X. Relief of Cadmium-Induced Intestinal Motility Disorder in Mice by *Lactobacillus plantarum* CCFM8610. *Front. Immunol.* **2020**, *11*, 619574. [CrossRef] [PubMed]
21. Zhai, Q.X.; Tian, F.W.; Zhao, J.X.; Zhang, H.; Narbad, A.; Chen, W. Oral Administration of Probiotics Inhibits Absorption of the Heavy Metal Cadmium by Protecting the Intestinal Barrier. *Appl. Environ. Microb.* **2016**, *82*, 4429–4440. [CrossRef]
22. Shang, X.; Xu, W.; Zhao, Z.; Luo, L.; Zhang, Q.; Li, M.; Sun, Q.; Geng, L. Effects of exposure to cadmium (Cd) and selenium-enriched *Lactobacillus plantarum* in *Luciobarbus capito*: Bioaccumulation, antioxidant responses and intestinal microflora. *Comp. Biochem. Physiol. C Toxicol. Pharmacol.* **2022**, *257*, 109352. [CrossRef] [PubMed]
23. Liu, C.; Zhu, Y.; Lu, Z.; Guo, W.; Tumen, B.; He, Y.; Chen, C.; Hu, S.; Xu, K.; Wang, Y.; et al. Cadmium Induces Acute Liver Injury by Inhibiting Nrf2 and the Role of NF-kappaB, NLRP3, and MAPKs Signaling Pathway. *Int. J. Environ. Res. Public Health* **2019**, *17*, 138. [CrossRef]
24. Jamwal, A.; Lemire, D.; Driessnack, M.; Naderi, M.; Niyogi, S. Interactive effects of chronic dietary selenomethionine and cadmium exposure in rainbow trout (*Oncorhynchus mykiss*): A preliminary study. *Chemosphere* **2018**, *197*, 550–559. [CrossRef] [PubMed]
25. Qin, D.L.; Jiang, H.F.; Bai, S.Y.; Tang, S.Z.; Mou, Z.B. Determination of 28 trace elements in three farmed cyprinid fish species from Northeast China. *Food Control* **2015**, *50*, 1–8. [CrossRef]
26. Wang, N.; Guo, Z.; Zhang, Y.; Zhang, P.; Liu, J.; Cheng, Y.; Zhang, L.; Li, Y. Effect on intestinal microbiota, bioaccumulation, and oxidative stress of *Carassius auratus gibelio* under waterborne cadmium exposure. *Fish Physiol. Biochem.* **2020**, *46*, 2299–2309. [CrossRef]
27. Wimmer, U.; Wang, Y.; Georgiev, O.; Schaffner, W. Two major branches of anti-cadmium defense in the mouse: MTF-1/metallothioneins and glutathione. *Nucleic Acids Res.* **2005**, *33*, 5715–5727. [CrossRef]
28. Zwolak, I. The Role of Selenium in Arsenic and Cadmium Toxicity: An Updated Review of Scientific Literature. *Biol. Trace Elem. Res.* **2020**, *193*, 44–63. [CrossRef]
29. Unsal, V.; Dalkiran, T.; Cicek, M.; Kolukcu, E. The Role of Natural Antioxidants against Reactive Oxygen Species Produced by Cadmium Toxicity: A Review. *Adv. Pharm. Bull.* **2020**, *10*, 184–202. [CrossRef]
30. Zhao, R.; Yu, Q.; Hou, L.; Dong, X.; Zhang, H.; Chen, X.; Zhou, Z.; Ma, J.; Huang, S.; Chen, L. Cadmium induces mitochondrial ROS inactivation of XIAP pathway leading to apoptosis in neuronal cells. *Int. J. Biochem. Cell Biol.* **2020**, *121*, 105715. [CrossRef]
31. Acharya, U.R.; Mishra, M.; Patro, J.; Panda, M.K. Effect of vitamins C and E on spermatogenesis in mice exposed to cadmium. *Reprod. Toxicol.* **2008**, *25*, 84–88. [CrossRef] [PubMed]
32. El-Boshy, M.E.; Risha, E.F.; Abdelhamid, F.M.; Mubarak, M.S.; Hadda, T.B. Protective effects of selenium against cadmium induced hematological disturbances, immunosuppressive, oxidative stress and hepatorenal damage in rats. *J. Trace Elem. Med. Biol.* **2015**, *29*, 104–110. [CrossRef]
33. El-Sharaky, A.S.; Newairy, A.A.; Badreldeen, M.M.; Eweda, S.M.; Sheweita, S.A. Protective role of selenium against renal toxicity induced by cadmium in rats. *Toxicology* **2007**, *235*, 185–193. [CrossRef]
34. Lee, K.H.; Jeong, D. Bimodal actions of selenium essential for antioxidant and toxic pro-oxidant activities: The selenium paradox (Review). *Mol. Med. Rep.* **2012**, *5*, 299–304. [CrossRef]
35. Saffari, S.; Keyvanshokooh, S.; Zakeri, M.; Johari, S.A.; Pasha-Zanoosi, H.; Mozanzadeh, M.T. Effects of dietary organic, inorganic, and nanoparticulate selenium sources on growth, hemato-immunological, and serum biochemical parameters of common carp (*Cyprinus carpio*). *Fish Physiol. Biochem.* **2018**, *44*, 1087–1097. [CrossRef]
36. Freitas, M.; Fernandes, E. Zinc, cadmium and nickel increase the activation of NF-kappaB and the release of cytokines from THP-1 monocytic cells. *Metallomics* **2011**, *3*, 1238–1243. [CrossRef]

37. Ge, J.; Guo, K.; Zhang, C.; Talukder, M.; Lv, M.W.; Li, J.Y.; Li, J.L. Comparison of nanoparticle-selenium, selenium-enriched *yeast* and sodium selenite on the alleviation of cadmium-induced inflammation via NF-kB/IkappaB pathway in heart. *Sci. Total Environ.* **2021**, *773*, 145442. [CrossRef]
38. Vaghari-Tabari, M.; Jafari-Gharabaghlou, D.; Sadeghsoltani, F.; Hassanpour, P.; Qujeq, D.; Rashtchizadeh, N.; Ghorbanihaghjo, A. Zinc and Selenium in Inflammatory Bowel Disease: Trace Elements with Key Roles? *Biol. Trace Elem. Res.* **2021**, *199*, 3190–3204. [CrossRef]
39. Pineton de Chambrun, G.; Body-Malapel, M.; Frey-Wagner, I.; Djouina, M.; Deknuydt, F.; Atrott, K.; Esquerre, N.; Altare, F.; Neut, C.; Arrieta, M.C.; et al. Aluminum enhances inflammation and decreases mucosal healing in experimental colitis in mice. *Mucosal Immunol.* **2014**, *7*, 589–601. [CrossRef] [PubMed]
40. Shang, X.C.; Wang, B.; Sun, Q.S.; Zhang, Y.; Lu, Y.T.; Liu, S.J.; Li, Y.H. Selenium-enriched *Bacillus subtilis* reduces the effects of mercury-induced on inflammation and intestinal microbes in carp (*Cyprinus carpio var. specularis*). *Fish Physiol. Biochem.* **2022**, *48*, 215–226. [CrossRef] [PubMed]
41. Zhao, X.; Wang, S.; Li, X.; Liu, H.; Xu, S. Cadmium exposure induces TNF-alpha-mediated necroptosis via FPR2/TGF-beta/NF-kappaB pathway in swine myocardium. *Toxicology* **2021**, *453*, 152733. [CrossRef] [PubMed]
42. Niture, S.K.; Khatri, R.; Jaiswal, A.K. Regulation of Nrf2-an update. *Free Radic. Biol. Med.* **2014**, *66*, 36–44. [CrossRef] [PubMed]
43. Shin, D.H.; Park, H.M.; Jung, K.A.; Choi, H.G.; Kim, J.A.; Kim, D.D.; Kim, S.G.; Kang, K.W.; Ku, S.K.; Kensler, T.W.; et al. The NRF2-heme oxygenase-1 system modulates cyclosporin A-induced epithelial-mesenchymal transition and renal fibrosis. *Free Radic. Biol. Med.* **2010**, *48*, 1051–1063. [CrossRef] [PubMed]
44. Du, J.H.; Xu, M.Y.; Wang, Y.; Lei, Z.; Yu, Z.; Li, M.Y. Evaluation of Taraxacum mongolicum flavonoids in diets for Channa argus based on growth performance, immune responses, apoptosis and antioxidant defense system under lipopolysaccharide stress. *Fish Shellfish Immunol.* **2022**, *131*, 1224–1233. [CrossRef]
45. Yu, Z.; Zhao, L.; Zhao, J.L.; Xu, W.; Guo, Z.; Zhang, A.Z.; Li, M.Y. Dietary Taraxacum mongolicum polysaccharide ameliorates the growth, immune response, and antioxidant status in association with NF-κB, Nrf2 and TOR in Jian carp (*Cyprinus carpio* var. Jian). *Aquaculture* **2022**, *547*, 737522. [CrossRef]
46. Zhang, C.; Lin, J.; Ge, J.; Wang, L.L.; Li, N.; Sun, X.T.; Cao, H.B.; Li, J.L. Selenium triggers Nrf2-mediated protection against cadmium-induced chicken hepatocyte autophagy and apoptosis. *Toxicol. In Vitro* **2017**, *44*, 349–356. [CrossRef]
47. Ibrahim, S.A.; Eltahawy, N.F.; Abdalla, A.M.; Khalaf, H.M. Protective effects of selenium in tacrolimus-induced lung toxicity: Potential role of heme oxygenase 1. *Can. J. Physiol. Pharmacol.* **2021**, *99*, 1069–1078. [CrossRef]
48. Reddi, A.S.; Bollineni, J.S. Selenium-deficient diet induces renal oxidative stress and injury via TGF-beta1 in normal and diabetic rats. *Kidney Int.* **2001**, *59*, 1342–1353. [CrossRef]
49. Fernandez-Gonzalez, A. TGF-beta and NF-kappaB Cross-Talk: Unexpected Encounters in the Developing Lung. *Am. J. Respir. Cell Mol. Biol.* **2021**, *64*, 275–276. [CrossRef]

Disclaimer/Publisher's Note: The statements, opinions and data contained in all publications are solely those of the individual author(s) and contributor(s) and not of MDPI and/or the editor(s). MDPI and/or the editor(s) disclaim responsibility for any injury to people or property resulting from any ideas, methods, instructions or products referred to in the content.