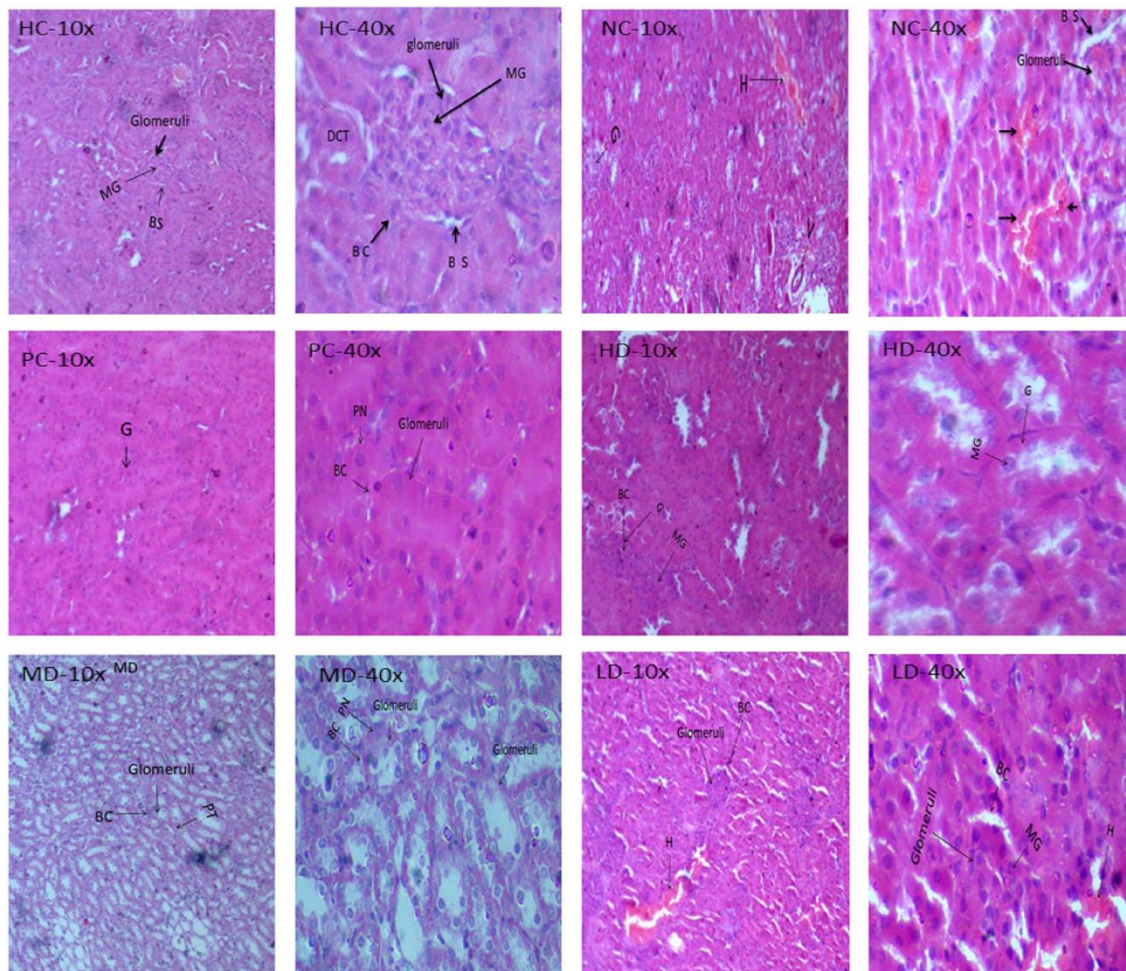
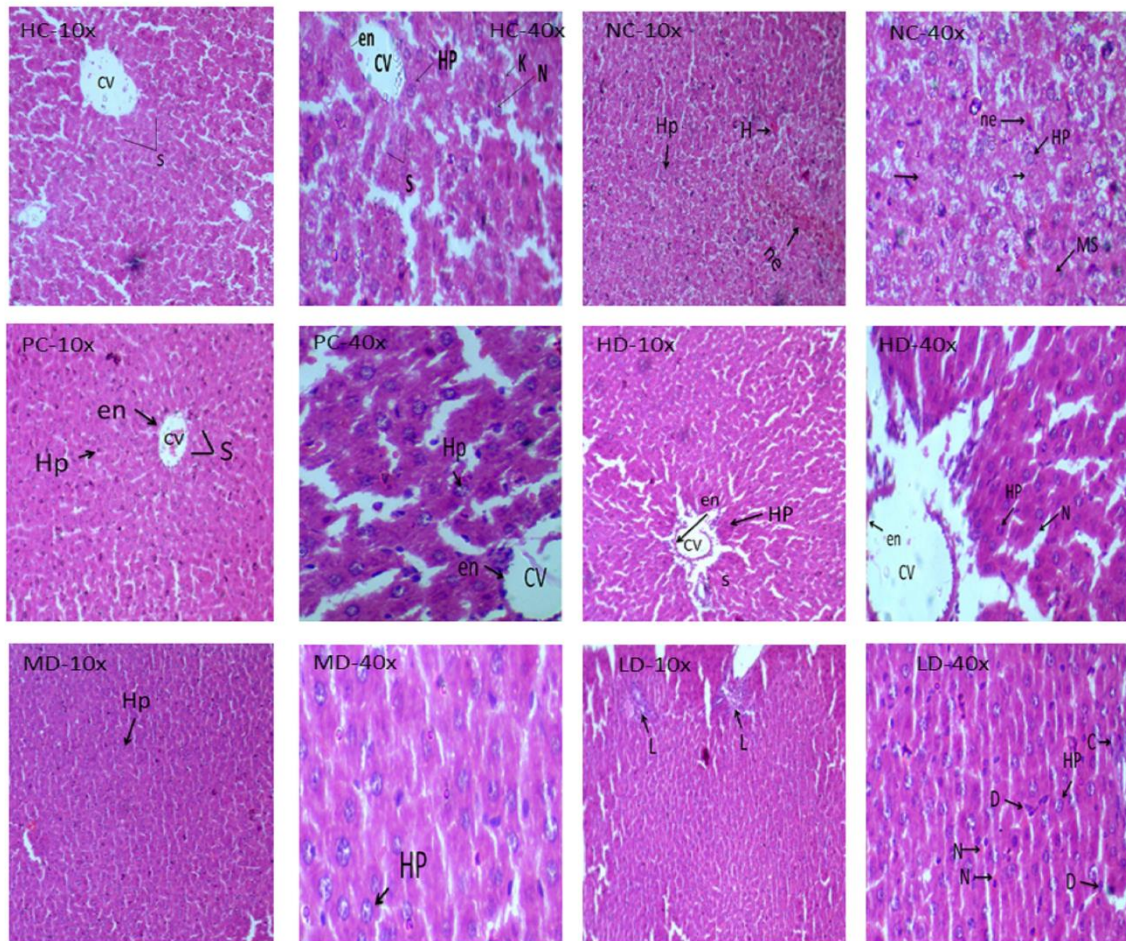


**Figure S1:** Effect of fermented wheat on histology of vital organs. All the slides were photographed at 10× and 40× magnifications

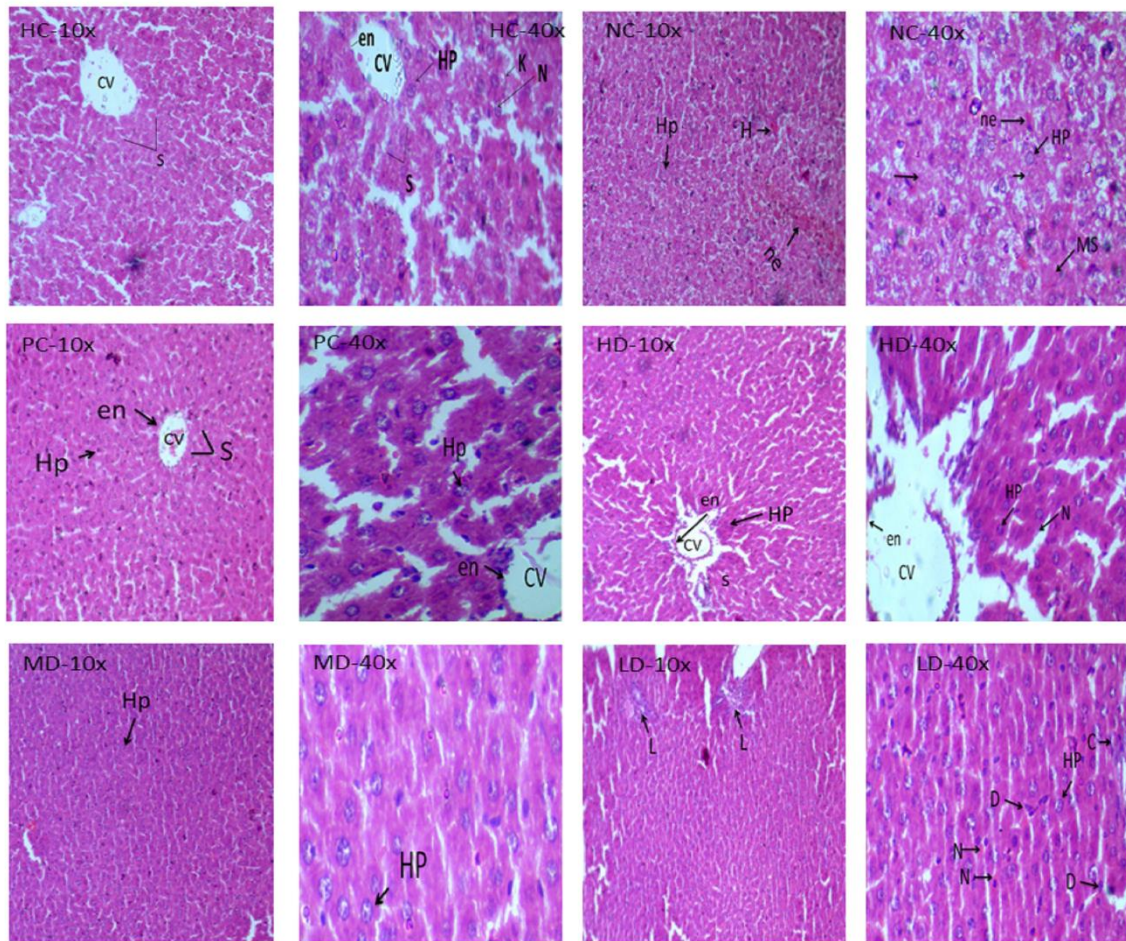


Histology of kidney

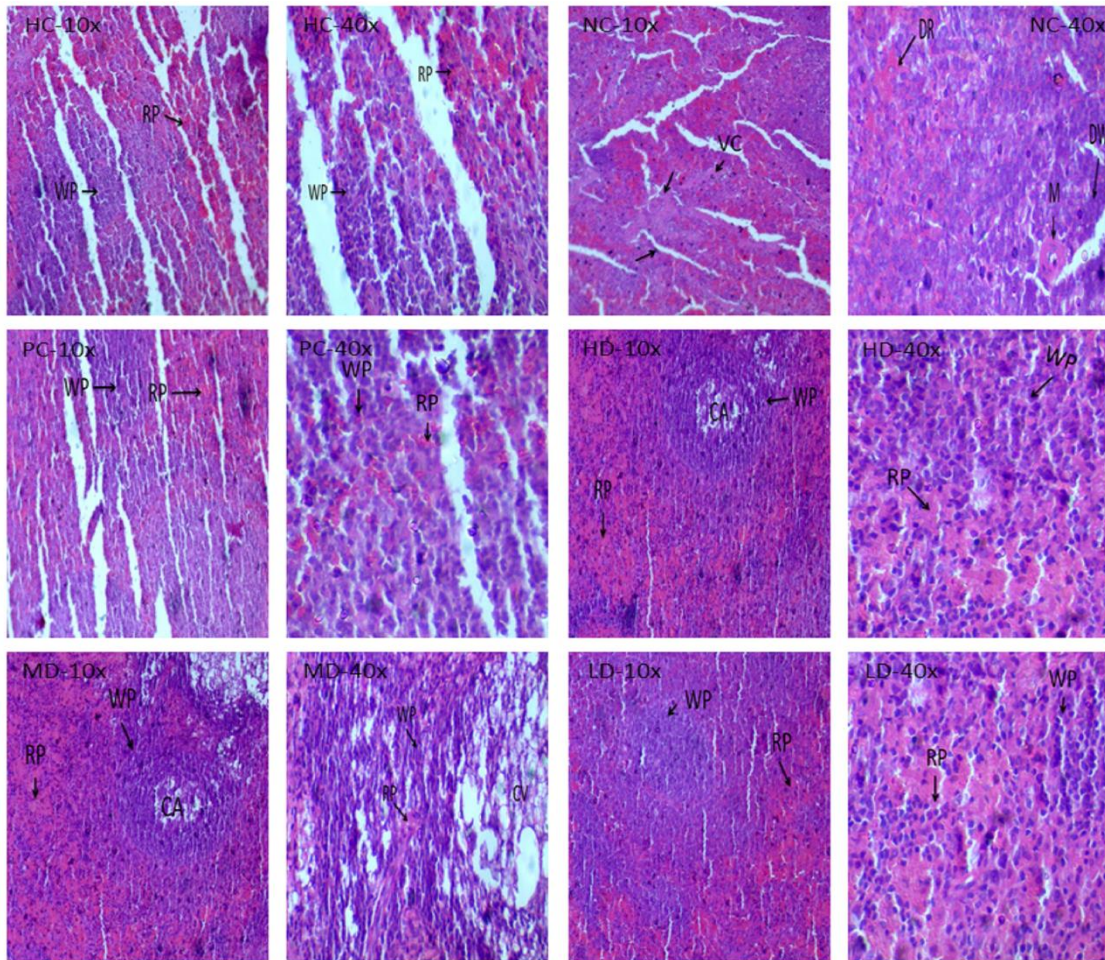


Histology of liver



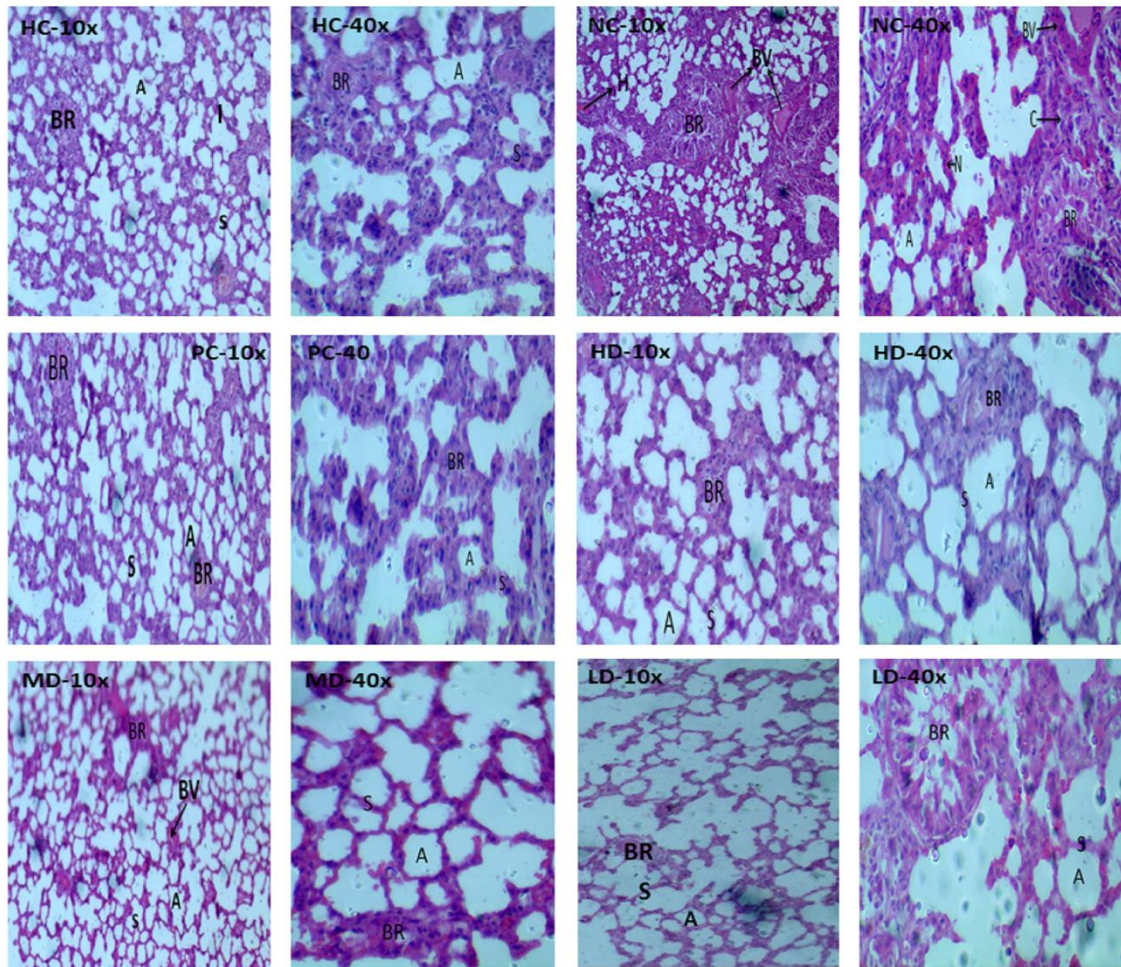


Histology of pancreas

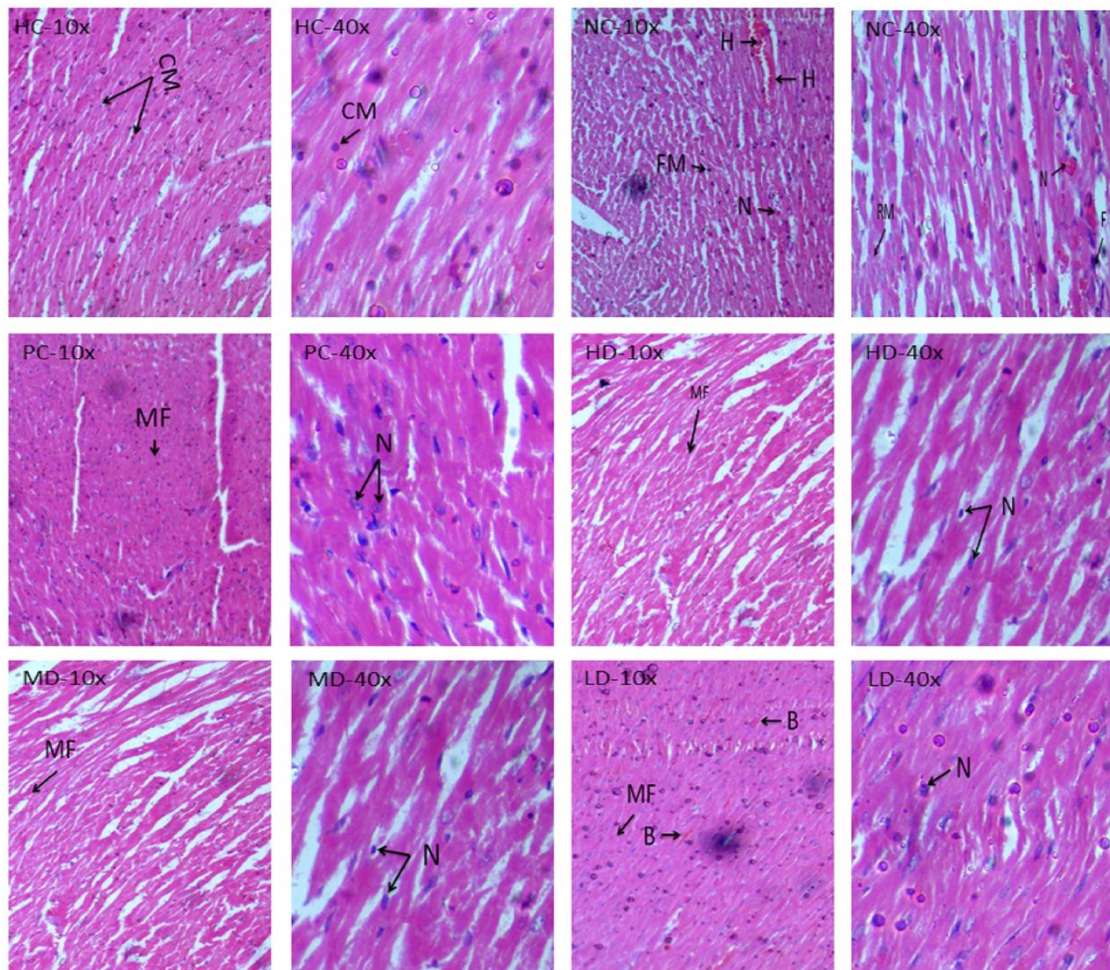


Histology of spleen





Histology of lung



Histology of heart