Journal of
Cardiovascular Development and Disease

MDPI

Review

Coronary Artery Ectasia and Acute Coronary Syndrome: A Contemporary Narrative Review

Fernando Quevedo-Candela [1,2], Stephanie LeBlanc [1,3], Andres Ruhl [1,2], Olivier F. Bertrand [1,2], Christian Nolte-Rickards [4], Erwan Salaun [1], Eric Larose [1,3] and Tomás Cieza [1,2,*]

1 Institut Universitaire de Cardiologie et de Pneumologie de Québec, Université Laval, Quebec, QC G1C 4G5, Canada; feque4@ulaval.ca (F.Q.-C.)
2 Interventional Cardiology Division, Quebec Heart-Lung Institute, 2725 Chemin Sainte-Foy, Québec, QC G1V 4G5, Canada
3 Département de Médecine, Faculté de Médecine, Université Laval, Québec, QC G1V 0A6, Canada
4 Interventional Cardiology, Hospital Central De La Fuerza Aérea Del Peru, Lima 15046, Peru
* Correspondence: tomas.cieza@criucpq.ulaval.ca; Tel.: +1-(418)-656-4657

Abstract

Coronary artery ectasia (CAE) is an uncommon coronary arteriopathy characterized by diffuse or segmental dilatation of an epicardial coronary artery to at least 1.5 times the diameter of an adjacent normal segment. Although traditionally regarded as an incidental angiographic finding, CAE is increasingly recognized as an active substrate for acute coronary syndrome (ACS). Abnormal vascular remodeling, extracellular matrix degradation, endothelial dysfunction, and disturbed flow promote stasis, platelet activation, intraluminal thrombosis, and distal embolization, so myocardial infarction may occur even without a critical obstructive lesion. CAE is reported in approximately 0.9% to 10% of patients with ACS and most frequently involves the right coronary artery. The Markis classification describes anatomical extent, with diffuse and multivessel phenotypes appearing to confer greater thrombotic risk. Coronary angiography remains the diagnostic cornerstone, whereas intravascular ultrasound and optical coherence tomography define vessel-wall pathology, thrombus burden, and stent apposition. Management follows established ACS principles, and percutaneous coronary intervention is technically challenging. The optimal long-term antithrombotic strategy remains unresolved; only one small randomized controlled trial is available, and it did not show a clear benefit of adding oral anticoagulation to antiplatelet therapy, while observational studies do not support routine anticoagulation. Adequately powered multicenter trials are needed to define risk stratification and optimal treatment.

Keywords: coronary artery ectasia; acute coronary syndrome; anticoagulation; percutaneous coronary intervention

Check for updates

Academic Editor: Tuncay Kırış

Received: 7 October 2026
Revised: 10 November 2026
Accepted: 12 November 2026
Published: 16 November 2026

Copyright: © 2026 by the authors. Licensee MDPI, Basel, Switzerland. This article is an open access article distributed under the terms and conditions of the Creative Commons Attribution (CC BY) license.

1. Introduction

Coronary artery ectasia (CAE) is an uncommon anatomical entity with increasingly relevant clinical implications [1,2]. Traditionally regarded as an incidental variant discovered during coronary angiography, CAE has been redefined over the past 15 years as an active pathophysiological substrate capable of promoting intraluminal thrombosis, distal embolization, and myocardial ischemia, even in the absence of significant obstructive stenosis [3,4].

The coexistence of CAE and acute coronary syndrome (ACS) presents a distinct clinical challenge. The interventional cardiologist must manage abnormal anatomy that alters

coronary flow, complicates device selection, and increases procedural risk, while also determining the most appropriate antithrombotic strategy for a phenotype in which specific hemodynamic and thrombotic mechanisms may coexist with conventional atherothrombosis caused by plaque disease [3]. In this setting, the fundamental question is not whether ectasia is clinically relevant—the available evidence indicates that it is—but rather which therapeutic strategy is optimal for each patient subgroup.

The prevalence of CAE in general angiographic series ranges from 0.3% to 8%. In selected cohorts of patients with ACS or ST-segment elevation myocardial infarction (STEMI); however, reported rates may reach 9–10%, suggesting a non-random enrichment of patients with a greater thrombotic burden [3,5,6]. The right coronary artery is the vessel most frequently affected in most series, followed by the left anterior descending artery [7,8].

From a mechanistic standpoint, CAE represents an exaggerated form of positive vascular remodeling characterized by collagen and elastin degradation mediated by matrix metalloproteinases (MMPs), chronic low-grade inflammation, and endothelial dysfunction [9,10]. In the setting of ACS, the dominant mechanism is hemodynamic: slow and disturbed flow within the dilated segment produces stasis, promotes platelet activation, facilitates the formation of organized thrombus, and leads to distal embolization into the microvascular bed, resulting in myocardial dysfunction [3,11,12].

Antithrombotic therapy in this setting lacks a well-established standard. The only available randomized clinical trial, OVER-TIME, compared dual antiplatelet therapy (DAPT) with clopidogrel plus rivaroxaban in 62 patients with ACS and CAE. The combination of a direct oral anticoagulant and antiplatelet therapy did not demonstrate statistically significant superiority, although favorable biological signals were observed [13]. The most recent meta-analysis and a retrospective cohort of 354 patients likewise failed to identify a significant reduction in major adverse cardiovascular events (MACE) with anticoagulation [14,15].

The aim of this review is to provide a critical and updated synthesis of the available evidence regarding CAE in ACS, encompassing its definition, anatomical classification, emerging therapeutic strategies, long-term prognosis, and the knowledge gaps that justify further clinical investigation.

Literature Search Strategy

This is a narrative review and was not conducted according to PRISMA methodology. We searched PubMed/MEDLINE, Embase, Scopus, Web of Science, and the Cochrane Library from inception to August 2026, combining the terms ("coronary artery ectasia" OR "coronary ectasia" OR "coronary artery aneurysm" OR "coronary dilatation" OR "ectatic coronary artery") with ("acute coronary syndrome" OR "myocardial infarction" OR "STEMI" OR "NSTEMI" OR "unstable angina" OR "thrombus" OR "antithrombotic" OR "antiplatelet" OR "anticoagulation" OR "percutaneous coronary intervention" OR "intravascular ultrasound" OR "optical coherence tomography"). Reference lists of retrieved articles and of previous reviews were hand-searched, and the search was last updated in August 2026. Records were eligible if they reported original human data, systematic reviews or meta-analyses, or guideline recommendations on CAE or coronary artery aneurysm in the setting of ACS. Case reports and small case series were retained only when no higher-level evidence addressed the question, for example, anticoagulation for recurrent ACS in the absence of obstructive disease. Two authors (F.Q.-C. and T.C.) independently screened titles and abstracts, and disagreements were resolved by consensus with a third author (A.R). No formal risk-of-bias assessment or quantitative synthesis was performed, and study selection was purposive rather than exhaustive.

2. Definition and Classification

2.1. Definition of Coronary Artery Ectasia

CAE is defined as abnormal luminal dilatation of an epicardial coronary artery measuring at least 1.5 times the diameter of the adjacent normal coronary segment or of the largest reference artery visualized during the same coronary angiographic examination [4,9]. This angiographic definition, which has been adopted almost universally, excludes normal variations in vessel caliber and simple parietal irregularities related to atherosclerosis.

CAE may affect one or several coronary vessels and may present as focal, segmental, extensive, or diffuse dilation. Diffuse CAE is characterized by dilation exceeding 1.5 times the reference diameter and extending over more than 20 mm or more than one third of the vessel length. Localized or segmental ectasia involves a shorter segment. The anatomical severity of CAE exists along a continuum, which has led to the development of multiple classification systems. The most widely used classification system remains the one proposed by Markis [16]. (Table 1).

Table 1. Markis Classification of Coronary Artery Ectasia.

Markis Types	Anatomic Pattern	Proposed Thrombotic Implications	Clinical Message
I	Diffuse ectasia in 2–3 major coronary vessels	Highest	Extensive multivessel disease; associated with slow flow, recurrent ACS, and greater thrombotic burden.
II	Diffuse ectasia in one vessel plus segmental ectasia in another	Intermediate–high	Mixed diffuse and segmental involvement; risk depends on the extent of ectasia and coronary flow.
III	Diffuse ectasia in a single vessel	Intermediate	Risk is mainly determined by the affected vessel, slow flow, and coexisting stenosis.
IV	Segmental or localized ectasia in a single vessel	Lower	Usually limited hemodynamic impact; risk increases when stenosis coexists near the ectatic segment.

Adapted from the original Markis classification [16]. CAE, coronary artery ectasia; ACS, acute coronary syndrome.

Coronary artery aneurysm refers to a focal, well-defined dilation—often saccular or fusiform—that exceeds 1.5 times the diameter of the adjacent normal segment and is less than 20 mm in length. Histologically, true aneurysms preserve all three layers of the vascular wall—the intima, media, and adventitia—whereas pseudoaneurysms are characterized by loss of wall integrity and adventitial injury. Among coronary artery aneurysms, saccular morphology is characterized by a transverse diameter greater than the longitudinal diameter, whereas fusiform morphology is characterized by a longitudinally elongated dilation. Saccular morphology may be associated with greater flow disturbance and thrombotic risk; however, the clinical risk also depends on aneurysm size, location, mural thrombus, and the underlying etiology.

In clinical practice, this distinction may have etiological implications. For example, saccular aneurysms are more frequently associated with vasculitis, particularly Kawasaki disease in children, whereas diffuse ectasia is predominantly associated with atherosclerosis in adults [9,10]. Giant coronary artery aneurysm (CAA) is commonly defined as a dilatation with a diameter greater than 8 mm or more than four times the reference vessel diameter. CAE and CAA may coexist in the same patient and represent a shared pathophysiological spectrum with important similarities in etiology and management [17,18].

The distinction between CAE and CAA is conceptually important, although the terms are frequently used interchangeably in the literature. Although CAE generally refers to a more diffuse or longitudinal dilation involving a substantial portion of the vessel, in the Markis Classification, the type IV CAE refers to localized or segmental ectasia and may therefore morphologically overlap with a focal coronary artery aneurysm. Therefore, the distinction between these entities should be based on the extent, morphology, and pattern of vessel involvement rather than on morphology alone [2,10].

2.2. Classification Systems

The Markis classification, originally proposed in 1976 [16], provides an anatomical framework for stratifying the anatomical extent of CAE and its potential thrombotic implications and clinical risk [2,4]. The criteria and clinical characteristics of each type are summarized in Table 1 and illustrated in Figure 1. Accordingly, more diffuse phenotypes, particularly Markis Type I, may be associated with greater coronary flow disturbance and higher thrombotic or ACS risks, whereas more focal phenotypes, particularly Types III and IV, are generally considered to have a lower hemodynamic impact. Types I and II are more frequently associated with thrombotic ACS presentations [19,20]. However, these associations are based mainly on observational data and may be modified by concomitant atherosclerotic disease and coronary stenosis [19,20]. Prospective validation of Markis-based stratification remains a priority for individualized treatment selection.

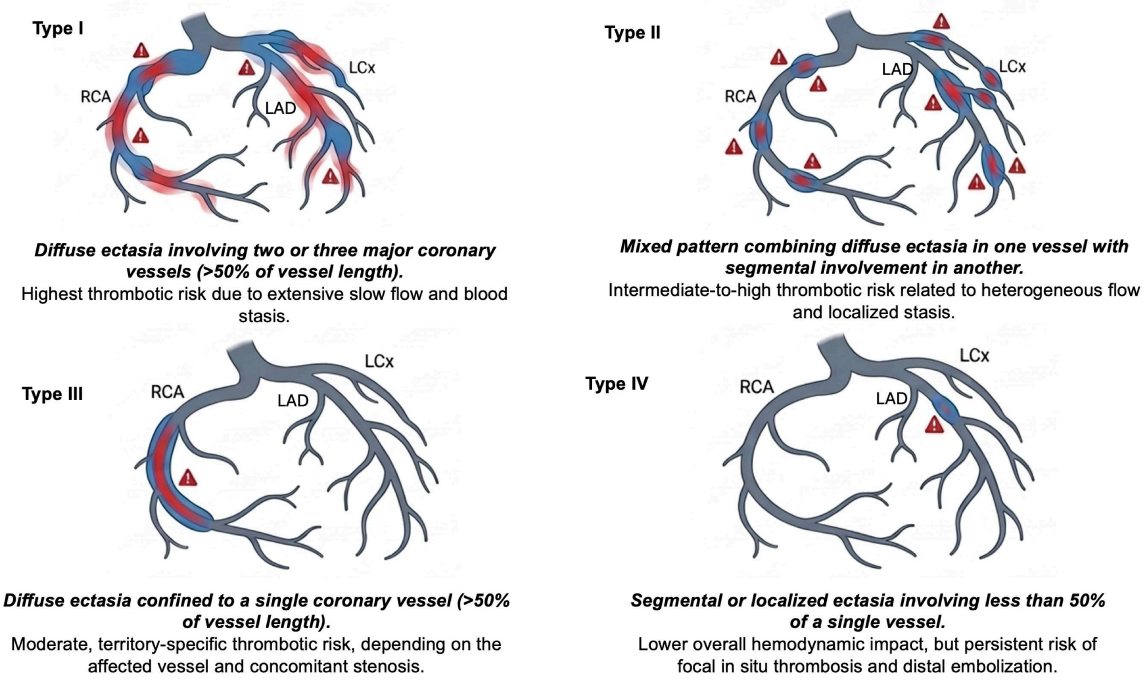

Figure 1. Markis classification and thrombotic risk in coronary artery ectasia. Original schematic prepared by the authors, based on the anatomical types described by Markis et al. [16]; the original publication did not include a schematic representation. Type I, diffuse multivessel involvement; Type II, mixed diffuse and segmental patterns; Type III, diffuse single-vessel involvement; Type IV, focal segmental dilation. Red-shaded areas and icons highlight zones of flow stasis and high thrombotic potential. Adapted from Markis JE et al. [16].

Several classification systems have been proposed to complement the Markis classification. Intravascular ultrasound (IVUS) evaluation allows the identification of four anatomopathological patterns in patients with coronary artery aneurysm or ectasia:

- True aneurysm, with preservation of the three vascular layers—the intima, media, and adventitia.
- Pseudoaneurysm, with loss of wall integrity and a hematoma contained by the adventitia or perivascular tissue.
- Complex plaque with an aneurysmal appearance secondary to plaque rupture or dissection.
- A normal segment with an aneurysmal appearance, generally caused by an imaging artifact or an anatomical variant adjacent to a stenosis [17].

2.3. Underlying Causes of Coronary Artery Ectasia

In adult series involving CAE associated with ACS, atherosclerosis accounts for more than 70% of cases and frequently coexists with traditional cardiovascular risk factors, including diabetes mellitus, hypertension, dyslipidemia, and smoking [21,22]. In addition to atherosclerosis—the most frequent cause in Western adults—and Kawasaki disease—the predominant etiology in pediatric patients—CAE may have congenital, inflammatory, infectious, iatrogenic, or connective-tissue-related causes. These include systemic vasculitis, systemic lupus erythematosus, polyarteritis nodosa, syphilis, Chagas disease, angioplasty with high-pressure balloon inflation, Marfan syndrome, and Ehlers–Danlos syndrome [3,10,23].

- According to an etiopathogenic classification, three principal mechanisms underlie the development of CAA and CAE:
- Atherosclerotic disease, responsible for approximately 70–80% of cases in Western adults.
- Non-inflammatory disease, including spontaneous coronary artery dissection, congenital malformations, iatrogenic disease following percutaneous coronary intervention (PCI) or cardiac surgery, and thoracic trauma [24].
    - Spontaneous coronary artery dissection is included in this group because it is a non-atherosclerotic, non-inflammatory arteriopathy that may involve the epicardial coronary wall and must be distinguished from true ectasia in young patients, particularly women [24,25].
- Inflammatory disease, including Kawasaki disease, Takayasu arteritis, polyangiitis, connective tissue diseases such as systemic sclerosis, lupus, and Sjögren syndrome, sarcoidosis, and, more recently, SARS-CoV-2 infection. SARS-CoV-2 infection has been recognized as an emerging cause of CAE in adults through mechanisms that may include activation of the angiotensin-converting enzyme 2 (ACE2) receptor in endothelial cells, cytokine storm with direct endothelial dysfunction, and systemic vascular inflammation mediated by multisystem inflammatory syndrome [18], but causality remains uncertain.

3. Epidemiology

3.1. General Prevalence in Angiographic Series

The prevalence of CAE in unselected angiographic series varies considerably according to the definition used, measurement technique, demographic characteristics of the population, and the operator's level of detection. Overall, the literature reports rates ranging from 0.3% to 8% of coronary angiograms [4,22,26].

In a five-year, two-center retrospective study conducted in Yazd, Iran, involving a cohort of patients who underwent cardiac catheterization for various indications, the prevalence of isolated CAE was 1.7%. The cohort was predominantly male (80.4%), and CAE was significantly associated with hypertension, diabetes, and hypercholesterolemia [26].

Larger institutional registries from Europe and the Americas suggest prevalence rates of 1–5% among patients undergoing coronary angiography. However, the strict application

of quantitative criteria— defined by an ectatic-to-normal segment diameter ratio of at least 1.5—tends to yield lower estimates than visual assessment alone [4,20].

With respect to demographic characteristics, men consistently predominate in the published literature, with male-to-female ratios ranging from approximately 4:1 to 10:1 in the largest angiographic series [20,26].

3.2. Prevalence in the Setting of ACS and STEMI

The prevalence of CAE is substantially higher in ACS cohorts than in elective angiographic series, supporting the hypothesis that ectasia acts as an active risk factor for acute thrombotic events rather than merely representing an incidental finding [3,6,27]. Consistent with this concept, the retrospective CAESAR registry found frequent coexistence of dilated and obstructive coronary disease, with major adverse cardiovascular events occurring in 38.1% of patients during a median follow-up of 18.9 months [28].

In a cohort of 4788 patients with acute myocardial infarction who underwent coronary angiography, CAE was identified in 3.6% of patients [29]. In a consecutive STEMI cohort, CAE was present in 10.4% (56 of 539) of patients, and the 30-day composite endpoint did not differ significantly between patients with and without CAE (8.93% [5/56] versus 10.35% [50/483]) [30]. Similarly, CAE was reported in 5.4% of patients in an angiographic ACS cohort, whereas a prevalence of 0.9% was observed among 966 patients with ACS in Pakistan [5,31].

In a cohort of ACS patients, unadjusted mortality was higher among patients with ectasia, reaching 8.2%, compared to the control group of randomly selected ACS patients without CAE. Worse prognosis was also associated with male sex, history of previous ACS, and presentation with STEMI [2].

In a cohort of 272 patients with CAE, ectatic segments measuring at least 39 mm in length or at least 6 mm in diameter were more strongly associated with ACS. These findings suggest that precise anatomical quantification of CAE, rather than its mere presence, is important for individual risk stratification [32]. However, these anatomical thresholds should be externally validated before being incorporated into follow-up and treatment algorithms.

The right coronary artery is the vessel most frequently affected in prior series, followed by the left anterior descending artery and, less commonly, the circumflex artery [8,20,22,33]. The predominance of right coronary artery involvement may be related to inherent anatomical characteristics of this vessel, including its greater length and reduced perivascular support in certain segments, although the underlying biology of this pattern remains incompletely understood.

4. Pathophysiology

4.1. Positive Vascular Remodeling and Extracellular Matrix Degradation

At its biological core, CAE may represent an exaggerated form of compensatory positive remodeling of the coronary arterial wall. Under normal conditions, positive remodeling is an adaptive response to plaque expansion that preserves the arterial lumen (Glagov's phenomenon). In CAE, this process becomes dysregulated and leads to abnormal expansion of the arterial wall with loss of structural integrity within the media [4,9].

The central cellular and molecular mechanisms involve overactivation of extracellular matrix metalloproteinases, particularly MMP-2, MMP-9, and MMP-12. These enzymes degrade type IV collagen, elastin, and other components of the extracellular scaffold that provide rigidity and mechanical strength to the vascular wall [9,10].

MMP activation occurs in the context of vascular inflammation. Macrophages, mast cells, and T lymphocytes infiltrate the adventitia and media, releasing proinflammatory cytokines such as tumor necrosis factor alpha, interleukin-6, and interleukin-1 beta. These

cytokines, in turn, stimulate MMP synthesis and secretion by vascular smooth muscle cells and adventitial fibroblasts [10,34].

At the same time, the activity of tissue inhibitors of metalloproteinases (TIMPs) may be reduced in CAE, shifting the proteolytic balance toward net matrix degradation [9]. This process creates a positive feedback loop: matrix degradation weakens the arterial wall, progressive dilatation generates abnormal shear stress, and hemodynamic stress acting on dysfunctional endothelium perpetuates local inflammation.

4.2. Inflammation and Endothelial Dysfunction

Traditional cardiovascular risk factors, including hypertension, dyslipidemia, smoking, and diabetes mellitus, are frequently reported in patients with CAE. However, their association with coronary dilatation is not consistent. Diabetes has been inversely associated with CAE in some studies, potentially reflecting diabetes-related negative vascular remodeling and reduced arterial dilatation [35]. Conversely, among patients with STEMI and an ectatic infarct-related artery, hypertension and smoking—but not diabetes—were independently associated with CAE. In this setting, CAE was also associated with a higher incidence of no-reflow during primary PCI, although one-year mortality and revascularization rates were similar to those observed in patients without ectasia [36]. Long-term data further suggest that the angiographic severity of ectasia has prognostic relevance, with high-grade CAE associated with a greater burden of adverse cardiovascular events and a potential benefit from antithrombotic therapy [37]. These findings support a heterogeneous pathophysiology in which conventional risk factors may contribute to, but do not fully explain, the inflammatory, endothelial, and remodeling processes underlying CAE.

Endothelial dysfunction is a frequent feature of CAE and often precedes the appearance of angiographically visible dilatation [4,10]. Markers of endothelial dysfunction—including reduced nitric oxide bioavailability, increased von Willebrand factor, and overexpression of adhesion molecules such as ICAM-1, VCAM-1, and E-selectin—have been documented more prominently in patients with CAE than in individuals with normal-caliber coronary arteries [3,9]. Endothelial dysfunction also promotes platelet adhesion and aggregation on the injured endothelium of ectatic segments, creating a procoagulant environment that facilitates thrombus formation even in the absence of plaque rupture [3,12].

Inflammatory biomarkers in CAE and CAA have been extensively investigated in recent years. Low-grade systemic inflammation, reflected by elevated high-sensitivity C-reactive protein, increased fibrinogen levels, and moderate leukocytosis, has been described in patients with stable CAE. These markers increase substantially during ACS associated with CAE, suggesting that acute inflammation superimposed on a chronic substrate may trigger the thrombotic event [2,34]. In particular, high-sensitivity C-reactive protein is likewise increased in multiple series and is one of the most reproducible markers of chronic inflammatory activation in this phenotype. Some studies have also reported an association between CAE and increased erythrocyte sedimentation rate [9,34].

Interleukin-6 is significantly elevated in patients with CAE or CAA compared with patients with isolated obstructive coronary artery disease and healthy controls, further reflecting sustained vascular inflammatory activation beyond conventional atherosclerosis [17,18].

Soluble adhesion molecules, including VCAM-1, ICAM-1, and E-selectin, are elevated in patients with CAE or CAA, providing evidence of sustained endothelial activation [17,18]. Moreover, plasminogen activator inhibitor-1 activity is significantly reduced in patients with CAE, facilitating increased plasmin activity and, consequently, greater activation of MMPs through conversion of pro-MMPs into their active forms [17].

With regard to extracellular matrix proteolysis, increased levels of MMP-2, MMP-3, MMP-8, MMP-9, and MMP-12 have been documented in the vascular walls and plasma of pa-

tients with CAE or CAA, together with a concomitant reduction in TIMPs. This MMP/TIMP imbalance represents a central mechanism in exaggerated positive vascular remodeling.

Moreover, plasma MMP-9 levels correlate directly with fibrinogen, C-reactive protein, and interleukin-6 activity, and this biochemical profile may predict the risk of acute myocardial infarction in these patients [17].

Emerging Markers

Endocan, also known as endothelial cell-specific molecule-1, is a soluble proteoglycan secreted by endothelial cells in response to proinflammatory cytokines. It has emerged as a marker of endothelial activation and dysfunction, and its plasma levels correlate with the anatomical severity of CAE as quantified by the total volume of dilatation [17,18].

Circulating microRNAs have emerged as potential differential biomarkers. Recent studies have identified miR-451a and miR-328-3p as improving the prediction of CAE or CAA compared with isolated coronary artery disease and control populations, although systematic clinical application remains under prospective validation [17].

With respect to adaptive immunity, a predominance of the Th2 profile has been described in patients with CAE or CAA compared with patients with isolated obstructive coronary artery disease [18]. In a cohort of 319 adults with CAE or CAA, antinuclear antibodies were positive in 40% of patients, suggesting an underlying autoimmune component in a clinically relevant subgroup. However, because antinuclear antibodies may also be prevalent in the general population, this finding should be interpreted cautiously [18]. Table 2 summarizes the biomarkers.

Table 2. Biomarkers of Inflammation, Vascular Remodeling, and Endothelial Dysfunction in Coronary Artery Ectasia and Coronary Artery Aneurysm.

Biomarkers	Category	Change in CAE/CAA	Mechanisms or Clinical Correlation
IL-6	Proinflammatory cytokine	Increased versus isolated CAD and controls	Sustained vascular inflammatory activation; correlates with CAE severity
hsCRP	Systemic inflammatory marker	Increased	Marker of low-grade chronic inflammation; predictor of cardiovascular events
Endocan (ESM-1)	Soluble endothelial proteoglycan	Increased	Endothelial activation and dysfunction; correlates with total dilatation volume
Fibrinogen	Acute-phase protein	Increased	MMP-9 activity correlates directly with fibrinogen, CRP, and IL-6 as predictors of myocardial infarction
VCAM-1, ICAM-1, E-selectin	Endothelial adhesion molecules	Increased	Sustained endothelial activation; platelet and leukocyte adhesion
MMP-2, MMP-3, MMP-8, MMP-9, MMP-12	Matrix metalloproteinases	Increased in plasma and tissue	Collagen and elastin degradation; exaggerated positive remodeling
TIMPs	Tissue inhibitors of MMPs	Decreased	MMP/TIMP imbalance; promotes extracellular matrix degradation
PAI-1	Plasminogen activator inhibitor-1	Decreased	Increased plasmin activity, greater pro-MMP activation, and enhanced proteolysis
miR-451a	Circulating microRNA	Differential expression versus CAD	Improves prediction of CAE or CAA; prospective validation ongoing

Table 2. *Cont.*

Biomarkers	Category	Change in CAE/CAA	Mechanisms or Clinical Correlation
miR-328-3p	Circulating microRNA	Differential expression versus CAD	Complementary molecular marker; prospective validation ongoing
ANA	Marker of systemic autoimmunity	Positive in approximately 40% of patients	Suggests an autoimmune component in a relevant subgroup; should be interpreted cautiously

CAE, coronary artery ectasia; CAA, coronary artery aneurysm; CAD, obstructive coronary artery disease; CRP, C-reactive protein; ESM-1, endothelial cell-specific molecule-1; hsCRP, high-sensitivity C-reactive protein; IL-6, interleukin-6; MMP, matrix metalloproteinase; TIMP, tissue inhibitor of metalloproteinase; PAI-1, plasminogen activator inhibitor-1; ANA, antinuclear antibodies. Evidence is derived primarily from observational studies [17,18].

The inflammatory substrate of CAE provides a rationale for anti-inflammatory therapy, although clinical benefit remains unproven. Statins and angiotensin-converting enzyme inhibitors have reduced inflammatory biomarkers in small CAE studies, without establishing improved clinical outcomes [38]. Colchicine has shown cardiovascular benefit in selected atherosclerotic coronary disease populations, but evidence cannot be directly extrapolated to CAE [39,40]. Elevated hsCRP alone therefore does not establish a CAE-specific indication for colchicine; its role requires dedicated prospective evaluation [38,39].

4.3. Slow Coronary Flow, Stasis, and Turbulence

The pathophysiological mechanism most directly responsible for ACS in CAE is the hemodynamic alteration caused by luminal expansion. According to the principle of flow continuity, when the cross-sectional area of a vessel increases within an ectatic segment, blood-flow velocity decreases proportionally. This reduction in velocity produces stasis and regions of recirculating and disturbed flow, particularly at the margins of the dilated segment and at the abrupt transition between normal and ectatic vessel segments [3,7,12].

Prolonged stasis promotes:

- Local accumulation of activated coagulation factors without adequate clearance by normal flow, activating the coagulation cascade under conditions resembling Virchow's triad: stasis, endothelial dysfunction, and hypercoagulability [3,7].
- Formation of red thrombus, rich in fibrin and erythrocytes, which may become organized into successive layers adherent to the wall of the ectatic segment [7,12].
- Distal embolization of thrombotic fragments into the microvascular bed, including arterioles and capillaries, resulting in microvascular obstruction, no-reflow, and regional myocardial dysfunction [3,11,41].

Slow coronary flow was defined angiographically as a corrected TIMI frame count (cTFC) greater than 27 frames in at least one epicardial coronary vessel, or TIMI flow grade 2, in the absence of an obstructive epicardial lesion (no stenosis ≥ 40%) [42,43]. This finding may complicate the differential diagnosis with vasospasm or with other causes of myocardial infarction with non-obstructive coronary arteries (MINOCA) during emergency coronary angiography [11,22].

Segmental backflow—defined as contrast progressing retrogradely from the ectatic segment toward the ostium during systole—and intraluminal contrast stasis are angiographic findings that should direct the operator toward CAE as a possible mechanism of ACS [2,11,22].

Key Pathophysiological Concept: The Virchow-like triad in coronary artery ectasia comprises stasis caused by slow flow within dilated segments, endothelial dysfunction with local prothrombotic activation, and systemic hypercoagulability promoted by chronic

inflammation. The interaction among these three components creates the substrate for ACS, even in the absence of significant obstructive stenosis.

4.4. Thrombogenesis and Distal Embolization

Intraluminal thrombus formation in CAE may occur through two principal pathways. The first is in situ thrombosis, in which the clot forms de novo within the ectatic segment without identifiable plaque rupture. The second is thrombosis overlying a plaque, in which concomitant atherosclerosis provides a lipid core or vulnerable plaque that ruptures within the ectatic segment or in a stenosis proximal to it [3,7].

In clinical practice, both mechanisms may coexist in the same patient, complicating mechanistic diagnosis during emergency coronary angiography.

Distal embolization of thrombotic fragments from a proximal ectatic segment into distal arterioles and capillaries explains myocardial infarction in patients with CAE without an obstructive culprit lesion [3,12,41]. This process results in simultaneous occlusion of multiple small-caliber vessels, producing a distribution of myocardial injury that differs from the classic proximal obstruction of a major epicardial artery.

The local inflammatory response to distal thrombus further amplifies tissue injury through complement activation and the release of reactive oxygen species [3,12]. The pathophysiological cascade from structural remodeling to ACS is summarized in Figure 2.

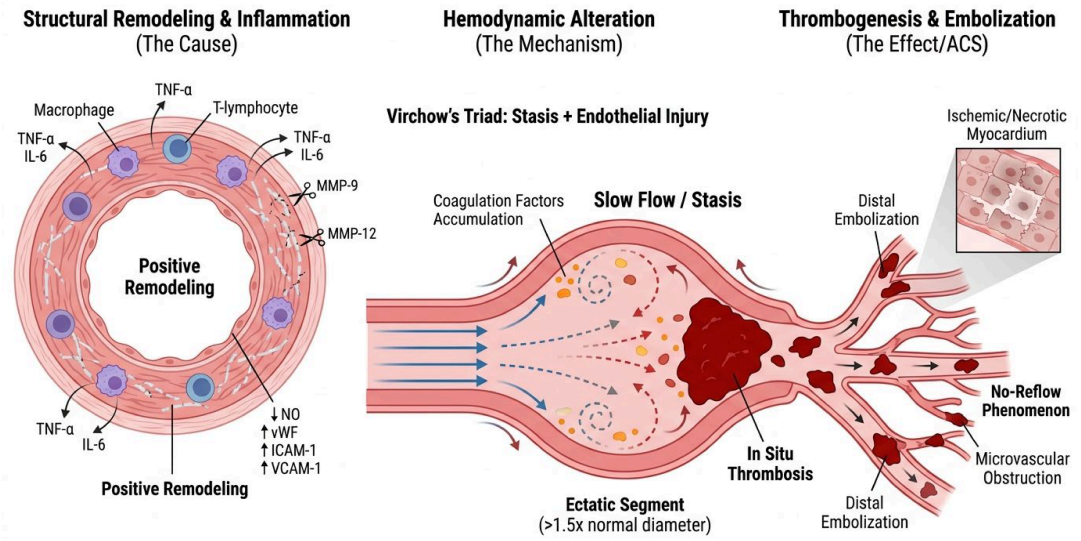

Figure 2. Pathophysiology of coronary artery ectasia: from structural remodeling to ACS. The cascade begins with structural remodeling (MMP-mediated matrix degradation and inflammation), leading to hemodynamic alterations (flow stasis and Virchow's triad within the ectatic segment). This creates a prothrombotic environment resulting in in situ thrombosis, distal embolization, and microvascular obstruction (no-reflow), ultimately precipitating acute coronary syndromes (ACSs).

5. Clinical Presentation in the Setting of Acute Coronary Syndrome

5.1. ST-Segment Elevation Myocardial Infarction

CAE may present across the entire ACS spectrum. STEMI represents its most severe acute manifestation and is one of the settings in which the thrombotic angiographic phenotype has been best characterized.

Acute thrombotic occlusion of the right coronary artery—the vessel most frequently affected by ectasia—accounts for most cases of inferior infarction in patients with CAE. However, anterior STEMI caused by thrombosis within an ectatic left anterior descending artery has also been documented [3,29,44,45].

The clinical presentation is generally indistinguishable from that of conventional STEMI due to atherosclerotic plaque disruption and typically includes pressure-like chest pain at rest, radiation to the left arm or jaw, diaphoresis, and ST-segment elevation on the electrocardiogram. Angiography, however, may reveal anything from a conventional obstructive atherothrombotic lesion within or adjacent to the ectatic segment to a large thrombotic burden without critical epicardial stenosis [3,11,43,46].

In STEMI series involving CAE, the proportion of patients with TIMI 0–1 flow at the beginning of coronary angiography is high, ranging from 40% to 70% across different cohorts. This finding reflects the predominant role of thrombotic occlusion on an ectatic substrate [2,30].

Total ischemic time remains a critical prognostic determinant in this setting. Diagnostic delays resulting from misinterpretation of ectatic anatomy during coronary angiography may further worsen outcomes.

5.2. Non-ST-Segment Elevation Myocardial Infarction and Unstable Angina

CAE may also present as NSTEMI or unstable angina, generally through two mechanisms:

- Partially occlusive thrombosis within the ectatic segment with recurrent distal embolization, resulting in transient troponin elevation and dynamic ST-segment changes on the electrocardiogram [3,12].
- Vasospasm superimposed on chronic endothelial dysfunction within the ectatic segment, causing episodic and reversible reductions in coronary flow [4,10].

Unstable angina associated with CAE is particularly relevant from a therapeutic standpoint because patients are often treated initially with DAPT without anticoagulation, despite the possibility that a thrombotic mechanism may dominate the ischemic process.

Recurrent ACS caused exclusively by right coronary artery ectasia in the absence of obstructive lesions has been described, with resolution following systemic anticoagulation [40]. Long-term oral anticoagulation has also been associated with favorable clinical evolution in a similar case of recurrent ACS involving right coronary artery ectasia [12]. Although anecdotal, these reports highlight the need to consider anticoagulation in patients with a high thrombotic burden and recurrent ACS without significant stenosis.

5.3. Coronary Embolic Phenomena and MINOCA

MINOCA, or myocardial infarction with non-obstructive coronary arteries, may result from an unrecognized ectatic segment acting as a source of distal coronary emboli.

In such cases, coronary angiography may appear normal if the ectatic segment is not recognized, particularly in focal Type IV CAE, or if the thrombus has undergone spontaneous lysis before angiography [3,43].

Intracoronary imaging with IVUS or Optical Coherence Tomography (OCT) may reveal endothelial erosions, organizing mural thrombi, or vulnerable plaques that are not visible on conventional angiography. This improves mechanistic diagnosis and permits more targeted treatment [17,43].

CAE as a cause of MINOCA has direct therapeutic implications. Management should not focus only on microvascular dysfunction or vasospasm without evaluating a thromboembolic mechanism and the potential need for antithrombotic therapy to prevent recurrent embolization from the ectatic segment [12,47].

In MINOCA, OCT distinguishes atherosclerotic causes, including non-flow-limiting plaque rupture, plaque erosion, and eruptive calcified nodule, from non-atherosclerotic causes such as SCAD, coronary embolism, and epicardial spasm, and may therefore identify an ectatic segment as the embolic source [48].

5.4. Atypical Presentations and Diagnostic Challenges

During coronary angiography, CAE may mimic other entities. An ectatic segment filled with thrombus and characterized by slow flow may be mistaken for spontaneous coronary artery dissection, chronic total occlusion with aneurysmal morphology, or even coronary perforation with pseudoaneurysm [49].

Real-time intracoronary imaging is the most reliable tool for resolving this diagnostic ambiguity [8,17].

5.5. Attribution of the Culprit Mechanism: Atherothrombosis Versus Stasis-Driven Thrombosis

A fundamental clinical question is what proportion of ACS events in patients with CAE is truly attributable to the ectatic segment rather than to coexisting conventional atherosclerotic plaque disruption. Currently, this cannot be answered with precision because most angiographic series report the prevalence of CAE without adjudicating the specific mechanism of the index event. Coexisting obstructive atherosclerosis is frequent in adult CAE cohorts, and in long-term observational analyses, the presence of mixed ectatic and obstructive disease—rather than ectasia in isolation—is the primary driver of adverse clinical outcomes [20]. Conversely, intracoronary imaging reveals that thin-cap fibroatheromas occur with higher frequency within dilated segments than in adjacent non-dilated reference vessels [50], indicating that atherothrombotic rupture within an ectatic segment is a genuine and common mechanism. At the other extreme, documented cases of recurrent ACS occurring exclusively in ectatic vessels devoid of obstructive stenosis, which achieve sustained resolution with anticoagulation alone, demonstrate that purely stasis-driven, red-thrombus occlusion also occurs [12,41,51].

We propose a pragmatic diagnostic attribution framework during invasive angiography: (i) *Definite CAE-related thrombosis:* presence of intraluminal thrombus within an ectatic segment in the absence of obstructive epicardial stenosis (stenosis < 40%) and without another candidate culprit lesion; (ii) *Probable CAE-related thrombosis:* thrombus within or immediately adjacent to an ectatic segment harboring non-flow-limiting atherosclerotic plaque (<50%); (iii) *Possible CAE-related ACS:* an ectatic segment within the culprit vessel but coexisting with an intermediate stenosis (50–70%) of uncertain physiological significance; and (iv) *Unlikely CAE-related ACS:* an unequivocal flow-limiting stenosis (>70%) or documented plaque rupture outside the ectatic segment. Whenever therapeutic decisions regarding the balance between antiplatelet therapy and systemic anticoagulation hinge on this distinction, high-resolution intracoronary imaging (OCT or IVUS) should be used to establish the true culprit mechanism [17,48].

6. Diagnosis

6.1. Invasive Coronary Angiography: Anatomical Reference Standard

Invasive coronary angiography remains the definitive diagnostic test for CAE because it permits direct visualization of the coronary lumen in multiple projections, quantification of the ectatic segment relative to a reference segment, and real-time assessment of coronary flow using the TIMI grading system [2,12,52].

Angiographic findings suggestive of CAE include:

- Luminal dilatation of at least 1.5 times the diameter of the adjacent normal segment.
- Irregularities in the contour of the dilated segment, frequently with a lobulated appearance.
- Slow anterograde filling with a contrast-opacification gradient between the normal proximal segment and the ectatic segment.
- Intraluminal contrast stasis with backflow or segmental retention

- Intraluminal filling defects compatible with thrombus [2,11,22].

The principal limitation of coronary angiography is that it provides exclusively luminal information. It does not adequately characterize the vascular wall, thrombus composition, or microstructural abnormalities such as focal endothelial erosion.

This limitation is particularly relevant in CAE, in which the mechanism of ACS often involves the vessel wall—mural thrombus, vulnerable plaque, or erosion—rather than severe luminal stenosis [11,17].

6.2. Intracoronary Imaging: IVUS and OCT

Intracoronary imaging with IVUS and OCT provides complementary high-resolution diagnostic information and has substantially improved understanding of the mechanisms underlying ACS in ectatic vessels [8,17,48].

IVUS provides deep tissue penetration and visualization of the three arterial wall layers—the intima, media, and adventitia—with an axial resolution of approximately 100–200 μm. It enables assessment of wall thickness, atherosclerotic plaque, the extent of vascular remodeling, and thrombus characteristics, including whether the thrombus is soft, organized, or calcified [17].

OCT, with an axial resolution of approximately 10–20 μm, is superior for characterizing the luminal surface. It can identify focal endothelial erosions, fibrin films, and mural microthrombi, and it may define the causal mechanism of ACS more precisely than angiography or IVUS when superficial structures are involved [8,48].

In patients with CAE and ACS, intracoronary imaging is particularly valuable for:

- Excluding spontaneous coronary artery dissection and other entities that may mimic CAE.
- Guiding stent sizing when PCI is performed and preventing overestimation of the reference diameter caused by the dilated lumen.
- Identifying the culprit ectatic segment when it is not obvious on angiography.
- Assessing stent apposition after PCI and detecting early malapposition [8,17,48].

A prospective comparative OCT study of aneurysmal and adjacent non-dilated segments in 21 patients with angiographically confirmed CAE or CAA characterized the intravascular morphological differences associated with this phenotype [50]. Lesions were located in the left anterior descending artery in 42.9% of patients, the right coronary artery in 28.6%, and the circumflex artery in 9.5%. STEMI was the presenting condition in 57.1% of patients, chronic coronary syndrome in 38.1%, and unstable angina in 4.8% [50].

The predominant morphology was diffuse ectasia, present in 61.9% of patients, followed by fusiform aneurysm in 28.6% and saccular aneurysm in 9.5%. The median maximum luminal diameter was 5.3 mm, and the median lesion length was 10.0 mm [50].

Comparative OCT analysis reveals marked structural and compositional differences between aneurysmal and adjacent reference segments, supporting a vascular remodeling pattern distinct from conventional atherosclerosis. Aneurysmal segments exhibit a substantially smaller maximum calcification arc alongside a lower frequency of lipid-rich plaques and a complete absence of local neovascularization compared with non-dilated reference regions. Paradoxically, thin-cap fibroatheromas are observed more frequently within ectatic and aneurysmal segments than in adjacent reference vessels, despite comparable fibrous-cap thickness between regions. This morphological profile points toward a heterogeneous plaque architecture shaped by chronic remodeling rather than a typical vulnerable atheroma phenotype [50]. These findings support the concept of maladaptive remodeling in CAE and CAA.

OCT has superior axial resolution compared with IVUS. It therefore allows for more detailed characterization of plaque morphology, fibrous-cap architecture, and intraluminal thrombus. Its limitations include lower tissue penetration and the need for contrast

flushing [17,50]. A multimodality comparison of imaging modalities is presented in Table 3, and an integrated diagnostic workflow is shown in Figure 3.

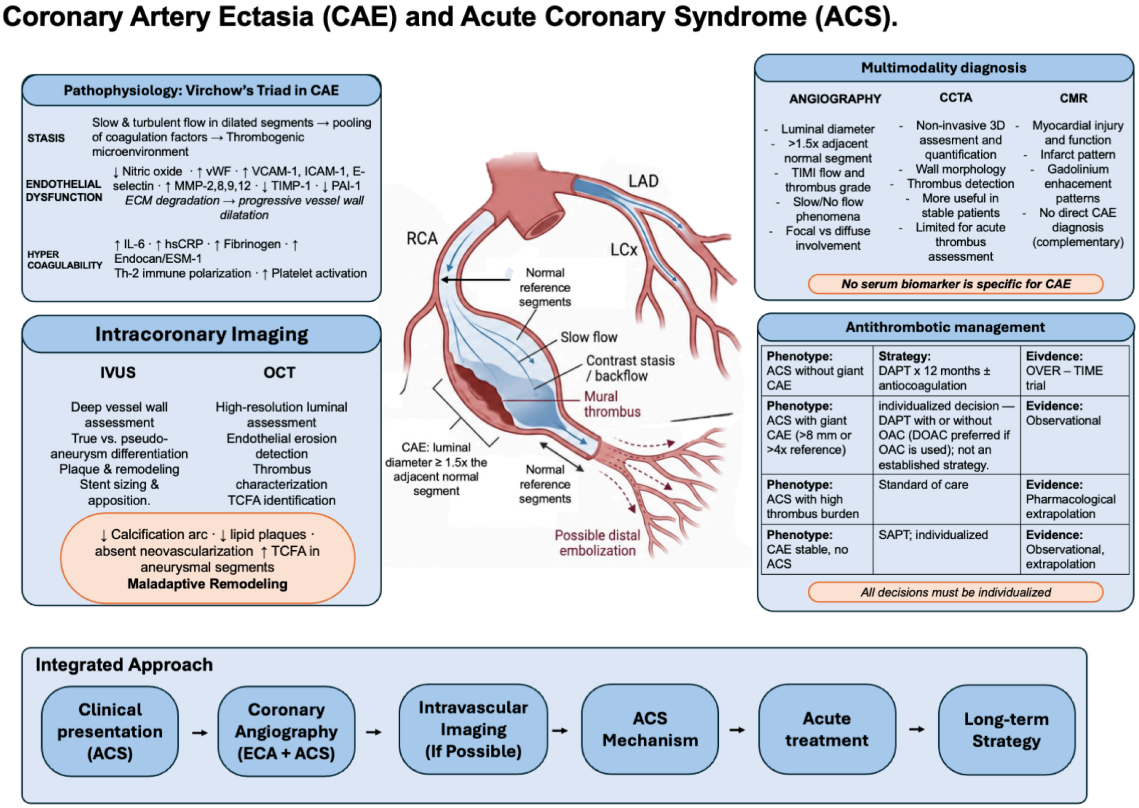

Figure 3. Multimodality diagnostic workflow for coronary artery ectasia (CAE) and related acute coronary syndrome (ACS). Integrated imaging assessment: (center) invasive coronary angiography shows luminal dilation with contrast stasis and mural thrombus (diameter ≥1.5× reference) with risk of distal embolization; (left) intracoronary imaging (IVUS/OCT) evaluates vessel-wall pathology, plaque/erosion, and thrombus burden; (right) CCTA provides noninvasive 3D wall and thrombus assessment (useful in stable patients) and CMR assesses myocardial injury/viability. Multimodal integration identifies the ACS mechanism (in situ thrombosis, embolization, spasm, or superimposed atherothrombosis) and guides acute and long-term antithrombotic strategy. No serum biomarker is specific for CAE. Abbreviations: ACS, acute coronary syndrome; CAE, coronary artery ectasia; CCTA, coronary computed tomography angiography; CMR, cardiac magnetic resonance; DOAC, direct oral anticoagulant; IVUS, intravascular ultrasound; OAC, oral anticoagulation; OCT, optical coherence tomography; SAPT, single antiplatelet therapy; TCFA, thin-cap fibroatheroma; VKA, vitamin K antagonist; vWF, von Willebrand factor; VCAM-1, vascular cell adhesion molecule 1; ICAM-1, intercellular adhesion molecule 1; MMP-2, MMP-8, MMP-9, and MMP-12, matrix metalloproteinases 2, 8, 9, and 12; TIMP-1, tissue inhibitor of metalloproteinases 1; PAI-1, plasminogen activator inhibitor 1; ECM, extracellular matrix; hsCRP, high-sensitivity C-reactive protein; ESM-1, endothelial cell-specific molecule 1 (endocan); Th2, T helper 2 cells; IL-6, interleukin 6. Arrows indicate an increase (↑) or decrease (↓).

Beyond the characterization of the ectatic segment itself, OCT has become the reference intravascular modality for identifying the mechanism of intracoronary thrombosis in ACS, distinguishing plaque rupture, plaque erosion, and eruptive calcified nodule, which carry different prognostic and therapeutic implications. In the specific context of CAE this distinction is clinically relevant, because a ruptured plaque within or adjacent to an ectatic segment identifies a patient in whom the dominant mechanism is atherothrombotic rather than stasis-driven, and in whom the balance between antiplatelet therapy and anticoagulation may differ [48]. OCT also allows for the identification of thin-cap fibroatheroma,

macrophage accumulation, microchannels, and healed plaque, and therefore contributes to the assessment of non-acute ischemic syndromes and of ischemia with non-obstructive coronary arteries, including epicardial spasm and myocardial bridge [48].

Table 3. Multimodality Comparison of Imaging Modalities in CAE Associated With ACS.

Assessment Parameter	Angiography	IVUS	OCT	CCTA
Luminal anatomy and flow	High	Useful	Useful	High
Relationship to culprit vessel	High	Useful	High	Limited
True dimensions and external elastic membrane	Useful	High	Useful	High
Plaque mechanism	Limited	Useful	High	Useful
Thrombus characterization	Useful	Limited	High	Useful
PCI planning and optimization	Useful	High	High	Not primary
Markedly ectatic vessels	Useful	High	Limited	High
Non-invasive anatomical follow-up	Not primary	Not primary	Not primary	High
Best clinical use	Initial ACS assessment	Sizing and optimization	Plaque and thrombus mechanism	Three-dimensional anatomy and follow-up

IVUS, intravascular ultrasound; OCT, optical coherence tomography; CCTA, coronary computed tomography angiography; PCI, percutaneous coronary intervention; ACS, acute coronary syndrome; EEM, external elastic membrane.

6.3. Coronary Computed Tomography Angiography and Non-Invasive Techniques

Coronary computed tomography angiography (CCTA) has been shown to play an increasing role in the evaluation of stable CAE. It permits quantification of luminal diameter throughout the affected vessel, assessment of the vascular wall, detection of coronary calcium, and identification of associated anatomical abnormalities without invasive catheterization [4,53].

Its usefulness in the acute setting is more limited because a stable heart rate is often required, motion artifacts may compromise image quality, and the detection of fresh thrombus may be challenging during emergency evaluation.

Nevertheless, in patients with known CAE who present with atypical symptoms or undergo scheduled follow-up, CCTA may provide complementary information regarding the anatomical evolution of the ectatic segment, plaque progression, and the early detection of organized intraluminal thrombus [53]. CCTA has also been used to diagnose and follow patients with STEMI, CAE, and unusual coronary aneurysms, highlighting its value in the characterization of complex morphology [53].

For incidentally detected, asymptomatic coronary aneurysms, management should be individualized, with cardiovascular risk-factor control, statins when atherosclerosis is present, and aspirin considered according to thrombotic and bleeding risk rather than prescribed universally [24,48]. Clinical follow-up may be complemented by CCTA to assess aneurysm size and mural thrombus, particularly in large or anatomically complex lesions, although surveillance intervals are not standardized [24,54]. Following uncomplicated ACS, ectasia alone does not establish an indication for routine repeat angiography; CCTA may be selected when anatomical reassessment could alter management, whereas invasive angiography is reserved for recurrent ischemia or planned intervention [24,54].

6.4. Biomarkers and Integrated Diagnostic Criteria

No serum biomarker is specific for the diagnosis of CAE. High-sensitivity troponin, creatine kinase-MB, and Brain Natriuretic Peptide (BNP) or N-terminal (NT)-proBNP reflect myocardial injury and ventricular dysfunction resulting from ACS occurring on an ectatic substrate, in a manner similar to conventional ACS [2,6].

Inflammatory markers, including high-sensitivity C-reactive protein, fibrinogen, and interleukin-6, may be elevated at baseline in patients with chronic CAE. However, acute elevation during ACS is not diagnostic of CAE and does not distinguish thrombosis over ectasia from thrombosis over a ruptured atherosclerotic plaque [10,34].

The diagnosis of CAE is therefore fundamentally angiographic and requires integration of imaging findings with the clinical presentation, electrocardiographic findings, and biomarkers of myocardial injury.

7. Therapeutic Management

7.1. General Principles and Acute-Phase Treatment

Initial management of ACS in patients with CAE follows standard guideline-directed care according to the clinical presentation, including antithrombotic therapy and the appropriate timing of invasive evaluation or reperfusion [6,7]. Coronary angiography establishes the diagnosis of CAE and characterizes the culprit lesion, thrombus burden, and coronary flow. From this stage onward, treatment is individualized according to the angiographic findings, with CAE-specific interventional and antithrombotic considerations discussed below [3,8].

7.2. Long-Term Medical Treatment: Antiplatelet Therapy, Anticoagulation, and Statins

Long-term antithrombotic therapy in patients with ACS and CAE lacks a Level I evidence-based standard. Current ACS practice guidelines do not provide specific recommendations for the CAE phenotype. Treatment decisions must therefore be individualized according to the available moderate- or low-level evidence and the patient's anatomical and clinical characteristics [3,6,55].

Standard DAPT consisting of aspirin plus a P2Y12 inhibitor for 12 months remains the baseline strategy recommended for patients with ACS treated with PCI, including those with CAE, by analogy with the general ACS population [6].

However, the pathophysiological rationale suggests that the low-velocity thrombotic component associated with stasis differs from thrombus overlying a ruptured plaque and may require an anticoagulant for effective prevention. Indeed, in the context of CAE, the thrombotic risk is not primarily explained by classic plaque vulnerability—thin fibrous cap, large lipid core, or neovascularization—but rather by hemodynamic factors, including disturbed flow, intraluminal stasis, and turbulence within dilated segments. These factors promote platelet activation and in situ thrombosis. This pathophysiological distinction has direct therapeutic implications. Antithrombotic agents directed at the stasis- and fibrin-related component, particularly anticoagulants, may therefore complement antiplatelet therapy in selected patients with high-risk CAE or CAA.

Low-molecular-weight heparins, vitamin K antagonists such as warfarin, and direct oral anticoagulants, including rivaroxaban, apixaban, and dabigatran, have been used in case series and observational studies, with variable results [9,12,56].

In high-risk ACS, including ACS with CAE and a large thrombotic burden, newer-generation P2Y12 inhibitors such as prasugrel and ticagrelor are generally preferred over clopidogrel because of their faster onset and greater antiplatelet potency [6,57].

High-intensity statins are an important component of chronic treatment because of the central role of atherosclerosis in the etiology of CAE in adults and because of their pleiotropic anti-inflammatory and plaque-stabilizing effects [6,9].

Angiotensin-system blockers and beta-blockers should be prescribed according to standard comorbidities, including ventricular dysfunction, hypertension, and atrial fibrillation. There are no specific data supporting their use solely because of CAE. Long-acting nitrates and calcium-channel blockers may be considered in patients with CAE and a documented clinical vasospastic component [4,7].

7.3. The OVER-TIME Trial: Evidence from the Only Available Randomized Clinical Trial

The OVER-TIME trial—Oral anticoagulants Versus antiplatElet thERapy in patienTs with coronary artEry ectasia and acute coronary syndrome—represents the most important investigational milestone in the field of antithrombotic treatment for CAE associated with ACS [13].

This was an open-label, exploratory randomized clinical trial that assigned 62 patients with ACS and a culprit coronary ectatic lesion to one of two strategies. Group A received standard DAPT with aspirin 100 mg/day and clopidogrel 75 mg/day for 12 months. Group B received anticoagulation plus single antiplatelet therapy with clopidogrel 75 mg/day and rivaroxaban 15 mg/day for 12 months.

The primary composite endpoints were the composite of cardiovascular death, recurrent MI and repeat revascularization and total bleeding events (BARC 1–5) at 12 months.

No statistically significant difference was observed between the two treatment groups for the primary composite endpoints. There was also no statistically significant difference in major bleeding according to TIMI or Bleeding Academic Research Consortium (BARC) ≥2 criteria [13].

However, analysis of individual components showed a numerical signal toward fewer recurrent myocardial infarctions in the rivaroxaban group. Parallel mechanistic studies demonstrated greater clot lysis and lower residual thrombin activity in the direct oral anticoagulant group [13].

Because of its small sample size and exploratory nature, the trial cannot establish definitive treatment recommendations. Nevertheless, it supports the need for larger studies.

OVER-TIME Trial in Perspective. With only 62 randomized patients, the OVER-TIME trial was underpowered to detect clinically meaningful differences in infrequent outcomes. Its favorable biological signals, including a numerical reduction in recurrent myocardial infarction and greater thrombus lysis, should therefore be regarded as hypothesis-generating rather than proof of clinical benefit. Extrapolation of these results to routine clinical practice requires caution.

7.4. Evidence Regarding Anticoagulation in Coronary Artery Ectasia

An early meta-analysis including three studies and 441 patients with CAE and ACS found no statistically significant reduction in MACE, recurrent myocardial infarction, or cardiovascular mortality with anticoagulation compared with DAPT [14].

A systematic review of 18 case reports suggested that anticoagulation, particularly when combined with antiplatelet therapy, may promote thrombus resolution and reduce recurrent ischemic events in selected patients with a high thrombotic burden or CAE without significant obstructive stenosis. However, the limited sample size, absence of a control group, and observational nature of the available evidence preclude definitive conclusions regarding efficacy or safety [47].

More recently, a systematic review and network meta-analysis of 5039 adults with CAE evaluated the comparative effectiveness of DAPT, aspirin monotherapy, anticoagulation,

and no antithrombotic treatment. DAPT was associated with the greatest reduction in MACE compared with no treatment (OR, 0.26; 95% CI, 0.11–0.62) and achieved the highest probability of being the most effective strategy according to the surface under the cumulative ranking curve (SUCRA, 0.91). Aspirin monotherapy was also associated with a lower risk of MACE (OR, 0.40; 95% CI, 0.17–0.96; SUCRA, 0.68). Although anticoagulation ranked higher than no treatment, the reduction in MACE was not statistically significant (OR, 0.63; 95% CI, 0.32–1.22; SUCRA, 0.37). These findings provide stronger support for antiplatelet therapy, particularly DAPT, than for routine anticoagulation in patients with CAE. Nevertheless, the analysis was based predominantly on observational studies, included no randomized controlled trials, and could not reliably evaluate bleeding or other safety outcomes [58]. Consistent with these findings, a single-center retrospective cohort of 354 patients with ACS and CAE, of whom 228 received DAPT and 126 received anticoagulation with or without an antiplatelet agent, found no reduction in MACE over 4.5 years: MACE occurred in 13.1% of patients receiving anticoagulation and 14.5% of those receiving DAPT (HR 0.95, 95% CI 0.47–1.54; $p = 0.59$) [15]. This finding does not support routine anticoagulation for all patients with ACS and CAE, although it does not exclude a benefit in selected anatomical or thrombotic phenotypes, and confounding by indication remains possible.

Observational data specifically addressing high-grade ectasia are limited but consistent in direction. In a long-term follow-up study stratified by angiographic severity, high-grade CAE was associated with a greater burden of adverse cardiovascular events, and antithrombotic or anticoagulant therapy appeared to be associated with better outcomes in this subgroup, whereas no such gradient was observed in low-grade ectasia [37]. Two further observational analyses focused on the role of anticoagulation, including non-vitamin K antagonist oral anticoagulants, in patients with ACS and CAE [9,56]. These observations are hypothesis-generating rather than directive: treatment was not randomized, the decision to anticoagulate was left to the operator, and the subgroups were small. They nonetheless support phenotype-directed rather than universal anticoagulation, and they justify the prespecified stratification by Markis type proposed for future trials.

Patients with giant CAA (>8 mm), may represent a subgroup with an exceptionally high risk of thrombosis. Long-term anticoagulation has therefore been proposed in selected patients with giant aneurysms, although the supporting evidence remains limited and is derived mainly from observational studies, case reports, and expert opinion.

When anticoagulation is clinically indicated, direct oral anticoagulants are generally preferred over vitamin K antagonists in contemporary practice. Triple antithrombotic therapy consisting of DAPT plus oral anticoagulation should be reserved for highly selected patients, such as those with CAE-associated ACS and concomitant atrial fibrillation or documented intraluminal coronary thrombosis. Because of the substantial risk of bleeding, the duration of triple therapy should be minimized [18,24].

Overall, current evidence does not support the routine use of anticoagulation instead of standard DAPT in all patients with CAE and ACS. Available data do not demonstrate that anticoagulation is superior to antiplatelet therapy for the prevention of MACE. However, a potential role for anticoagulation cannot be excluded in selected high-risk phenotypes, including diffuse multivessel CAE corresponding to Markis Types I–II, substantial angiographic thrombotic burden, CAE without an obstructive culprit lesion, giant coronary aneurysms, documented intracoronary thrombosis, or recurrent ACS despite antiplatelet therapy.

Until higher-level evidence becomes available, antithrombotic treatment should be individualized according to the anatomical extent of ectasia, the presumed mechanism of ACS, the presence of intracoronary thrombus, concomitant indications for anticoagulation, and the patient's bleeding risk. A practical therapeutic framework is summarized in

Table 4 [3,14,15,58]. The therapeutic framework for CAE associated with ACS is summarized in Table 4.

Table 4. Therapeutic Framework for Coronary Artery Ectasia Associated With Acute Coronary Syndrome.

Clinical Scenario	Baseline Management	Additional Consideration	Specific Evidence in CAE
ACS with a clear atherosclerotic culprit lesion	Standard ACS management with or without PCI; DAPT according to ischemic and bleeding risk	CAE increases technical complexity but does not alter the basic indication for reperfusion	Limited
ACS with a large thrombotic burden, slow flow, or no-reflow	Selective or bailout use of glycoprotein IIb/IIIa inhibitors or thrombectomy; not routine	Parenteral anticoagulation during the invasive strategy	Indirect
Culprit CAE without clear fixed stenosis	Restore flow and define the mechanism before implanting a stent	Initial conservative pharmacological management and anatomical reassessment may be considered in stable cases	Observational
Secondary prevention after ACS	DAPT as the initial standard strategy; duration individualized	Routine oral anticoagulation has not demonstrated superiority over DAPT	Small randomized trial plus observational studies
Recurrent ACS with probable CAE-related thrombosis	Reassess the mechanism, treatment adherence, culprit lesion, and bleeding risk	Anticoagulation may be considered individually; no validated recommendation exists	Very low
Independent indication for anticoagulation, such as atrial fibrillation	Follow contemporary guidelines for ACS associated with anticoagulation	Minimize triple therapy; subsequently use oral anticoagulation plus antiplatelet therapy according to risk	Extrapolated

Practical message: ACS should first be treated according to established evidence. The clinician should then determine whether CAE is the culprit and identify the dominant mechanism. Additional treatment strategies should be individualized only after this assessment. Routine anticoagulation for isolated CAE is not supported by current evidence. CAE, coronary artery ectasia; ACS, acute coronary syndrome; PCI, percutaneous coronary intervention; DAPT, dual antiplatelet therapy; AF, atrial fibrillation; OAC, oral anticoagulation; GPIIb/IIIa, glycoprotein IIb/IIIa inhibitors.

7.5. Percutaneous Coronary Intervention: Technical Challenges and Device Selection

PCI in ectatic vessels represents one of the greatest technical challenges in contemporary coronary intervention. Specific problems include:

- Overestimation of the reference diameter because of the dilated lumen, potentially leading to inappropriate stent selection.
- A high thrombotic burden with a risk of massive distal embolization during wire crossing and balloon deployment.
- A higher frequency of post-PCI no-reflow than in normal-caliber vessels.
- Acute stent malapposition within the ectatic segment adjacent to the treated lesion.
- Difficulty predicting distal anatomy when thrombus limits visualization [8,59].

In a cohort analysis, PCI was not associated with a significant reduction in long-term MACE compared with conservative management in patients with CAE and ACS. In-hospital mortality was similar between the groups [59].

In patients with CAE and a high thrombotic burden without a clear obstructive culprit lesion, conservative management with systemic anticoagulation may be a reasonable alternative to PCI, particularly when the ectatic segment is the only visible substrate and no stenosis greater than 50% is present [3,15].

Successful thrombus resolution using triple antithrombotic therapy combined with selective intracoronary thrombolysis has been reported in a patient with CAE and a high thrombotic burden that was not amenable to conventional thrombectomy [51].

The relationship of the ectatic segment to the stenosis should be explicitly assessed when planning PCI. Proximal ectasia may complicate proximal landing-zone selection and stent apposition, whereas distal ectasia may compromise distal reference sizing, particularly when thrombus obscures the vessel lumen. Thrombus within either segment can contribute to distal embolization and no-reflow; these risks are therefore not exclusive to post-stenotic ectasia [50]. Rather than prioritizing one location, procedural planning should assess both reference segments, thrombus burden, and coronary flow, with IVUS guidance to optimize stent sizing and landing-zone selection [55].

7.6. Coronary Artery Bypass Grafting

Coronary artery bypass grafting has a limited and highly specific role in CAE associated with ACS. It may be reserved for cases in which coronary anatomy makes PCI unsafe or impossible, such as extensive CAE involving the proximal and mid portions of the left anterior descending artery with tandem obstructive lesions; surgical exclusion of large coronary aneurysms at risk of rupture; or rescue surgery after failed initial PCI [3,7]. Exclusion does not appear to offer any advantage over isolated revascularization, supporting the current trends in managing this rare condition [60].

Outcomes of coronary artery bypass grafting in CAE are heterogeneous in the literature, and high-quality disease-specific evidence is limited. No comparative trials are available to guide the choice between surgery and PCI in this setting [3,4]. In a recent series of 146 patients undergoing surgery for coronary artery aneurysms, bypass grafting was used in 81% of cases, either alone or combined with aneurysm ligation, excision, or reconstructive techniques. Operative mortality was 2.8%, while five- and ten-year survival rates were 72% and 56%, respectively, with long-term survival comparable to that of patients undergoing CABG for ischemic coronary disease [61]. Although these findings primarily concern coronary aneurysms rather than diffuse CAE, they support the feasibility of individualized surgical management in symptomatic patients treated at experienced centers.

8. Prognosis and Major Adverse Cardiovascular Events

8.1. Mortality and MACE

The prognostic impact of CAE in ACS is heterogeneous and depends on the population studied, the anatomical extent of ectasia, the presence of concomitant obstructive disease, and the definition of MACE.

In a cohort of 4788 patients with myocardial infarction, CAE was associated with a higher incidence of MACE at a median follow-up of 3.5 years, with rates of 36.8% versus 25.6% and an adjusted hazard ratio of 1.60 (95% CI 1.28–1.99; $p < 0.001$) [29].

Similarly, a meta-analysis involving 13,908 patients with myocardial infarction demonstrated a higher risk of MACE and recurrent myocardial infarction in the presence of CAE, without a statistically significant increase in all-cause or cardiovascular mortality [62].

In a comparative cohort of 280 patients with ACS and CAE and 280 control patients without CAE, mortality during follow-up was higher in the CAE group, at 8.2% versus 2.8%, with $p = 0.005$. Individual non-fatal events were infrequent and did not differ significantly between the groups [2].

By contrast, in a STEMI cohort, no significant difference was identified in the 30-day composite endpoint between patients with and without CAE. Interpretation of this finding is limited by incomplete methodological information in the abstract in which the data were reported [30]. Table 5 summarizes key prognostic and therapeutic studies of coronary artery ectasia in patients with ACS or acute myocardial infarction.

Table 5. Relevant Prognostic and Therapeutic Studies in Coronary Artery Ectasia and ACS or Acute Myocardial Infarction.

Study	Design and Population	Follow-Up	Main Reported Outcomes	Principal Finding
Wang et al., 2021 [29]	Retrospective comparative cohort of 4788 patients with myocardial infarction undergoing coronary angiography; CAE identified in 3.6%	Median 3.5 years	MACE: 36.8% with CAE versus 25.6% without CAE; adjusted HR 1.597, 95% CI 1.28–1.99; $p < 0.001$	CAE was independently associated with a higher long-term risk of MACE after myocardial infarction
Dattoli-García et al., 2021 [30]	Observational cohort comparing patients with and without CAE among patients with STEMI	30 days	MACE: 8.93% with CAE versus 10.3% without CAE; no significant difference and no significant difference in bleeding	No short-term adverse prognostic signal was demonstrated, although interpretation is limited by incomplete methodological information
Magdi et al., 2023 [63]	Systematic review and meta-analysis of observational studies in patients with myocardial infarction and pre-existing CAE	Variable; long-term	Mortality and MACE were evaluated; results varied across the included studies	Results were heterogeneous and did not establish a consistent association between CAE and mortality or MACE
Ghanem et al., 2023 [32]	Prospective cohort of 272 patients with CAE	Duration not uniformly reported	ACS occurred in 41.2% of the cohort; ectatic length ≥39 mm or diameter ≥6 mm was associated with ACS presentation	Anatomical extent of CAE was associated with ACS presentation; thresholds remain exploratory and require external validation
Abdelaaty et al., 2025 [2]	Retrospective-prospective comparative cohort of 280 patients with ACS and CAE and 280 controls without CAE	Approximately one year for the overall cohort; follow-up up to two years in approximately 50%	Mortality: 8.2% with CAE versus 2.8% without CAE; $p = 0.005$. During follow-up: myocardial infarction 2.5% versus 1.0%; stroke 0.4% versus 0%; target-vessel revascularization 2.1% versus 1.0%	CAE was associated with higher mortality during follow-up; individual non-fatal events were infrequent and did not differ significantly
Ruiz-Beltran et al., 2025 [19]	Single-center retrospective cohort of patients with CAE after ACS, stratified according to Markis classification	Variable; not verifiable from the cited abstract	Recurrent myocardial infarction and MACE according to Markis classification	Suggested a prognostic gradient according to anatomical extent, with greater risk among diffuse Markis I–II phenotypes; hypothesis-generating evidence requiring validation
Solis-Jiménez et al., 2025 [15]	Single-center retrospective comparative cohort of 354 patients with ACS and CAE: 228 treated with DAPT and 126 with anticoagulation with or without antiplatelet therapy	4.5 years	Composite MACE of death from any cause, recurrent myocardial infarction, or ischemic stroke: 14.5% with DAPT versus 13.1% with anticoagulation; HR 0.95, 95% CI 0.47–1.54; $p = 0.59$	Anticoagulation was not associated with a significant reduction in MACE compared with DAPT; observational confounding by indication remains possible
Otountzidis et al., 2026 [62]	Systematic review and meta-analysis of observational studies comparing angiographic CAE with absence of CAE among patients with myocardial infarction; 10 studies and 13,908 patients	Variable according to study	MACE: OR 2.12, 95% CI 1.34–3.36. Recurrent myocardial infarction: OR 2.76, 95% CI 1.62–4.71. No significant difference in mortality or repeat revascularization	CAE was associated with greater risk of MACE and recurrent myocardial infarction, without conclusive evidence of increased mortality; heterogeneity limits causal inference
Pastrana et al., 2024 [14]	Systematic review and meta-analysis of 3 observational studies including 441 patients with CAE and ACS; anticoagulation was compared with antiplatelet therapy	Not uniformly reported	No statistically significant reduction in MACE, recurrent myocardial infarction, or cardiovascular mortality with anticoagulation compared with DAPT	Anticoagulation did not demonstrate a significant clinical benefit over antiplatelet therapy; the evidence was limited by the small number of studies and observational design
Azarboo et al., 2025 [58]	Systematic review and network meta-analysis of 8 observational studies including 5039 adults with CAE; 6 studies contributed to the quantitative analysis	11.6–116.4 months	Compared with no treatment, DAPT reduced MACE (OR 0.26, 95% CI 0.11–0.62), as did aspirin monotherapy (OR 0.40, 95% CI 0.17–0.96); anticoagulation showed a non-significant reduction (OR 0.63, 95% CI 0.32–1.22)	DAPT ranked as the most effective strategy for preventing MACE, followed by aspirin and anticoagulation; routine anticoagulation was not supported

CAE, coronary artery ectasia; ACS, acute coronary syndrome; CI, confidence interval; DAPT: dual antiplatelet therapy; HR, hazard ratio; MACE, major adverse cardiovascular events; OR, odds ratio; STEMI, ST-segment elevation myocardial infarction.

8.2. Prognostic Factors and Risk Stratification

The heterogeneity of prognostic findings in the literature reflects the existence of patient subgroups with substantially different levels of risk. Factors that appear to predict poorer outcomes in patients with CAE and ACS include:

- Diffuse anatomical extension of CAE, corresponding to Markis Types I–II.
- Multivessel involvement.
- Ectatic segments with greater length, at least 39 mm, or greater diameter, at least 6 mm.
- A high thrombotic burden on initial coronary angiography.
- CAE as the only identifiable substrate in the absence of significant obstructive stenosis.
- Left ventricular dysfunction after ACS.
- Recurrent ACS involving the same ectatic segment [19,20,32].

The Markis classification is currently the most extensively studied anatomical stratification tool. A single-center retrospective cohort documented a significant prognostic gradient according to Markis type, with a greater incidence of recurrent myocardial infarction and long-term MACE among diffuse phenotypes, particularly Types I–II [19].

In a retrospective cohort of 161 patients with CAE, isolated CAE was associated with more extensive involvement, including three or more ectatic vessels in 42.5% of patients and diffuse ectasia in 92.5% [20]. Despite this more extensive anatomical phenotype, the patient-oriented composite endpoint was less frequent in isolated CAE than in mixed CAE and atherosclerotic heart disease (25.0% vs 48.8%), largely because of fewer ACS events during follow-up [20]. These findings suggest that concomitant atherosclerotic disease, rather than the extent of ectasia alone, may be a more important determinant of clinical outcomes.

8.3. Recurrence and Long-Term Events

Recurrent ischemic events arising from the ectatic substrate are a defining feature of the long-term CAE phenotype. In contrast to ACS caused by rupture of an atherosclerotic plaque, in which the culprit artery is treated with PCI and the risk of recurrence at that segment decreases substantially, the pathophysiological substrate in CAE—including slow flow, endothelial dysfunction, and prothrombotic activation—persists indefinitely if the underlying mechanism is not addressed [12]. Observational cohorts and meta-analyses have associated CAE in patients with myocardial infarction with a higher risk of MACE and recurrent myocardial infarction, although the magnitude of the association varies across studies [28,62,64]. Consistent with these findings, a retrospective study of 404 patients with first myocardial infarction due to isolated CAE reported a higher incidence of death or recurrent MI in patients with CAE than in those without CAE (26.7% vs. 16.3%), as well as higher rates of recurrent MI (22.8% vs. 13.4%) and stent thrombosis (8.9% vs. 1.5%) [64]. CAE remained independently associated with death or recurrent MI (HR, 1.84; 95% CI, 1.11–3.05) and recurrent MI alone (HR, 2.07; 95% CI, 1.08–3.96), including recurrence from the index infarct-related artery [64].

Late stent thrombosis within an ectatic segment is a specific and serious complication. It is promoted by chronic stent malapposition within the dilated lumen, persistent residual slow flow, and ongoing platelet activation driven by underlying endothelial inflammation. Prevention requires close follow-up, strict adherence to antithrombotic treatment, and intracoronary imaging when clinically significant malapposition is suspected [8,17].

9. Knowledge Gaps and Future Directions

9.1. Lack of Level I Evidence for Antithrombotic Treatment

The most critical and urgent research gap in CAE associated with ACS is the absence of adequately powered randomized clinical trials comparing antithrombotic strategies.

The only available randomized trial, OVER-TIME, enrolled 62 patients, used an exploratory design, followed patients for 12 months, and lacked sufficient statistical power to detect differences in clinically meaningful outcomes [13]. Consequently, daily clinical decisions are based on extrapolation from conventional ACS guidelines, low- to moderate-level observational evidence, and clinical judgment.

There is a need for prospective and multicenter randomized trials with an adequately powered, event-driven multicenter trial patients with CAE and ACS. Such studies should compare DAPT with a combination of antiplatelet therapy and a direct oral anticoagulant, with prespecified stratification according to Markis classification and ACS mechanism, including in situ thrombosis versus distal embolization [3,15].

9.2. Stratification According to Markis Classification and Anatomical Phenotype

Although the Markis classification was proposed nearly five decades ago, it has not been prospectively validated as a risk-stratification tool or as a criterion for therapeutic selection in any clinical trial.

Available retrospective data suggest that diffuse phenotypes, particularly Types I–II, carry greater risk. However, these findings arise from single-center retrospective cohorts and are subject to the limitations inherent in that design [19,20].

The research priority should be prospective validation of Markis classification as a stratification variable in clinical trials and multicenter registries. This should include the definition of quantitative thresholds for length and diameter that could facilitate automated and reproducible decision-making [20,33]. The proposed thresholds of an ectatic length of at least 39 mm or a diameter of at least 6 mm as predictors of ACS represent a valuable starting point but require external validation [32].

9.3. Multicenter Registries and Collaborative Databases

CAE is sufficiently uncommon that no single center can independently recruit adequately sized cohorts. Prospective multicenter registries are therefore essential to characterize the natural history of the disease, identify event predictors, evaluate variations in clinical practice, and provide the methodological foundation for future clinical trials [3,30]. Recent collaborative initiatives include the international multicenter Coronary Artery Aneurysm Registry (CAAR), established to facilitate standardized data collection and collaborative outcome research in this heterogeneous population and the retrospective Coronary Artery Ectasia and Aneurysm Registry (CAESAR), which provides real-world data on the clinical characteristics and outcomes of patients with coronary artery aneurysms [28,65].

9.4. Systematic Intracoronary Imaging and PCI Guidance in CAE

The usefulness of intracoronary imaging with IVUS or OCT in CAE associated with ACS has been documented in case series and clinical reports, but it has not been evaluated in randomized clinical trials specifically involving this phenotype [17,44].

Available observational data support the notion that systematic IVUS or OCT use during PCI in ectatic vessels improves stent sizing, reduces malapposition, and may help guide the decision between PCI and conservative management. A clinical trial randomizing patients with CAE and ACS to intracoronary imaging-guided PCI versus angiography-guided PCI alone would provide evidence directly applicable to clinical practice [8,17].

The same technology has already been proposed as a tool to reclassify ischemic syndromes beyond the stenosis-centred model, and its systematic application in CAE would place this phenotype within that framework rather than outside it [48].

9.5. Biomarkers of Specific Thrombotic Risk

Identifying serum biomarkers that reflect the thrombogenic activity of the ectatic segment, beyond generic markers of inflammation or coagulation, could allow for earlier identification of patients at risk of ACS caused by CAE and potentially guide the intensity of prophylactic antithrombotic therapy. Potential biological candidates include:

- D-dimer as a marker of ongoing thrombosis.
- MMP fragments as indicators of active proteolytic activity.
- Thrombin–antithrombin complexes.
- Platelet-derived microparticles.
- Endothelial-derived microparticles associated with endothelial dysfunction.

Evaluation of these biomarkers in prospective longitudinal cohorts of patients with known CAE represents a priority for translational research [3,9,10].

9.6. CAE in Diverse Patient Populations: Women, Young Patients, and CAE Without Atherosclerosis

The literature on CAE and ACS is dominated by middle-aged men with traditional cardiovascular risk factors. Women were under-represented in a two-center angiographic cohort, accounting for 19.6% of patients with isolated CAE [26]. This is particularly relevant when considering conditions such as spontaneous coronary artery dissection (SCAD), in which 74–100% of patients in contemporary angiographic series are women [26], and Takayasu arteritis, in which 97% of patients in the largest North American cohort were women [66]. These female-predominant conditions may contribute to coronary involvement in younger patients and highlight the importance of considering non-atherosclerotic mechanisms when evaluating CAE.

Similarly, young patients under 45 years of age with non-atherosclerotic CAE caused by congenital disease, inflammation, or connective tissue disorders represent a subgroup with specific therapeutic needs that have not been addressed in prospective studies [3,10].

10. Limitations

This review has several limitations that should be considered when interpreting its conclusions. First, it is a narrative synthesis without a registered protocol, formal risk-of-bias assessment, or quantitative pooling; study selection was purposive and therefore susceptible to selection and interpretation bias. Second, the field is dominated by retrospective, single-center observational cohorts with heterogeneous definitions of ectasia, inconsistent use of quantitative criteria, variable follow-up, and substantial confounding by indication, particularly for anticoagulation, which is preferentially prescribed to patients with a greater thrombotic burden. Third, several key analyses are available only as conference abstracts, which limits verification of methods and effect estimates. Fourth, randomized evidence is restricted to a single exploratory trial of 62 patients. Fifth, the literature is largely English-language and derived from high-income settings, and women and young patients with non-atherosclerotic disease are under-represented, limiting generalizability. Finally, no meta-analysis was performed, so the summary estimates reported here are those of the original publications and were not independently recalculated.

11. Conclusions

Coronary artery ectasia in the setting of acute coronary syndrome is an uncommon clinical entity with pathophysiology more complex than atherosclerosis alone and without a standardized optimal treatment strategy.

Available evidence consistently indicates that CAE constitutes an active thrombogenic substrate through slow flow, stasis, endothelial dysfunction, and distal embolization. These mechanisms can produce myocardial ischemia and infarction even in the absence of significant obstructive stenosis.

The Markis classification provides an anatomical framework with emerging prognostic value. Diffuse phenotypes, particularly Types I–II, appear to carry a greater thrombotic risk, a higher frequency of ACS, and possibly a poorer long-term prognosis. These associations, however, require confirmation through prospective evaluation.

From a therapeutic perspective, the only available randomized clinical trial, OVERTIME, did not demonstrate statistically significant superiority of clopidogrel plus rivaroxaban over standard DAPT, although its favorable biological signals justify larger clinical trials. Meta-analyses and retrospective cohorts have likewise failed to demonstrate a significant reduction in MACE with routine anticoagulation.

PCI in ectatic vessels presents specific technical challenges, including no-reflow, distal thrombus embolization, and stent malapposition. These challenges support the consideration of intracoronary imaging and appropriately adapted procedural protocols.

The principal lesson of this review is that CAE associated with ACS is not a benign anatomical variant. It is clinically relevant because of its association with recurrent ischemic events, greater interventional complexity, and antithrombotic decisions that remain unsupported by Level I evidence. Management requires the clinical and interventional cardiologist to have a thorough understanding of the underlying pathophysiology, perform detailed anatomical assessment, and develop an individualized therapeutic strategy until prospective and randomized provide definitive answers.

Author Contributions: Conceptualization and methodology, F.Q.-C. and T.C.; writing—original draft preparation, F.Q.-C., S.L., A.R., E.S., E.L. and T.C.; writing—review and editing, A.R.,S.L., E.S., E.L., O.F.B., C.N.-R.; supervision, T.C. and O.F.B. All authors have read and agreed to the published version of the manuscript.

Funding: This research received no external funding.

Institutional Review Board Statement: Not applicable.

Informed Consent Statement: Not applicable.

Data Availability Statement: No new data were created or analyzed in this study. Data sharing is not applicable to this article.

Acknowledgments: Declaration of Generative AI and AI-Assisted Technologies in the Writing Process: Grammarly Pro (https://www.grammarly.com/pro) was used only to paraphrase and refine author-written text. The authors reviewed and approved the final content.

Conflicts of Interest: The authors declare no conflicts of interest.

References

1. Abbasi, W.; Javed, A.; Nazir, A.; Niazi, K.; Malik, J.; Almas, T. Thrombus aspiration from an ectatic coronary artery using SOPHIA plus catheter during primary angioplasty for acute myocardial infarction. *Int. J. Cardiol. Heart Vasc.* **2022**, *39*, 100996. [CrossRef] [PubMed]
2. Abdelaaty, E.; Zaki, A.; Sadaka, M.; Rafla, S. Predictors and outcomes of coronary ectasia presenting with acute coronary syndrome. *Heart Vessels Transplant.* **2025**, *9*, 3. [CrossRef]
3. Ahmed, T.; Khan, M.T.I.; Hasan, A.; Shahadat, S. Coronary artery ectasia with acute myocardial infarction: A case report. *Community Based Med. J.* **2025**, *14*, 193–197. [CrossRef]
4. Eitan, A.; Roguin, A. Coronary artery ectasia: New insights into pathophysiology, diagnosis, and treatment. *Coron. Artery Dis.* **2016**, *27*, 420–428. [CrossRef] [PubMed]
5. Aydemir, S.; Aydın, S.; Altınkaya, O.; Özmen, M.; Özkoç, M.; Aksakal, E. Examination of coronary artery ectasia predictors in acute coronary syndrome. *Biomark. Med.* **2025**, *19*, 589–596. [CrossRef] [PubMed]

6. Bhatt, D.L.; Lopes, R.; Harrington, R. Diagnosis and treatment of acute coronary syndromes: A review. *JAMA* **2022**, *327*, 662–675. [CrossRef] [PubMed]
7. Boles, U.; Rakhit, R.; Shiu, M.F.; Patel, K.; Henein, M.Y. Coronary artery ectasia as a culprit for acute myocardial infarction: Review of pathophysiology and management. *Anadolu Kardiyol. Derg.* **2013**, *13*, 695–701. [CrossRef] [PubMed]
8. Chietera, F.; Ghetti, G. P61 coronary artery ectasia: An enemy not to be underestimated in acute coronary syndrome. *Eur. Heart J. Suppl.* **2022**, *24*, suac012.059. [CrossRef]
9. Chou, Y.D.; Lu, T.; Lin, S.I.; Cheng, H.E.; Liao, F.C.; Lee, C.W. The role of anticoagulation in acute coronary syndrome patients with coronary artery ectasia. *Res. Rep. Clin. Cardiol.* **2025**, *16*, 41–49. [CrossRef]
10. Daas, M.A.; Almasaabi, M.A.; Abdrabou, E.M.; Elmahal, M.; Mahdi, A.-M.O.; Tello, E.A.; Mahdi, O.; Alayyaf, A.E.; Aladwani, A.J.; Ramadan, M.M. A case report of complex acute coronary syndrome presentation: Plaque rupture and mild coronary artery ectasia presenting as de Winter T-waves morphing into anterior ST-elevation myocardial infarction in a young adult male. *SAGE Open Med. Case Rep.* **2025**, *13*, 2050313X251331733. [CrossRef] [PubMed]
11. Dadabaev, M.K.; Radzhapova, Z.; Murataliev, T.M.; Otkeeva, Z.A. Coronary artery ectasia: Current concepts. *Avicenna Bull.* **2025**, *27*, 695–702. [CrossRef]
12. Damay, V.; Pranata, R.; Wiharja, W. Recurrent acute coronary syndrome in a patient with right coronary artery ectasia: A case report. *J. Med. Case Rep.* **2019**, *13*, 78. [CrossRef] [PubMed]
13. Araiza-Garaygordobil, D.; Gopar-Nieto, R.; Martínez, J.S.D.; Mullasari, A.S.; Belderrain-Morales, N.; Nájera-Rojas, N.A.; Diaz-Herrera, B.A.; Sarabia-Chao, V.; Alfaro-Ponce, D.L.; la Cruz, J.L.B.-D.; et al. A randomized trial of antithrombotic therapy in patients with acute coronary syndrome and coronary ectasia. *Am. Heart J.* **2024**, *281*, 103–111. [CrossRef] [PubMed]
14. Pastrana, H.S.; Doma, M.; Fatima, S.R.; Hemdanieh, M.; Kritya, M.; Huang, W.; Naji, Z.; Lingamsetty, S.S.P.; Gewehr, D.M.; Esparza, X.L.R.; et al. Anticoagulation versus antiplatelets in coronary artery ectasia and acute coronary syndrome: A systematic review and meta-analysis. *Circulation* **2024**, *150*, A4135975. [CrossRef]
15. Solis-Jiménez, F.; Esparza, X.L.R.; Guzman-Solorzano, H.P.; Villalobos-Pedroza, M.; Morales-Villamil, L.A.; Diaz-Herrera, B.A.; Hernandez-Pastrana, S.; Gopar-Nieto, R.; Arias-Sanchez, E.A.; Marroquín-Donday, L.A.; et al. Anticoagulant versus antiplatelet therapy after acute coronary syndromes in patients with coronary artery ectasia: A retrospective cohort study. *Cardiovasc. Drugs Ther.* **2025**, *40*, 1021–1033. [CrossRef] [PubMed]
16. Markis, J.E.; Joffe, C.D.; Cohn, P.F.; Feen, D.J.; Herman, M.V.; Gorlin, R. Clinical significance of coronary arterial ectasia. *Am. J. Cardiol.* **1976**, *37*, 217–222. [CrossRef] [PubMed]
17. Woźniak, P.; Iwańczyk, S.; Błaszyk, M.; Stępień, K.; Lesiak, M.; Mularek-Kubzdela, T.; Araszkiewicz, A. Coronary artery aneurysm or ectasia as a form of coronary artery remodeling: Etiology, pathogenesis, diagnostics, complications, and treatment. *Biomedicines* **2024**, *12*, 1984. [CrossRef] [PubMed]
18. Markousis-Mavrogenis, G.; Ebrahimihoor, E.; Lima, J.A.C.; Weber, B.; Schwitter, J.; Mavrogeni, S.I. Coronary artery ectatic/aneurysmatic disease: From pathophysiology to management. *Prog. Cardiovasc. Dis.* **2026**, *96*, 118–130. [CrossRef] [PubMed]
19. Ruiz-Beltran, A.; Hur, S.; Solis, F.; de la Cortina-Martinez, L.G.; Wong, V.J.S.; Valencia, C.I.V.; Aragon, F.A.; Juvera, F.A.; Araiza, D. Abstract 4363481: Prognostic value of Markis classification in patients with coronary ectasia after an acute coronary syndrome: A single-center retrospective cohort study. *Circulation* **2025**, *152*. [CrossRef]
20. Willner, N.; Ehrenberg, S.; Musallam, A.; Roguin, A. Coronary artery ectasia: Prevalence, angiographic characteristics and clinical outcome. *Open Heart* **2020**, *7*, e001096. [CrossRef] [PubMed]
21. Dastgir, N.; Masood, A.; Muqeet, A.; Niazi, G.Z.K. Frequency of risk factors in patients with acute coronary syndrome due to coronary ectasia. *Asian Cardiovasc. Thorac. Ann.* **2020**, *28*, 312–315. [CrossRef] [PubMed]
22. Habib, M. Incidence, clinical presentation and angiographic findings among patients with coronary artery ectasia in Gaza. *Health* **2024**, *16*, 234–241. [CrossRef]
23. Khan, M.S.; Ahmed, O.; Nwaedozie, S. Abstract 442: Anaconda right coronary artery. *Arterioscler. Thromb. Vasc. Biol.* **2023**, *43*, A442. [CrossRef]
24. Barioli, A.; Visco, E.; Pellizzari, N.; Marzot, F.; Lanzellotti, D.; Favero, L.; Cernetti, C. Diagnostic workup and treatment options for aneurysmal coronary artery disease. *Vessel Plus* **2024**, *8*, 13. [CrossRef]
25. Hayes, S.N.; Kim, E.S.H.; Saw, J.; Adlam, D.; Arslanian-Engoren, C.; Economy, K.E.; Ganesh, S.K.; Gulati, R.; Lindsay, M.E.; Mieres, J.H.; et al. Spontaneous coronary artery dissection: Current state of the science: A scientific statement from the American Heart Association. *Circulation* **2018**, *137*, e523–e557. [CrossRef] [PubMed]
26. Nough, H.; Moradi, F.; Varasteravan, H.; Afkhami, L.; Azimizadeh, M.; Mohammadi, H.; Shafiee, M.; Emami, M.; Sartipzade, N.H.; Dahaj, F.S.; et al. Assessment of prevalence and risk factors of isolated coronary artery ectasia: A five-year double-center retrospective study in Yazd, Iran. *Casp. J. Intern. Med.* **2024**, *15*, 244–250. [CrossRef] [PubMed]
27. Donati, F.; Bendandi, F.; Ghetti, G.; Taglieri, N. 623 Coronary ectasia in different clinical subsets: Stable and acute coronary syndromes. *Eur. Heart J. Suppl.* **2021**, *23*, suab134.014. [CrossRef]

28. Candreva, A.; Huwiler, J.; Gallo, D.; Schweiger, V.; Gilhofer, T.; Leone, R.; Würdinger, M.; Rizzini, M.L.; Chiastra, C.; Stehli, J.; et al. Outcomes of coronary artery aneurysms: Insights from the Coronary Artery Ectasia and Aneurysm Registry (CAESAR). *Swiss Med. Wkly.* **2025**, *155*, 3857. [CrossRef] [PubMed]
29. Wang, X.; Montero-Cabezas, J.; Mandurino-Mirizzi, A.; Hirasawa, K.; Marsan, N.A.; Knuuti, J.; Bax, J.J.; Delgado, V. Prevalence and long-term outcomes of patients with coronary artery ectasia presenting with acute myocardial infarction. *Am. J. Cardiol.* **2021**, *156*, 9–15. [CrossRef] [PubMed]
30. Dattoli-García, C.; Gonzalez-Gutiérrez, J.; Jackson-Pedroza, C.; Gallardo-Grajeda, A.; Gopar-Nieto, R.; Pina-Fragoso, V.; Alfaro-Ponce, D.; Ruiz-Fuentes, O.; Araiza-Garaygordobil, D.; Arias-Mendoza, A. Risk factors and cardiovascular outcomes in patients with coronary artery ectasia presenting with ST-elevation myocardial infarction. *Eur. Heart J. Acute Cardiovasc. Care* **2021**, *10*, zuab020.084. [CrossRef]
31. Ilyas, M.; Dastagir, N.; Muqeet, A.; Rehman, I.U.; Afzal, L.; Butt, A. Frequency of coronary artery ectasia as a cause of acute coronary syndrome in patients presenting in Jinnah Hospital Lahore. *JAIMC* **2025**, *22*. [CrossRef]
32. Ghanem, I.; Neguib, T.A.; Gad, M. Relation between coronary artery ectasia characteristics and development of acute coronary syndrome. *Egypt. J. Hosp. Med.* **2023**, *90*, 3428–3436. [CrossRef]
33. Falla, D.A.R.; Rafael-Horna, E.; Burgos, J.Q.; Lévano-Pachas, G.; Meneses, G. Clinical and angiographic characteristics of patients with coronary artery ectasia in a referral hospital. *Arch. Peru. Cardiol. Cir. Cardiovasc.* **2022**, *3*, 139–144. [CrossRef]
34. Devabhaktuni, S.R.; Mercedes, A.; Diep, J.; Ahsan, C. Coronary artery ectasia—A review of current literature. *Curr. Cardiol. Rev.* **2016**, *12*, 318–323. [CrossRef] [PubMed]
35. Androulakis, A.E.; Andrikopoulos, G.K.; Kartalis, A.N.; Stougiannos, P.N.; Katsaros, A.A.; Syrogiannidis, D.N.; Tapanlis, E.N.; Stefanadis, C.; Kallikazaros, I.E. Relation of coronary artery ectasia to diabetes mellitus. *Am. J. Cardiol.* **2004**, *93*, 1165–1167. [CrossRef] [PubMed]
36. Ipek, G.; Gungor, B.; Karatas, M.B.; Onuk, T.; Keskin, M.; Tanik, O.; Hayiroglu, M.I.; Oz, A.; Borklu, E.B.; Bolca, O. Risk factors and outcomes in patients with ectatic infarct-related artery who underwent primary percutaneous coronary intervention after ST-elevated myocardial infarction. *Catheter. Cardiovasc. Interv.* **2016**, *88*, 748–753. [CrossRef] [PubMed]
37. Gunasekaran, P.; Stanojevic, D.; Drees, T.; Fritzlen, J.; Haghnegahdar, M.; McCullough, M.; Barua, R.; Mehta, A.; Hockstad, E.; Wiley, M.; et al. Prognostic significance, angiographic characteristics and impact of antithrombotic and anticoagulant therapy on outcomes in high versus low grade coronary artery ectasia: A long-term follow-up study. *Catheter. Cardiovasc. Interv.* **2019**, *93*, 1219–1227. [CrossRef] [PubMed]
38. Khedr, A.; Neupane, B.; Proskuriakova, E.; Jada, K.; Djossi, S.K.; A Mostafa, J. Pharmacologic management of coronary artery ectasia. *Cureus* **2021**, *13*, e17832. [CrossRef] [PubMed]
39. Wang, H.; Jiang, M.; Li, X.; Zhao, Y.; Shao, J.; Liu, Z.; Lin, L.; Xu, Q.; Wang, L.; Lu, X.; et al. Anti-inflammatory therapies for coronary heart disease: A systematic review and meta-analysis. *Front. Cardiovasc. Med.* **2021**, *8*, 726341. [CrossRef] [PubMed]
40. Taghizadeh, M.J.; Khodadadi, S.; Zamanifard, S. Evaluation of drugs and strategies for treating coronary artery ectasia: Update and future perspective. *Jundishapur J. Chronic Dis. Care* **2022**, *11*, e123301. [CrossRef]
41. Malky, Y.; Bourzeg, K.; Yahya, A.A.; Jamili, M.; Hattaoui, M. Acute coronary syndrome revealing coronary artery ectasia: Case report. *Sch. J. Med. Case Rep.* **2021**, *9*, 1206–1208. [CrossRef]
42. Gibson, C.M.; Cannon, C.P.; Daley, W.L.; Dodge, J.T., Jr.; Alexander, B., Jr.; Marble, S.J.; McCabe, C.H.; Raymond, L.; Fortin, T.; Poole, W.K.; et al. TIMI frame count: A quantitative method of assessing coronary artery flow. *Circulation* **1996**, *93*, 879–888. [CrossRef] [PubMed]
43. Beltrame, J.F.; Limaye, S.B.; Horowitz, J.D. The coronary slow flow phenomenon—A new coronary microvascular disorder. *Cardiology* **2002**, *97*, 197–202. [CrossRef] [PubMed]
44. Kulkarni, S.; Bhairappa, S.; Mujeer, A.; Surhonne, P. Coronary artery ectasia: A rare cause of acute coronary syndrome. *BMJ Case Rep.* **2018**, *14*, bcr2018225654. [CrossRef] [PubMed]
45. Latt, H.; Aung, S.; Kyaw, K.; Seher, R. Coronary artery ectasia presenting with acute inferior wall myocardial infarction in a young adult. *J. Community Hosp. Intern. Med. Perspect.* **2017**, *7*, 262–264. [CrossRef] [PubMed]
46. Marian, S.; Harb, A.; Nadim, S. Coronary artery ectasia in patients presenting with acute coronary syndrome, a mini case series: Presentation, angiographic findings and management. *Clin. Med. Image Libr.* **2018**, *4*, 104. [CrossRef]
47. Pranata, R.; Yonas, E.; Chintya, V.; Alkatiri, A.A. Is anticoagulant necessary in patients with coronary artery ectasia presenting with acute coronary syndrome? A systematic review of case reports. *Int. J. Angiol.* **2019**, *28*, 231–236. [CrossRef] [PubMed]
48. Buonpane, A.; De Caterina, A.R.; Trimarchi, G.; Di Muro, F.M.; Galante, D.; Zella, S.; Pizzino, F.; Ciardetti, M.; Paradossi, U.; Concistrè, G.; et al. Unveiling the causes of acute and non-acute myocardial ischemic syndromes: The role of optical coherence tomography. *Medicina* **2025**, *61*, 1218. [CrossRef] [PubMed]
49. Jeon, H.; Cho, J.M.; Yang, I.H.; Kim, N.; Park, C. Coronary artery ectasia presenting as acute coronary syndrome and misinterpreted as coronary artery perforation: Case report. *Medicine* **2025**, *104*, e42330. [CrossRef] [PubMed]

50. Woźniak, P.; Iwańczyk, S.; Stępień, K.; Błaszyk, M.; Lesiak, M.; Jędraszak, W.; Krupka, G.; Mularek-Kubzdela, T.; Araszkiewicz, A. Assessment of vascular remodeling in coronary artery aneurysm and ectasia using optical coherence tomography: A comparative analysis of dilated and non-dilated segments. *Bioengineering* **2026**, *13*, 14. [CrossRef] [PubMed]
51. Kancharla, S.; Bridges, M.; Hinson, C.L.; Lemor, A. Conquering acute coronary syndrome in coronary artery ectasia: Thrombus resolution with intracoronary thrombolysis, aspiration thrombectomy, and triple therapy. *Cardiovasc. Revasc. Med.* **2024**, *4*, 100044. [CrossRef]
52. Mavrogeni, S. Coronary artery ectasia: From diagnosis to treatment. *Helenic. J. Cardiol.* **2010**, *51*, 158–163.
53. Maltempi, M.; Sforna, S.; Girella, E.; Grassano, D.; Massei, F.; Armadi, P.; Ricci, M.; Aimi, A.; Sclafani, R.; Carluccio, E. ST-segment elevation acute myocardial infarction in patient with coronary artery ectasia and unusual coronary aneurysm. *Eur. Heart J. Suppl.* **2025**, *27*, suaf076.453. [CrossRef]
54. Sorathia, S.; Arockiam, A.D.; Agrawal, A.; Haroun, E.; Khurana, R.; Ahmed, A.; Cho, L.; Jaber, W.; Griffin, B.; Wang, T.K.M. Contemporary review of the clinical features, multi-modality imaging, and management of coronary artery aneurysms. *Eur. Heart J.–Imaging Methods Pract.* **2025**, *3*, qyaf054. [CrossRef] [PubMed]
55. Esposito, L.; Di Maio, M.; Silverio, A.; Cancro, F.P.; Bellino, M.; Attisano, T.; Tarantino, F.F.; Esposito, G.; Vecchione, C.; Galasso, G.; et al. Treatment and outcome of patients with coronary artery ectasia: Current evidence and novel opportunities for an old dilemma. *Front. Cardiovasc. Med.* **2022**, *8*, 805727. [CrossRef] [PubMed]
56. Izraiq, M.; Alshoubaki, N.; Abu-Dhaim, O.A.; Aqel, R. Coronary artery ectasia in acute coronary syndrome: The role of non-vitamin K antagonist oral anticoagulants in management. *Interv. Cardiol.* **2024**, *19*, e25. [CrossRef] [PubMed]
57. Byrne, R.A.; Rossello, X.; Coughlan, J.J.; Barbato, E.; Berry, C.; Chieffo, A.; Claeys, M.J.; Dan, G.-A.; Dweck, M.R.; Galbraith, M.; et al. 2023 ESC Guidelines for the management of acute coronary syndromes. *Eur. Heart J.* **2023**, *44*, 3720–3826. [CrossRef] [PubMed]
58. Azarboo, A.; Daneshvar, M.S.; Abroy, A.S.; Assempoor, R.; Taghvaei, A.; Nasrollahizadeh, A.; Hajiqasemi, M.; Ghaseminejad-Raeini, A.; Hosseini, K. Antithrombotic therapy in adults with ectatic coronary artery disease: A systematic review and network meta-analysis. *Egypt. Heart J.* **2025**, *77*, 13. [CrossRef] [PubMed]
59. Villalobos-Pedroza, M.; Araiza-Garaygordobil, D.; Vega-Servin, N.S.; Arias-Mendoza, M.; Solis-Jiménez, F.; Eid-Lidt, G. Percutaneous coronary intervention and risk of major adverse cardiovascular events in patients with coronary artery ectasia and acute coronary syndrome. *Eur. Heart J. Acute Cardiovasc. Care* **2024**, *13*, zuae036.148. [CrossRef]
60. Greiten, L.E.; Laan, D.; Joyce, L.D.; Greason, K.L.; Daly, R.C.; Schaff, H.V.; King, K.S.; Joyce, D.L. Management of coronary artery aneurysms at the time of surgical revascularization. *J. Surg. Res.* **2020**, *253*, 288–293. [CrossRef] [PubMed]
61. Alshneikat, M.; Bakaeen, F.; Ramsingh, R.; Awad, A.K.; Alaraj, R.; Houghtaling, P.; Unai, S.; Koprivanac, M.; Xu, B.; Tong, Z.Y.; et al. Coronary artery aneurysms: Evolving trends in surgical management. *Thorac. Cardiovasc. Surg.* **2026**, *171*, S23–S24. [CrossRef]
62. Otountzidis, N.; Stalikas, N.; Baroutidou, A.; Karagiannidis, E.; Didagelos, M.; Fyntanidou, B.; Ziakas, A.; Giannakoulas, G. Major adverse cardiovascular events in patients with acute myocardial infarction and angiographic evidence of coronary artery ectasia: A systematic review and meta-analysis. *J. Clin. Med.* **2026**, *15*, 3482. [CrossRef] [PubMed]
63. Magdi, M.; Mostafa, M.R.; Alabdouh, A.; AbdelQadir, Y.H.; Mohamed, S.; Abdelazeem, B.; Ismayl, M.; Abusnina, W.; Alweis, R.; Corteville, D.C.; et al. Long-term outcomes of acute myocardial infarction in preexisting coronary artery ectasia: A systematic review and meta-analysis. *Curr. Probl. Cardiol.* **2023**, *48*, 101626. [CrossRef] [PubMed]
64. Abaci, A.; Yerlikaya, M.G.; Kapanşahin, T.; Savaş, G.; Akyüz, A.R.; Uslu, Ş.; Çekin, M.E.; Hoşoğlu, A.; Bağci, A.; Arslan, A.; et al. Long-term prognosis of acute myocardial infarction caused by isolated diffuse coronary artery ectasia. *Circ. Cardiovasc. Interv.* **2026**, *19*, e016071. [CrossRef] [PubMed]
65. Núñez-Gil, I.J.; Nombela-Franco, L.; Bagur, R.; Bollati, M.; Cerrato, E.; Alfonso, E.; Liebetrau, C.; Hernandez, J.M.D.l.T.; Camacho, B.; Mila, R.; et al. Rationale and design of a multicenter, international, and collaborative Coronary Artery Aneurysm Registry (CAAR). *Clin. Cardiol.* **2017**, *40*, 580–585. [CrossRef] [PubMed]
66. Kerr, G.S.; Hallahan, C.W.; Giordano, J.; Leavitt, R.Y.; Fauci, A.S.; Rottem, M.; Hoffman, G.S. Takayasu arteritis. *Ann. Intern. Med.* **1994**, *120*, 919–929. [CrossRef] [PubMed]

Disclaimer/Publisher's Note: The statements, opinions and data contained in all publications are solely those of the individual author(s) and contributor(s) and not of MDPI and/or the editor(s). MDPI and/or the editor(s) disclaim responsibility for any injury to people or property resulting from any ideas, methods, instructions or products referred to in the content.