Journal of
Cardiovascular Development and Disease

MDPI

Case Report

Post-TAVI Hypotension as a Diagnostic and Therapeutic Challenge: A Case Report of Delayed-Onset Suicide Left Ventricle

Martino Pepe [1], Ivano Barnaba [1,*], Pierpaolo Caretto [1], Antonio Mastrangelo [1], Michelearcangelo Moretti [1], Salvatore Giordano [2], Rocco Tritto [3] and Marco Matteo Ciccone [1]

[1] Division of Cardiology, Department of Interdisciplinary Medicine (D.I.M.), University of Bari Aldo Moro, Piazza Giulio Cesare 11, 70124 Bari, Italy; martino.pepe@uniba.it (M.P.); pierpaolo.caretto@gmail.com (P.C.); antonio.mastrangelo.999@gmail.com (A.M.); moretti.arcangelo@gmail.com (M.M.); marcomatteo.ciccone@uniba.it (M.M.C.)
[2] Division of Cardiology, Department of Medical and Surgical Sciences, "Magna Graecia" University, Viale Europa, 88100 Catanzaro, Italy
[3] Interventional Cardiology Service, Città di Lecce Hospital, GVM Care & Research, Via Provinciale per Arnesano Km 4, 73100 Lecce, Italy
* Correspondence: ivanobarnaba@gmail.com

Abstract

Background: Transcatheter aortic valve implantation (TAVI) for severe aortic stenosis leads to haemodynamic improvement. Patients with a small, hypertrophic left ventricle are predisposed to dynamic left ventricular outflow tract obstruction (LVOTO). Abrupt afterload reduction may trigger "suicide left ventricle", characterised by hypercontractility, near-complete cavity obliteration, systolic anterior motion (SAM)-related LVOTO, and hypotension. Early recognition is crucial because treatments may aggravate the obstruction. Case presentation: A 78-year-old man with hypertension, dyslipidaemia, severe calcific tricuspid aortic stenosis, LV hypertrophy, small LV cavity, and bifascicular block underwent pre-TAVI evaluation. Coronary angiography excluded obstructive coronary disease; because of recurrent syncope, a dual-chamber pacemaker was implanted before TAVI. After transfemoral implantation of a 29 mm Medtronic Evolut FX+ bioprosthesis, the patient developed dyspnoea and hypotension. Bleeding, arrhythmias, and cardiac tamponade were excluded, and no evidence of an acute structural prosthetic complication was identified. Echocardiography showed SAM, a hyperdynamic LV with near-complete systolic cavity obliteration, and a 106 mmHg LVOT gradient with a "dagger-shaped" profile. Intravenous fluid administration, avoidance of diuretics, esmolol, and pacemaker reprogramming were followed by haemodynamic stabilisation and a reduction in LVOTO. Conclusions: Suicide left ventricle is a rare cause of post-TAVI hypotension; male sex and delayed haemodynamic instability were atypical. Early echocardiographic recognition, post-procedural monitoring, and pathophysiology-driven management were paramount for preventing progression to shock.

Keywords: transcatheter aortic valve implantation; suicide left ventricle; left ventricular outflow tract obstruction; systolic anterior motion; hypotension

Check for updates

Academic Editor: Takashi Murashita

Received: 7 September 2026
Revised: 19 October 2026
Accepted: 21 October 2026
Published: 31 October 2026

Copyright: © 2026 by the authors. Licensee MDPI, Basel, Switzerland. This article is an open access article distributed under the terms and conditions of the Creative Commons Attribution (CC BY) license.

1. Introduction

Severe aortic stenosis (AS) is a valvular heart disease with a major prognostic impact; transcatheter aortic valve implantation (TAVI) has recently been progressively expanding indications to intermediate- and also low-risk patients [1].

After TAVI, the reduction in the transvalvular gradient and afterload usually leads to prompt post-procedural haemodynamic improvement [2]. However, in a subset of patients with a hypertrophic left ventricle (LV), small LV cavity, and predisposition to dynamic left ventricular outflow tract obstruction (LVOTO), the abrupt decrease in afterload may paradoxically worsen symptoms and lead to the so-called "suicide left ventricle" (SLV) syndrome [3–5].

SLV is characterised by

- A reduction in end-systolic volume and "near-complete" end-systolic cavity obliteration with contact ("kissing") between the interventricular septum and the inferolateral wall;
- New onset or worsening of dynamic LVOTO, predominantly secondary to systolic anterior motion (SAM) of the anterior mitral leaflet (AML) and eccentric mitral regurgitation [5–7];
- Hypotension, sometimes leading to cardiogenic shock in the absence of obstructive coronary artery disease (CAD) [3,8,9].

SLV has also been described after surgical aortic valve replacement [10] and in other postoperative settings [11]. In recent years, cases have increasingly been reported after TAVI, with presentations ranging from transient hypotension to refractory cardiogenic shock [4–6,9].

We present a case of SLV after TAVI in an elderly patient with severe aortic stenosis and no obstructive coronary artery disease.

2. Case Report

We report the case of a 78-year-old man with hypertension and dyslipidaemia.

In November 2025, the patient was admitted to our Cardiology Division for exertional dyspnoea and syncope. The ECG showed sinus bradycardia associated with bifascicular block (left anterior fascicular block and complete right bundle branch block). Transthoracic echocardiography (TTE), performed under stable haemodynamic conditions (BP 120/70 mmHg, HR 67 bpm), documented a sclerocalcific tricuspid aortic valve and severe stenosis (peak velocity 5.7 m/s; maximum PG 129 mmHg; mean PG 77 mmHg) with mild regurgitation. A marked LV hypertrophy (interventricular septal thickness 18 mm), reduced end-systolic volume, preserved global systolic function (LVEF approximately 55%), and grade I diastolic dysfunction were also shown together with mild mitral and tricuspid regurgitation, an estimated pulmonary artery systolic pressure of 25 mmHg, and a mild non-obstructive chordal SAM (Table 1). The patient was therefore referred for TAVI. ECG-gated CT documented severe calcification of the aortic cusps and an aortic annular diameter of 24 mm, while coronary angiography excluded obstructive coronary artery disease.

Because of recurrent syncope followed by marked bradycardia in the setting of symptomatic bifascicular block, a dual-chamber pacemaker was implanted before TAVI.

At implantation, the device was programmed in DDD mode with a lower rate limit of 60 bpm, a sensed AV delay of 150 ms, and a paced AV delay of 180 ms. Before haemodynamic deterioration, the ventricular pacing burden was approximately 70%.

During the same hospitalisation, under local anaesthesia and conscious sedation, the patient underwent left transfemoral TAVI with implantation of a self-expanding bioprosthesis (Medtronic Evolut FX+ 29 mm). The procedure ended without intraprocedural complications. The nominal diameter-based oversizing was 20.8%, and the final implantation depth was 3 mm below the annular plane using the cusp-overlap technique. Sedation comprised midazolam (2.5 mg), fentanyl (75 µg), and propofol administered in two doses of 20 and 30 mg, totalling 50 mg. An intravenous infusion of normal saline from a 500 mL bag was started at 40 mL/h before the procedure. Hours after transfer to the coronary

intensive care unit (CICU), the patient developed dyspnoea (without auscultatory or radiographic signs of pulmonary congestion) and asthenia associated with persistent severe hypotension (systolic blood pressure 80 mmHg). Heart rate was within the normal range, and haemoglobin was 11 g/dL, with no clinical signs of active bleeding. ECG excluded new ischaemic ST-T changes and major ventricular arrhythmias. At the time of hypotension, before any therapeutic manoeuvre, arterial blood gas analysis showed a normal lactate level (0.5 mmol/L), consistent with early and/or predominantly mechanical haemodynamic instability without evidence of severe tissue hypoperfusion at the time of sampling.

Table 1. Haemodynamic and echocardiographic parameters before and after TAVI. This table compares the main haemodynamic and echocardiographic parameters before TAVI and during post-TAVI haemodynamic instability. Abbreviations: BP = blood pressure; HR = heart rate; LV = left ventricle; LVEF = left ventricular ejection fraction; IVS = interventricular septum; SAM = systolic anterior motion; MR = mitral regurgitation; TR = tricuspid regurgitation; PASP = pulmonary artery systolic pressure; LVOT = left ventricular outflow tract; CW = continuous wave; ABG = arterial blood gas analysis.

Variable	Pre-TAVI	Post-TAVI (During Instability)
BP/HR	120/70 mmHg; 67 bpm	80/40 mmHg; 60 bpm
Native aortic stenosis	Vmax 5.7 m/s; peak gradient 129 mmHg; mean gradient 77 mmHg	Valve replaced
Aortic prosthesis (Medtronic Evolut FX+ 29 mm)	—	Well positioned; peak gradient 33 mmHg; mean gradient 19 mmHg
Paravalvular leak	—	Trivial-to-mild
LV function	Estimated LVEF ~55%	Hyperdynamic ("kissing")
LV hypertrophy	IVS 18 mm	IVS 18 mm
SAM	Present, mild	Present, severe
Mitral regurgitation	Mild	Mild-to-moderate, eccentric
Dynamic LVOT/intraventricular gradient	Absent	Present, peak gradient 106 mmHg (CW "dagger-shaped")
TR/PASP	Mild TR; PASP 25 mmHg	Mild TR; PASP not measurable
Pericardial effusion	Absent	Absent
Lactate (ABG)	—	0.5 mmol/L

TTE during haemodynamic instability (BP 80/40 mmHg, HR 60 bpm) excluded cardiac tamponade and showed no evidence of acute structural prosthetic complication (aortic prosthesis peak gradient 33 mmHg, mean gradient 19 mmHg, and trivial-to-mild paravalvular leak), but demonstrated marked LV hypercontractility with a tendency towards systolic "kissing" between the mid segments of the lateral wall and the interventricular septum (Figure 1C; Video S1). TTE also highlighted severe SAM of the anterior mitral leaflet, mild-to-moderate mitral regurgitation with an eccentric jet (Figure 1A,B), and a significant dynamic gradient (peak gradient 106 mmHg). In detail, continuous-wave Doppler showed a dagger-shaped mid-to-late systolic profile, consistent with dynamic LVOTO due to SAM (Figure 1D). Separate CW recordings obtained with different beam alignments yielded profiles interpreted as prosthetic flow and dynamic subvalvular obstruction. However, a contribution of dynamic LVOTO to the reported prosthetic gradient cannot be excluded. The Doppler velocity index was unavailable because the required quantitative Doppler measurements were not acquired during the emergency examination. Overall, these findings supported a diagnosis of post-TAVI suicide left ventricle.

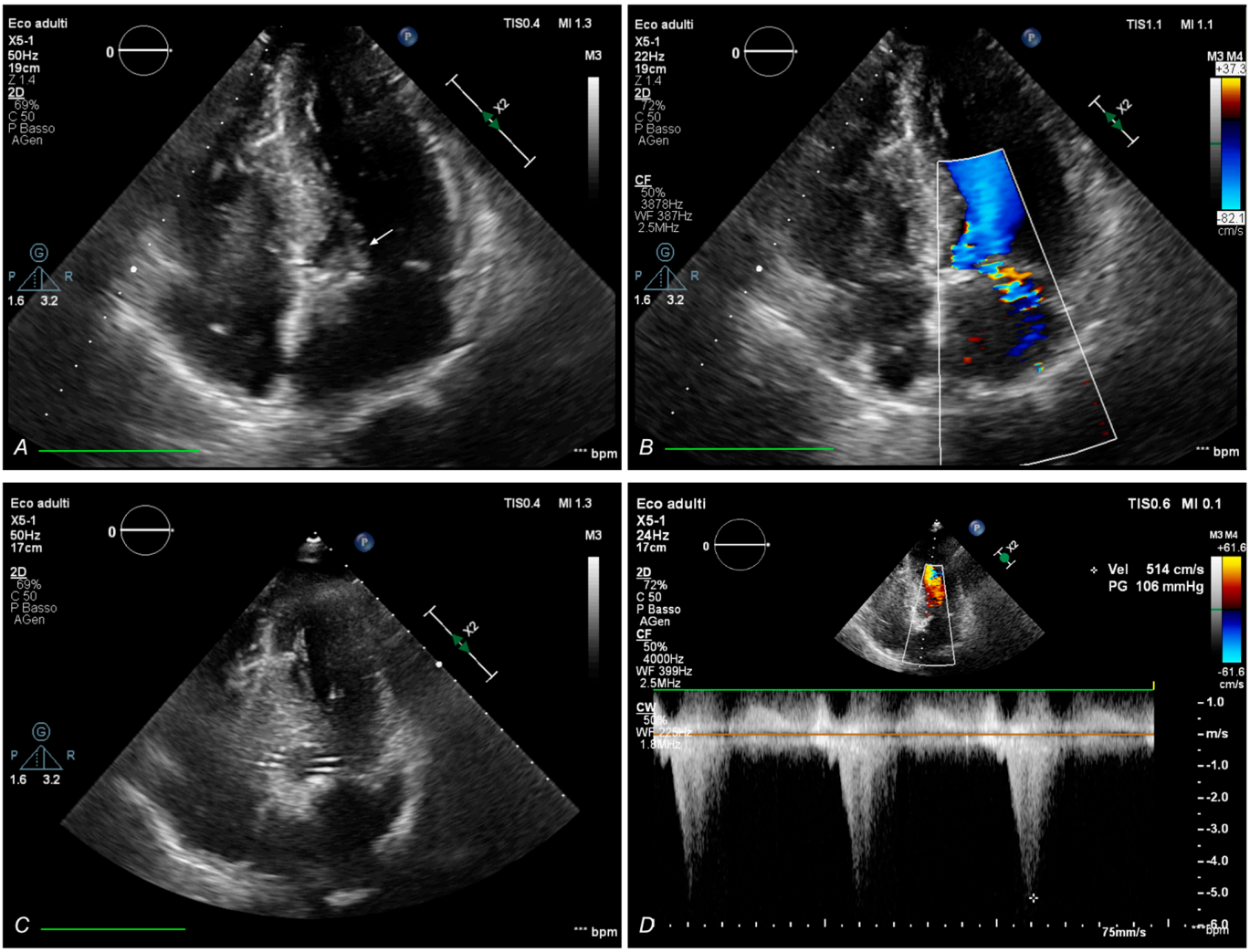

Figure 1. Transthoracic echocardiography assessing mitral SAM and post-TAVI dynamic LVOTO. (**A**) Two-dimensional image showing severe SAM of the anterior mitral leaflet (arrow). (**B**) Colour Doppler showing mild-to-moderate eccentric mitral regurgitation directed toward the posterior left atrial wall, consistent with SAM of the AML. (**C**) Apical four-chamber view showing near-complete LV end-systolic obliteration with "kissing" between the interventricular septum and lateral wall. (**D**) Continuous-wave Doppler spectrum at the LVOT showing a dynamic gradient with a mid-to-late systolic "dagger-shaped" profile, consistent with dynamic LVOTO.

According to the pathophysiological rationale and available evidence [3,6,8], the intravenous saline infusion rate was increased from 40 to 80 mL/h, and esmolol was administered by continuous intravenous infusion at 25 µg/kg/min for approximately three hours, without a loading dose. Diuretics were not administered to avoid further preload reduction. The sensed and paced AV delays were shortened to 100 ms and 120 ms, respectively, to favour fully paced ventricular activation and minimise possible fusion with intrinsic conduction. Fusion was hypothesised rather than demonstrated. Pacemaker reprogramming to favour right ventricular pacing during beta-blockade may have contributed to haemodynamic improvement by inducing a degree of septal dyssynchrony and modifying LV geometry. However, the independent contribution of pacing cannot be distinguished from the simultaneous effects of intravenous fluid administration and beta-blockade. Vasopressors were not administered during the hypotensive episode. Intravenous inotropes were avoided because increased LV contractility could have exacerbated the dynamic obstruction. Beta-blockade reduced inotropism, while appropriate pacemaker programming prevented

excessive bradycardia. Over the following 24–48 h, blood pressure progressively improved to 110–120/60–70 mmHg, together with a reduction in LVOTO, although a residual peak gradient of 45 mmHg persisted. Lactate remained below 2 mmol/L.

The patient was transferred to the cardiology ward and discharged on optimised medical therapy which included a titrated beta-blocker. At discharge, pacemaker interrogation showed normal device function, no arrhythmic events and a ventricular pacing burden >90%; the device was programmed in DDD mode with a lower rate limit of 60 bpm, a sensed AV delay of 120 ms, and a paced AV delay of 150 ms. At the 1-month follow-up visit the patient was asymptomatic and haemodynamically stable, with a peak LVOT gradient of 22 mmHg. At the latest clinical and echocardiographic assessment, performed in August 2026, approximately nine months after TAVI, the patient remained clinically stable, with a peak LVOT gradient of 8 mmHg, persistent chordal SAM, and trivial mitral regurgitation. At this assessment, the mean transprosthetic aortic gradient was 16 mmHg and the peak gradient was approximately 31 mmHg, with a peak transprosthetic velocity of 2.8 m/s. The DVI estimated from the peak velocity ratio was approximately 0.50. The clinical timeline is summarised in Figure 2, with the main clinical parameters, interventions and follow-up findings reported in Table 2 [12].

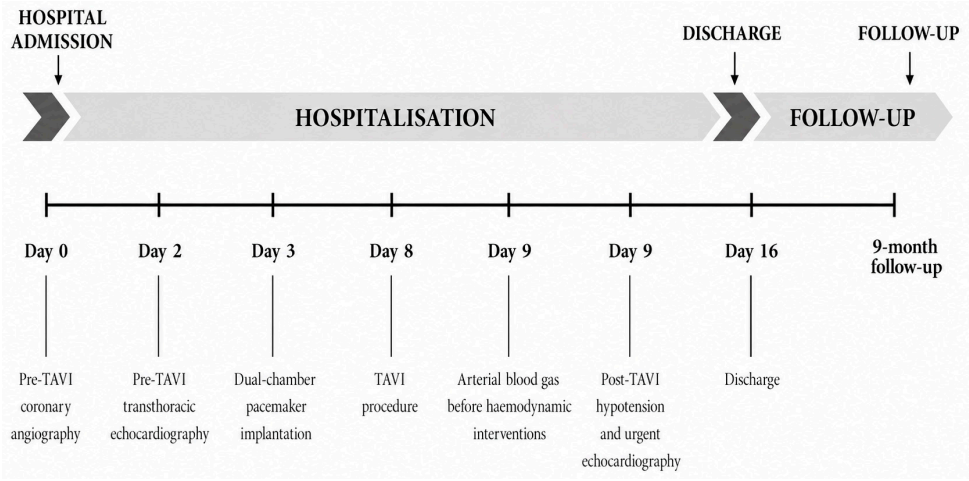

Figure 2. Case report timeline. The figure chronologically summarises the main clinical and diagnostic milestones from the pre-procedural phase through follow-up. The timeline shows the main events that occurred during the hospitalisation, from Day 0, when the patient was admitted to hospital, to Day 16, when he was discharged, as well as the approximately nine-month follow-up.

Table 2. Clinical course, diagnostic findings, interventions, and response during hospitalisation and follow-up. The table shows the main clinical parameters, diagnostic findings, and interventions during the hospital stay and at the one-month and approximately nine-month follow-up assessments. Abbreviations: BP = blood pressure; HR = heart rate; TAVI = transcatheter aortic valve implantation; LAD = left anterior descending artery; IVS = interventricular septum; LVEF = left ventricular ejection fraction; MR = mitral regurgitation; TR = tricuspid regurgitation; PASP = pulmonary artery systolic pressure; SAM = systolic anterior motion; ABG = arterial blood gas analysis. LVOT = left ventricular outflow tract; DVI = Doppler velocity index; Vmax = peak velocity.

Time	Event	Clinical Parameters	Main Tests or Results	Intervention and Response
Admission (Day 0)	Pre-TAVI coronary angiography	BP 131/60 mmHg	No obstructive CAD; short ~30% proximal LAD stenosis	Right radial approach; no complications

Table 2. *Cont.*

Time	Event	Clinical Parameters	Main Tests or Results	Intervention and Response
Day 2	Pre-TAVI transthoracic echocardiography	BP 120/70 mmHg; HR 67 bpm	Severe AS (Vmax 5.7 m/s; peak/mean gradients 129/77 mmHg); LVEF ~55%; IVS 18 mm; mild MR/TR; PASP 25 mmHg; no pericardial effusion	—
Day 3	Dual-chamber pacemaker implantation	BP 125/70 mmHg; HR 65 bpm	—	Successful implantation; no complications
Day 8	TAVI procedure	BP 135/95 mmHg; HR 60 bpm	Medtronic Evolut FX+ 29 mm implantation; optimal angiographic result	Transfemoral TAVI; no procedural complications
Day 9	Arterial blood gas before haemodynamic interventions	During subsequent hypotensive episode	Lactate 0.5 mmol/L	—
Day 9	Post-TAVI hypotension and urgent echocardiography	BP 80/40 mmHg; HR 60 bpm	Prosthesis well positioned; prosthetic peak/mean gradients 33/19 mmHg; trivial-to-mild paravalvular leak; hyperdynamic "kissing" LV; severe SAM; mild-to-moderate eccentric MR; dynamic gradient 106 mmHg; no pericardial effusion	Increase in intravenous fluid infusion rate, avoidance of diuretic administration, esmolol and pacing optimisation; haemodynamic improvement and reduction in the dynamic gradient.
Discharge (Day 16)	—	BP 140/90 mmHg; HR 60 bpm	Clinically stable. Peak LVOT gradient 45 mmHg	—
1-month follow-up	Clinical and echocardiographic assessment	Asymptomatic; haemodynamically stable	Peak LVOT gradient 22 mmHg	Continued and titrated beta-blocker therapy
Approximately 9-month follow-up (August 2026)	Clinical and echocardiographic assessment	Clinically stable	Peak LVOT gradient 8 mmHg; persistent chordal SAM; trivial MR; prosthetic peak/mean gradients approximately 31/16 mmHg; prosthetic Vmax 2.8 m/s; DVI estimated from peak velocities approximately 0.50	—

3. Discussion

3.1. Mechanism and Pathophysiology

SLV is a rare but clinically relevant complication of aortic valve replacement, either surgical or transcatheter. Its pathogenesis involves several key steps:

- Abrupt afterload reduction after aortic stenosis correction;

- Hypercontractility of a small, stiff, and hypertrophic LV with a drastic reduction in end-systolic volume;
- Onset of dynamic LVOTO due to SAM of the anterior mitral leaflet, which may be elongated or redundant, and/or direct septal–posterior wall contact (kissing ventricle) leading to a further reduction in forward flow and worsening of hypotension in a vicious cycle.

This sequence may cause severe hypotension and cardiogenic shock and also mimic acute myocardial infarction because of the mismatch between myocardial oxygen supply and demand, despite negative or unchanged coronary angiographic findings [3,4,6,9].

The ventricular portion of a self-expanding prosthesis may influence LVOT geometry and its relationship with the anterior mitral leaflet, potentially contributing to SAM [13]. In this patient, the final implantation depth of 3 mm below the annular plane does not establish or exclude a mechanical contribution of the frame. Valve selection in patients with a hypertrophic LV, small cavity, and baseline SAM should consider annular and LVOT anatomy, the mitral apparatus, frame design, and anticipated ventricular protrusion. This case cannot establish whether a different prosthesis would have prevented LVOTO.

3.2. Differential Diagnosis of Hypotension After TAVI

Post-TAVI hypotension is a diagnostic challenge and requires a targeted strategy to exclude multiple possible causes (Figure 3). VARC-3 provides standardised definitions for procedural complications and bioprosthetic valve dysfunction [14].

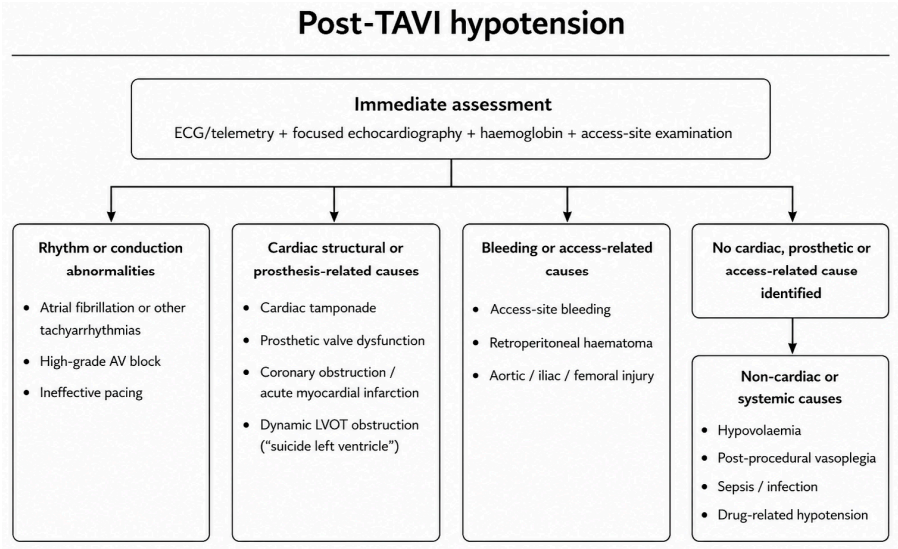

Figure 3. Diagnostic approach to post-TAVI hypotension. During post-TAVI hypotension, the main potential causes should initially be considered; therefore, it is necessary to assess the ECG or telemetry monitoring, check the haemoglobin level, examine the access site, and perform echocardiography. The figure shows an algorithm including the main possible causes of post-TAVI hypotension.

Clinical assessment of vascular access sites, physical examination of femoral pulses, and haemoglobin measurement are essential to exclude early vascular complications that may explain hypotension. Echocardiographic assessment of LV segmental wall motion and ECG evaluation of ST–T segments help to rule out new-onset acute myocardial ischaemia.

Moreover, echocardiography in the setting of post-TAVI hypotension is essential to exclude cardiac tamponade and early prosthetic dysfunction associated with elevated transprosthetic gradients or severe intra- or paravalvular regurgitation. Importantly, it may also identify the characteristic features of SLV.

Arrhythmias must also be ruled out by telemetry monitoring and/or prompt ECG acquisition when hypotension occurs.

3.3. Predisposing Factors and Evidence from the Literature

In a recent series, post-TAVI LVOTO (defined as a peak gradient above 30 mmHg) occurred in 1.3% of patients and was associated with greater septal thickness, smaller LVOT dimension, and higher pre-procedural LVOT velocity; six patients developed acute haemodynamic compromise immediately after TAVI [2].

A recent narrative review on post-TAVI SLV by Romano et al. [3] highlighted predisposing factors which included small LV cavity, basal septal hypertrophy or a "sigmoid septum," pre-existing (even latent) dynamic LVOTO, female sex, and long-standing hypertension.

Hypertension and severe AS provide plausible explanations for LV hypertrophy, but concomitant hypertrophic cardiomyopathy or transthyretin cardiac amyloidosis (ATTR) cannot be excluded [15]. Increased LV wall thickness and conduction disease in an elderly patient with AS warrant consideration of cardiac amyloidosis [16]. The patient reported no family history of hypertrophic cardiomyopathy or sudden cardiac death, although this does not exclude hypertrophic cardiomyopathy. Longitudinal strain analysis with assessment of apical sparing and bone scintigraphy were not performed. Bone scintigraphy to investigate possible ATTR cardiac amyloidosis is planned during follow-up.

A systematic review by Barzallo et al. [8] highlighted that acute haemodynamic compromise after TAVI due to dynamic LV obstruction frequently requires advanced strategies including pacing, vasopressors, mechanical support, or septal ablation, with such measures used in nearly 65% of reported patients. Several therapeutic approaches have been described, often in combination:

- Conservative management: volume loading, discontinuation of inotropes, use of beta-blockers and pure vasoconstrictors (phenylephrine, vasopressin) to increase afterload and vascular tone and help reduce dynamic obstruction [3,6,8];
- Right ventricular apical pacing or dual-chamber pacing at controlled rates, which may modify LV geometry and reduce the LVOT gradient [3,6,7];
- Septal reduction therapy with alcohol septal ablation in refractory cases with marked septal hypertrophy [6], or, more recently, pre-TAVI endocardial radiofrequency septal ablation in selected high-risk patients [17];
- Temporary mechanical support such as veno-arterial ECMO may be considered in refractory shock [10,18], whereas IABP-induced afterload reduction may exacerbate dynamic LVOTO [19]. Impella requires individualised assessment of LV filling and suction risk; successful use has been reported in mixed cardiogenic and distributive shock after alcohol septal ablation had relieved LVOTO [20].

Favourable outcomes have also been reported with combined dual-chamber pacing and vasopressor therapy in post-TAVI SLV, supporting a potential role for heart-rate control and atrioventricular synchronisation within a multimodal strategy [6].

3.4. What This Case Adds

- Anatomic predisposition: Hypertrophic LV, small LV cavity, and mild non-obstructive chordal SAM already present at baseline suggested a vulnerable substrate, despite the absence of a resting dynamic gradient. This further supports focused pre-TAVI echocardiographic assessment for resting or provocable dynamic LVOTO, using physiological manoeuvres such as Valsalva when clinically appropriate [15,21].
- Clinical presentation: The patient was male, despite the marked female predominance in previous literature [8]. Moreover, haemodynamic instability developed several hours after TAVI rather than immediately after valve deployment.

- Role of dual-chamber pacing: Although the device was implanted for an indication unrelated to the obstruction, pacemaker reprogramming to favour right ventricular pacing during beta-blockade may have contributed to haemodynamic improvement. Ventricular pacing with a left bundle branch block-type activation pattern (Figure 4) may induce a degree of septal dyssynchrony and modify LV geometry, thereby reducing mitral–septal contact and the dynamic gradient. This mechanism is consistent with the obstructive hypertrophic cardiomyopathy pacing literature [22,23] and with post-TAVI reports describing a reduction in LVOTO during right ventricular pacing [5,7]. Nevertheless, treatment in this patient was multicomponent, and the independent effect of pacing cannot be separated from the simultaneous effects of intravenous fluid administration and beta-blockade.

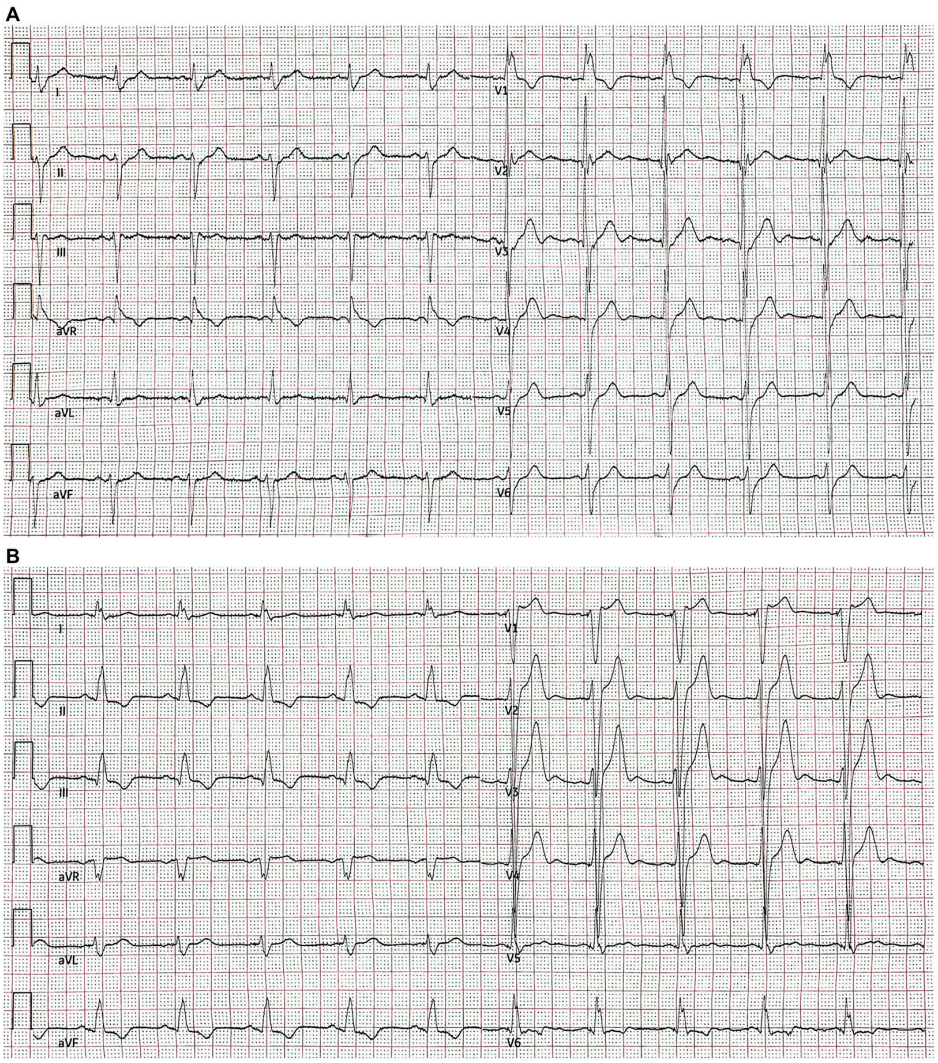

Figure 4. Twelve-lead ECG before and after pacemaker implantation. (**A**) Before pacemaker implantation: sinus rhythm with bifascicular block (right bundle branch block and left anterior fascicular block). Ventricular rate 67 bpm, PR 168 ms, QRS 166 ms, QT/QTc (Bazett) 444/469 ms. (**B**) After pacemaker implantation, before TAVI: paced rhythm with atrial-sensed ventricular pacing and a left bundle branch block-type morphology. Ventricular rate 64 bpm, PR 152 ms, QRS 186 ms, QT/QTc (Bazett) 485/501 ms. The paced QRS morphology reflects dyssynchronous ventricular activation, which may theoretically modify septal contraction and LV geometry, increase end-systolic cavity size, and reduce mitral–septal contact. In this patient, however, the independent contribution of pacing to haemodynamic improvement cannot be distinguished from the simultaneous effects of intravenous fluid administration and beta-blockade.

- Echocardiographic pattern of SAM plus kissing ventricle: The emergence of severe SAM, supported by the development of eccentric mitral regurgitation, together with marked hypercontractility and a kissing LV pattern, should be systematically sought in hypotensive post-TAVI patients. In this case, the temporal association between hypotension, SAM, cavity obliteration, and the dynamic LVOT gradient was decisive for the diagnosis.

3.5. Clinical Implications

Pre-procedural assessment should specifically consider

- Hypertrophic LV with small cavity and prominent basal septum;
- Elongated or redundant anterior mitral leaflet and a narrow mitral–aortic angle;
- Pre-existing or provocable dynamic LVOT gradient at baseline echocardiography.

When the risk of post-TAVI SLV is considered high, it is reasonable to

- Avoid excessive blood pressure reduction during the pre- and peri-procedural phases;
- Optimise fluid management by carefully balancing intravenous volume administration and diuretic therapy;
- Plan early echocardiographic monitoring after TAVI.

When SLV is suspected, management should be pathophysiology driven and may include

- Adequate volume loading, while avoiding negative fluid balance and excessive diuretic doses;
- Short-acting, cardioselective beta-blockade with agents such as esmolol or landiolol to reduce contractility and heart rate;
- Avoidance or withdrawal of inotropes and use of pure vasoconstrictors when required;
- Tailored pacing protocols;
- Septal reduction therapy or temporary mechanical support with VA-ECMO in refractory cases.

3.6. Limitations

This case report includes only the available data on pre-procedural and follow-up echocardiography, pacing, and fluid balance. Echocardiography during haemodynamic instability was performed urgently, with limited time for a complete quantitative assessment. The underlying cause of LV hypertrophy was not fully characterised. Moreover, as the treatments were administered concurrently, the contribution of each intervention to haemodynamic improvement cannot be established. Specifically, pre-procedural LVOT diameter and peak velocity, anterior mitral leaflet length, aorto-mitral angle, CT-derived LVOT dimensions, aortic annular perimeter and area, and a Valsalva-provoked LVOT gradient were unavailable. LVOT pulsed-wave Doppler was not acquired during the acute episode, preventing calculation of the DVI at that time. A complete peri-procedural fluid balance and the ventricular pacing percentage during haemodynamic deterioration were also unavailable. Quantitative LV dimensions at discharge and follow-up, systematic SAM grading at these assessments, and MR severity at discharge and one month were not documented in the available reports. Longitudinal strain analysis with assessment of apical sparing and bone scintigraphy were not performed.

4. Conclusions

"Suicide left ventricle" is a rare but potentially serious complication of TAVI in patients with severe aortic stenosis and a predisposition to dynamic LVOTO. In the present case, marked hypotension and an echocardiographic pattern of SAM, kissing ventricle, and

dynamic obstruction enabled prompt diagnosis and a pathophysiology-driven multimodal strategy, including pacemaker reprogramming, with a favourable outcome.

Pre-procedural echocardiographic assessment for latent LVOTO, early recognition of SLV, and timely haemodynamic management are essential. Active involvement of the multidisciplinary valve team is crucial to prevent, promptly identify, and effectively treat this infrequent but potentially life-threatening complication.

Supplementary Materials: The following supporting information can be downloaded at https://www.mdpi.com/article/10.3390/jcdd13110558/s1: Video S1: Transthoracic echocardiographic cine loop showing near-complete left ventricular end-systolic cavity obliteration ("kissing") after TAVI.

Author Contributions: Conceptualisation, I.B., M.P. and M.M.C.; methodology, I.B., M.P. and M.M.C.; investigation, I.B., P.C., A.M., M.M., S.G. and R.T.; resources, P.C., A.M., M.M., S.G. and R.T.; data curation, I.B., P.C., A.M., M.M., S.G. and R.T.; validation, I.B., M.P. and M.M.C.; visualisation, I.B.; writing—original draft preparation, I.B.; writing—review and editing, I.B., M.P., P.C., A.M., M.M., S.G., R.T. and M.M.C.; supervision, M.P. and M.M.C.; project administration, I.B. All authors have read and agreed to the published version of the manuscript.

Funding: This research received no external funding.

Institutional Review Board Statement: Ethical review and approval were not required for this single-patient case report according to local institutional policy.

Informed Consent Statement: Written informed consent has been obtained from the patient to publish this paper and the associated images. Data were anonymised to protect confidentiality.

Data Availability Statement: The clinical information supporting the findings of this case report is contained within the article. Additional patient-level data are not publicly available because of privacy and ethical restrictions.

Acknowledgments: During the preparation of this manuscript, the authors used ChatGPT (GPT-5.6 Sol, OpenAI) to generate the graphical layouts of Figures 2 and 3. The authors have reviewed and edited the outputs and take full responsibility for the content of this publication.

Conflicts of Interest: The authors declare no conflicts of interest.

References

1. Praz, F.; Borger, M.A.; Lanz, J.; Marin-Cuartas, M.; Abreu, A.; Adamo, M.; Ajmone Marsan, N.; Barili, F.; Bonaros, N.; Cosyns, B.; et al. 2025 ESC/EACTS Guidelines for the management of valvular heart disease. *Eur. Heart J.* **2025**, *46*, 4635–4736. [CrossRef] [PubMed]
2. Kobayashi, Y.; Enta, Y.; Nakashima, M.; Saigan, M.; Satomi, N.; Teng, Y.; Tazawa, D.; Munehisa, Y.; Taguri, M.; Hata, M.; et al. Incidence, predictors, and prognostic impact of left ventricular outflow tract obstruction following transcatheter aortic valve replacement. *CJC Open* **2025**, *7*, 1236–1243. [CrossRef] [PubMed]
3. Romano, S.; D'Andrea, E.; Cozac, D.A.; Savo, M.T.; Cecchetto, A.; Baritussio, A.; Martini, M.; Napodano, M.; Bauce, B.; Pergola, V. Silent threats of the heart: A case series and narrative review on suicide left ventricle post-aortic valve replacement in patients with dynamic LVOT obstruction and aortic stenosis. *J. Clin. Med.* **2024**, *13*, 5555. [CrossRef] [PubMed]
4. Suh, W.M.; Witzke, C.F.; Palacios, I.F. Suicide left ventricle following transcatheter aortic valve implantation. *Catheter. Cardiovasc. Interv.* **2010**, *76*, 616–620. [CrossRef] [PubMed]
5. Weich, H.S.v.; John, T.J.; Joubert, L.; Moses, J.; Herbst, P.; Doubell, A. Dynamic left ventricular outflow tract obstruction post-transcatheter aortic valve replacement. *JACC Case Rep.* **2021**, *3*, 871–874. [CrossRef] [PubMed]
6. Koliastasis, L.; Drakopoulou, M.; Latsios, G.; Apostolos, A.; Ktenopoulos, N.; Katsaros, O.; Kachrimanidis, I.; Synetos, A.; Tsioufis, K.; Toutouzas, K. Overcoming the obstacle of suicide left ventricle after transcatheter aortic valve replacement phenomenon. *JACC Case Rep.* **2023**, *26*, 102065. [CrossRef] [PubMed]
7. Marchel, M.; Szczerba, E.; Pędzich-Placha, E.; Huczek, Z.; Kochman, J.; Kochanowski, J.; Grabowski, M.; Opolski, G. Left ventricular outflow obstruction after TAVR due to systolic anterior motion successfully treated with cardiac pacing. *J. Cardiothorac. Vasc. Anesth.* **2020**, *34*, 2718–2721. [CrossRef] [PubMed]

8. Barzallo, D.; Torrado, J.; Benites-Moya, C.J.; Sturla, M.; Echarte-Morales, J.; Scotti, A.; Kharawala, A.; Terré, J.A.; Sugiura, T.; Wiley, J.; et al. Acute hemodynamic compromise after transcatheter aortic valve replacement due to dynamic left ventricle obstruction: A systematic review. *Am. J. Cardiol.* **2024**, *214*, 125–135. [CrossRef] [PubMed]
9. Schulz, C.; Brunner, F.J.; Pecha, S.; Sörensen, N.; Schofer, N. When the heart becomes suicidal: A case report of severe left ventricular outflow tract obstruction following transcatheter aortic valve implantation. *Eur. Heart J. Case Rep.* **2025**, *9*, ytaf164. [CrossRef] [PubMed]
10. Lioufas, P.A.; Kelly, D.N.; Brooks, K.S.; Marasco, S.F. Unexpected suicide left ventricle post-surgical aortic valve replacement requiring veno-arterial extracorporeal membrane oxygenation support despite gold-standard therapy: A case report. *Eur. Heart J. Case Rep.* **2022**, *6*, ytac020. [CrossRef] [PubMed]
11. Naseerullah, F.S.; Wickramasinghe, S.R. Unusual case of post-operative suicide left ventricle in a patient with dynamic LVOT obstruction. *J. Cardiol. Cases* **2022**, *26*, 236–238. [CrossRef] [PubMed]
12. Gagnier, J.J.; Kienle, G.; Altman, D.G.; Moher, D.; Sox, H.; Riley, D.; CARE Group. The CARE Guidelines: Consensus-based Clinical Case Reporting Guideline Development. *Glob. Adv. Health Med.* **2013**, *2*, 38–43. [CrossRef] [PubMed]
13. Pislaru, S.V.; Nkomo, V.T.; Sandhu, G.S. Assessment of Prosthetic Valve Function After TAVR. *JACC Cardiovasc. Imaging* **2016**, *9*, 193–206. [CrossRef] [PubMed]
14. VARC-3 Writing Committee; Généreux, P.; Piazza, N.; Alu, M.C.; Nazif, T.; Hahn, R.T.; Pibarot, P.; Bax, J.J.; Leipsic, J.A.; Blanke, P.; et al. Valve Academic Research Consortium 3: Updated endpoint definitions for aortic valve clinical research. *Eur. Heart J.* **2021**, *42*, 1825–1857. [CrossRef] [PubMed]
15. Arbelo, E.; Protonotarios, A.; Gimeno, J.R.; Arbustini, E.; Barriales-Villa, R.; Basso, C.; Bezzina, C.R.; Biagini, E.; Blom, N.A.; de Boer, R.A.; et al. 2023 ESC Guidelines for the management of cardiomyopathies. *Eur. Heart J.* **2023**, *44*, 3503–3626. [CrossRef] [PubMed]
16. Garcia-Pavia, P.; Rapezzi, C.; Adler, Y.; Arad, M.; Basso, C.; Brucato, A.; Burazor, I.; Caforio, A.L.P.; Damy, T.; Eriksson, U.; et al. Diagnosis and treatment of cardiac amyloidosis: A position statement of the ESC Working Group on Myocardial and Pericardial Diseases. *Eur. Heart J.* **2021**, *42*, 1554–1568. [CrossRef] [PubMed]
17. Valdigem, B.P.; Paladino Filho, A.T.; de Andrade Vilela, A.; de Barros Correia, E.; Ramos, A.; Assef, J.E.; Siqueira, D.; Pinto Filho, I.M. Septal preparation for TAVR using radiofrequency catheters in patients with LVOT obstruction: 1-year follow-up. *JACC Case Rep.* **2025**, *30*, 103606. [CrossRef] [PubMed]
18. Torrado, J.; Barzallo, D.; Terré, J.A.; Benites-Moya, C.J.; Ríos, S.; García, M.; Chau, M.; Wiley, J.M.; Latib, A. Impact of VA-ECMO on dynamic LV outflow obstruction after transcatheter aortic valve replacement. *JACC Case Rep.* **2024**, *29*, 102157. [CrossRef] [PubMed]
19. Coddens, J.; Van Alphen, J.; Deloof, T.; Hendrickx, J. Dynamic left ventricular outflow tract obstruction caused by afterload reduction induced by intra-aortic balloon counterpulsation. *J. Cardiothorac. Vasc. Anesth.* **2002**, *16*, 749–751. [CrossRef] [PubMed]
20. Matsuda, J.; Nakata, J.; Yamamoto, T.; Asai, K. Mixed shock after alcohol septal ablation for hypertrophic obstructive cardiomyopathy: Impella in crisis management. *J. Cardiol. Cases* **2025**, *31*, 134–138. [CrossRef] [PubMed]
21. Ommen, S.R.; Ho, C.Y.; Asif, I.M.; Balaji, S.; Burke, M.A.; Day, S.M.; Dearani, J.A.; Epps, K.C.; Evanovich, L.; Ferrari, V.A.; et al. AHA/ACC/AMSSM/HRS/PACES/SCMR Guideline for the Management of Hypertrophic Cardiomyopathy: A Report of the American Heart Association/American College of Cardiology Joint Committee on Clinical Practice Guidelines. *Circulation* **2024**, *149*, e1239–e1311. [CrossRef] [PubMed]
22. Fananapazir, L.; Epstein, N.D.; Curiel, R.V.; Panza, J.A.; Tripodi, D.; McAreavey, D. Long-term results of dual-chamber (DDD) pacing in obstructive hypertrophic cardiomyopathy: Evidence for progressive symptomatic and hemodynamic improvement and reduction of left ventricular hypertrophy. *Circulation* **1994**, *90*, 2731–2742. [CrossRef] [PubMed]
23. Pak, P.H.; Maughan, W.L.; Baughman, K.L.; Kieval, R.S.; Kass, D.A. Mechanism of acute mechanical benefit from VDD pacing in hypertrophied heart: Similarity of responses in hypertrophic cardiomyopathy and hypertensive heart disease. *Circulation* **1998**, *98*, 242–248. [CrossRef] [PubMed]

Disclaimer/Publisher's Note: The statements, opinions and data contained in all publications are solely those of the individual author(s) and contributor(s) and not of MDPI and/or the editor(s). MDPI and/or the editor(s) disclaim responsibility for any injury to people or property resulting from any ideas, methods, instructions or products referred to in the content.