veterinary sciences

MDPI

Case Report

Foramen Magnum Decompression and Cranioplasty Without Rigid Fixation for Chiari-like Malformation with Atlanto-Occipital Overlapping in an Adult Maltese Dog: A Case Report

Ja-Won Lee [1], Eun-Ji Jung [1], Sang-Woo Kwak [1], Sung-Yeon Moon [1], Gil-Ho Lee [1], Ki-Dong Eom [2], Hwi-Yool Kim [1] and Jung-Moon Kim [1,*]

[1] Department of Veterinary Surgery, College of Veterinary Medicine, Konkuk University, Seoul 05029, Republic of Korea; syrius82@konkuk.ac.kr (J.-W.L.); sahujayu@naver.com (E.-J.J.); moonjjang815@hanmail.net (S.-Y.M.); hykim@konkuk.ac.kr (H.-Y.K.)

[2] Department of Veterinary Medical Imaging, College of Veterinary Medicine, Konkuk University, Seoul 05029, Republic of Korea; eomkd@konkuk.ac.kr

* Correspondence: kimjungm418@gmail.com

Simple Summary

Chiari-like malformation can cause overcrowding at the junction between the skull and cervical spine in dogs, while atlanto-occipital overlapping occurs when the first cervical vertebra is displaced cranially toward the foramen magnum. When these abnormalities occur together, compression of the brainstem and upper cervical spinal cord can result in severe neurological dysfunction. This report describes a 6-year-old Maltese dog with rapidly progressive tetraparesis associated with concurrent Chiari-like malformation and atlanto-occipital overlapping. During surgery, the atlas repositioned caudally without manual reduction immediately after abnormal ligamentous attachments between the atlas and occipital bone were sharply released. Foramen magnum decompression, partial dorsal laminectomy of the atlas, and titanium mesh–polymethylmethacrylate cranioplasty were performed without rigid craniocervical fixation. The dog regained independent ambulation and showed marked neurological improvement through postoperative day 24, but died following acute respiratory distress on day 26; the cause of death was undetermined. Because mechanical stability was not evaluated using standardized dynamic testing and postoperative magnetic resonance imaging was unavailable, this report documents an intraoperative observation and a short-term clinical outcome rather than establishing the efficacy or safety of decompression without rigid fixation.

Check for updates

Academic Editors: Zhijun Zhong and Ryou Tanaka

Received: 30 September 2026
Revised: 17 November 2026
Accepted: 23 November 2026
Published: 26 November 2026

Copyright: © 2026 by the authors. Licensee MDPI, Basel, Switzerland. This article is an open access article distributed under the terms and conditions of the Creative Commons Attribution (CC BY) license.

Abstract

A 6-year-old, 2.03-kg spayed female Maltese dog was referred for rapidly progressive neurological dysfunction that had advanced to non-ambulatory tetraparesis with absent postural reactions and proprioceptive deficits in all four limbs, while nociception remained intact. Magnetic resonance imaging demonstrated Chiari-like malformation with cerebellar herniation, kinking of the medulla oblongata and cranial cervical spinal cord, dorsal compression at C1–C2, mild cervical syringomyelia, and ventriculomegaly. Computed tomography demonstrated cranial displacement of the dorsal arch of the atlas overlapping the foramen magnum, consistent with atlanto-occipital overlapping. During surgery, sharp transection of abnormal ligamentous attachments between the atlas and occipital bone was immediately followed by caudal repositioning of the atlas without manual reduction. Foramen magnum decompression, partial dorsal laminectomy of the cranial one-third of the atlas, excision

of a fibrous compressive band, and titanium mesh–polymethylmethacrylate cranioplasty were performed without rigid craniocervical fixation. Bilateral miosis resolved by postoperative day 1, postural reactions began to return by day 4, and independent ambulation was regained by day 12, with neurological improvement documented through day 24. The dog died on day 26 following peracute respiratory distress of undetermined cause. No standardized dynamic stability assessment or postoperative magnetic resonance imaging was documented. Following ligamentous release, the atlas repositioned caudally without manual reduction, and the dog demonstrated marked short-term neurological improvement. However, the limited follow-up period precluded assessment of the long-term durability of this surgical outcome.

Keywords: Chiari-like malformation; atlanto-occipital overlapping; craniocervical junction; foramen magnum decompression; cranioplasty; dog

1. Introduction

Craniocervical junction abnormalities comprise a heterogeneous group of developmental disorders affecting the occipital bone, atlas, axis, and their associated joints and ligaments, and are increasingly recognized as causes of neurological dysfunction in small-breed dogs [1,2]. These abnormalities include Chiari-like malformation (CM), atlanto-occipital overlapping (AOO), atlantoaxial instability, dorsal compressive lesions at the atlantoaxial junction, and abnormalities of the dens. More than one abnormality may coexist in the same patient, complicating interpretation of diagnostic imaging and selection of treatment [1,2].

CM, also described in dogs as caudal occipital malformation syndrome [3], is characterized by a mismatch between the volume of the caudal cranial fossa and the neural parenchyma it contains, resulting in overcrowding of the cerebellum and brainstem at the foramen magnum and disturbance of cerebrospinal fluid (CSF) movement across the craniocervical junction [3–5]. Altered CSF dynamics are considered central to the development of syringomyelia (SM) [6]. Although CM has been characterized most extensively in Cavalier King Charles Spaniels, it also occurs in other small and toy breeds [1,4,7,8]. Clinical manifestations range from craniocervical pain, phantom scratching, and scoliosis to proprioceptive ataxia and tetraparesis [3,6].

AOO is a craniodorsal malposition of the atlas in which the dorsal arch overlaps the supraoccipital bone or protrudes into the foramen magnum and has been regarded as a canine analogue of basilar invagination in humans [9]. The displaced atlas may compress the caudal medulla oblongata and cranial cervical spinal cord and may further obstruct CSF pathways at the foramen magnum [2,9].

Foramen magnum decompression (FMD), consisting of suboccipital craniectomy with or without dorsal laminectomy of the atlas, is widely used for medically refractory CM [7,10,11]. Titanium mesh and polymethylmethacrylate (PMMA) cranioplasty has been advocated to reduce scar-tissue formation and recompression at the decompression site [12]. In contrast, there is no consensus regarding stabilization for AOO. Craniocervical stabilization has been described in dogs with AOO, particularly when concurrent instability is present [13,14], but the small number of surgically treated canine cases limits comparisons among surgical strategies. The relationship between the intraoperative reducibility of AOO, mechanical stability, and the need for rigid fixation remains uncertain. This report describes an adult Maltese dog with concurrent CM and AOO in which caudal repositioning of the atlas was observed immediately after release of abnormal ligamentous attachments, followed by decompression and cranioplasty without rigid fixation, and documents the short-term neurological outcome and its limitations.

2. Case Presentation

A 6-year-old, 2.03-kg spayed female Maltese dog was referred to the Veterinary Medical Teaching Hospital of Konkuk University for surgical evaluation of rapidly progressive tetraparesis. The available history described recent-onset depression followed by worsening stumbling, ataxia, and knuckling during ambulation; neurological dysfunction had been recognized approximately 12 days before referral and had progressively worsened. Spinal hyperesthesia and bilateral pinpoint miosis had also been documented. The owner reported compulsive scratching directed toward both ears when the dog was lifted; this behavior resolved after pregabalin administration and was interpreted as phantom scratching. No earlier episodes of neurological dysfunction or preceding fall or trauma were documented in the available records. However, the records did not establish whether these possibilities had been specifically excluded during the initial owner interview; consequently, an earlier subtle history or an inciting event cannot be ruled out. At referral, the dog remained in sternal or lateral recumbency and did not attempt to stand. Neurological examination showed non-ambulatory tetraparesis, bilateral pinpoint miosis, absent postural reactions, and proprioceptive deficits in all four limbs. Limb withdrawal was brisk and nociception was intact. The lesion was localized to the caudal brainstem and/or C1–C5 spinal cord segments.

Complete blood count showed marked neutrophilic leukocytosis (white blood cells 25.45 × 10^9/L; reference interval [RI], 5.05–16.76; neutrophils 21.86 × 10^9/L; RI, 2.95–11.64) and mild anemia (hematocrit 34.2%; RI, 37.3–61.7). Serum biochemistry showed increased alanine aminotransferase activity (204 U/L; RI, 10–100) and alkaline phosphatase activity (223 U/L; RI, 23–212). Thoracic radiographs were unremarkable.

Magnetic resonance imaging of the brain and cervical spine revealed an inwardly malformed caudal occipital bone with herniation of the cerebellum into the foramen magnum, consistent with CM, together with kinking of the medulla oblongata and cranial cervical spinal cord, dorsal soft-tissue compression at C1–C2, mild cervical syringomyelia, and ventriculomegaly (Figure 1). Computed tomography (CT) demonstrated cranial displacement of the dorsal arch of the atlas overlapping the foramen magnum, with intrusion of its cranial portion judged to compress the medulla oblongata and cranial cervical spinal cord, consistent with AOO (Figure 2A). These preoperative studies characterized the static anatomical abnormalities; standardized dynamic stress imaging and quantitative measurements under stress were not documented. Because of severe progressive neurological deficits despite medical management, FMD with partial dorsal laminectomy of the atlas was elected.

Methylprednisolone sodium succinate (30 mg/kg IV) was administered preoperatively. Anesthesia was induced with propofol and maintained with isoflurane in oxygen. The dog was positioned in sternal recumbency with the craniocervical junction flexed. A dorsal midline approach exposed the suboccipital bone and dorsal arch of the atlas. The bilateral cervical musculature and periosteal tissues were dissected to expose the dorsal atlas and suboccipital bone. The ligamentous attachments between the dorsal edge of the atlas and margin of the foramen magnum were sharply transected with a No. 11 blade, immediately followed by caudal repositioning of the atlas without manual reduction. Suboccipital craniectomy was performed using a 3-mm high-speed cutting burr and rongeurs. The cranial one-third of the dorsal arch of the atlas was removed, and the laminectomy margins were trimmed. A discrete fibrous band bridging the atlas and foramen magnum dorsal to the neural structures was sharply excised. Durotomy was not performed.

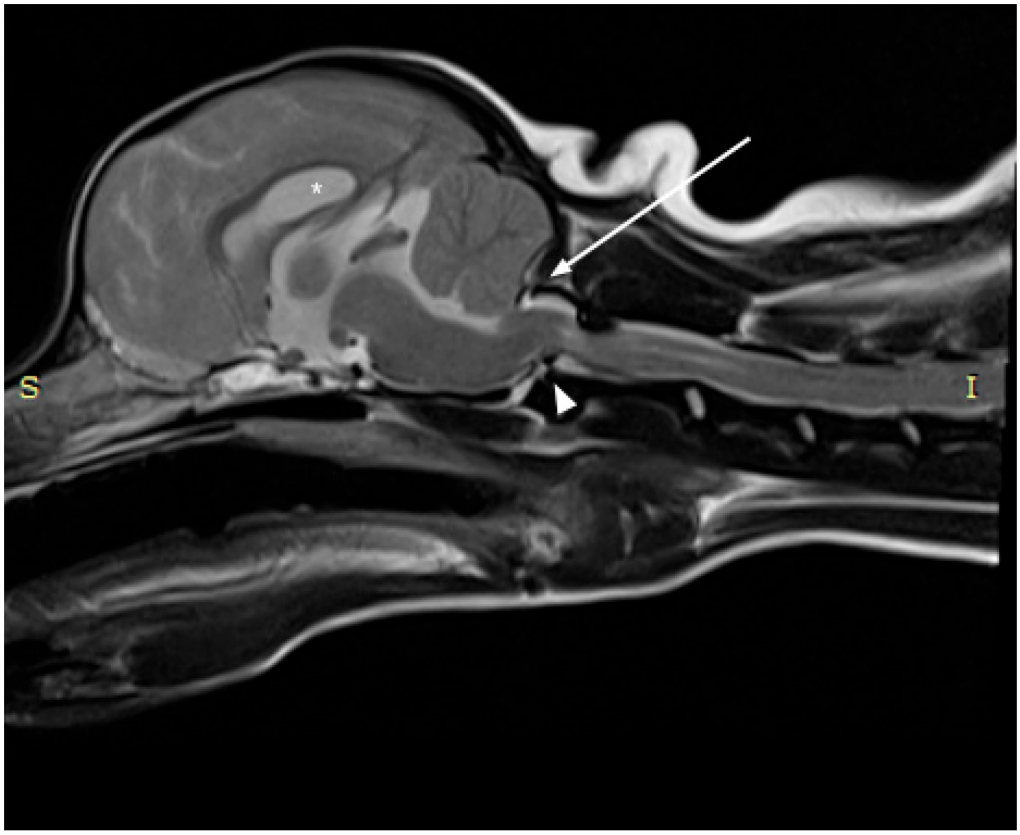

Figure 1. Preoperative midsagittal T2-weighted magnetic resonance image of the brain and cranial cervical region. The caudal occipital bone is malformed and displaced inward, with crowding and herniation of the cerebellum at the foramen magnum (arrow) and kinking of the medulla oblongata and cranial cervical spinal cord (arrowhead). Ventriculomegaly is also present (asterisk).

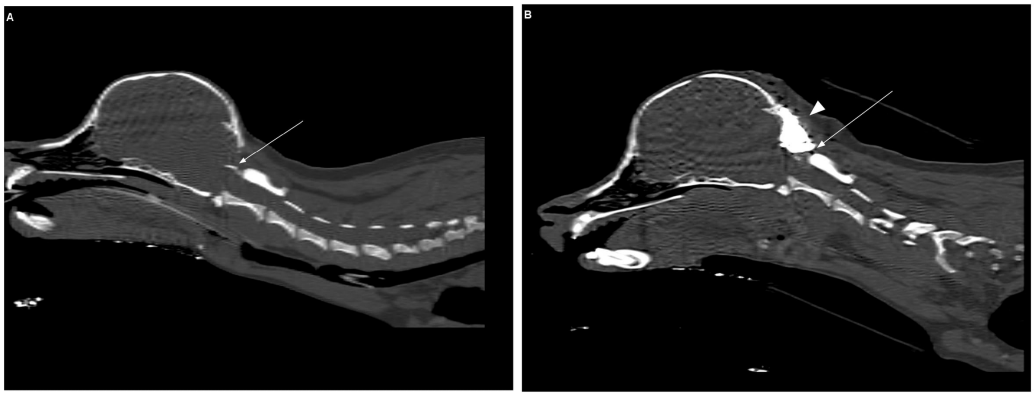

Figure 2. Midsagittal computed tomographic images of the craniocervical junction in a bone window obtained before (**A**) and immediately after (**B**) surgery. (**A**) The dorsal arch of the atlas is displaced cranially, overlapping the supraoccipital bone and protruding into the foramen magnum (arrow). (**B**) The shortened dorsal arch of the atlas is repositioned caudally (arrow), and the suboccipital craniectomy defect is covered by titanium mesh, screws, and polymethylmethacrylate (arrowhead).

A 30 mm × 30 mm titanium mesh was trimmed to cover the suboccipital defect and secured to the skull with five 1.2-mm self-tapping cortical screws. PMMA was applied over the mesh and screw heads to reinforce the construct and discourage scar-tissue adhesion to the decompression site; the surgical field was lavaged with cold saline during polymerization. Rigid craniocervical fixation was not performed. The decision reflected

the observed caudal atlas repositioning after ligamentous release and the decompressive surgical plan, rather than a documented demonstration of normal dynamic stability. No standardized intraoperative manual stress testing was recorded. Immediate postoperative CT documented the extent of bony decompression, implant position, and caudal repositioning of the atlas (Figure 2B); CT did not establish neural decompression or mechanical stability under motion. Intraoperative stages are shown in Figure 3.

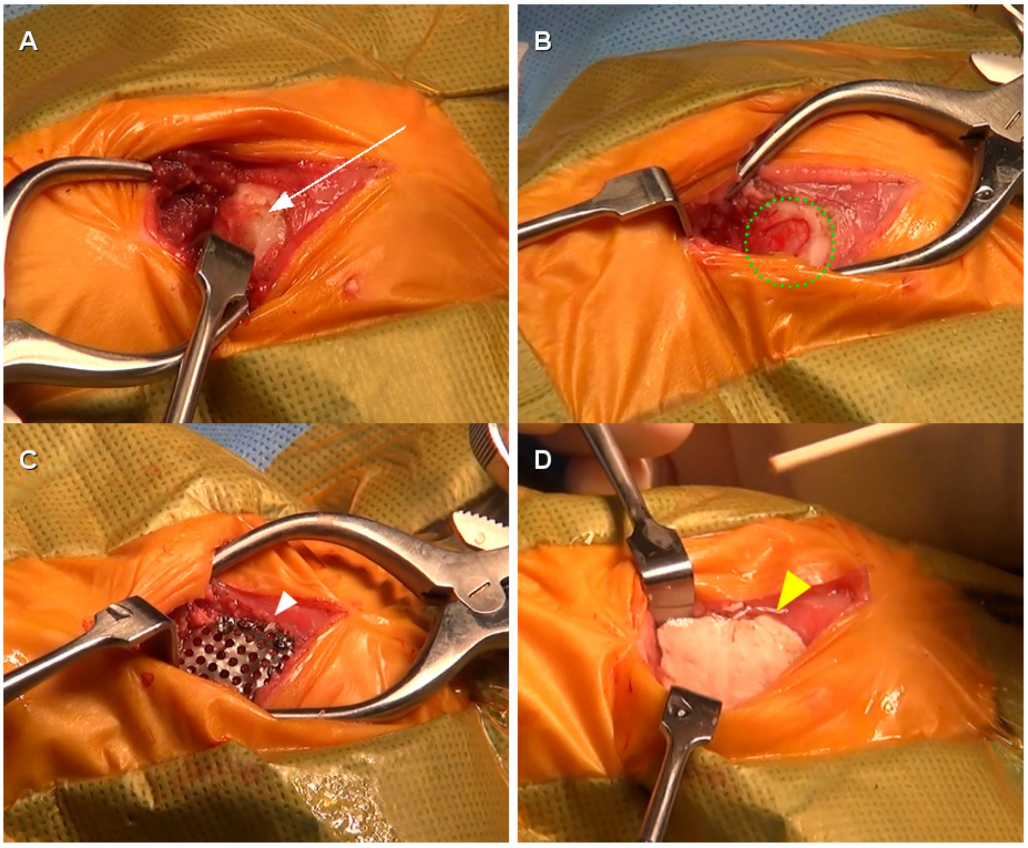

Figure 3. Intraoperative photographs illustrating the sequential stages of foramen magnum decompression and cranioplasty (cranial is to the right). (**A**) Exposure of the suboccipital bone (white arrow) and dorsal arch of the atlas. (**B**) Suboccipital craniectomy and partial dorsal laminectomy of the cranial one-third of the atlas (green dotted outline). (**C**) Placement of the pre-trimmed titanium mesh over the decompression defect and fixation with self-tapping cortical screws (white arrowhead). (**D**) Application of polymethylmethacrylate over the titanium mesh and screws to complete the cranioplasty (yellow arrowhead). The original intraoperative photographs were not digitally altered, enhanced, or retouched. Annotations were added solely to identify the relevant anatomical structures and surgical findings.

Postoperative Course and Outcome

Postoperatively, the dog was maintained in a padded intensive-care cage in sternal recumbency and fitted with a soft cervical brace to limit craniocervical motion. Bilateral miosis had resolved by postoperative day (POD) 1, and pupillary light reflexes were normal. Voluntary motor activity remained minimal during the first two days, but purposeful limb movements were first observed on POD 3. Postural reactions began to return from POD 4, and a transient right head turn and intermittent horizontal nystagmus observed during the early postoperative period resolved within 10 days.

The dog first rose without assistance on POD 7 and was discharged on POD 9 with confinement and continued oral medication. At POD 12, the dog moved independently at home and had regained ambulation on level ground. By POD 15, it could walk outdoors for

more than 10 min with markedly reduced staggering. On POD 19, the owner reported brisk walking and running without falling. At POD 24, the dog remained ambulatory on all four limbs, with further improvement in postural reactions and right-sided deficits (Table 1). Skull radiographs on POD 19 showed no apparent implant-associated abnormality. No overt neurological deterioration suggestive of recurrent compression was documented during this short follow-up, although clinical observation and static radiography could not exclude dynamic instability or recurrent neural compression.

Table 1. Serial postural-reaction findings before surgery and during postoperative follow-up.

Neurologic Examination	Pre-OP	POD 1–3	POD 4	POD 5–23	POD 24
Proprioception—L	0	0	0	1	1
Proprioception—R	0	0	0	0	1
Hopping—L	0	1	2	2	2
Hopping—R	0	0	0	1	1
Hemistanding/hemiwalking—L	0	1	2	2	2
Hemistanding/hemiwalking—R	0	0	0	1	1
Wheelbarrowing—L	0	0	1	2	2
Wheelbarrowing—R	0	0	1	1	2
Extensor postural thrust—L	0	0	1	2	2
Extensor postural thrust—R	0	0	0	1	2

Postural reactions were graded as 0 (absent), 1 (decreased or delayed), or 2 (normal). L, left; R, right; Pre-OP, preoperative; POD, postoperative day.

Intercurrent problems during hospitalization included transient electrolyte abnormalities during furosemide and saline therapy and catheter-associated bacterial cystitis. These were managed medically and were not considered related to the surgical site. On POD 26, after having been clinically stable through the previous evening, the dog developed peracute weakness and open-mouth gasping respiration, progressed to cardiopulmonary arrest, and died despite resuscitation. Thoracic radiographs obtained during the acute deterioration were interpreted as showing a pulmonary interstitial pattern; pulmonary edema (including a possible neurogenic mechanism) and pneumonia were considered among the differential diagnoses. Airway-fluid bacterial culture yielded no growth and viral respiratory PCR testing was negative; these findings did not establish a definitive cause of respiratory failure. No craniocervical CT or MRI was obtained at the time of deterioration, and a necropsy was not performed. Therefore, the cause of death remained undetermined, and a causal relationship with the surgical procedure, implants, or underlying craniocervical disease could neither be established nor excluded.

3. Discussion

The principal observation in this case was that the cranially displaced atlas moved caudally immediately after sharp release of abnormal ligamentous attachments to the occipital bone, without manual traction. Decompression was subsequently completed without rigid craniocervical fixation. This was followed by resolution of bilateral miosis by POD 1, return of postural reactions from POD 4, recovery of independent ambulation by POD 12, and continued neurological improvement through POD 24. The temporal association between ligamentous release and atlas repositioning suggests that soft-tissue tethering may have contributed to the abnormal position in this dog. Nevertheless, this observation does not prove that tethering was the sole cause of AOO; intraoperative craniocervical flexion, changes in tissue tension, and the underlying osseous anatomy may also have influenced atlas position [9,15].

AOO has been regarded as a canine analogue of basilar invagination in humans [9], and treatment recommendations in dogs have partly been extrapolated from that analogy. Published canine surgical descriptions have emphasized stabilization when AOO is associated with craniocervical instability [13,14]. In the present case, static preoperative MRI and CT defined the craniocervical abnormalities, while immediate postoperative CT and POD 19 skull radiographs provided limited information on osseous alignment and the cranioplasty construct. No dynamic stress imaging under anesthesia, quantitative stress-based alignment assessment, or standardized intraoperative manual testing was documented. The observed caudal repositioning of the atlas was not a mechanical stability test. Consequently, atlanto-occipital or atlantoaxial instability was not objectively excluded, and the absence of rigid fixation must not be interpreted as evidence that fixation was unnecessary or that the junction was mechanically stable. Head and neck positioning is known to affect imaging measurements of the canine craniovertebral junction [9,15,16]. A soft cervical brace was used to restrict motion during early healing. Although no apparent implant abnormality was seen on POD 19 radiographs, these static observations and the short follow-up period do not establish the durability or safety of a non-fixation strategy.

A discrete fibrous band bridging the atlas and foramen magnum dorsal to the neural structures was also excised. Dorsal compressive bands at the atlantoaxial junction have been associated with clinical signs and SM in mature Cavalier King Charles Spaniels [2], and dural bands showing evidence of chronic mechanical stress have been described at the craniocervical junction in humans with Chiari type I malformation and syringomyelia [17]. Excision of constrictive tissue was therefore considered part of adequate decompression in this dog. Durotomy was not performed. Suboccipital craniectomy combined with durotomy and dural grafting has been described in dogs [10,18], but in this case bony decompression and removal of the compressive band were followed by rapid neurological improvement. The incremental value of durotomy cannot be determined from a single case.

Cranioplasty with titanium mesh and PMMA was performed because recurrence after FMD alone has been attributed in part to scar-tissue formation and recompression at the decompression site [7,11], and cranioplasty has been proposed to reduce this complication [12]. No implant-associated complication was documented during the available short-term follow-up. Bilateral pinpoint miosis resolved within one day of decompression. The first-order oculosympathetic pathways descend from the hypothalamus through the brainstem and cranial cervical spinal cord; lesions affecting these pathways can cause miosis or Horner-like signs [19,20]. Bilateral involvement of these pathways is anatomically possible at the cervicomedullary junction and does not necessarily require complete transverse spinal cord dysfunction, because sympathetic pupillary pathways and nociceptive pathways are anatomically and functionally distinct. Thus, bilateral miosis can coexist with tetraparesis and preserved nociception, as observed here. Bilateral sympathetic dysfunction has also been described in dogs with cervical myelopathy [20], although this does not establish a compressive mechanism in the present patient. The resolution of miosis after surgery supports a possible association with the craniocervical lesion but does not prove causation. Because full ophthalmic characterization and pharmacological localization were not performed, a central Horner syndrome cannot be confirmed.

Functional gait improved faster than several formal postural-reaction tests. The dog regained independent ambulation by POD 12 and had near-normal functional gait by POD 19, while proprioceptive positioning and right-sided postural reactions remained delayed. This difference supports the use of serial neurological examination in addition to owner-reported gait and general mobility when evaluating postoperative recovery.

The dog died on POD 26 after peracute respiratory distress, including open-mouth gasping respiration, and cardiopulmonary arrest. Neurological function had improved

through POD 24, and POD 19 skull radiographs had shown no apparent abnormality of the cranioplasty construct. However, those earlier findings cannot exclude complications that developed subsequently. Thoracic radiographs obtained during the terminal episode showed a pulmonary interstitial pattern, but this nonspecific finding did not identify the cause of respiratory failure. Airway bacterial culture and respiratory viral PCR testing were negative, although these tests cannot reliably exclude all infectious, inflammatory, or aspiration-related pulmonary disorders.

A central mechanism deserves particular consideration because the caudal medulla oblongata contains essential networks governing respiratory rhythm and upper-airway function. The preoperative cervicomedullary kinking and compression make dysfunction at this level anatomically plausible. Gasping respiration may occur during severe respiratory failure or disordered brainstem respiratory control, but its presence is not specific for a medullary lesion. The comparative human literature describes acute respiratory failure associated with Chiari malformation and respiratory arrest after posterior fossa decompression, including mechanisms involving medullary dysfunction, ischemia or edema, secondary compression, hematoma, or hydrocephalus [21,22]. A canine report of respiratory arrest after caudal fossa surgery also supports the potential vulnerability of this anatomical region, although it involved an immediate postoperative event and is not directly comparable with death on POD 26 [23]. Delayed or recurrent medullary compression, herniation, and postoperative tissue changes are therefore reasonable differential mechanisms in this case, but no terminal neurological examination or advanced craniocervical imaging was available to document them.

Neurogenic pulmonary edema is another biologically plausible mechanism. An acute central neurological insult may trigger intense sympathetic activation, altered pulmonary vascular pressures, and pulmonary fluid accumulation [24,25]. Noncardiogenic pulmonary edema in dogs and cats has heterogeneous causes, including neurogenic events and upper-airway obstruction, and may show interstitial-to-alveolar radiographic opacities [24,26]. Thus, the interstitial pulmonary pattern recorded during this dog's terminal episode is compatible with, but not diagnostic of, pulmonary edema. The same radiographic finding can occur with other pulmonary processes, and the negative airway culture and viral PCR do not establish a neurogenic etiology. Pneumonia, aspiration, upper-airway obstruction, cardiogenic or other noncardiogenic edema, and unrelated acute cardiopulmonary disease cannot be excluded.

A late structural complication also remains possible. Subsequent displacement of the atlas, occult dynamic craniocervical instability, recurrent soft-tissue compression, or an implant-related complication could theoretically affect the cervicomedullary region. The POD 19 radiographs did not show an apparent implant-associated abnormality, but they were static studies obtained seven days before death and did not assess the neural tissues or dynamic joint stability. No CT, MRI, mechanical stability assessment, or postmortem examination was performed during the terminal event. These possibilities must therefore remain unconfirmed differential diagnoses rather than established postoperative complications. The clinical improvement preceding death cannot be used either to establish or to exclude a causal relationship between surgery and the subsequent respiratory arrest.

This report has several important limitations. It concerns one retrospectively documented dog, and the earlier neurological history and possible precipitating events were incompletely documented. Neither standardized dynamic stress imaging nor intraoperative manual testing was available to establish craniocervical stability. Postoperative assessment consisted of CT and radiographs, not MRI. Thus, even though postoperative CT documented bony decompression and caudal atlas position, it could not determine whether cerebellar herniation or medullary kinking had resolved, whether syringomyelia had changed, or

whether CSF flow dynamics were normalized or remained improved over time [7,27]. Short-term clinical recovery should not be taken as objective confirmation of sustained neural decompression. The absence of imaging at the time of terminal respiratory deterioration and of necropsy prevented determination of the cause of death. Accordingly, this case cannot establish the long-term safety, biomechanical stability, or comparative efficacy of decompression without rigid fixation. Further studies require standardized assessment of reducibility and mechanical instability, postoperative MRI, and longer-term neurological and imaging follow-up.

4. Conclusions

In this adult Maltese dog with concurrent CM and AOO, caudal repositioning of the atlas was observed immediately after sharp release of abnormal ligamentous attachments, without manual reduction. Foramen magnum decompression, partial dorsal laminectomy of the atlas, excision of a compressive fibrous band, and titanium mesh–PMMA cranioplasty without rigid craniocervical fixation were followed by marked short-term neurological improvement. However, the observation does not establish that ligamentous release alone caused reduction. Given the absence of standardized stability testing, postoperative MRI, and long-term follow-up, together with the unexplained death on POD 26, this report documents an intraoperative observation and a short-term clinical outcome rather than establishing the efficacy or safety of decompression without rigid fixation. Further cases with objective stability assessment and postoperative neuroimaging are needed before treatment recommendations can be made.

Author Contributions: Conceptualization, J.-W.L., J.-M.K. and H.-Y.K.; investigation, J.-W.L., E.-J.J., S.-W.K., S.-Y.M., G.-H.L., K.-D.E., H.-Y.K. and J.-M.K.; clinical management and surgery, J.-W.L., E.-J.J., S.-W.K., S.-Y.M., G.-H.L., H.-Y.K. and J.-M.K.; diagnostic imaging, K.-D.E.; data curation, J.-W.L. and J.-M.K.; writing—original draft preparation, J.-W.L.; writing—review and editing, all authors; visualization, J.-W.L., K.-D.E. and J.-M.K.; supervision, H.-Y.K. and J.-M.K. All authors have read and agreed to the published version of the manuscript.

Funding: This research received no external funding.

Institutional Review Board Statement: Ethical review and approval were waived because this report describes a single retrospective clinical case managed according to routine diagnostic and therapeutic procedures.

Informed Consent Statement: Written informed consent was obtained from the owner of the dog for publication of this case report and accompanying images.

Data Availability Statement: The original contributions presented in this case report are included in the article. Further inquiries can be directed to the corresponding author.

Acknowledgments: During the preparation of this manuscript, the authors used GPT-6 Astra (OpenAI, San Francisco, CA, USA) and Claude (Claude Fable 5; Anthropic, San Francisco, CA, USA) to assist with manuscript drafting, improving the clarity and readability of the English text, and refining the organization and scientific expression of the Introduction, Case Presentation, Discussion, and Conclusions sections. These tools were not used to generate or modify clinical data, diagnostic images, or study results. All AI-assisted text was critically reviewed and revised by the authors, who independently verified the scientific accuracy, interpretation of the findings, and references. The authors take full responsibility for the accuracy, originality, and integrity of the final manuscript.

Conflicts of Interest: The authors declare no conflicts of interest.

Abbreviations

AOO	atlanto-occipital overlapping
CM	Chiari-like malformation
CSF	cerebrospinal fluid
CT	computed tomography
FMD	foramen magnum decompression
MRI	magnetic resonance imaging
PMMA	polymethylmethacrylate
POD	postoperative day
SM	syringomyelia

References

1. Cerda-Gonzalez, S.; Dewey, C.W. Congenital diseases of the craniocervical junction in the dog. *Vet. Clin. N. Am. Small Anim. Pract.* **2010**, *40*, 121–141. [CrossRef] [PubMed]
2. Cerda-Gonzalez, S.; Olby, N.J.; Griffith, E.H. Dorsal compressive atlantoaxial bands and the craniocervical junction syndrome: Association with clinical signs and syringomyelia in mature Cavalier King Charles Spaniels. *J. Vet. Intern. Med.* **2015**, *29*, 887–892. Erratum in *J. Vet. Intern. Med.* **2020**, *34*, 1357. https://doi.org/10.1111/jvim.15755. [CrossRef] [PubMed] [PubMed Central]
3. Dewey, C.W.; Berg, J.M.; Stefanacci, J.D.; Barone, G.; Marino, D.J. Caudal occipital malformation syndrome in dogs. *Compend. Contin. Educ. Pract. Vet.* **2004**, *26*, 886–895.
4. Cross, H.R.; Cappello, R.; Rusbridge, C. Comparison of cerebral cranium volumes between Cavalier King Charles spaniels with Chiari-like malformation, small breed dogs and Labradors. *J. Small Anim. Pract.* **2009**, *50*, 399–405. [CrossRef] [PubMed]
5. Nishikawa, M.; Sakamoto, H.; Hakuba, A.; Nakanishi, N.; Inoue, Y. Pathogenesis of Chiari malformation: A morphometric study of the posterior cranial fossa. *J. Neurosurg.* **1997**, *86*, 40–47. [CrossRef] [PubMed]
6. Rusbridge, C.; Jeffery, N.D. Pathophysiology and treatment of neuropathic pain associated with syringomyelia. *Vet. J.* **2008**, *175*, 164–172. [CrossRef] [PubMed]
7. Rusbridge, C. Chiari-like malformation with syringomyelia in the Cavalier King Charles spaniel: Long-term outcome after surgical management. *Vet. Surg.* **2007**, *36*, 396–405. [CrossRef] [PubMed]
8. Rusbridge, C.; Knowler, S.P.; Pieterse, L.; McFadyen, A.K. Chiari-like malformation in the Griffon Bruxellois. *J. Small Anim. Pract.* **2009**, *50*, 386–393. [CrossRef] [PubMed]
9. Cerda-Gonzalez, S.; Dewey, C.W.; Scrivani, P.V.; Kline, K.L. Imaging features of atlanto-occipital overlapping in dogs. *Vet. Radiol. Ultrasound.* **2009**, *50*, 264–268. [CrossRef] [PubMed]
10. Vermeersch, K.; Van Ham, L.; Caemaert, J.; Tshamala, M.; Taeymans, O.; Bhatti, S.; Polis, I. Suboccipital craniectomy, dorsal laminectomy of C1, durotomy and dural graft placement as a treatment for syringohydromyelia with cerebellar tonsil herniation in Cavalier King Charles spaniels. *Vet. Surg.* **2004**, *33*, 355–360. [CrossRef] [PubMed]
11. Dewey, C.W.; Berg, J.M.; Barone, G.; Marino, D.J.; Stefanacci, J.D. Foramen magnum decompression for treatment of caudal occipital malformation syndrome in dogs. *J. Am. Vet. Med. Assoc.* **2005**, *227*, 1270–1275. [CrossRef] [PubMed]
12. Dewey, C.W.; Marino, D.J.; Bailey, K.S.; Loughin, C.A.; Barone, G.; Bolognese, P.; Milhorat, T.H.; Poppe, D.J. Foramen magnum decompression with cranioplasty for treatment of caudal occipital malformation syndrome in dogs. *Vet. Surg.* **2007**, *36*, 406–415. [CrossRef] [PubMed]
13. Fujita, A.; Nishimura, R. Surgical stabilization of the atlanto-occipital overlap with atlanto-axial instability in a dog. *Jpn. J. Vet. Res.* **2016**, *64*, 141–145. [PubMed]
14. Dewey, C.W.; Cerda-Gonzalez, S.; Scrivani, P.V. Case report—Surgical stabilization of a craniocervical junction abnormality with atlanto-occipital overlapping in a dog. *Compend. Contin. Educ. Vet.* **2009**, *31*, E1–E6. [PubMed]
15. Planchamp, B.; Forterre, F.; Vidondo, B.; Beugger, A.; Müller, A.; Precht, C. Influence of the head neck position on imaging measurements used to assess the craniovertebral junction in small breed dogs: A cadaveric study. *Vet. Comp. Orthop. Traumatol.* **2021**, *34*, 268–278. [CrossRef] [PubMed]
16. Cerda-Gonzalez, S.; Bibi, K.F.; Gifford, A.T.; Mudrak, E.L.; Scrivani, P.V. Magnetic resonance imaging-based measures of atlas position: Relationship to canine atlantooccipital overlapping, syringomyelia and clinical signs. *Vet. J.* **2016**, *209*, 133–138. [CrossRef] [PubMed]
17. Nakamura, N.; Iwasaki, Y.; Hida, K.; Abe, H.; Fujioka, Y.; Nagashima, K. Dural band pathology in syringomyelia with Chiari type I malformation. *Neuropathology* **2000**, *20*, 38–43. [CrossRef] [PubMed]
18. Cobb, M.A.; Badylak, S.F.; Janas, W.; Simmons-Byrd, A.; Boop, F.A. Porcine small intestinal submucosa as a dural substitute. *Surg. Neurol.* **1999**, *51*, 99–104. [CrossRef] [PubMed]
19. Zwueste, D.M.; Grahn, B.H. A review of Horner's syndrome in small animals. *Can. Vet. J.* **2019**, *60*, 81–88. [PubMed]

20. Murthy, V.D.; Phillips, K.; Knipe, M.; Giuffrida, M.; Li, C.F. Horner syndrome as a physiological biomarker of disease in canine cervical myelopathy. *J. Vet. Intern. Med.* **2023**, *37*, 598–605. [CrossRef]
21. Alvarez, D.; Requena, I.; Arias, M.; Valdés, L.; Pereiro, I.; De la Torre, R. Acute respiratory failure as the first sign of Arnold-Chiari malformation associated with syringomyelia. *Eur. Respir. J.* **1995**, *8*, 661–663. [CrossRef]
22. Atallah, O.; Wireko, A.A.; Chaurasia, B. Respiratory arrest after posterior fossa decompression in patients with Chiari malformations: An overview. *J. Craniovertebr. Junction Spine* **2023**, *14*, 217–220. [CrossRef] [PubMed]
23. Molín, J.; Rentmeister, K.; Matiasek, K. Caudal fossa respiratory epithelial cyst in a dog: Clinical, magnetic resonance imaging, and histopathologic findings. *J. Vet. Intern. Med.* **2014**, *28*, 1336–1340. [CrossRef]
24. Drobatz, K.J.; Saunders, H.M.; Pugh, C.R.; Hendricks, J.C. Noncardiogenic pulmonary edema in dogs and cats: 26 cases (1987–1993). *J. Am. Vet. Med. Assoc.* **1995**, *206*, 1732–1736. [CrossRef]
25. Šedý, J.; Kuneš, J.; Zicha, J. Pathogenetic mechanisms of neurogenic pulmonary edema. *J. Neurotrauma* **2015**, *32*, 1135–1145. [CrossRef] [PubMed]
26. Nemi, J.R.; Hopper, K.; Epstein, S.E. Retrospective evaluation of noncardiogenic pulmonary edema in dogs and cats (2000–2021): 31 cases. *J. Vet. Emerg. Crit. Care* **2023**, *33*, 354–359. [CrossRef] [PubMed]
27. Colverde, A.S.; Nicetto, T.; Falzone, C. Occipital cranioplasty using customized titanium prosthesis yields successful outcome in association with foramen magnum decompression in dogs suffering by Chiari-like malformation. *Am. J. Vet. Res.* **2022**, *83*, 275–282. [CrossRef] [PubMed]

Disclaimer/Publisher's Note: The statements, opinions and data contained in all publications are solely those of the individual author(s) and contributor(s) and not of MDPI and/or the editor(s). MDPI and/or the editor(s) disclaim responsibility for any injury to people or property resulting from any ideas, methods, instructions or products referred to in the content.