

Article

Quantifying the Impact of Uneventful LASIK on the Cornea

Arieke Jadnanansing ¹, Elke O. Kreps ^{1,2} and Ilse Claerhout ^{2,3}, Philippe G. Kestelyn ², Alejandra Consejo ^{4,*}¹ Department of Ophthalmology, Ghent University Hospital, 9000 Ghent, Belgium; arieke.jadnanansing@ugent.be (A.J.); elke.kreps@ugent.be (E.O.K.)² Faculty of Medical Sciences, Ghent University, 9000 Ghent, Belgium; ilse.claerhout@ugent.be (I.C.); philippe.kestelyn@ugent.be (P.G.K.)³ Department of Ophthalmology, Maria Middelaers General Hospital, 9000 Ghent, Belgium⁴ Aragon Institute for Engineering Research (I3A), University of Zaragoza, 50018 Zaragoza, Spain

* Correspondence: alejandra.consejo@unizar.es

Abstract: This study investigates the changes in the optical properties of the cornea after laser in situ keratomileusis (LASIK) based on Scheimpflug light intensity distribution. Retrospective data from patients who had undergone uneventful LASIK surgery were eligible. Scheimpflug images obtained with the Pentacam(6.10r59) HR device prior to the LASIK treatment, 3 months afterwards and (in a subset of patients) 1 year after treatment were exported for analysis of corneal transparency in different depths and regions. Corneal segmentation and statistical modeling of the pixel brightness distribution were performed for each image. The intensity of the pixels corresponding to the central 8 mm of the cornea was statistically modeled using the Weibull function, yielding two derived parameters: the scale parameter (α , representing corneal transparency) and the shape parameter (β , representing corneal tissue homogeneity). Additionally, the same analysis was carried out within the flap area (central 3.5 mm). A total of 90 patients were included. No statistically significant changes were observed in parameter α ($p > 0.05$). Parameter β exhibited significantly lower values at both the 3-month follow-up (in the anterior cornea and stroma, $p < 0.05$) and 1-year follow-up (in all depths, $p < 0.05$). In conclusion, the cornea demonstrated significantly lower tissue homogeneity following uncomplicated LASIK surgery, but overall corneal transparency remained unchanged.

Keywords: LASIK; Scheimpflug images; tissue transparency; corneal tissue; light intensity distribution; refractive surgery

Citation: Jadnanansing, A.; Kreps, E.O.; Claerhout, I.; Kestelyn, P.G.; Kestelyn, P.; Consejo, A. Quantifying the Impact of Uneventful LASIK on the Cornea. *Photonics* **2024**, *11*, 315. <https://doi.org/10.3390/photonics11040315>

Received: 26 February 2024

Revised: 25 March 2024

Accepted: 27 March 2024

Published: 28 March 2024



Copyright: © 2024 by the authors. Licensee MDPI, Basel, Switzerland. This article is an open access article distributed under the terms and conditions of the Creative Commons Attribution (CC BY) license (<https://creativecommons.org/licenses/by/4.0/>).

1. Introduction

Laser in situ keratomileusis (LASIK) is a widely utilized, safe and reliable corneal surgical technique for correcting refractive errors. This technique modifies the corneal shape to achieve the desired therapeutic effect, which can lead to biomechanical changes [1]. Subsequently, the cornea relies on its wound healing response, involving complex cellular interactions, to repair the surgically induced injury and restore normal tissue function, including transparency [2]. Alterations in the corneal microstructure can result in increased light scattering, thereby affecting visual quality and causing side effects such as blurred vision, halos, low contrast sensitivity or visual discomfort [3]. Modern imaging techniques now permit detailed and quantitative assessment of corneal transparency [4,5].

The Scheimpflug-based Pentacam System (Oculus Optikgeräte GmbH, Wetzlar, Germany) provides densitometry maps in its built-in software, representing the mean pixel brightness in a Scheimpflug image on a scale ranging from 0 (maximum transparency) to 100 (no transparency). Compared to older techniques such as photorefractive keratectomy (PRK), LASIK has been shown to result in lower corneal light backscatter [6]. However, studies investigating corneal transparency following LASIK surgery, as measured by conventional densitometry, have produced conflicting results regarding the impact of LASIK on corneal transparency [6–8].

An alternative method for evaluating corneal transparency, which is platform-independent, is the densitometry distribution analysis (DDA). This analysis provides two parameters, α and β , which represent tissue transparency and homogeneity, respectively, offering a more comprehensive assessment compared to conventional corneal densitometry. DDA has demonstrated its utility in evaluating changes in corneal clarity associated with keratoconus [9,10], age-related changes [11] and subclinical changes related to low-level hypoxia caused by scleral and soft contact lens wear [12,13].

The objective of this study was to enhance the understanding of LASIK-induced changes in corneal optical properties by comparing pre- and postoperative DDA values in different regions and depths of LASIK-treated eyes, as well as investigating the correlations between induced changes and treatment parameters.

2. Materials and Methods

2.1. Patients

A retrospective cohort study was conducted at the Department of Ophthalmology, Ghent University Hospital, Belgium. Patients who had undergone uneventful LASIK treatment between July 2010 and November 2014 and had had corneal assessment prior to the LASIK treatment and at the 3-month postoperative follow-up using the same Pentacam HR device were eligible. Uneventful LASIK surgery was defined as LASIK surgery with no intraoperative or postoperative complications that influenced tissue transparency including significant dry eye disease, flap buttonholes, diffuse lamellar keratitis, epithelial ingrowth and central toxic keratitis. Isolated subjective symptoms such as visual aberrations and glare were not considered exclusion criteria. Exclusion criteria comprised missing data, poor image quality at baseline or follow-up and postoperative complications affecting corneal transparency. For a subset of patients, additional follow-up data at 1 year were available. Patients were instructed to refrain from wearing contact lenses for 2 weeks before the assessments. Trained personnel obtained images in the Ophthalmology Outpatient Clinic. If image quality was insufficient (not marked as “OK”), the images were re-taken. All patients included in the study had undergone uncomplicated primary LASIK using the same refractive surgery platform (Allegretto Wavelight). The stromal ablation was performed with the Wavelight Eye-Q excimer laser (Alcon, Fort Worth, TX, USA) with a conventional optical zone of 6.5 mm. The procedures were performed by 2 anterior segment surgeons (IC and PhK). The flap thickness was set at 120 μm and 110 μm using a microkeratome and femtosecond laser, respectively. The femtosecond laser flap creation was performed using the mode-locked, diode-pumped oscillator Femtolaser LDV2 (Ziemer, Port, Switzerland) with a pulse repetition rate greater than 5 MHz and a central wavelength of 1035–1055 nm. Patients received a tapering regimen of steroid eye drops for 1 week and preservative-free artificial tears for 3 months. The study adhered to the principles of the Declaration of Helsinki and was approved by the Ethics Committee of the University Hospital of Ghent (No. BC-08222).

2.2. Data Analysis

In addition to extracting corneal parameters provided by the device's software, Scheimpflug images corresponding to 25 corneal meridians (a fixed size of 500×1080 pixels) were exported without gamma correction or contrast enhancement for further analysis. Each image underwent two steps of processing: corneal segmentation and statistical modeling of the pixel brightness distribution, as described in detail elsewhere [4,13]. In the first step, the anterior and posterior boundaries of the cornea were automatically extracted. After segmentation, a moving region of interest (ROI) was automatically selected for statistical modeling, as described elsewhere [4,13]. The horizontal (lateral) dimension of the moving ROI had an optimized fixed size of 11 pixels [4]. For the vertical (axial) dimension, three different depths were investigated: (1) full corneal thickness, (2) stroma and (3) anterior cornea including the epithelium. Therefore, the vertical dimension of the

ROI varied depending on the analyzed corneal depth. In the case of the full corneal thickness, the number of vertical pixels in the ROI was determined by the corneal thickness of each subject, as previous research has shown that corneal thickness does not affect statistical analysis of corneal Scheimpflug images [10]. When considering the stroma, pixels corresponding to corneal epithelium were excluded, as they provide different statistical information compared to the stroma. In the scenario of the anterior cornea including epithelium, as the epithelial layer is difficult to unequivocally distinguish in Scheimpflug images, a fixed vertical ROI starting from the detected anterior corneal border, approximately corresponding to the anterior 180 μm , was considered [14].

The moving ROI covered approximately the central 8 mm of the cornea. An additional central ROI of 3.5 mm was selected to omit the impact of the flap. To avoid undesired border effects (strong limbal/scleral reflections) and flap-related changes, the peripheral cornea was not included in the analysis [4,13,14]. The intensity of the pixels corresponding to a given ROI was statistically modeled with the Weibull function, a two-parameter distribution function previously used for modeling corneal Scheimpflug images [4,11–15]. The output parameters were estimated using the method of maximum likelihood from the pixel intensities of the selected ROI in each image. As described in previous research [4,14], the Weibull distribution function provides two parameters that describe the light distribution in corneal tissue.

These parameters are the scale parameter (referred to as α in this study), which represents corneal transparency (larger α indicates lower corneal transparency), and the shape parameter (referred to as β in this study), which represents corneal tissue homogeneity (larger β indicates greater tissue homogeneity) [13]. Finally, to construct corneal α and β parameter maps, the data were transformed from Cartesian (X , Y) to polar coordinates (r , θ) and interpolated, and second-order Zernike polynomials were used for smoothing, following previous research [4,12,13].

The statistical analysis was performed using SPSS Statistics 25.0 for Windows (IBM Corp., Armonk, NY, USA). The normality of variables was assessed and not rejected (Shapiro–Wilk test, $p > 0.05$). The paired two-sample t -test was used to compare parameters between the preoperative and 3-month follow-up sessions. Additionally, the independent two-sample t -test was used to compare light distribution metrics based on the surgical technique (femtosecond vs. keratome).

Furthermore, for a subgroup of participants with available data, one-way repeated measures ANOVA was conducted to determine whether light distribution metrics changed over time (preoperatively, at 3-month follow-up and at 1-year follow-up). The Bonferroni correction was applied to control for multiple comparisons in the post hoc tests. The Shapiro–Wilk test, Mauchly’s test of sphericity and Levene’s test indicated that the assumptions of normality, sphericity and homogeneity of variances, respectively, had not been violated. The level of significance was set at 0.05 and the analysis was conducted separately for the right and left eyes, treating them as independent entities.

3. Results

A total of 133 patients who had undergone uneventful LASIK treatment between July 2010 and November 2014 with pre- and postoperative measurements on the same device were identified. Seven (5.3%) patients were subsequently excluded due to different flap or laser settings (5) and ocular comorbidity (2). For the remaining 126 participants, all images were exported for analysis. However, in 36 (28.6%) participants, the data were deemed to be of insufficient or uncertain quality. This was typically due to missing data in certain meridians and the presence of fluorescein in the tear film, which was identified by an over-reflective anterior surface. The mean age of the 90 participants included and analyzed in the study was 31.0 ± 7.1 years (range, 20–55 years). Among them, 58 (64.4%) patients were female. There was no statistically significant difference in refractive error between the right and left eyes ($p > 0.05$; paired t -test). To account for intraindividual correlation, only

one treated eye per patient was included in the analysis. Therefore, results will be presented for all 90 treated left eyes. The baseline refractive and corneal characteristics before the LASIK treatment are presented in Table 1, including data from the left eyes only. Most patients had undergone myopic and/or astigmatic LASIK correction, with only 2 patients (2.2%) with hyperopic correction.

Table 1. Treatment characteristics including pre-treatment (pre-Tx) refractive error, keratometry and pachymetry based on Pentacam analysis. D: diopter; K1F: flat meridian of the anterior corneal surface; K2F: steep meridian of the anterior corneal surface; RSB: residual stromal bed. Data shown as mean \pm standard deviation [range].

Treatment Characteristic	Value
Refractive error Pre-Tx	
Sphere (D)	-3.6 ± 2.3 [−9.0, 5.2]
Cylinder (D)	0.6 ± 1 [−5.0, 0.0]
Keratometry Pre-Tx	
K1F (D)	43.1 ± 1.4 [40.4, 46.7]
K2F (D)	44.1 ± 1.3 [41, 47.6]
Pachymetry Pre-Tx	
Pachy apex (μm)	571 ± 35 [502, 687]
Pachy min (μm)	569 ± 34 [497, 686]
Ablated tissue (μm)	65 ± 24 [23, 118]
RSB (μm)	394 ± 37 [312, 472]

The results of the light intensity distribution metrics, comparing pre- and postoperative values, are presented in Table 2 (results for left eyes). Additionally, graphical representations of the results can be found in Figures 1 and 2. There was no statistically significant difference observed in any of the light distribution parameters between the right and left eyes (all $p > 0.05$). When comparing the femtosecond ($n = 66$) with the keratome ($n = 24$) subgroup, no statistically significant difference was found in any of the analyzed depths for both parameters α and β .

Table 2. Light intensity distribution parameters (α and β) for the full cohort of subjects ($n = 90$) before and 3 months after LASIK for different corneal depths and corneal regions. Paired t -test was performed.

	Area	α			β		
		Pre-op	3-Month FU	p -Value	Pre-op	3-Month FU	p -Value
Full cornea	3.5 mm	31 ± 4 [24, 43]	32 ± 6 [23, 67]	0.08	3.8 ± 0.5 [2.9, 5.2]	3.8 ± 0.6 [2.5, 5.6]	0.72
	8 mm	35 ± 6 [28, 44]	35 ± 6 [25, 45]	0.32	3.8 ± 0.3 [2.9, 4.9]	3.7 ± 0.5 [2.4, 5.3]	0.13
Anterior cornea (including epithelium)	3.5 mm	39 ± 7 [21, 51]	39 ± 7 [22, 65]	0.015 *	4.9 ± 1.4 [3.4, 11.6]	4.5 ± 0.9 [3.2, 8.1]	<0.001 *
	8 mm	40 ± 6 [21, 53]	41 ± 7 [23, 53]	0.15	4.7 ± 1.0 [3.3, 8.3]	4.4 ± 0.8 [3.0, 7.7]	0.004 *
Stroma	3.5 mm	26 ± 5 [20, 38]	26 ± 5 [19, 54]	0.57	13.3 ± 1.4 [9.0, 15.8]	12.9 ± 1.9 [6.3, 16.2]	0.08
	8 mm	29 ± 3 [23, 44]	28 ± 4 [21, 37]	0.21	11.9 ± 1.3 [7.8, 13.9]	11.4 ± 1.5 [6.2, 14.0]	0.03 *

* indicates statistical significance.

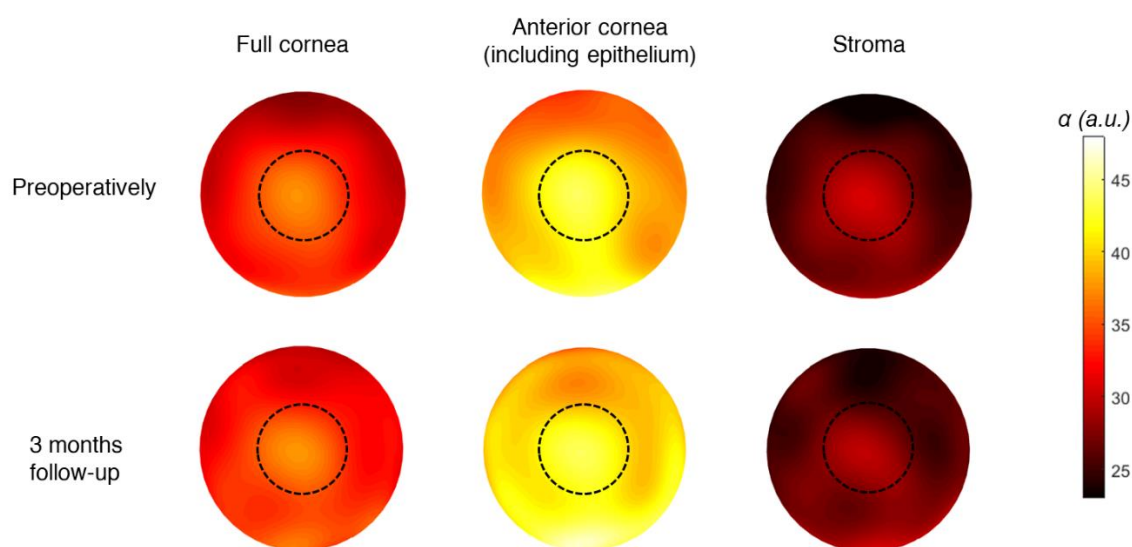


Figure 1. The mean distribution of α (tissue transparency) in the 8 mm central cornea of the total cohort of participants ($n = 90$) before and 3-month after LASIK, for different corneal depths. The dashed circles represent the 3.5 mm central cornea. The color bar (α) is expressed in arbitrary units.

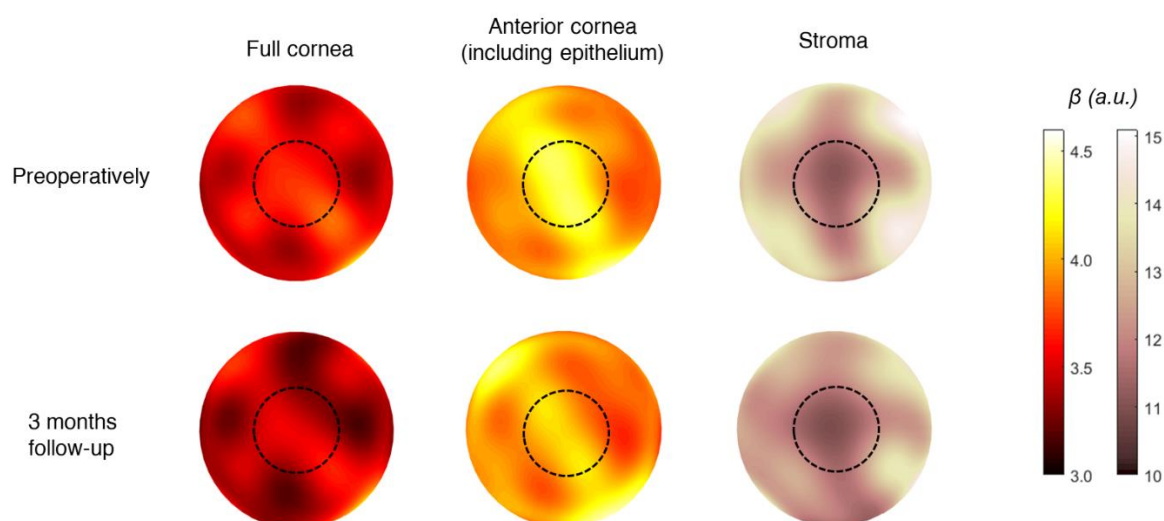


Figure 2. The mean distribution of β (tissue homogeneity) in the 8 mm central cornea of the total cohort of participants ($n = 90$) before and 3-month after LASIK, for different corneal depths. The dashed circles represent the 3.5 mm central cornea. The color bars (β) are expressed in arbitrary units.

The correlation between pre- and postoperative light distribution metrics and various parameters, including age, central corneal thickness (CCT), spherical equivalent (SE), ablation thickness (AT) and residual stromal bed (RSB), was also examined. The results are shown in Table 3. A weak correlation was observed for age, which reached statistical significance, in contrast with CCT, SE, AT and RSB.

Table 3. Pearson Correlation between light intensity distribution parameters (α and β) and different biometrical parameters for the full cohort of subjects ($n = 90$) before, 3-month after LASIK and the difference between sessions. Results are shown for the different corneal depths under analysis. The corresponding p -value is shown in parentheses. AT = ablation thickness, CCT = central corneal thickness, RSB = residual stromal bed, SE = spherical equivalent.

		α			β		
		Pre-op ($n = 90$)	3-Month FU ($n = 90$)	Difference Pre-op/3M FU ($n = 90$)	Pre-op ($n = 90$)	3-Month FU ($n = 90$)	Difference Pre-op/3M FU ($n = 90$)
Full cornea	Age	0.22 (0.03) *	0.22 (0.03) *	0.20 (0.03) *	0.18 (0.04) *	0.18 (0.04) *	0.18 (0.04) *
	CCT	0.05 (0.30)	0.05 (0.30)	0.12 (0.12)	0.08 (0.23)	0.12 (0.12)	0.04 (0.34)
	SE	0.08 (0.23)	0.08 (0.23)	0.08 (0.23)	0.06 (0.27)	0.12 (0.12)	0.06 (0.27)
	AT	0.13 (0.10)	0.05 (0.30)	0.02 (0.40)	0.02 (0.42)	0.05 (0.33)	0.02 (0.40)
	RSB	0.08 (0.22)	<0.01 (0.50)	0.08 (0.22)	0.09 (0.19)	<0.01 (0.50)	0.06 (0.29)
Anterior cornea (including epithelium)	Age	0.21 (0.02) *	0.18 (0.04) *	0.18 (0.04) *	0.18 (0.04) *	0.18 (0.04) *	0.18 (0.04) *
	CCT	0.05 (0.30)	0.04 (0.35)	0.12 (0.12)	0.16 (0.05)	0.03 (0.36)	0.12 (0.12)
	SE	0.05 (0.31)	0.02 (0.41)	0.01 (0.45)	0.13 (0.11)	0.08 (0.23)	0.03 (0.36)
	AT	0.16 (0.06)	0.07 (0.26)	0.17 (0.06)	0.02 (0.43)	−0.14 (0.09)	0.17 (0.10)
	RSB	0.15 (0.07)	0.05 (0.29)	0.06 (0.28)	<0.01 (0.50)	0.07 (0.25)	0.05 (0.32)
Stroma	Age	0.20 (0.03) *	0.25 (0.01) *	0.19 (0.03) *	0.21 (0.02) *	0.18 (0.04) *	0.18 (0.04) *
	CCT	0.04 (0.35)	0.08 (0.23)	0.16 (0.05)	0.08 (0.23)	0.04 (0.35)	0.12 (0.12)
	SE	0.02 (0.41)	0.01 (0.45)	0.03 (0.36)	0.08 (0.23)	0.01 (0.45)	0.13 (0.11)
	AT	0.15 (0.08)	0.03 (0.38)	0.07 (0.24)	0.14 (0.10)	0.06 (0.28)	0.14 (0.09)
	RSB	0.06 (0.27)	0.01 (0.18)	0.14 (0.09)	0.10 (0.17)	0.03 (0.38)	0.06 (0.28)

* indicates statistical significance.

Table 4 represents the results for the subgroup with 3-month and 1-year follow-up ($n = 22$). No statistically significant changes were seen in parameter α . However, parameter β showed significantly lower values at both the 3-month and 1-year follow-up time points. Post hoc analysis for parameter β confirmed the significant findings at both follow-up time points (Table 5).

Table 4. Light intensity distribution parameters (α and β) for a subgroup of subjects ($n = 22$) before, 3-month and 1 year after LASIK for different corneal depths and corneal regions. ANOVA one-way repeated measurements were performed.

Area		Pre-op	3-Month FU	1-Year FU	F-Stats	p -Value
Parameter α						
Full cornea	3.5 mm	31 ± 4 [24, 40]	33 ± 7 [25, 56]	31 ± 7 [22, 47]	F(2,42) = 0.73	0.49
	8 mm	34 ± 5 [28, 44]	36 ± 7 [29, 61]	32 ± 5 [25, 49]	F(2,42) = 2.61	0.08
Anterior cornea (including epithelium)	3.5 mm	36 ± 6 [25, 47]	40 ± 9 [28, 63]	36 ± 7 [26, 58]	F(2,42) = 1.89	0.056
	8 mm	40 ± 6 [29, 54]	43 ± 9 [34, 65]	38 ± 7 [27, 63]	F(2,42) = 2.13	0.13
Stroma	3.5 mm	26 ± 4 [20, 34]	27 ± 6 [19, 47]	27 ± 7 [19, 44]	F(2,42) = 0.41	0.66
	8 mm	28 ± 4 [24, 37]	29 ± 6 [23, 49]	26 ± 4 [22, 41]	F(2,42) = 1.63	0.20

Parameter β						
Full cornea	3.5 mm	3.8 ± 0.4 [3.0, 4.7]	3.7 ± 0.6 [2.5, 5.6]	3.0 ± 0.6 [1.7, 4.6]	$F(2,42) = 12.3$	<0.001 *
	8 mm	3.8 ± 0.4 [3.3, 4.8]	3.6 ± 0.6 [2.4, 5.3]	3.2 ± 0.4 [2.5, 4.4]	$F(2,42) = 10.84$	<0.001 *
Anterior cornea (including epithelium)	3.5 mm	4.9 ± 1.0 [3.5, 8.0]	4.4 ± 0.8 [3.2, 6.2]	4.3 ± 0.9 [3.3, 6.9]	$F(2,42) = 2.7$	0.07
	8 mm	4.6 ± 0.7 [3.5, 6.1]	4.3 ± 0.6 [3.2, 5.3]	4.2 ± 0.5 [3.4, 5.4]	$F(2,42) = 4.82$	0.028 *
Stroma	3.5 mm	13.4 ± 1.5 [9.6, 15.3]	12.7 ± 2.2 [6.3, 15.2]	10.2 ± 2.5 [4.3, 14.7]	$F(2,42) = 13.9$	<0.001 *
	8 mm	12 ± 1.5 [8.9, 13.9]	11.4 ± 2.0 [6.3, 13.4]	10.2 ± 1.6 [4.7, 12.4]	$F(2,42) = 5.94$	0.004 *

* indicates statistical significance.

Table 5. Post hoc test (Bonferroni) for parameter β corresponding to the ANOVA test presented in Table 4. FU: follow-up.

		Preop vs. 3-Month FU (n = 22)	Preop vs. 1-Year FU (n = 22)	3-month FU vs. 1-Year FU (n = 22)
3.5 mm	Full cornea	0.94	<0.001 *	0.001 *
	Anterior cornea (including epithelium)	1.00	0.09	0.24
	Stroma	0.92	<0.001 *	0.001 *
8 mm	Full cornea	0.218	<0.001 *	0.020 *
	Anterior cornea (including epithelium)	0.036 *	0.024 *	0.64
	Stroma	0.040 *	0.003 *	0.101

* indicates statistical significance.

4. Discussion

The present study focuses on the changes in corneal reflectivity associated with routine, uncomplicated LASIK surgery. Using Scheimpflug-based DDA analysis, two parameters, α (corneal transparency) and β (corneal homogeneity), were generated. Following routine LASIK surgery, a significant decrease in optical homogeneity (lower β values) was observed in the corneal tissue. The reduced β values indicate increased variability in tissue reflectivity within the analyzed tissue, providing information on the optical characteristics beyond the net value of backscattered light. The study specifically examined both the central 3.5 mm and 8 mm of the cornea to exclude flap-induced changes in corneal reflectivity. Previous investigations utilizing ex vivo and in vivo confocal microscopy have identified several changes in corneas after LASIK, including focal areas of thickened epithelium, a variably thick hypocellular interface stromal scar and variably reflective cellular structures [16–18]. Some of these changes, such as the morphologies of regenerated nerve fibers, do not fully return to their normal preoperative levels [19]. Research has also demonstrated that keratocyte densities in the stromal flap and anterior retroablation layer decrease for up to 5 years following LASIK [20,21]. The regional changes in corneal microstructure resulting from postoperative wound repair processes may contribute to the decreased corneal homogeneity observed after LASIK. Wound repair following LASIK shows considerable biological diversity, even in contralateral eyes of the same patient [22]. Following initial apoptosis of the stromal keratocytes, proliferation and migration of the remaining keratocytes ensues, resulting in activated keratocytes and myofibroblasts. These cells play a comprehensive role in collagen and extracellular matrix remodeling

[22]. The observed changes in tissue homogeneity may reflect this stromal remodeling anterior and posterior to the lamellar interface.

The study further observed that corneal homogeneity (β parameter) remains lower after 1 year compared to the status at 3 months, suggesting that microstructural changes in the cornea persist beyond the temporary increase in light backscatter. One could speculate that these microstructural changes may influence a cornea's susceptibility to develop postoperative corneal ectasia. A follow-up study, in which the corneal α and β parameters are investigated in patients who developed post-LASIK ectasia, would be of particular interest to test this hypothesis. No correlations were found between the observed changes in the β parameter and other corneal or treatment parameters. Additionally, changes in tissue homogeneity were independent of the flap creation method (mechanical microkeratome or femtosecond laser).

On the other hand, the α parameter, which reflects mean backward light scattering, remained unchanged at both the 3-month and 1-year post-LASIK time points. A correlation between the α parameter and corneal densitometry readings has previously been demonstrated [11]. Most studies investigating corneal densitometry post-LASIK did not find significant changes beyond the early postoperative period, although Wei et al. did observe a decrease in corneal densitometry in certain regions and depths 6 months after LASIK [6,7,23,24]. Whether decreased tissue homogeneity combined with a lack of changes in corneal transparency, as found in this study, could affect visual performance following LASIK surgery requires further research. The decrease in keratocyte density following LASIK surgery has not been found to elicit changes in vision in previous research [25]. Conceptually, the overall reduced tissue homogeneity may contribute to higher-order aberrations that may degrade quality of vision; however, this hypothesis warrants further exploration.

Several limitations of the study should be acknowledged. Optical techniques such as DDA or traditional corneal densitometry by Oculus Pentacam utilize light reflectivity as a measure to differentiate tissue, which does not provide accurate discrimination of tissue components compared to techniques like light or electron microscopy. Therefore, the exact histological correlation of the DDA findings remains speculative. Future studies should ideally incorporate multiple imaging techniques to further elucidate the significance of these findings. The retrospective nature of the study limited the availability of images to the 3-month follow-up time point, with only a subset having a 1-year follow-up. A prospective study with more frequent and standardized follow-up time points would be beneficial to investigate the progression of the observed changes. Additionally, our study focused only on uncomplicated LASIK surgery, to document the changes induced by uneventful surgery itself, and therefore did not include cases with postoperative complications. A follow-up study in patients who developed postoperative complications, both biomechanical (e.g., post-LASIK ectasia) and visual problems (e.g., glare, higher-order aberrations) would be of particular interest to elucidate whether these eyes had different pre- and/or postoperative values in tissue homogeneity. It should also be noted that while patients were instructed to refrain from wearing contact lenses prior to their assessments, compliance was self-reported and not objectively verified, representing a limitation of the study. However, it is generally observed that patients tend to adhere to pre-surgical instructions to avoid potential complications. Regarding the influence of age, it is acknowledged that age can be a confounding factor in corneal tissue readings [5,11]. Nevertheless, in our study, where each eye serves as its own control over time, the effects of age should be mitigated given that all statistical analyses performed are paired. This design minimizes the confounding impact of age on the observed changes in corneal tissue following LASIK surgery. Additionally, as indicated in the Methodology, our analysis was intentionally restricted to the central 8 mm of the cornea to avoid undesired border effects such as strong limbal/scleral reflections and flap-related changes; consequently, the peripheral cornea was not included in the analysis in agreement with the previous literature

[4,13,14]. This decision was informed by the technical limitations of current imaging techniques and the desire to maintain consistency and reliability in our measurements. Acknowledging this, we suggest that future research should aim to develop and utilize imaging techniques capable of accurately capturing and analyzing the peripheral cornea without the confounding effects that currently limit our analysis. Advancements in this area could provide a more comprehensive understanding of corneal changes post-surgery.

5. Conclusions

In conclusion, based on the findings of this study using light reflectivity, it was observed that 3 months after LASIK surgery, the overall level of backscattered light (tissue transparency) has been restored, while the tissue homogeneity had not. This impact on tissue homogeneity remains significant at 1 year after LASIK.

Author Contributions: Conceptualization, E.O.K.; methodology, E.O.K. and A.C.; software, A.C.; validation, E.O.K. and A.C.; formal analysis, A.C.; investigation, A.J. and E.O.K.; resources, I.C. and P.G.K.; data curation, A.J.; writing—original draft preparation, A.J.; writing—review and editing, E.O.K., A.C. and I.C.; visualization, A.C.; supervision, E.O.K.; project administration, E.O.K. and A.C. All authors have read and agreed to the published version of the manuscript.

Funding: This research received no external funding.

Institutional Review Board Statement: The study adhered to the principles of the Declaration of Helsinki and was approved by the Ethics Committee of the University Hospital of Ghent (No. BC-08222). Date of approval: 3 November 2020.

Informed Consent Statement: Informed consent was waived as this study did not involve the use of personal or identifiable information. The research relied on comparing Scheimpflug images captured before and after LASIK surgery. The images, depicting cross-sections of the cornea, were obtained by trained nurses using the Pentacam device, as detailed earlier. Notably, the patient's identity is completely unrecognizable in these images. All images were stored within the Pentacam device at the outpatient clinic. Prior to the start of the study, the images were searched for, and all data were thoroughly anonymized using the Pentacam software. Only the link between the pre-LASIK and post-LASIK images was retained. The data relating to the laser procedure itself, such as the number of diopters corrected, the method (keratome versus femtosecond) and the size of the treated area, along with the Pentacam images, constituted the only sources of information. No additional clinical or demographic data were used. No personal information was available to the investigators during the entire study. Furthermore, the study population consisted of patients who had undergone treatment in the past (2010–2014) by Prof. Ilse Claerhout (currently working at Maria Middeles) and Prof. Philippe Kesteley (currently retired). Follow-up assessments typically occurred between 3 months and 1 year post-treatment. Consequently, these patients were no longer in follow-up at the ophthalmology department, University Hospital of Ghent.

Data Availability Statement: The data underlying the results presented in this paper are not publicly available at this time but may be obtained from the authors upon reasonable request.

Acknowledgments: A.C. was supported by Cátedra SAMCA de Desarrollo Tecnológico de Aragón, Universidad de Zaragoza (III Premio a la Innovación Multidisciplinar).

Conflicts of Interest: The authors declare no conflicts of interest.

References

1. Bao, F.; Lopes, B.T.; Zheng, X.; Ji, Y.; Wang, J.; Elsheikh, A. Corneal Biomechanics Losses Caused by Refractive Surgery. *Curr. Eye Res.* **2023**, *48*, 137–143. <https://doi.org/10.1080/02713683.2022.2103569>.
2. Netto, M.V.; Mohan, R.R.; Ambrósio, R.J.; Hutcheon, A.E.K.; Zieske, J.D.; Wilson, S.E. Wound Healing in the Cornea: A Review of Refractive Surgery Complications and New Prospects for Therapy. *Cornea* **2005**, *24*, 509–522. <https://doi.org/10.1097/01.icc.0000151544.23360.17>.
3. Boulze-Pankert, M.; Driel, R.; Hoffart, L. Corneal Scheimpflug Densitometry Following Photorefractive Keratectomy in Myopic Eyes. *J. Refract. Surg.* **2016**, *32*, 788–791. <https://doi.org/10.3928/1081597X-20160720-02>.

4. Consejo, A.; Jiménez-García, M.; Issarti, I.; Rozema, J.J. Detection of Subclinical Keratoconus with a Validated Alternative Method to Corneal Densitometry. *Transl. Vis. Sci. Technol.* **2021**, *10*, 32. <https://doi.org/10.1167/tvst.10.9.32>.
5. Dhuhbhghail, S.N.; Rozema, J.J.; Jongenelen, S.; Hidalgo, I.R.; Zakaria, N.; Tassignon, M.J. Normative Values for Corneal Densitometry Analysis by Scheimpflug Optical Assessment. *Investig. Ophthalmol. Vis. Sci.* **2013**, *55*, 162–168. <https://doi.org/10.1167/iovs.13-13236>.
6. Savini, G.; Huang, J.; Lombardo, M.; Serrao, S.; Schiano-Lomoriello, D.; Venanzio, S.; Ducoli, P. Objective Monitoring of Corneal Backward Light Scattering After Femtosecond Laser-Assisted LASIK. *J. Refract. Surg.* **2016**, *32*, 20–25. <https://doi.org/10.3928/1081597X-20151207-08>.
7. Fares, U.; Otri, A.M.; Al-Aqaba, M.A.; Faraj, L.; Dua, H.S. Wavefront-Optimized Excimer Laser in Situ Keratomileusis for Myopia and Myopic Astigmatism: Refractive Outcomes and Corneal Densitometry. *J. Cataract Refract. Surg.* **2012**, *38*, 2131–2138. <https://doi.org/10.1016/j.jcrs.2012.07.041>.
8. Poyales, F.; Garzón, N.; Mendicute, J.; Illarramendi, I.; Caro, P.; Jáñez, O.; Argüeso, F.; López, A. Corneal Densitometry after Photorefractive Keratectomy, Laser-Assisted in Situ Keratomileusis, and Small-Incision Lenticule Extraction. *Eye* **2017**, *31*, 1647–1654. <https://doi.org/10.1038/eye.2017.107>.
9. Consejo, A.; Gławdecka, K.; Karnowski, K.; Solariski, J.; Rozema, J.J.; Wojtkowski, M.; Iskander, D.R. Corneal Properties of Keratoconus Based on Scheimpflug Light Intensity Distribution. *Investig. Ophthalmol. Vis. Sci.* **2019**, *60*, 3197–3203. <https://doi.org/10.1167/iovs.19-26963>.
10. Consejo, A.; Solariski, J.; Karnowski, K.; Rozema, J.J.; Wojtkowski, M.; Iskander, D.R. Keratoconus Detection Based on a Single Scheimpflug Image. *Transl. Vis. Sci. Technol.* **2020**, *9*, 36. <https://doi.org/10.1167/tvst.9.7.36>.
11. Consejo, A.; Jiménez-García, M.; Rozema, J.J. Age-Related Corneal Transparency Changes Evaluated With an Alternative Method to Corneal Densitometry. *Cornea* **2021**, *40*, 215–222. <https://doi.org/10.1097/ICO.0000000000002511>.
12. Consejo, A.; Trillo-Moreno, I.; Remon, L. Corneal Tissue Changes Following Short-Term Soft Contact Lens Wear of Different Materials. *Ophthalmic Physiol. Opt. J. Br. Coll. Ophthalmic Opt.* **2023**, *43*, 35–45. <https://doi.org/10.1111/opo.13067>.
13. Consejo, A.; Alonso-Caneiro, D.; Wojtkowski, M.; Vincent, S.J. Corneal Tissue Properties Following Scleral Lens Wear Using Scheimpflug Imaging. *Ophthalmic Physiol. Opt. J. Br. Coll. Ophthalmic Opt.* **2020**, *40*, 595–606. <https://doi.org/10.1111/opo.12710>.
14. Tack, M.; Kreps, E.O.; De Zaeytijd, J.; Consejo, A. Scheimpflug-Based Analysis of the Reflectivity of the Cornea in Marfan Syndrome. *Transl. Vis. Sci. Technol.* **2021**, *10*, 34. <https://doi.org/10.1167/tvst.10.9.34>.
15. Miazdzyk, M.; Consejo, A.; Iskander, D.R. Assessing and Compensating for the Confounding Factors in Scheimpflug-Based Corneal Densitometry. *Biomed. Opt. Express* **2022**, *13*, 6258–6272. <https://doi.org/10.1364/BOE.473534>.
16. Pisella, P.J.; Auzeir, O.; Bokobza, Y.; Debbasch, C.; Baudouin, C. Evaluation of Corneal Stromal Changes in Vivo after Laser in Situ Keratomileusis with Confocal Microscopy. *Ophthalmology* **2001**, *108*, 1744–1750. [https://doi.org/10.1016/s0161-6420\(01\)00771-0](https://doi.org/10.1016/s0161-6420(01)00771-0).
17. Latvala, T.; Linna, T.; Tervo, T. Corneal Nerve Recovery after Photorefractive Keratectomy and Laser in Situ Keratomileusis. *Int. Ophthalmol. Clin.* **1996**, *36*, 21–27. <https://doi.org/10.1097/00004397-199603640-00005>.
18. Dawson, D.G.; Holley, G.P.; Geroski, D.H.; Waring, G.O., 3rd; Grossniklaus, H.E.; Edelhauser, H.F. Ex Vivo Confocal Microscopy of Human LASIK Corneas with Histologic and Ultrastructural Correlation. *Ophthalmology* **2005**, *112*, 634–644. <https://doi.org/10.1016/j.ophtha.2004.10.040>.
19. Vesaluoma, M.; Pérez-Santonja, J.; Petroll, W.M.; Linna, T.; Alió, J.; Tervo, T. Corneal Stromal Changes Induced by Myopic LASIK. *Investig. Ophthalmol. Vis. Sci.* **2000**, *41*, 369–376.
20. Erie, J.C.; Nau, C.B.; McLaren, J.W.; Hodge, D.O.; Bourne, W.M. Long-Term Keratocyte Deficits in the Corneal Stroma after LASIK. *Ophthalmology* **2004**, *111*, 1356–1361. <https://doi.org/10.1016/j.ophtha.2003.10.027>.
21. Cañadas, P.; de Benito-Llopis, L.; Hernández-Verdejo, J.L.; Teus, M.A. Comparison of Keratocyte Density after Femtosecond Laser vs Mechanical Microkeratome from 3 Months up to 5 Years after LASIK. *Graefes Arch. Clin. Exp. Ophthalmol.* **2013**, *251*, 2171–2179. <https://doi.org/10.1007/s00417-013-2357-9>.
22. Dupps, W.J., Jr.; Wilson, S.E. Biomechanics and wound healing in the cornea. *Exp. Eye Res.* **2006**, *83*, 709–720. <https://doi.org/10.1016/j.exer.2006.03.015>.
23. Shajari, M.; Wanner, E.; Rusev, V.; Mir Mohi Sefat, S.; Mayer, W.J.; Kohnen, T.; Priglinger, S.; Kook, D. Corneal Densitometry after Femtosecond Laser-Assisted In Situ Keratomileusis (Fs-LASIK) and Small Incision Lenticule Extraction (SMILE). *Curr. Eye Res.* **2018**, *43*, 605–610. <https://doi.org/10.1080/02713683.2018.1431288>.

24. Wei, R.; Li, M.; Yang, W.; Shen, Y.; Zhao, Y.; Fu, D.; Shang, J.; Zhang, J.; Choi, J.; Zhou, X. Corneal Densitometry After Small Incision Lenticule Extraction (SMILE) and Femtosecond Laser-Assisted LASIK (FS-LASIK): 5-Year Prospective Comparative Study. *Front. Med.* **2020**, *7*, 521078. <https://doi.org/10.3389/fmed.2020.521078>.
25. McLaren, J.W.; Bourne, W.M.; Maguire, L.J.; Patel, S.V. Changes in keratocyte density and visual function five years after laser in situ keratomileusis: Femtosecond laser versus mechanical microkeratome. *Am. J. Ophthalmol.* **2015**, *160*, 163–170. <https://doi.org/10.1016/j.ajo.2015.04.006>.

Disclaimer/Publisher's Note: The statements, opinions and data contained in all publications are solely those of the individual author(s) and contributor(s) and not of MDPI and/or the editor(s). MDPI and/or the editor(s) disclaim responsibility for any injury to people or property resulting from any ideas, methods, instructions or products referred to in the content.