Entecavir as specific antiviral therapy in selected cases of severe acute hepatitis B

Oana Streinu-Cercel,[1] Anca Streinu-Cercel,[2,*] Liliana Lucia Preoțescu,[3] Adrian Streinu-Cercel[4]

Abstract

The role of specific antiviral treatment in severe acute hepatitis B has been subject to debate during the past few years. We present clinical findings in a series of three cases of severe acute hepatitis B and one case of acute hepatitis B treated with entecavir during 2007-2009, with interesting evolution.

Entecavir appeared to improve the clinical evolution in the reported cases. Two of the patients displayed HBsAg to HBsAb seroconversion while another patient went into an inactive HBsAg carrier state. In the case of mild acute hepatitis B, the liver enzymes had returned to normal, symptomatology had receded but HBsAg had remained positive. Without data on viral load, we were unable to determine whether the patient had entered an inactive HBsAg carrier state or had continued into the services of another medical unit, for treatment of chronic HBV infection.

We also discuss into detail a case which displayed transient initial HBe seroconversion at 1 week, followed by seroreversion to positive HBeAg and negative HBeAb at week 3, and a new seroconversion at week 7. We assess the possible roles of precore mutations, antibody-dependent cellular cytotoxicity, coinfection with Epstein Barr virus and the function of Kupffer cells.

Keywords **Severe acute hepatitis B, entecavir, antiviral therapy.**

Introduction

Severe acute hepatitis B (SAHB) is an outline of disease which may often lead to acute hepatic failure[1] and requires individual care.[2] The current indication of antiviral use in the treatment of acute hepatitis B is in patients with severe or prolonged evolution of disease.[3] However, until 2009 when the American Association for the Study of Liver Diseases (AASLD)[3] and the European Association for the Study of the Liver (EASL)[4] published the updated guidelines, there was little evidence on the use of antivirals in general and of entecavir in particular in SAHB.

In order to shed some light on this issue, we performed a controlled study in the National Institute of Infectious Diseases 'Prof.Dr. Matei Balș', Bucharest, Romania (article in press). However, not all patients with SAHB treated in our Institute met the study's eligibility criteria or were diagnosed during the trial enrollment period.[5] Therefore, we report a series of three cases of SAHB and one case of acute hepatitis B treated with entecavir during 2007-2009, with interesting evolution. We define SAHB by IgM-positive and IgG-negative HBcAb (hepatitis B core antibodies), prothrombin concentration below 36%, serum bilirubin over 10 mg/dL or INR greater than 2.0.

Received: 7 December 2011; accepted: 3 February 2012
[1]Carol Davila University of Medicine and Pharmacy, Bucharest, Romania; [2]MD, PhD, Lecturer, Department of Infectious Diseases, Carol Davila University of Medicine and Pharmacy, Bucharest, Romania, National Institute for Infectious Diseases 'Prof. Dr. Matei Balș', Romania; [3]MD, PhD, Assistant lecturer, Department of Infectious Diseases, Carol Davila University of Medicine and Pharmacy, Bucharest, Romania, National Institute for Infectious Diseases 'Prof. Dr. Matei Balș', Romania; [4]MD, PhD, Professor, Department of Infectious Diseases, Carol Davila University of Medicine and Pharmacy, Bucharest, Romania, National Institute for Infectious Diseases 'Prof. Dr. Matei Balș', Romania
*Corresponding author: Anca Streinu-Cercel, MD, PhD, Lecturer, Department of Infectious Diseases, Carol Davila University of Medicine and Pharmacy, 37 Dionisie Lupu Street, Bucharest, 020022; National Institute for Infectious Diseases 'Prof. Dr. Matei Balș', 1 Dr. Calistrat Grozovici street, Bucharest, Romania; anca_sc@yahoo.com

Article downloaded from www.germs.ro
Published on 1 March 2012
© GERMS 2012
ISSN 2248 – 2997
ISSN – L = 2248 – 2997

Case series

Case 1

A 46 year-old male patient presented with SAHB in 2007, with the following biochemical tests: alanine aminotransferase (ALT) 2761 U/L; aspartate aminotransferase (AST) 1700 U/L; serum bilirubin 12 mg/dL; HBV-DNA 110 million IU/mL; positive HBsAg (hepatitis B surface antigen) with negative HBsAb (hepatitis B surface antibodies) and positive HBeAg (hepatitis B e antigen) with negative HBeAb (hepatitis B e antibodies).

Given the altered clinical status, we started administering entecavir 1 mg/day along with the usual care for acute hepatitis B, mostly symptomatic. During the course of the following 4 weeks, the patient started to show biochemical improvement, with ALT 1608 U/L, AST 1200 U/L but with bilirubin levels still at 11 mg/dL, which determined us to start therapy with ursodeoxycholic acid and hydrocortisone succinate 300 mg/day for 4 days. What was notable was that the patient presented a dramatic decrease in HBV-DNA, down to 227 IU/mL which, however, was not associated with clearance of HBsAg or HBeAg or with development of antibodies.

After another 3 weeks, ALT decreased to 456 U/L, AST to 375 U/L and bilirubin to 0.9 mg/dL, with undetectable HBV-DNA and HBe Ag to HBe Ab seroconversion, which was not, however, accompanied by clearance of HBsAg. At this point, due to local unavailability of the drug, we had to stop entecavir treatment. Off-treatment, the patient displayed a good clinical evolution, with the following parameters at his follow-up at 24 weeks from baseline: ALT 48 U/L, AST 43 U/L, serum bilirubin 0.9 mg/dL; undetectable HBV-DNA, HBe seroconversion; however HBsAg was still positive, with no development of antibodies. The most recent follow-up data for the patient is available at 2 years and 7 months from the acute episode, with the patient being in inactive HBsAg carrier state,[3] with liver function parameters remaining normal, still positive for HBsAg, but with undetectable HBV-DNA, negative HBeAg and positive HBeAb.

Case 2

In the beginning of 2009, a 28 year-old female patient presented to the hospital with jaundice, elevated liver enzymes and coagulation issues. Her ALT was 5778 U/L, her AST 3419 U/L, bilirubin 7.1 mg/dL and INR 2.1; positive HBsAg, negative HBsAb, positive HBeAg and HBeAb were recorded. She was diagnosed with SAHB and started treatment with entecavir 1 mg/day, along with symptomatic care.

After 3 weeks of therapy, ALT decreased to 278 U/L, AST to 116 U/L and serum bilirubin to 2.5 mg/dL. HBsAg was still positive, with negative antibodies, but she had cleared HBeAg under positive HBeAb. Treatment was continued for another 10 weeks, until HBsAg was cleared, with antigen to antibody seroconversion, normal liver enzymes and liver function tests: ALT 21 U/L, AST 34 U/L; bilirubin 0.9 mg/dL. Antiviral treatment was stopped and at follow-up after 11 weeks (at 24 weeks from baseline), the HBs and HBe seroconversions were maintained, ALT was 16 U/L, AST 27 U/L and serum bilirubin was 0.6 mg/dL.

We have follow-up data at 1 year and 3 months from the acute episode, with normal liver tests and sustained HBs seroconversion.

Case 3

A 26 year-old male patient was admitted in 2009 for SAHB, with ALT 4243 U/L, AST 1540 U/L, bilirubin 11 mg/dL and HBV-DNA 2.6 IU/mL, positive HBsAg and HBeAb, negative HBsAb and HBeAb. Treatment with entecavir 1 mg/day was started and after one week, we recorded HBe seroconversion. At 3 weeks, ALT decreased to 293 U/L, AST to 176 U/L, bilirubin to 4.8 mg/dL and HBV-DNA to 589 IU/mL. The patient had not cleared HBsAg or developed antibodies, moreover he had seroreverted to positive HBeAg and negative HBeAb. Treatment was continued for another 4 weeks, when HBs and HBe seroconversions were recorded, with undetectable HBV-DNA and normal liver tests: bilirubin 2.2 mg/dL; ALT 34 U/L and AST 31 U/L.

Case 4

A 23 year-old female patient was diagnosed with acute hepatitis B in 2008, based on positive HBsAg, negative HBsAb, positive HBeAg, negative HBeAb, ALT 308 U/L AST 183 U/L, prothrombin concentration 91% and bilirubin 1.5 mg/dL. Due to the altered clinical state, dyspeptic syndrome and high viral load (9.6 million IU/mL) we decided to start entecavir 1 mg/day. The patient's clinical state significantly improved and by 6 weeks, the liver enzymes had returned to normal. She had an ALT of 43 U/L, AST 42 U/L; prothrombin concentration was 102% and bilirubin 0.8 mg/dL. We recorded HBe seroconversion, but HBsAg was not cleared and the patient had not developed HBsAb. At this point, the patient decided to stop therapy and was subsequently lost to medical follow-up in our institute and therefore, we do not have the necessary data to determine whether she entered an inactive HBsAg carrier state or she continued into the services of another medical unit, for treatment of chronic HBV infection.

Discussion

All three cases of SAHB displayed good clinical evolution under entecavir treatment, with liver enzymes returning to normal (figure 1) in a relatively short time span after starting therapy. HBs and HBe seroconversions were eventually recorded in two of the three cases, at 13 and 7 weeks respectively. One of the cases went into an inactive HBsAg carrier state with persistently positive HBsAg but with normal liver function and no apparent hepatic damage at 2 years and 7 months from the acute episode.

The fourth case, that of a patient with acute hepatitis B, could point to the fact that antivirals, although useful in the treatment of SAHB, may not be of much use in milder outlines of acute hepatitis B and should be reserved for selected, severe cases, as specified in the AASLD guidelines subsequently developed in 2009.[3]

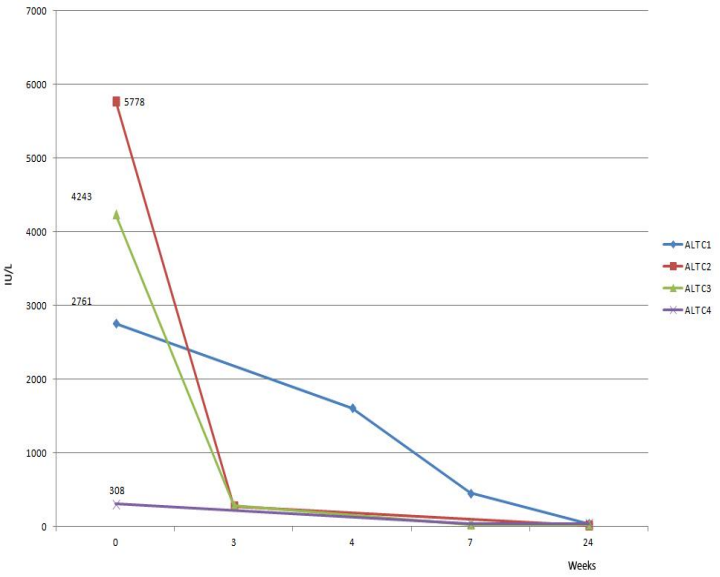

Figure 1. ALT dynamics in the four reported cases

ALT C1 – alanine aminotransferase values for case 1; ALT C2 – alanine aminotransferase values for case 2; ALT C3 – alanine aminotransferase values for case 3; ALT C4 – alanine aminotransferase values for case 4.

One of the cases displayed transient initial HBe seroconversion at 1 week, followed by seroreversion to positive HBeAg and negative HBeAb at week 3, which was subsequently followed by another seroconversion at week 7 which, this time, was maintained over the course of the following month, when the patient kept up with follow-up visits. There are several possible explanations for this chain of events, one of them being precore mutations[6] (unfortunately, at that point, we were unable to perform mutation sequencing or resistance tests). In the context of a low viral load (below 2000 IU/mL), if the patient does not present signs of hepatic damage such as increased necroinflammatory activity, fibrosis and/or increase of ALT, we can take into account a potential mutation affecting viral fitness,[7] which would lead to a relatively low replication rate of the virus, a decreased virulence and could contribute to increasing the patient's life expectancy and his chance of being at some point enrolled in a therapeutic trial, for treatment with a new molecule which would facilitate viral

clearance (including clearance of cccDNA from circulating monocytes).[8]

One other mechanism could be antibody-dependent cellular cytotoxicity (ADCC) with cross-reactive antibodies, possibly through co-infection with another DNA virus. Given that at the time of seroreversion ALT and AST values were mildly increased, we considered a possible co-infection with the Epstein Barr virus, taking into consideration the fact that mononucleosis is known to target the liver, with transaminases increased 5-fold, on average.[9]

Another mechanism worth considering is a partial deficit in HBV specific T helper cells. Kupffer cells are known to play an important role in conditioning the immune response, acting as antigen presenting cells.[10,11] Under antiviral therapy quantitative variations in viral load may occur, thus changing the stimuli to which Kupffer cells are exposed. Subsequently, these antigen presenting cells may alter the specific immune response or release anti-inflammatory cytokines.[12] The proportion of previously released proinflammatory cytokines which are still circulating and that of the newly released anti-inflammatory cytokines can therefore unbalance the immune response.

In order to evaluate the sustainability of the seroconversion, we need to assess three major parameters: 1) low necroinflammatory activity, 2) normal liver enzymes, both associated with 3) favorable immune response. When all three parameters are in accordance, the prognosis is bound to be favorable. If there is discordance in any of the three parameters, we can expect rebound.

Conclusions

Entecavir improved the clinical evolution of SAHB in all reported cases. Two of the patients displayed HBsAg to HBsAb seroconversion while another patient went into an inactive HBsAg carrier state and the last case, that of mild acute hepatitis B, was lost to follow-up after the liver enzymes had returned to normal, symptomatology had receded but HBsAg had remained positive.

In the light of our clinical experience and comparing our case series with the positive reports on the use of entecavir in field literature,[13-15] for the time being we can consider entecavir to be an option in selected cases with SAHB. It is, however, not possible to determine a recommended duration of treatment based on the scarce data available so far.

Conflicts of interest All authors – none to declare.

Author contributions OSC performed the literature review and wrote the manuscript; Anca SC and LP provided the clinical information and contributed to the final version of the manuscript. ASC interpreted the data and contributed to the manuscript with valuable clinical insight.

Acknowledgement This paper is supported by the Sectoral Operational Programme Human Resources Development (SOP HRD), financed from the European Social Fund and by the Romanian Government under the contract number POSDRU/89/1.5/S/64109.

References

1. Khanna S, Tandon R. Management of severe acute hepatitis B. Hepatitis B Annual. 2007; 4(1): 107-17.
2. Streinu-Cercel A. Hepatitis B in the spotlight. GERMS. 2011; 1(1): 5.
3. Lok AS, McMahon BJ. Chronic hepatitis B: update 2009. Hepatology. 2009; 50(3): 661-2.
4. EASL Clinical Practice Guidelines: management of chronic hepatitis B. J Hepatol. 2009; 50(2): 227-42.
5. Streinu-Cercel A, Rebedea I, Streinu-Cercel O, Streinu-Cercel A, Preoțescu L, Manolache D. Hepatitis C virus superinfection in individuals with chronic hepatitis B virus infection. A comparative case study. Therapeutics, Pharmacology and Clinical Toxicology. 2010; XIV(1): 25-35.
6. Liu CJ, Chen PJ, Lai MY, Kao JH, Chen DS. Evolution of precore/core promoter mutations in hepatitis B carriers with hepatitis B e antigen seroreversion. J Med Virol. 2004; 74(2): 237-45.
7. Sheldon J, Rodes B, Zoulim F, Bartholomeusz A, Soriano V. Mutations affecting the replication capacity of the hepatitis B virus. J Viral Hepat. 2006; 13(7): 427-34.
8. Xu CH, Li ZS, Dai JY, Zhu HY, Yu JW, Lv SL. [Establishment and application of nested real-time quantitative polymerase chain reaction assay for detection of hepatitis B virus covalently closed circular DNA]. Zhonghua Shi Yan He Lin Chuang Bing Du Xue Za Zhi. 2011; 25(4): 307-9.
9. Kofteridis DP, Koulentaki M, Valachis A, Christofaki M, Mazokopakis E, Papazoglou G, et al. Epstein Barr virus hepatitis. Eur J Intern Med. 2011; 22(1): 73-6.
10. Pulford K, Souhami RL. The surface properties and antigen-presenting function of hepatic non-parenchymal cells. Clin Exp Immunol. 1981; 46(3): 581-8.

11. Tang TJ, Kwekkeboom J, Laman JD, Niesters HG, Zondervan PE, de Man RA, et al. The role of intrahepatic immune effector cells in inflammatory liver injury and viral control during chronic hepatitis B infection. J Viral Hepat. 2003; 10(3): 159-67.
12. Gao B. Hepatoprotective and anti-inflammatory cytokines in alcoholic liver disease. J Gastroenterol Hepatol. 2012; 27 Suppl 2: 89-93.
13. De Socio GV, Mercuri A, Di Candilo F, Baldelli F. Entecavir to treat severe acute hepatitis B. Scand J Infect Dis. 2009; 41(9): 703-4.
14. De Socio GV, Sgrelli A, Tosti A, Baldelli F. Severe acute hepatitis B treated with entecavir. Mediterr J Hematol Infect Dis. 2011; 3(1): e2011010.
15. Jochum C, Gieseler RK, Gawlista I, Fiedler A, Manka P, Saner FH, et al. Hepatitis B-associated acute liver failure: immediate treatment with entecavir inhibits hepatitis B virus replication and potentially its sequelae. Digestion. 2009; 80(4): 235-40.

Please cite this article as:
Streinu-Cercel O, Streinu-Cercel A, Preoțescu LL, Streinu-Cercel A. Entecavir as specific antiviral therapy in selected cases of severe acute hepatitis B. GERMS. 2012;2(1):18-22