children

MDPI

Systematic Review

Beyond Relapse Count: Surgical Decision-Making in Residual and Recurrent Idiopathic Clubfoot After Ponseti Treatment: A Systematic Review

Maurizio De Pellegrin [1,2,*], Daniela Alessia Marletta [3], Gabriele Giuca [4], Lorenzo Marcucci [1,5], Nicola Guindani [2] and Ignacio Sanpera [6]

[1] Pediatric Orthopedic Unit, Piccole Figlie Hospital, 43125 Parma, Italy; lore.marcucci93@gmail.com
[2] Department of Orthopedics, Regional Health Care and Social Agency Papa Giovanni XXIII, 24127 Bergamo, Italy; nicola.guindani@gmail.com
[3] Paediatric Orthopaedic Department, Pediatric Hospital ASST Spedali Civili, 25123 Brescia, Italy; damarletta2@gmail.com
[4] Section of Orthopaedics and Traumatology, Department of Biomedical Sciences and Morphological and Functional Images, University of Messina, 98122 Messina, Italy; gabgiuca@unime.it
[5] Department of Orthopedics and Traumatology, Ospedale San Bortolo, 36100 Vicenza, Italy
[6] Paediatric Orthopaedic Department, Hospital Universitari Son Espases, Ctra. Valldemossa, 79, 07120 Palma, Spain; ignasi.sanpera@ssib.es
* Correspondence: depellegrin1956@gmail.com

Highlights

What are the main findings?

- No eligible comparative study validated surgery after a first, second or third relapse.
- Recurrence count may inform prognosis, but correctability and the residual deformity identify the operative target.

What are the implications of the main findings?

- A recorrectable relapse warrants the assessment of renewed casting and brace suitability before considering operative escalation.
- The proposed phenotype-oriented approach clarifies treatment goals but is not a validated decision rule.

Abstract

Background/Objectives: A recurrent clubfoot is not necessarily a surgical clubfoot. This review evaluated whether relapse count defines an operative threshold and how the remaining deformity guides intervention. **Methods:** Five databases were searched through on 9 August 2026. Primary evidence was restricted to idiopathic clubfeet initially treated with Ponseti; non-Ponseti or syndromic reports were considered separately as context. Observational outcomes were synthesized narratively. **Results:** Definitions of relapse, retreatment, and surgery varied inconsistently across studies. In one series, 74 of 97 children with relapse (76.3%) avoided study-defined surgery, though repeat percutaneous Achilles tenotomy was excluded from that endpoint. In a second series, 26 of 35 reassessed children (74.3%) met clinical correction criteria after recasting; 36 of 71 eligible children were not reassessed. These outcomes were not pooled. Dynamic supination in a passively corrected foot indicated tibialis anterior tendon transfer, while persistent equinus prompted targeted Achilles management. No comparative study validated surgery after specified recurrences. **Conclusions:** Relapse count can signal prognosis but cannot determine the

Academic Editors: Ernesto Ippolito, Johannes Michael Mayr

Received: 28 September 2026
Revised: 18 November 2026
Accepted: 26 November 2026
Published: 28 November 2026

Copyright: © 2026 by the authors. Licensee MDPI, Basel, Switzerland. This article is an open access article distributed under the terms and conditions of the Creative Commons Attribution (CC BY) license.

surgical target. A phenotype-oriented pathway is clinically informative, not prospectively validated.

Keywords: clubfoot; congenital talipes equinovarus; Ponseti method; relapse; recurrent deformity; surgical indications; tibialis anterior tendon transfer; systematic review

1. Introduction

The Ponseti method transformed idiopathic clubfoot care by making extensive primary soft-tissue release unnecessary for most children. Serial manipulation and casting, selective Achilles tenotomy and prolonged foot-abduction bracing generally achieve correction while avoiding many of the long-term consequences historically associated with extensive release, including stiffness, pain, residual deformity and degenerative change [1–4]. Surgery nevertheless retains an important place in selected patients: the central challenge is no longer whether surgery can correct a recurrent clubfoot, but identifying which deformity warrants which intervention.

Relapse after initial Ponseti correction remains clinically important, but estimates vary with follow-up duration, the definition of recurrence and whether the outcome is reported per child or per foot. Morcuende et al. reported recurrence in approximately 10% of patients, whereas Dobbs et al. documented relapse in 31% of infants [2,5]. Recasting, repeat tenotomy, tendon transfer and extensive joint release should not be combined into a single treatment-failure rate. The frequency of renewed treatment therefore describes the burden of follow-up care, not a uniform need for an operation [2,5–12].

A central difficulty is that "relapse" is not a single clinical entity. A relapsed clubfoot may be flexible or rigid, early or late, dynamic or fixed, mild or severe, brace-related or biologically resistant. A toddler with recurrent equinus after brace noncompliance is not the same patient as a 5-year-old with dynamic supination during gait, an older child with fixed adduction after failed casting or an adolescent with a stiff, scarred, multiply operated foot [13–25]. Yet these conditions are often grouped under the same term. For this reason, the role of surgery cannot be understood simply by counting how many operations were performed. It must be interpreted according to deformity phenotype, timing, flexibility, braceability, previous treatment and response to renewed Ponseti management.

These distinctions also explain why the existing literature has not fully resolved the surgical decision. Previous systematic reviews have examined outcomes after Ponseti correction and factors associated with recurrence [11,26], but predicting relapse is not the same as identifying when, or why, a particular operation becomes necessary. The present review addresses this gap by separating evidence directly applicable to initially Ponseti-treated idiopathic feet from historical and salvage experience and by examining surgical indications in relation to the deformity that remains after reassessment. Particular attention is given to the response to renewed casting, passive correctability and the distinction between dynamic muscle imbalance and fixed structural deformity [2,5–14,16,17].

This review asked whether published evidence identifies a defensible relapse-count threshold for surgery, which residual clinical findings prompt limited procedures and how the outcomes of repeat casting and phenotype-matched surgery vary across initially Ponseti-treated idiopathic clubfoot cohorts. Its specific contribution is a critical distinction between relapse count as a possible prognostic marker and the residual deformity as the anatomical target for surgery. We hypothesized that passive correctability, recurrent equinus, gait-related dynamic supination, age, prior treatment and the response to renewed casting would be more clinically actionable than counting recurrences alone.

https://doi.org/10.3390/children13121679

2. Materials and Methods

2.1. Protocol and Registration

The systematic review was conducted and reported in accordance with PRISMA 2020 [27]. Literature searching began on 9 July 2026, followed by the initiation of study screening on 1 August 2026 and the final database search on 9 August 2026. The review was retrospectively registered in PROSPERO on 28 August 2026 (CRD420261489943), after searching and screening had begun. During the subsequent eligibility reassessment, the criteria for direct evidence were refined to distinguish initially Ponseti-treated idiopathic clubfeet from historical non-Ponseti, non-idiopathic and previously operated salvage populations. Mixed-treatment studies were retained only when relevant Ponseti-specific outcomes could be extracted. These refinements were made to improve the consistency between the review question, the eligible population and the interpretation of the evidence.

2.2. Eligibility Criteria

The review targeted primary studies reporting recurrence, residual deformity, repeat treatment or secondary operative decisions among children with idiopathic clubfoot initially managed using the Ponseti method. Studies of overall Ponseti cohorts were eligible when they reported extractable outcomes in recurrent or subsequently operated children; not every participant was required to have relapsed. In studies comparing initial treatments, only Ponseti-specific results contributed to the primary synthesis. Previously untreated children who first received Ponseti treatment were eligible, whereas outcomes from children previously managed with another corrective technique contributed only when separable. Non-idiopathic, neurological, syndromic, historical non-Ponseti and previously operated salvage cohorts without separable initially Ponseti-treated idiopathic data were excluded from direct estimates but could inform the discussion. Postoperative immobilization trials were excluded if they did not address the review question. Possible companion reports were identified from center, author and recruitment years and were never assumed to represent nonoverlapping patients. Atypical or complex-appearing idiopathic clubfeet were distinguished from syndromic and neurological deformities. Data from these feet contributed to the direct synthesis only when initial Ponseti treatment and the relevant outcomes could be established within an otherwise eligible cohort.

2.3. Information Sources and Search Strategy

A systematic literature search was conducted in MEDLINE/PubMed, Embase, Scopus, Web of Science Core Collection, and the Cochrane Central Register of Controlled Trials (CENTRAL), with the final search performed on 9 August 2026. The search combined three main concepts: congenital clubfoot, Ponseti treatment and residual or recurrent deformity requiring further management. Both conservative and surgical interventions were considered to capture the full spectrum of treatment escalation. Controlled vocabulary was incorporated where available and search syntax was adapted to the indexing structure of each database.

The database-specific strategies were as follows:

MEDLINE/PubMed:

("Clubfoot"[MeSH Terms] OR clubfoot*[tiab] OR "congenital talipes equinovarus"[tiab] OR "pes equinovarus"[tiab]) AND (Ponseti[tiab] OR "serial casting"[tiab] OR "foot abduction brace"[tiab]) AND (relaps*[tiab] OR recurren*[tiab] OR "residual deformity"[tiab] OR recast*[tiab] OR "tibialis anterior"[tiab] OR tenotom*[tiab] OR surg*[tiab]).

Embase:

('clubfoot'/exp OR clubfoot*:ti,ab,kw OR 'congenital talipes equinovarus':ti,ab,kw OR 'pes equinovarus':ti,ab,kw) AND (ponseti:ti,ab,kw OR 'serial casting':ti,ab,kw OR 'foot abduction brace':ti,ab,kw) AND (relaps*:ti,ab,kw OR recurren*:ti,ab,kw OR 'residual deformity':ti,ab,kw OR recast*:ti,ab,kw OR 'tibialis anterior':ti,ab,kw OR tenotom*:ti,ab,kw OR surg*:ti,ab,kw).

Scopus:

TITLE-ABS-KEY(clubfoot* OR "congenital talipes equinovarus" OR "pes equinovarus") AND TITLE-ABS-KEY(ponseti OR "serial casting" OR "foot abduction brace") AND TITLE-ABS-KEY(relaps* OR recurren* OR "residual deformity" OR recast* OR "tibialis anterior" OR tenotom* OR surg*).

Web of Science Core Collection:

TS=(clubfoot* OR "congenital talipes equinovarus" OR "pes equinovarus") AND TS=(Ponseti OR "serial casting" OR "foot abduction brace") AND TS=(relaps* OR recurren* OR "residual deformity" OR recast* OR "tibialis anterior" OR tenotom* OR surg*).

Cochrane Library (CENTRAL):

1. MeSH descriptor: [Clubfoot] explode all trees.
2. (clubfoot* OR "congenital talipes equinovarus" OR "pes equinovarus"):ti,ab,kw.
3. #1 OR #2.
4. (Ponseti OR "serial casting" OR "foot abduction brace"):ti,ab,kw.
5. (relaps* OR recurren* OR "residual deformity" OR recast* OR "tibialis anterior" OR tenotom* OR surg*):ti,ab,kw.
6. #3 AND #4 AND #5.

The reference lists of eligible studies and relevant reviews were also screened to identify potentially overlooked publications. The reference lists of eligible studies and relevant reviews were screened to identify potentially overlooked publications. This process identified no additional unique records beyond those already retrieved through the electronic database searches and therefore did not alter the final evidence set.

2.4. Study Selection

Two reviewers independently screened titles and abstracts and assessed potentially eligible full-text articles to determine final eligibility. Disagreements were resolved by discussion and, when necessary, by adjudication by a third reviewer. When multiple reports described the same or an overlapping cohort, the most complete peer-reviewed publication was used as the principal source; companion reports were retained only to cross-check or supplement nonduplicated information. Where partially overlapping cohorts addressed different clinical questions or outcomes, their findings were retained separately without combining patient counts or treating the reports as independent confirmation of the same effect.

The study-selection process is presented in Figure 1 according to PRISMA 2020 [27]. The records identified through electronic databases and citation searching were tracked separately. The electronic database search and supplementary reference-list screening were documented separately, with the latter contributing no additional eligible reports. Publications originating from potentially overlapping cohorts were identified through institutional affiliation, recruitment periods and population characteristics.

2.5. Data Extraction

Two reviewers independently extracted study design, setting, recruitment period, population, previous treatment, study size by child and foot, follow-up, initial correction, definitions of residual deformity and relapse, number and response of recasting attempts, operative indications, timing and type of surgery and reported clinical and patient-

reported outcomes. For each numerical result, its numerator, denominator, unit of analysis, time point and outcome definition were preserved. Operative thresholds were coded as explicitly reported only when the source stated a decision rule; otherwise, treatment patterns were labeled descriptive or inferred. Discrepancies were resolved by consensus. Bilateral feet were not assumed to be statistically independent and patient-level and foot-level estimates were never combined into a pooled numerator or denominator. For outcomes with an extractable numerator and denominator, study-specific proportions and 95% confidence intervals were calculated using the Wilson score method. These estimates were descriptive and were not pooled. Confidence intervals based on foot-level observations were interpreted cautiously because within-patient correlation could not be accounted for without individual participant data.

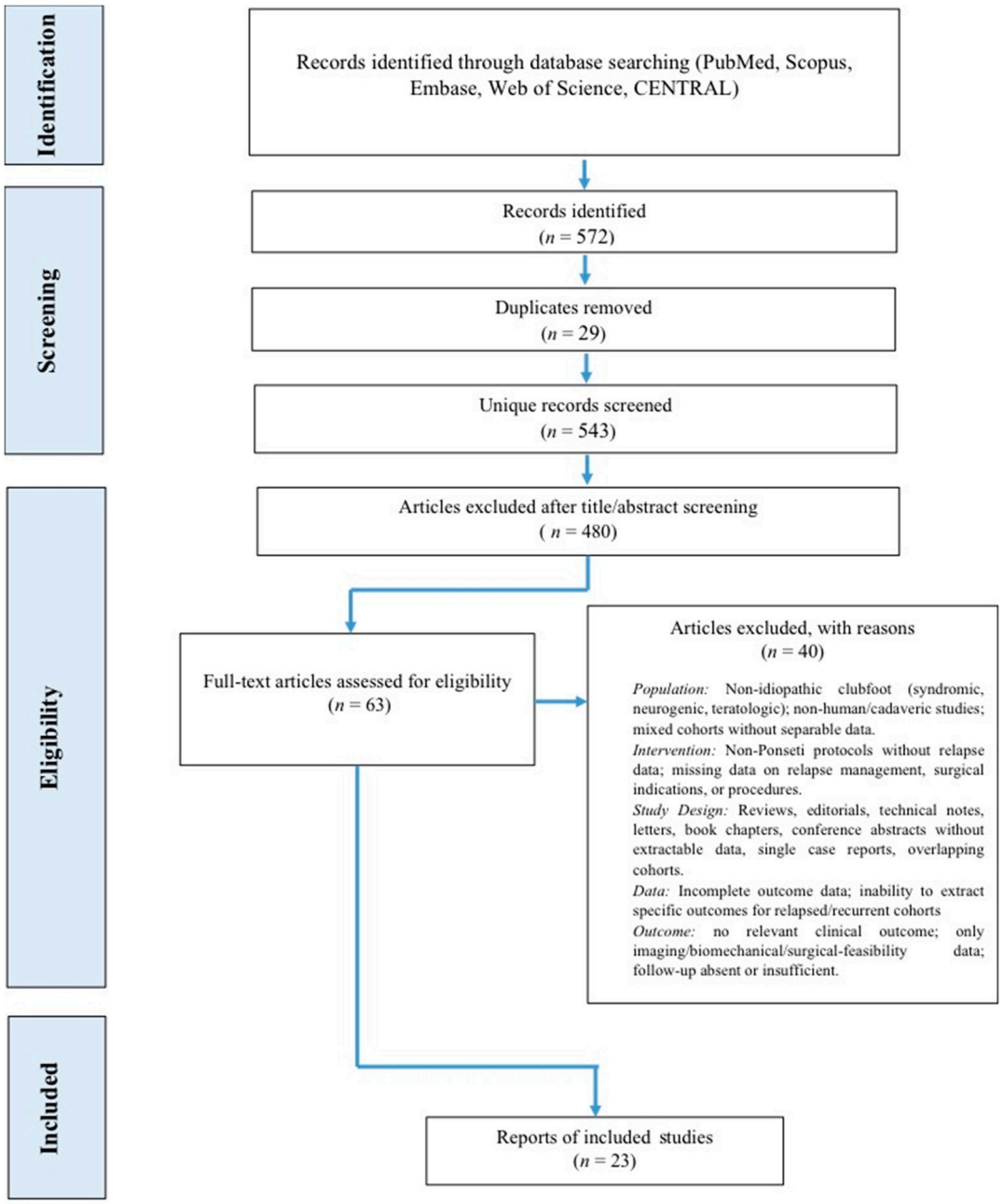

Figure 1. PRISMA flow diagram.

2.6. Risk of Bias Assessment

Methodological appraisal was tailored to the study design and review-relevant outcome. Prognostic-factor analyses were evaluated using the six domains of the Quality in Prognosis Studies (QUIPS) tool, whereas descriptive clinical series were assessed using the ten-item Joanna Briggs Institute (JBI) Case Series Checklist. The prospective nonrandomized functional comparison by Gray et al. was evaluated using the JBI Quasi-Experimental Checklist. QUIPS domains were classified as low, moderate or high risk of bias, while JBI items were recorded as yes, no, unclear or not applicable. No numerical summary score was calculated across instruments. Study-specific judgments and their clinical implications are presented in Supplementary Table S1. Two reviewers independently assessed methodological quality using the tool appropriate to each study design and review-relevant outcome. Differences in domain-level judgments were resolved by discussion and consensus. The resulting assessments were interpreted according to the clinical question addressed, without combining scores from different appraisal instruments.

2.7. Synthesis Approach

A narrative synthesis was undertaken because differences in study design, initial treatment, recurrence definitions, operative indications, follow-up and units of analysis precluded meaningful quantitative pooling. Evidence from initially Ponseti-treated idiopathic clubfeet was organized according to the clinical problem at reassessment: passively correctable recurrence, persistent equinus, dynamic supination after structural correction and fixed or complex deformity. Residual deformity and true recurrence were distinguished whenever the original report provided sufficient information.

Study-specific outcomes were retained using their original definitions, denominators and follow-up periods. Prognostic associations were interpreted separately from treatment outcomes and findings from potentially overlapping cohorts were not combined as independent estimates. Historical reconstruction, non-idiopathic deformities and previously operated salvage populations were discussed as contextual evidence without contributing to the primary synthesis. No meta-analysis was performed because clinical heterogeneity and confounding by indication did not support valid comparisons between treatment strategies.

3. Results

3.1. Study Selection

The electronic database searches identified 572 records. After removal of 29 duplicates, 543 records underwent title and abstract screening and 63 reports were assessed at full text. Forty reports were excluded following eligibility assessment, leaving 23 reports for the narrative synthesis (Figure 1). Several eligible reports originated from institutions with overlapping recruitment periods and the underlying patient populations could not always be established as independent. Accordingly, findings were synthesized at the report level without combining potentially duplicated patient data. Several clinically relevant publications did not meet the criteria for direct synthesis. Zeifang et al. [19] examined postoperative immobilization rather than the management threshold for recurrent deformity. Carpiaux et al. [28] and Bhatti et al. [29] addressed non-idiopathic populations, whereas Stouten et al. [30] reported mixed initial treatment pathways without sufficiently separable Ponseti-specific outcomes for the present analysis. The administrative study by Hamad et al. [31] could not confirm initial Ponseti treatment or the clinical recurrence phenotype at the individual-patient level. These publications were therefore considered only where they provided relevant clinical context, without contributing to the primary outcome estimates.

3.2. Study Characteristics

The design, population and clinical relevance of the included reports are summarized in Table 1. Reports from potentially overlapping cohorts were not treated as independent patient samples. The eligible part of Richards et al. comprised 176 children with 267 Ponseti-treated feet, separate from the French-method comparison group [6]. In Göksan et al., only 70 previously untreated children with 102 feet formed the strictly eligible initial-Ponseti subgroup; the overall cohort included 32 previously treated feet [32]. Halanski et al. reported 25 eligible Ponseti-treated children separately from an initially operated comparator, whereas Ošťádal et al. reported 195 consecutive children with 303 initially Ponseti-treated feet [33,34]. These distinctions matter: rates of subsequent treatment from mixed primary-treatment populations should not be transferred uncritically to relapse after successful Ponseti correction.

3.3. Risk of Bias

The methodological appraisal identified recurring concerns regarding selection and attrition, reliance on caregiver-reported brace adherence, heterogeneous recurrence definitions and incomplete control of confounding (Supplementary Table S1). These limitations were particularly relevant to prognostic associations with subsequent surgery. Descriptive studies provided useful information on treatment patterns and functional outcomes but rarely permitted unbiased comparisons between operative and nonoperative strategies. The prospective functional evaluation of tibialis anterior tendon transfer offered more detailed outcome measurements, although baseline differences and concomitant procedures limited causal interpretation. These limitations restrict the conclusions that can be drawn from the available studies. Observational associations between baseline severity, brace adherence, recurrence and subsequent surgery cannot establish the benefit of one treatment strategy over another. Similarly, functional improvements after tendon transfer cannot be attributed solely to the procedure when baseline differences and concomitant operations are present. The evidence supports a clinically plausible phenotype-based interpretation but provides no direct comparative estimate for selecting surgery according to the number of previous relapses.

3.4. Definitions and Frequency of Relapse

Published recurrence definitions captured different events. Morcuende et al. and Dobbs et al. described the loss of a previously obtained correction; Zionts et al. counted deformity requiring renewed casting or surgery; Haft et al. operationalized recurrence as subsequent surgery itself [2,5,9,35]. Importantly, Gremminger et al. did not count isolated dynamic supination as structural relapse and excluded repeat percutaneous tenotomy from their main surgical endpoint [12]. Thus, a study reporting "relapse", "recasting" or "operation" may not have measured the same biological or clinical event. Patient-level and foot-level percentages were retained separately and no pooled relapse proportion was considered clinically justified.

Reported relapse frequency varied accordingly, from approximately 10% in the series by Morcuende et al. [2] to approximately one-third in several contemporary cohorts, with higher rates reported in some longer-term series. Differences in follow-up duration, unit of analysis, relapse definition and treatment threshold limited direct comparison between studies.

3.5. Conservative Management of Recurrence

Renewed casting remains relevant when correction can be recovered, but its apparent effectiveness depends on the endpoint chosen. In Gremminger et al., 74 of 97 children with relapse (76.3%; Wilson 95% CI, 66.9–83.6%) did not require treatment classified by that

study as surgery; importantly, repeat percutaneous Achilles tenotomy was excluded from its operative definition and five children in the nonsurgical relapse subgroup underwent repeat tenotomy [12]. In van Praag et al., 26 of 35 reassessed children with recurrence (74.3%; Wilson 95% CI, 57.9–85.8%) had a clinically well-corrected foot after repeat casting and bracing, although only 35 of 71 eligible recurrent children were reassessed [36]. In the reassessed subgroup, satisfactory correction occurred in 18 of 19 children after one recurrence compared with 8 of 16 after multiple recurrences [36]. These figures cannot be combined: avoidance of study-defined surgery differs from correction at reassessment, attrition is substantial and the Toronto recruitment periods may overlap. Earlier cohorts also describe renewed casting followed by selective repeat Achilles procedures for equinus that remains uncorrected [2,5,9]. Figure 2 separates avoidance of study-defined surgery from clinical correction following recasting and makes the incomplete reassessment in van Praag et al. explicit. The lower proportion of satisfactory correction after multiple recurrences is a prognostic observation, not evidence for an operative threshold [12,36].

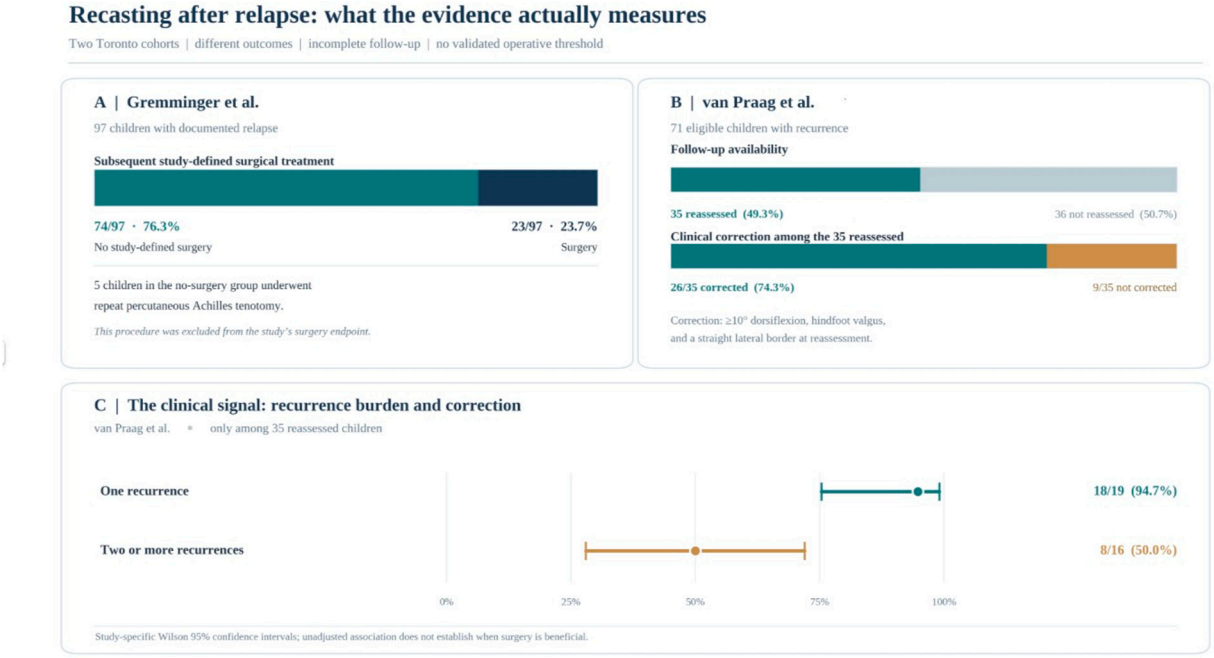

Figure 2. Recasting after Ponseti relapse: outcomes, reassessment and recurrence burden. (**A**) Gremminger et al. [12] reported study-defined surgery in 23 of 97 children with relapse; five children in the nonsurgical group underwent repeat percutaneous Achilles tenotomy, which was not classified as surgery. (**B**) In van Praag et al. [36], only 35 of 71 eligible children were reassessed, and 26 of 35 met clinical correction criteria. (**C**) Among those assessed, satisfactory correction occurred after one recurrence in 18 of 19 children versus 8 of 16 after two or more recurrences (Wilson 95% confidence intervals) [36]. The studies used different endpoints and potentially overlapping institutional recruitment periods; estimates should not be pooled or interpreted as surgical thresholds.

3.6. How Many Relapses Trigger Surgery?

No study prospectively tested surgery after a first, second or third relapse against a competing management threshold. The recurrence count nevertheless may convey prognosis: van Praag et al. reported lower rates of satisfactory clinical correction after multiple recurrences, without demonstrating that operating earlier would have improved outcomes [36]. Observational cohorts also linked later surgery with baseline severity and brace adherence. Goldstein et al. recorded 28 operated children among 86 analyzed (32.6%), with an adjusted odds ratio of 6.0 (95% CI, 1.7–21.4) for reported brace

nonadherence, but 87 of 173 potentially eligible children lacked minimum three-year follow-up [37]. Hemo et al. found surgery in 82 of 333 children (24.6%) and 119 of 500 feet (23.8%), associated with baseline Pirani score and initial casting burden [38]. These associations concern risk, not the benefit of a particular operation. A decision to operate still requires examination of correctability, persistent equinus, dynamic supination or fixed structural deformity rather than a relapse count alone.

Table 1. Characteristics and clinical relevance of direct evidence addressing residual or recurrent idiopathic clubfoot following Ponseti treatment.

Study	Eligible Population	Design/Follow-Up	Clinical Domain	Most Informative Result
Richards et al., 2008 [6]	176 children/267 feet; Ponseti subgroup	Prospective comparative; mMean 4.3 y	Initially untreated; Ponseti arm; relapse after primary correction	37% of initially corrected Ponseti feet relapsed; one-third of recurrent feet managed nonoperatively.
Bhaskar and Patni, 2013 [13]	91 children/164 relapsed feet	Retrospective clinical series; mMean 4.5 y	Relapsed idiopathic feet after initial Ponseti; grades IA, IB, IIA, IIB, III	Five phenotype classes from reduced dorsiflexion and dynamic supination to fixed multidimensional deformity.
Ošťádal et al., 2013 [33]	195 children/303 feet	Retrospective consecutive cohort; vVariable; up to 7 y	Initially Ponseti-treated idiopathic; recurrence/operative escalation	82/195 children and 111/303 feet received surgery after recurrence; selected repeat casting before surgery.
Haft et al., 2007 [35]	51 children/73 feet	Prospective cohort; mMean 35 mo	Recurrence defined as need for any subsequent operative treatment	21/51 had recurrence defined by surgery: 12 extensive and 9 limited procedures.
Dobbs et al., 2004 [5]	51 children/86 feet	Retrospective cohort; mMean 26.7 mo	Loss of correction after initial Ponseti	16/51 children experienced clinical recurrence; renewed casting preceded selective Achilles surgery.
Radler et al., 2013 [7]	113 observed children/182 feet	Prospective registry-derived series; mMean 5.2 y	Idiopathic Ponseti, recurrence and selected secondary surgery	Open joint surgery reported in 5%; TATT 13%; response and function incompletely ascertained.
Ramírez et al., 2011 [39]	53 children/73 feet	Retrospective cohort; mMean 48 mo	Relapse after initial Ponseti, Dimeglio deterioration requiring recasting	16/53 children relapsed; bracing difficulty associated with recurrence and reintervention.
Bor et al., 2009 [8]	74 children/117 feet	Retrospective cohort; mMean 6.3 y	Ponseti-treated idiopathic; additional surgery	24/74 children underwent additional surgery; follow-up allowed later intervention ascertainment.
Göksan et al., 2006 [32]	Initially untreated subgroup: 70 children/102 feet	Clinical treatment series; mMean 46 mo	Untreated initial Ponseti group A; prior non-Ponseti-treated B/C excluded from direct rates	Untreated subgroup: 27/102 feet relapsed and 3/102 required joint release; mixed sample excluded.
Morcuende et al., 2004 [2]	157 children/256 feet	Consecutive treatment series; mMean 26 mo	Idiopathic, Ponseti initially	17/157 children relapsed; only 4/157 needed extensive corrective surgery.
Zionts et al., 2012 [9]	57 children/84 feet	Prospective consecutive series; mMean 37.9 mo	Relapse requiring casting or surgery; Mitchell–-Ponseti brace	40/84 feet recurred and regained correction with casts; 19/84 had or were scheduled for TATT.
Holt et al., 2015 [14]	35 traced adults/60 feet; TATT group 14 adults	Retrospective 37–55-year follow-up; mMean 43 y post-TATT	Initially Ponseti-treated idiopathic; relapsed subgroup treated with TATT	No re-relapse documented among traced TATT recipients; low long-term ascertainment.
Gremminger et al., 2025 [12]	268 children/397 feet; 97 with recurrence	Retrospective single-center cohort; 91.5 mo relapse/60.8 mo no -relapse	Idiopathic classic and complex-type Ponseti; dynamic-only supination not classified as relapse	74/97 had no study-defined surgery; repeat percutaneous tenotomy was not classified as surgery.
Masrouha and	66 children/102 feet	Retrospective post-TATT series; mMean 6.8 y	Re-relapse after TATT performed for idiopathic post-Ponseti recurrence	10/66 children developed further relapse after TATT, prompting further casting/orthotic care.

Morcuende, 2012 [16]				
Halanski et al., 2010 [34]	Ponseti arm: 25 children	Retrospective two-arm clinical series; mMinimum 2 y	Early abnormality versus later recurrence after Ponseti, mixed-treatment comparator excluded	22/25 displayed residual/recurrent abnormality; 11/25 required surgery; high referral/selection risk.
Siebert et al., 2020 [10]	336 children/504 feet corrected without surgery by age 2	Retrospective selected cohort; mMean 8.8 y	Later surgery among initially successful Ponseti feet	122/336 later underwent surgery; estimates conditional on successful correction at age 2.
Gelfer et al., 2024 [11]	293 children/432 feet	Multicenter observational cohort; mMedian review age 89 mo	Clinically adjudicated relapse and standardized core outcomes	Relapse reported in ~37% of feet; severity/outcomes differed by definition and follow-up.
McKay et al., 2012 [17]	39 patients/60 feet	Retrospective late-relapse cohort; fFinal mean age 23.3 y	Late relapse after initially Ponseti-treated idiopathic clubfoot	41% reported activity-related pain; 18% limited function; repeat operations occurred.
van Praag et al., 2018 [36]	71 eligible; 35 assessed (49 feet)	Retrospective recurrence follow-up; mMean 89.6 mo	Recasting following initial Ponseti correction	26/35 reassessed children met a specified clinical correction endpoint after recasting.
Gray et al., 2014 [40]	20 TATT children/24 feet; 12 controls	Prospective nonrandomized comparison; 12 mo (19/20 retained)	Persistent dynamic supination after Ponseti correction	Muscle balance and loading improved; 2/19 assessed children had new recurrence.
Sangiorgio et al., 2017 [41]	191 children/94 with relapse	Prospective observational cohort; mMean 4.3 y	First and repeated clinical recurrences after Ponseti	94/191 relapsed; 36/94 relapsed children underwent TATT; possible overlap with Zionts.
Goldstein et al., 2015 [37]	86 analyzed children/134 feet (173 eligible)	Retrospective prognostic cohort; mMean 58.8 mo	Factors predicting later surgery after Ponseti	28/86 children underwent secondary surgery; substantial follow-up loss (87/173).
Hemo et al., 2021 [38]	333 children/500 feet	Retrospective analysis of registry; 5–20 y	Primary Ponseti initial correction followed for surgery	82/333 children underwent surgery; higher baseline severity and casting burden associated.

Reports are not assumed to represent independent clinical cohorts. Ponseti-treated subgroups are distinguished from mixed-treatment populations when separable.

3.7. Types of Surgery

3.7.1. Repeat Achilles Tenotomy

When recurrent equinus remained after renewed manipulation and casting, repeat Achilles tenotomy or lengthening was the most consistently reported targeted intervention [2,5,9,12,39]. Local protocols used minimum dorsiflexion targets, including 15° in some cohorts, but none directly compared alternative angular thresholds. Dobbs et al. performed repeat tenotomy in six children after renewed casting failed to restore the required dorsiflexion and Ramírez et al. reported repeat Achilles procedures, sometimes combined with TATT, in feet that remained incompletely corrected [5,39]. Age, prior tendon procedures, tendon tissue quality and associated fixed components informed the choice between percutaneous and open techniques. The surgical indication is therefore residual structural equinus, not a universal number of casts or recurrences.

3.7.2. Tibialis Anterior Tendon Transfer

Tibialis anterior tendon transfer (TATT) addresses persistent dynamic supination in a foot whose fixed deformity has first been corrected; it should not be expected to correct a rigid foot [7,9,12,40]. Gray et al. prospectively followed 20 children receiving TATT, 14 after preoperative repeat casting. Nineteen were assessed at 12 months: the eversion-to-inversion strength ratio and measures of plantar loading and function improved, but limitations in ankle motion and posture remained compared with nonoperative controls [40];

five feet underwent concomitant posterior lengthening and two children developed recurrent deformity treated with further casting [40]. Holt et al. found favorable adult function in 14 traced TATT recipients 37–55 years after childhood treatment; however, only 35 of 126 potentially eligible patients in the entire source cohort were available for long-term reassessment [29]. These observations support the anatomical rationale for TATT without proving causal superiority or universal long-term durability.

TATT is not a definitive safeguard against every subsequent recurrence. Masrouha and Morcuende documented further relapse in 10 of 66 children (15.2%), involving 15 of 102 feet, after TATT for idiopathic post-Ponseti recurrence; most episodes were treated conservatively, although selected patients required additional procedures [16]. The series included children later identified with neuromuscular abnormalities, underscoring the need to reconsider the underlying phenotype when the foot repeatedly relapses.

3.7.3. Posterior, Posteromedial, Subtalar and Limited Releases

The frequency and extent of release reflected both deformity rigidity and the definition of a surgical endpoint. Morcuende et al. reported extensive corrective surgery in 4 of 157 children (2.5%), while in the untreated-at-presentation subgroup of Göksan et al. joint release was required in 3 of 102 feet (2.9%) [2,32]. In contrast, Ošťádal et al. reported surgery for recurrent deformity in 82 of 195 children (42.1%) and 111 of 303 feet (36.6%), with substantial variation in duration of surveillance and operative practice [33]. These figures describe different case mixes, follow-up intervals and procedural thresholds, not a direct comparison of surgical efficacy. Fixed equinus, hindfoot varus and persistent adduction should remain separate from isolated dynamic supination when discussing the rationale for open release. Table 2 summarizes the reported anatomical indications for treatment, distinguishing explicit local criteria from observed clinical practice and the authors' interpretations of indirect evidence.

Table 2. Phenotype-anchored decision points in recurrent idiopathic clubfoot: reported indications, procedural targets, and evidentiary boundaries.

Clinical Phenotype	Decision-Defining Finding	Reported Treatment and Target	Basis of Indication/Evidence	What Remains Unproven
Residual deformity/incomplete correction	The relevant component never fully corrected; no documented interval of satisfactory alignment.	Reassess initial correction and each fixed component. Recast if reducible; treat persistent contracture selectively.	Clinical classification; reported diagnostic distinction in Halanski [34] and phenotype categories in Bhaskar [13].	A proposed timing distinction does not establish an objective diagnostic cutoff or indicate a specific operation.
Passively correctable recurrence	Previously corrected alignment reappears but can be restored by gentle manipulation; examine brace fit and tolerance.	Repeat Ponseti casting and optimize foot-abduction bracing; reassess remaining deformity before considering surgery.	Observed management in Ponseti cohorts [2,5,9,12,36]; outcomes use different definitions.	Neither a universal recasting success rate nor a relapse-count threshold is validated.
Persistent equinus after renewed correction	Ankle dorsiflexion remains restricted after correction of the other components; assess Achilles contracture.	Consider repeat percutaneous Achilles tenotomy or tendon lengthening, selected for age, previous procedures and tissue quality.	Explicit local criterion: <15° dorsiflexion after up to three casts in Zionts [9]. Descriptive use in Dobbs [5] and Ramírez [39].	Local angular targets and casting counts were not compared or validated across patient groups.
Dynamic supination with passive correction	Gait-related active supination in an otherwise passively corrected, supple	Consider tibialis anterior tendon transfer (TATT) after structural correction; correct coexisting	Reported phenotype-based indication [7,9,16,40]; Gray [40]	Selection bias, concomitant procedures and re-recurrence preclude claims of causal

	foot; check for residual fixed deformity.	fixed components separately.	provides prospective functional data.	superiority or permanent correction.
Fixed or multidimensional recurrence	Irreducible equinus, varus and/or adduction despite appropriate correction attempts; pain and scarring modify goals.	Individualize limited release or more extensive structural correction to the remaining deformity; define functional goals.	Descriptive direct evidence [13,33]; reconstructive techniques in historical series are contextual [20–25].	No head-to-head evidence supports a particular procedure or escalation after a given number of relapses.
Boundary condition: previously operated salvage feet	Severe stiffness, pain, extensive postoperative scarring or reconstruction after a non-Ponseti pathway.	Specialist structural assessment; salvage techniques only for clearly defined functional objectives.	Context only: historical/nonexchangeable cohorts [20–25], not direct post-Ponseti recurrence evidence.	Outcomes cannot be transferred to supple idiopathic Ponseti-treated feet or used to validate surgical thresholds.

Indications describe local practice or clinical reasoning and must not be interpreted as validated surgical thresholds. Individual feet may have more than one deformity component.

3.8. Procedure-Specific Outcomes and Complications

Procedure-specific outcomes were heterogeneous and could not be reduced to a single rate of "success". Gray et al. reported two recurrences among 19 children seen 12 months after TATT, while Masrouha and Morcuende observed further recurrence in 10 of 66 children over longer follow-up [16,40]. Among 39 patients (60 feet) treated for late recurrence, McKay et al. reported activity-related pain in 41% and functional limitation in 18%, with five feet requiring revision surgery after TATT and two ultimately undergoing triple arthrodesis [17]. The multicenter CoCo study observed relapse in 37% of feet and poorer clinical and quality-of-life outcomes among those with relapse, but did not provide a causal comparison between corrective strategies [11]. Follow-up, baseline severity, definitions of recurrence and concomitant procedures differed too substantially for pooling.

The surveillance cohorts describe the subsequent treatment burden rather than effectiveness of one intervention against another. Siebert et al. reported surgery in 122 of 336 children (36.3%) after successful correction at age two years; 79 underwent surgery between ages two and five, while some children later reappeared in the older surgical interval and must not be counted twice [10]. Goldstein et al. reported surgery in 28 of 86 analyzed children, compared with 82 of 333 children and 119 of 500 feet in Hemo et al. [37,38]. These estimands differ in unit, observation time, eligibility and surgical definition. They were therefore presented separately, without pooling patient and foot denominators or equating secondary surgery with clinical relapse. Study-specific outcomes, original denominators and descriptive confidence intervals are summarized in Table 3. Differences in clinical endpoints and follow-up precluded a meaningful pooled estimate. Rates of later surgery differed across cohorts with distinct eligibility criteria, observation periods and procedural definitions (Figure 3). These proportions describe treatment burden rather than comparative effectiveness.

Table 3. Selected study-specific recurrence and treatment outcomes: original denominators and descriptive Wilson 95% confidence intervals.

Outcome Domain	Study	Study-Defined Endpoint	Numerator/Denominator	% (95% CI)	Follow-Up/Key Caveat
Recurrence	Morcuende [2]	Clinical relapse	17/157 children	10.8% (6.9–16.7%)	Mean 26 mo
Recurrence	Dobbs [5]	Clinical relapse	16/51 children	31.4% (20.3–45.0%)	Mean 26.7 mo
Recurrence	Göksan [32]	Clinical relapse, untreated subgroup	27/102 feet	26.5% (18.9–35.8%)	Mean 46 mo · Prior-treatment cohort excluded
Recurrence	Zionts [9]	Clinical recurrence	40/84 feet	47.6% (37.3–58.2%)	Mean 37.9 mo · All recurred feet recast

Recurrence	Sangiorgio [41]	At least one relapse	94/191 children	49.2% (42.2–56.2%)	Mean 4.3 y
Recurrence	Gremminger [12]	At least one clinical relapse	97/268 children	36.2% (30.7–42.1%)	FU differs by relapse
Recasting	van Praag [36]	Clinically well corrected at reassessment	26/35 children	74.3% (57.9–85.8%)	Mean 89.6 mo · Only 35/71 assessed
Recasting	Gremminger [12]	No paper-defined surgery after relapse	74/97 children	76.3% (66.9–83.6%)	Relapse mean 91.5 mo · Repeat percutaneous tenotomy counted as non-surgical
Later surgery	Ošťádal [33]	Surgery after recurrent deformity	82/195 children	42.1% (35.3–49.1%)	Variable, up to 7 y
Later surgery	Goldstein [37]	Surgery beyond initial tenotomy	28/86 children	32.6% (23.6–43.0%)	≥3 y · 87/173 missing FU; right-foot analytical rule
Later surgery	Siebert [10]	Surgery after age-2 success	122/336 children	36.3% (31.3–41.6%)	Mean 8.8 y · Selected initially successful cohort
Later surgery	Hemo [38]	Further surgery	82/333 children	24.6% (20.3–29.5%)	5–20 y
Later surgery	Gremminger [12]	Paper-defined surgery	23/268 children	8.6% (5.8–12.5%)	≥1 y · Results count; source abstract inconsistent
After TATT	Masrouha [16]	Re-relapse following TATT	10/66 children	15.2% (8.4–25.7%)	Mean 6.8 y
After TATT	Gray [40]	Re-recurrence at 12 months	2/19 children	10.5% (2.9–31.4%)	12 mo · Nonrandomized; concomitant releases

Intervals express sampling precision only; they do not correct for attrition, bilateral correlation, confounding by indication or overlapping enrolment. Outcome types must not be pooled.

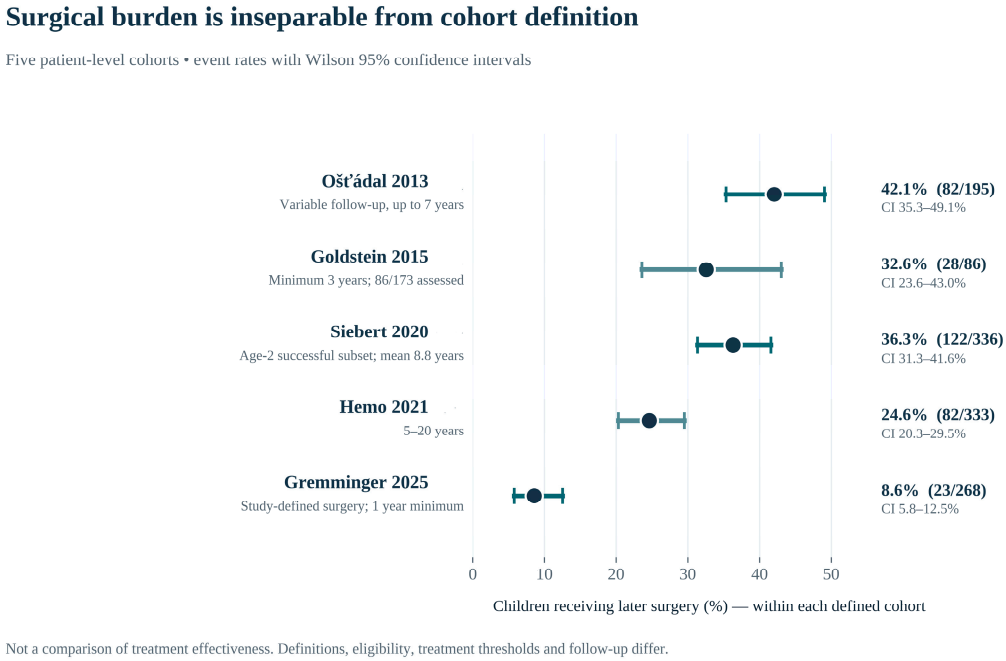

Figure 3. Subsequent surgical treatment across selected Ponseti-treated cohorts. Patient-level surgery proportions with Wilson 95% confidence intervals, shown without meta-analysis. Follow-up, study selection, definitions of surgery and treatment thresholds differed across cohorts [10,12,33,37,38]. Gremminger et al. [12] excluded repeat percutaneous tenotomy from its primary surgical endpoint; the plotted numerator follows the Results section. Between-study differences must not be interpreted as comparative effectiveness.

4. Discussion

A recurrence is a clinical event, not an operative diagnosis. Its relevance depends on whether the foot remains flexible, has persistent equinus, develops gait-associated dynamic supination or has become structurally fixed. This distinction is the review's clinical contribution: relapse count may inform prognosis, but the deformity remaining after reassessment determines the surgical target. The literature already supports renewed casting and selective tendon procedures [2,5,9,12,36,40]; what has been missing is a transparent separation between the outcome of recasting, the rationale for operative escalation and the fundamentally different evidence derived from rigid or previously operated feet. The current synthesis does not prove that a phenotype-based strategy is superior, but it shows why "surgery after the second relapse" is an inadequate universal instruction. Relapse count alone does not describe passive flexibility, hindfoot alignment, active muscle imbalance or whether the foot remains suitable for effective bracing.

Repeat casting can be more informative than another binary failure endpoint: it may restore correction while revealing which deformity components remain resistant. That interpretation is clinically plausible, although renewed casting has not been validated as a diagnostic test. The Toronto cohorts reported different endpoints and overlapping recruitment periods and Gremminger et al. did not classify repeat percutaneous tenotomy as surgery [12,36]. Thus, the apparent convergence near three-quarters does not establish a pooled success probability. Once recorrection has been attempted when appropriate, the next question becomes whether the remaining problem is persistent equinus, fixed varus or adduction or dynamic supination. Claims-based intervention patterns provide context but cannot answer this phenotype-specific question [31].

Brace adherence remains central to maintaining correction. Dobbs et al., Haft et al., Ramírez et al. and Bor et al. consistently associated brace difficulty or nonadherence with recurrence or additional treatment [5,8,35,39]. This relationship should not be reduced to parental behavior alone. Brace fit, discomfort, access to orthotic services, socioeconomic constraints, caregiver understanding and the ability of a residual deformity to tolerate the brace may all contribute. Clinically, recurrence during bracing should therefore prompt assessment of the foot and the treatment system around the family, not simply attribution of blame.

The operative evidence supports a staged distinction between persistent equinus and dynamic muscle imbalance. Repeat Achilles tenotomy or lengthening was used when equinus remained after renewed casting, although age, previous tenotomy, tissue quality and the threshold for adequate dorsiflexion varied across studies [2,5,9,12,17]. Within directly applicable Ponseti cohorts, tibialis anterior tendon transfer was primarily directed towards persistent dynamic supination after passive structural correction had been achieved [7,9,16,40]. Contemporary expert consensus further emphasizes careful identification of the dynamic component before selecting tendon transfer [42]. This sequence matters: tendon transfer should preserve a correction, not be asked to create one.

The strength of the TATT literature lies in the consistency of the indication, not in a proven comparative advantage over all alternatives. Long-term observational follow-up after TATT has been reported by Holt et al., but substantial attrition and selection limit its generalizability [14]. Gray et al. add prospective evidence of improved eversion-to-inversion balance, plantar loading and patient-reported outcomes within 12 months; although ankle motion and posture did not entirely normalize, some feet underwent concomitant lengthening and two children had recurrent deformity [40]. Masrouha and Morcuende reported further recurrence after transfer in 15.2%, reinforcing the need for continued surveillance [16]. Together, these data support matching TATT to a dynamic, passively correctable phenotype and argue against using tendon transfer to force the correction of a rigid foot. They do not establish that early transfer after a specific recurrence count prevents subsequent relapse.

Historical reconstructive studies illuminate the consequences of a different clinical state. After extensive earlier surgery, a rigid, scarred, painful or multiply operated foot may require release, osteotomy, gradual correction or fusion to obtain a plantigrade, shoeable foot [20–25]. These cohorts differ fundamentally from the child whose recurrence remains supple after modern Ponseti care. They belong in the discussion of the limits of generalizability, not in the pooled or descriptive denominators of direct post-Ponseti relapse evidence. Similarly, non-idiopathic cases and expert reviews may define important boundary conditions but cannot validate an operative threshold in idiopathic clubfoot [28,29,43–45].

4.1. Proposed Phenotype-Based Clinical Framework

The first question in recurrent clubfoot is whether correction was ever fully achieved. Persistent deformity and the return of a previously corrected component may appear similar, but they represent different clinical problems. Once this distinction has been established, examination should identify which components remain flexible, whether dynamic supination is present during gait and how the foot responds to bracing and previous treatment.

When structural correction remains achievable, renewed Ponseti casting can be considered before operative escalation [2,5,9,12,36]. Residual equinus may justify repeat Achilles tenotomy or lengthening, whereas tibialis anterior tendon transfer is directed towards persistent dynamic supination in a passively corrected foot [9,16,40]. Fixed or severely scarred deformities require a different discussion, balancing the potential functional benefit of reconstruction against the morbidity of more extensive procedures.

This approach is intended to organize clinical assessment rather than impose a mandatory treatment sequence. Severe, painful or irreducible deformity may warrant early specialist surgical evaluation, while recurrence count alone should never determine the operation. The framework remains a clinical synthesis and its effect on long-term correction, function and subsequent surgery requires prospective validation.

4.2. Strengths

This review focuses on a clinically important decision that is obscured when recurrence, repeat treatment and surgery are treated as equivalent endpoints. Its contribution is the separation of residual deformity from true relapse and of passive correctability from dynamic imbalance, with direct idiopathic Ponseti evidence kept distinct from historical or salvage contexts. The resulting synthesis seeks to clarify what the literature can support and where treatment choices remain dependent on judgment rather than validated comparative evidence.

4.3. Limitations

The interpretation of this review is constrained by inconsistent definitions of relapse, surgery and treatment success; highly variable follow-up; and nonrandom treatment assignment driven by deformity severity. Some institutional cohorts may share patients: Haft/Halanski, Zionts/Sangiorgio, van Praag/Gremminger and possibly contributors to the multicenter CoCo cohort warrant special caution [9–12,34–36,41]. Missing outcome data are substantial in several key studies, including van Praag (35 of 71 reassessed), Goldstein (86 of 173 eligible followed for at least three years) and the very long-term Holt cohort (35 of 126 traced) [14,36,37]. Bilateral feet were often treated as independent observations; the reported descriptive confidence intervals do not correct that dependence. Finally, clinical improvement after an intervention cannot be interpreted as superiority over another strategy in these uncontrolled or selectively operated populations. The proposed

phenotype-based framework therefore remains a clinical synthesis rather than a prospectively validated algorithm.

4.4. Future Research

Prospective multicenter studies should distinguish persistent residual deformity, first recurrence and subsequent re-recurrence, while documenting the timing and completeness of initial correction. Standardized assessments should include passive dorsiflexion, reducibility of individual deformity components, gait-associated dynamic supination, age, previous treatment and objectively measured brace wear where feasible. Studies should prespecify whether treatment success means restored plantigrade alignment, maintenance without surgery, absence of re-recurrence, pain reduction or improved patient-reported function and should document outcomes separately by child and by foot. Adequate follow-up and explicit handling of bilateral correlation are essential. Comparative studies should evaluate phenotype-specific treatment strategies rather than regard "any surgery" as a homogeneous endpoint.

5. Conclusions

Recurrence after Ponseti treatment does not, by itself, identify the need for surgery. The available studies indicate that the clinically relevant question is what deformity persisted after reassessment and, when appropriate, renewed correction. A correctable recurrence may respond to further casting; persistent equinus and dynamic supination may justify targeted Achilles procedures or tibialis anterior tendon transfer, whereas fixed deformity requires a different reconstructive strategy. Relapse number may signal prognosis, but no study validated a numerical threshold at which surgery is preferable. Because the evidence is heterogeneous and predominantly observational, the proposed phenotype-based approach should guide clinical questioning rather than be regarded as a proven algorithm. Its long-term functional value requires prospective testing.

Supplementary Materials: The following supporting information can be downloaded at https://www.mdpi.com/article/10.3390/children13121679/s1. Supplementary Table S1: Design- and outcome-specific methodological appraisal of studies included in the systematic review.

Author Contributions: Conceptualization, M.D.P. and D.A.M.; methodology, D.A.M. and M.D.P.; software, G.G.; validation, N.G., L.M. and G.G.; formal analysis, D.A.M.; investigation, G.G. and D.A.M.; resources, L.M.; data curation, D.A.M. and N.G.; writing—original draft preparation, D.A.M., G.G. and L.M.; writing—review and editing, M.D.P. and I.S.; visualization, N.G.; supervision, I.S.; project administration, M.D.P. All authors have read and agreed to the published version of the manuscript.

Funding: This research received no external funding.

Institutional Review Board Statement: Not applicable.

Informed Consent Statement: Not applicable.

Data Availability Statement: The complete extraction dataset, cohort-classification file and analysis code are available from the corresponding author on reasonable request.

Conflicts of Interest: The authors declare no conflicts of interest.

Abbreviations

The following abbreviations are used in this manuscript:

ABS	Amniotic band syndrome

AFO	Ankle–foot orthosis
CAVE	Cavus, Adduction, Varus, Equinus
CoCo	Core outcome Clubfoot
JBI	Joanna Briggs Institute
NOS	Newcastle–Ottawa Scale
PMR	Posteromedial release
PRISMA	Preferred Reporting Items for Systematic Reviews and Meta-Analyses
PROSPERO	International Prospective Register of Systematic Reviews
QUIPS	Quality In Prognosis Studies
RoB 2	Risk of Bias 2 tool
ROBINS-I	Risk Of Bias In Non-randomized Studies-of Interventions
TAL	Tendo-Achilles lengthening
TATT	Tibialis Anterior Tendon Transfer

References

1. Laaveg, S.J.; Ponseti, I.V. Long-Term Results of Treatment of Congenital Club Foot. *J. Bone Jt. Surg. Am. Vol.* **1980**, *62*, 23–31.
2. Morcuende, J.A.; Dolan, L.A.; Dietz, F.R.; Ponseti, I.V. Radical Reduction in the Rate of Extensive Corrective Surgery for Clubfoot Using the Ponseti Method. *Pediatrics* **2004**, *113*, 376–380. https://doi.org/10.1542/peds.113.2.376.
3. Ponseti, I.V.; Smoley, E.N. The Classic: Congenital Club Foot: The Results of Treatment. *Clin. Orthop. Relat. Res.* **2009**, *467*, 1133–1145. https://doi.org/10.1007/s11999-009-0720-2.
4. Cooper, D.M.; Dietz, F.R. Treatment of Idiopathic Clubfoot. A Thirty-Year Follow-up Note. *J. Bone Jt. Surg.* **1995**, *77*, 1477–1489. https://doi.org/10.2106/00004623-199510000-00002.
5. Dobbs, M.B.; Rudzki, J.R.; Purcell, D.B.; Walton, T.; Porter, K.R.; Gurnett, C.A. Factors Predictive of Outcome After Use of the Ponseti Method for the Treatment of Idiopathic Clubfeet. *J. Bone Jt. Surg.-Am. Vol.* **2004**, *86*, 22–27. https://doi.org/10.2106/00004623-200401000-00005.
6. Richards, B.S.; Faulks, S.; Rathjen, K.E.; Karol, L.A.; Johnston, C.E.; Jones, S.A. A Comparison of Two Nonoperative Methods of Idiopathic Clubfoot Correction: The Ponseti Method and the French Functional (Physiotherapy) Method. *J. Bone Jt. Surg.-Am. Vol.* **2008**, *90*, 2313–2321. https://doi.org/10.2106/JBJS.G.01621.
7. Radler, C.; Mindler, G.T.; Riedl, K.; Lipkowski, C.; Kranzl, A. Midterm Results of the Ponseti Method in the Treatment of Congenital Clubfoot. *Int. Orthop. (SICOT)* **2013**, *37*, 1827–1831. https://doi.org/10.1007/s00264-013-2029-8.
8. Bor, N.; Coplan, J.A.; Herzenberg, J.E. Ponseti Treatment for Idiopathic Clubfoot: Minimum 5-Year Followup. *Clin. Orthop. Relat. Res.* **2009**, *467*, 1263–1270. https://doi.org/10.1007/s11999-008-0683-8.
9. Zionts, L.E.; Frost, N.; Kim, R.; Ebramzadeh, E.; Sangiorgio, S.N. Treatment of Idiopathic Clubfoot: Experience with the Mitchell-Ponseti Brace. *J. Pediatr. Orthop.* **2012**, *32*, 706–713. https://doi.org/10.1097/BPO.0b013e3182694f4d.
10. Siebert, M.J.; Karacz, C.M.; Richards, B.S. Successful Ponseti-Treated Clubfeet at Age 2 Years: What Is the Rate of Surgical Intervention After This? *J. Pediatr. Orthop.* **2020**, *40*, 597–603. https://doi.org/10.1097/BPO.0000000000001614.
11. Gelfer, Y.; Cavanagh, S.E.; Bridgens, A.; Ashby, E.; Bouchard, M.; Leo, D.G.; Eastwood, D.M. The Core Outcome Clubfoot (CoCo) Study: Relapse, with Poorer Clinical and Quality of Life Outcomes, Affects 37% of Idiopathic Clubfoot Patients: An International Multicentre Observational Study. *Bone Jt. J.* **2024**, *106-B*, 735–743. https://doi.org/10.1302/0301-620X.106B7.BJJ-2023-1258.R1.
12. Gremminger, R.; Cristofaro, C.; Sadat, M.; Bouchard, M. Rate and Predictors of Relapse and Surgery in Idiopathic Clubfeet after Successful Ponseti Treatment in Infancy: A Single Centre, Retrospective, Comparative Study. *Bone Jt. Open* **2025**, *6*, 1275–1281. https://doi.org/10.1302/2633-1462.610.BJO-2025-0170.R1.
13. Bhaskar, A.; Patni, P. Classification of Relapse Pattern in Clubfoot Treated with Ponseti Technique. *Indian J. Orthop.* **2013**, *47*, 370–376. https://doi.org/10.4103/0019-5413.114921.
14. Holt, J.B.; Oji, D.E.; Yack, H.J.; Morcuende, J.A. Long-Term Results of Tibialis Anterior Tendon Transfer for Relapsed Idiopathic Clubfoot Treated with the Ponseti Method: A Follow-up of Thirty-Seven to Fifty-Five Years. *J. Bone Jt. Surg.* **2015**, *97*, 47–55. https://doi.org/10.2106/JBJS.N.00525.
15. Farsetti, P.; Caterini, R.; Mancini, F.; Potenza, V.; Ippolito, E. Anterior Tibial Tendon Transfer in Relapsing Congenital Clubfoot: Long-Term Follow-Up Study of Two Series Treated with a Different Protocol. *J. Pediatr. Orthop.* **2006**, *26*, 83–90. https://doi.org/10.1097/01.bpo.0000188999.21427.fb.
16. Masrouha, K.Z.; Morcuende, J.A. Relapse After Tibialis Anterior Tendon Transfer in Idiopathic Clubfoot Treated by the Ponseti Method. *J. Pediatr. Orthop.* **2012**, *32*, 81–84. https://doi.org/10.1097/BPO.0b013e31823db19d.

17. McKay, S.D.; Dolan, L.A.; Morcuende, J.A. Treatment Results of Late-Relapsing Idiopathic Clubfoot Previously Treated with the Ponseti Method. *J. Pediatr. Orthop.* **2012**, *32*, 406–411. https://doi.org/10.1097/BPO.0b013e318256117c.
18. Faldini, C.; Traina, F.; Nanni, M.; Sanzarello, I.; Borghi, R.; Perna, F. Congenital Idiopathic Talipes Equinovarus before and after Walking Age: Observations and Strategy of Treatment from a Series of 88 Cases. *J. Orthop. Traumatol.* **2016**, *17*, 81–87. https://doi.org/10.1007/s10195-015-0377-4.
19. Zeifang, F.; Carstens, C.; Schneider, S.; Thomsen, M. Continuous Passive Motion versus Immobilisation in a Cast after Surgical Treatment of Idiopathic Club Foot in Infants: A PROSPECTIVE, BLINDED, RANDOMISED, CLINICAL STUDY. *J. Bone Jt. Surg. Br. Vol.* **2005**, *87-B*, 1663–1665. https://doi.org/10.1302/0301-620X.87B12.16551.
20. Al-Aubaidi, Z.; Lundgaard, B.; Pedersen, N.W. Anterior Distal Tibial Epiphysiodesis for the Treatment of Recurrent Equinus Deformity After Surgical Treatment of Clubfeet. *J. Pediatr. Orthop.* **2011**, *31*, 716–720. https://doi.org/10.1097/BPO.0b013e31822109b6.
21. Chu, A.; Chaudhry, S.; Sala, D.A.; Atar, D.; Lehman, W.B. Calcaneocuboid Arthrodesis for Recurrent Clubfeet: What Is the Outcome at 17-Year Follow-Up? *J. Child. Orthop.* **2014**, *8*, 43–48. https://doi.org/10.1007/s11832-014-0557-4.
22. Ferreira, R.C.; Costa, M.T.; Frizzo, G.G.; Santin, R.A.L. Correction of Severe Recurrent Clubfoot Using a Simplified Setting of the Ilizarov Device. *Foot Ankle Int.* **2007**, *28*, 557–568. https://doi.org/10.3113/FAI.2007.0557.
23. El-Mowafi, H.; El-Alfy, B.; Refai, M. Functional Outcome of Salvage of Residual and Recurrent Deformities of Clubfoot with Ilizarov Technique. *Foot Ankle Surg.* **2009**, *15*, 3–6. https://doi.org/10.1016/j.fas.2008.04.007.
24. Franke, J.; Grill, F.; Hein, G.; Simon, M. Correction of Clubfoot Relapse Using Ilizarov's Apparatus in Children 8–15 Years Old. *Arch. Orthop. Trauma Surg.* **1990**, *110*, 33–37. https://doi.org/10.1007/BF00431363.
25. Lampasi, M.; Bettuzzi, C.; Palmonari, M.; Donzelli, O. Transfer of the Tendon of Tibialis Anterior in Relapsed Congenital Clubfoot: LONG-TERM RESULTS IN 38 FEET. *J. Bone Jt. Surgery. Br. Vol.* **2010**, *92-B*, 277–283. https://doi.org/10.1302/0301-620X.92B2.22504.
26. Van Schelven, H.; Moerman, S.; Van Der Steen, M.; Besselaar, A.T.; Greve, C. Prognostic Factors for Recurrent Idiopathic Clubfoot Deformity: A Systematic Literature Review and Meta-Analysis. *Acta Orthop.* **2021**, *93*, 11–28. https://doi.org/10.1080/17453674.2021.1982576.
27. Page, M.J.; McKenzie, J.E.; Bossuyt, P.M.; Boutron, I.; Hoffmann, T.C.; Mulrow, C.D.; Shamseer, L.; Tetzlaff, J.M.; Akl, E.A.; Brennan, S.E.; et al. The PRISMA 2020 Statement: An Updated Guideline for Reporting Systematic Reviews. *BMJ* **2021**, *372*, n71. https://doi.org/10.1136/bmj.n71.
28. Carpiaux, A.M.; Hosseinzadeh, P.; Muchow, R.D.; Iwinski, H.J.; Walker, J.L.; Milbrandt, T.A. The Effectiveness of the Ponseti Method for Treating Clubfoot Associated with Amniotic Band Syndrome. *J. Pediatr. Orthop.* **2016**, *36*, 284–288. https://doi.org/10.1097/BPO.0000000000000444.
29. Bhatti, A.; Rahman, S.A.U.; Mazar, S.; Ali, P.; Bhatti, M.Y. Outcome of Tibialis Anterior Tendon Transfer in Recurrent Relapsed Clubfoot Deformity with Concomitant Peroneal Nerve Dysfunction. *Pak. J. Med. Sci.* **2026**, *42*, 414–422. https://doi.org/10.12669/pjms.42.2.12956.
30. Stouten, J.H.; Besselaar, A.T.; Van Der Steen, M.C. Identification and Treatment of Residual and Relapsed Idiopathic Clubfoot in 88 Children. *Acta Orthop.* **2018**, *89*, 448–453. https://doi.org/10.1080/17453674.2018.1478570.
31. Hamad, C.D.; Wiener, J.; Liu, T.; Golzar, A.; Dajani, A.-H.J.; Kaelber, D.C.; Bernthal, N.M.; Sheppard, W.L.; Baghdadi, S.; Silva, M. Contemporary National Treatment Patterns for Clubfoot Relapse-Related Interventions: A Large Multi-Institutional Cohort. *BMC Musculoskelet. Disord.* **2026**, *27*, 638. https://doi.org/10.1186/s12891-026-10032-7.
32. Göksan, S.B.; Bursalı, A.; Bilgili, F.; Sıvacıoğlu, S.; Ayanoğlu, S. Ponseti Technique for the Correction of Idiopathic Clubfeet Presenting up to 1 Year of Age. A Preliminary Study in Children with Untreated or Complex Deformities. *Arch. Orthop. Trauma Surg.* **2006**, *126*, 15–21. https://doi.org/10.1007/s00402-005-0070-9.
33. Ošťádal, M.; Chomiak, J.; Dungl, P.; Frydrychová, M.; Burian, M. Comparison of the Short-Term and Long-Term Results of the Ponseti Method in the Treatment of Idiopathic Pes Equinovarus. *Int. Orthop. (SICOT)* **2013**, *37*, 1821–1825. https://doi.org/10.1007/s00264-013-2033-z.
34. Halanski, M.A.; Maples, D.L.; Davison, J.E.; Huang, J.-C.; Crawford, H.A. Separating the Chicken from the Egg: An Attempt to Discern between Clubfoot Recurrences and Incomplete Corrections. *Iowa Orthop. J.* **2010**, *30*, 29–34.
35. Haft, G.F.; Walker, C.G.; Crawford, H.A. Early Clubfoot Recurrence After Use of the Ponseti Method in a New Zealand Population. *J. Bone Jt. Surg.* **2007**, *89*, 487–493. https://doi.org/10.2106/JBJS.F.00169.
36. Van Praag, V.M.; Lysenko, M.; Harvey, B.; Yankanah, R.; Wright, J.G. Casting Is Effective for Recurrence Following Ponseti Treatment of Clubfoot. *J. Bone Jt. Surg.* **2018**, *100*, 1001–1008. https://doi.org/10.2106/JBJS.17.01049.

37. Goldstein, R.Y.; Seehausen, D.A.; Chu, A.; Sala, D.A.; Lehman, W.B. Predicting the Need for Surgical Intervention in Patients with Idiopathic Clubfoot. *J. Pediatr. Orthop.* **2015**, *35*, 395–402. https://doi.org/10.1097/BPO.0000000000000282.
38. Hemo, Y.; Yavor, A.; Kalish, M.; Segev, E.; Wientroub, S. Ponseti Treated Idiopathic Clubfoot—Outcome Predictive Factors in the Test of Time: Analysis of 500 Feet Followed for Five to 20 Years. *J. Child. Orthop.* **2021**, *15*, 426–432. https://doi.org/10.1302/1863-2548.15.210156.
39. Ramírez, N.; Flynn, J.M.; Fernández, S.; Seda, W.; Macchiavelli, R.E. Orthosis Noncompliance After the Ponseti Method for the Treatment of Idiopathic Clubfeet: A Relevant Problem That Needs Reevaluation. *J. Pediatr. Orthop.* **2011**, *31*, 710–715. https://doi.org/10.1097/BPO.0b013e318221eaa1.
40. Gray, K.; Burns, J.; Little, D.; Bellemore, M.; Gibbons, P. Is Tibialis Anterior Tendon Transfer Effective for Recurrent Clubfoot? *Clin. Orthop. Relat. Res.* **2014**, *472*, 750–758. https://doi.org/10.1007/s11999-013-3287-x.
41. Sangiorgio, S.N.; Ebramzadeh, E.; Morgan, R.D.; Zionts, L.E. The Timing and Relevance of Relapsed Deformity in Patients with Idiopathic Clubfoot. *J. Am. Acad. Orthop. Surg.* **2017**, *25*, 536–545. https://doi.org/10.5435/JAAOS-D-16-00522.
42. Baskar, D.; Hosseinzadeh, P.; Mosca, V.; Bouchard, M.; Aroojis, A.; Arkader, A.; Cidambi, E.; Denning, J.; Eastwood, D.; Gantsoudes, G.; et al. Dynamic Supination in Congenital Clubfoot: A Modified Delphi Panel Approach to Standardizing Definitions and Indications for Treatment. *J. Pediatr. Orthop.* **2022**, *42*, e459–e465. https://doi.org/10.1097/BPO.0000000000002119.
43. Helmers, A.C. Die initiale Therapie beim kongenitalen Klumpfuß und beim Rezidiv. *Fuß Sprunggelenk* **2026**, *24*, 9–38. https://doi.org/10.1016/j.fuspru.2025.10.005.
44. De Pellegrin, M.; Marcucci, L.; Brogioni, L.; Prati, G. Surgical Treatment of Clubfoot in Children with Moebius Syndrome. *Children* **2021**, *8*, 310. https://doi.org/10.3390/children8040310.
45. Helmers, A.C. The Treatment of Neglected Clubfoot. *Foot Ankle Clin.* **2021**, *26*, 705–725. https://doi.org/10.1016/j.fcl.2021.07.004.

Disclaimer/Publisher's Note: The statements, opinions and data contained in all publications are solely those of the individual author(s) and contributor(s) and not of MDPI and/or the editor(s). MDPI and/or the editor(s) disclaim responsibility for any injury to people or property resulting from any ideas, methods, instructions or products referred to in the content.