children

MDPI

Review

ZNF711-Associated Neurodevelopmental Disorder in a 5-Year-Old Boy: A Case Report and Narrative Review of the Literature

Carmine Antini [1,2], Roberta Battini [1,2], Federica Batini [1], Lucia Pfanner [1], Matilde Barabino [1], Rosa Pasquariello [1], Stefano Pagano [1], Filippo Maria Santorelli [1] and Guja Astrea [1,*]

[1] Department of Developmental Neuroscience, IRCCS Stella Maris Foundation, Calambrone, 56128 Pisa, Italy; carmine.antini@fsm.unipi.it (C.A.); roberta.battini@fsm.unipi.it (R.B.); federica.batini@fsm.unipi.it (F.B.); lucia.pfanner@fsm.unipi.it (L.P.); matilde.barabino@fsm.unipi.it (M.B.); rosa.pasquariello@fsm.unipi.it (R.P.); stefano.pagano@fsm.unipi.it (S.P.); f.santorelli@fsm.unipi.it (F.M.S.)

[2] Department of Clinical and Experimental Medicine, University of Pisa, 56126 Pisa, Italy

* Correspondence: guja.astrea@fsm.unipi.it

Highlights

What are the main findings?

- Variants in *ZNF711* cause a rare form of non-syndromic X-linked intellectual disability, which appears mild to moderate in most cases described.
- No consistent structural neuroimaging abnormality has been established yet; epilepsy or epileptiform anomalies have been described in sporadic cases.

What are the implications of the main findings?

- Attributing pathogenicity to *ZNF711* variants remains challenging for clinicians given the lack of disease-specific markers.
- Proper attention should be given to *ZNF711* variants in cases of X-linked intellectual disability, as the disorder is of relatively recent discovery and remains understudied.

Abstract

Background/Objectives: Loss-of-function mutations in the *ZNF711* gene cause a rare form of X-linked intellectual disability. Only a few cases of the condition are reported, and two recent articles have broadened the clinical picture by describing new electrophysiological findings in the disorder. We report on the current literature findings and describe an additional case, presenting with a previously unreported mutation. **Methods**: As for the narrative review section, PubMed, Embase and Scopus were searched with no date restrictions to find previous reports on the disorder; two independent authors screened the articles and summarized their findings. No formal data analysis was conducted; only a narrative summary is given. We also describe the clinical case of a 5-year-old boy carrying a c.937C>T, p.(Arg313Ter) variant in the *ZNF711* gene. The functional profile was delineated using standardized national/international tests; brain MRI was performed using a clinical 3T machine. **Results**: The clinical picture in *ZNF711*-related intellectual disability is extremely variable. No specific clinical sign can give a high degree of suspicion, as the presentation appears non-specific. **Conclusions**: When evaluating familial pedigrees presenting with X-linked intellectual disability, the *ZNF711* gene should be kept in mind, both in cases of overt ID and in cases with borderline intellectual functioning. A thorough functional evaluation is of paramount importance in these cases, whereas instrumental examinations (brain MRI, EEG) should be performed according to clinical necessity.

Check for updates

Academic Editor: Anthony D. Slonim

Received: 20 October 2026
Revised: 17 November 2026
Accepted: 21 November 2026
Published: 24 November 2026

Copyright: © 2026 by the authors. Licensee MDPI, Basel, Switzerland. This article is an open access article distributed under the terms and conditions of the Creative Commons Attribution (CC BY) license.

Keywords: X-linked intellectual disability; *ZNF711*; neurodevelopmental disorder

1. Introduction

ZNF711, located on the X chromosome (Xq21.1; OMIM #314990), encodes a Krüppel-type C2H2 zinc finger protein [1]. *ZNF711* is expressed across various tissues, but it seems to be particularly crucial in neurodevelopment [1–4]. Truncating mutations in *ZNF711* were first suspected to cause X-linked intellectual disability (XLID) in 2009, by Tarpey and colleagues [5]. The role of *ZNF711* and the way in which pathogenic variants in *ZNF711* cause intellectual disability (ID) are still incompletely understood. *ZNF711* seems to act as a transcription activator when bound downstream of the transcription start site in CpG island promoters, either on its own or when bound to other co-factors [2]. Because ZFX proteins bind to a myriad of CpG island promoters, loss of *ZNF711* may cause severe defects in proliferation and down-regulation of essential "house-keeping" functions [1].

Additionally, *ZNF711* could act as a co-factor for the histone demethylase PHF8 [2], a protein that, in and of itself, is linked to ID when depleted [6,7]. *ZNF711* recruits PHF8 to promoters, and the interaction between *ZNF711* and PHF8 may stabilize the association of PHF8 with the histone tail and catalyze efficient demethylation from H3K9me2, which in turn has been associated with transcriptionally inactive genes.

In particular, *ZNF711* could compete with other co-factors to recruit PHF8 at the *KDM5C* promoter, which has been posited as a central hub in a pathogenic cascade involved in a variety of neurodevelopmental disorders (NDDs) [3].

Pathogenic variants in *ZNF711* are now well established as a cause of non-syndromic XLID and have also been associated with facial dysmorphism, macrocephaly, and NDDs, including speech impairment and autism spectrum disorder (ASD) [3,5,8,9]. *ZNF711*-related disorders are of relatively recent discovery and remain understudied and underreported. To further complicate matters, XLID itself only accounts for 5–10% of cases of ID in males [10], with *ZNF711*-related cases estimated to account for only 0.3% of cases of male ID [5], making the disorder exceedingly rare.

Due to the rarity of the disorder, only a few cases of *ZNF711*-associated intellectual disability have been described [5,8,9,11–15]. Unsurprisingly, the full spectrum of *ZNF711*-related NDDs is still under study, as new findings keep emerging and new cases are described. Recently, the description of four Italian cases has broadened the clinical spectrum of *ZNF711*-related disorders by describing new electrophysiological findings [11,12]. Clinicians, however, are left with little guidance when confronted with this rare condition. Inspired by our recent experience with one such case, we summarize the current knowledge on this disorder with the aim of providing clinicians and researchers with updated information on this rare cause of ID.

Although not classified as a review, we acknowledge that a brief section of the article authored by Minerva et al. [12] summarizes clinical cases related to *ZNF711* up to 2025. Considering the recent description of additional cases, with the present work, we aim to update the groundwork laid by our colleagues and, explicitly and methodically, compile a narrative review for clinical usability.

Additionally, we report on the clinical case we encountered: a 5-year-old boy harboring a novel mutation in *ZNF711*. We report on his clinical history and describe his cognitive, functional, and adaptive profile, as well as neuroimaging findings. To the best of our knowledge, there are 39 cases currently described worldwide. By reporting this case, we bring the total number of cases described worldwide to 40. We compare our case to previous reports and expand the current knowledge on this rare condition.

2. Materials and Methods

The literature review portion of our paper was conducted as follows. Scopus, Embase and PubMed were searched for relevant studies using «"*ZNF711*" OR "ZNF6" OR "MRX97 " OR "XLID97" OR "CMPX1"» as a search string on all datasets. The search was conducted on 30 October 2026; PubMed "All Fields", Scopus "Title and Abstract" and Embase "Broad search" were searched. No date restrictions were applied. As for the selection criteria, we included peer-reviewed original studies conducted on humans of any age reporting on the clinical pictures of subjects harboring a *ZNF711* mutation. Given the paucity of studies published, we did not impose stringent restrictions on the type of studies to include; we mainly found case series and case reports. We excluded studies published in languages other than English. Since the main aim of this work was to describe *ZNF711*-related XLID, we formally excluded studies on cells, animal models and cancer. We did, however, leverage those studies to discuss the role of the protein in the introduction section. Duplicates were automatically removed using Covidence [16]. Two independent raters (namely G.A. and C.A.) performed title and abstract screening, followed by full-text screening on Covidence. No formal data synthesis was performed. Relevant information was extracted from the selected articles on a data extraction sheet and summarized narratively.

When it comes to our case description, we wrote it after receiving informed consent from the parents. The patient was evaluated by a multidisciplinary team of clinicians, comprising a pediatric neurologist (G.A.), a medical resident in pediatric neurology (C.A.), a clinical psychologist (F.B.), a motor therapist (M.B.), a speech therapist (L.P.), a neuroradiologist (R.P.) and a clinical geneticist (S.P.). The patient was evaluated using standardized tests adequate for his chronological age, comprising the Vineland-II adaptive behavior scale [17], WPPSI-IV [18], and standardized logopedic tests for the Italian language [19–21].

3. Results

PubMed, Scopus, and Embase searches yielded 41, 66, and 123 results, respectively. A total of 112 studies were automatically marked as duplicates; 118 studies underwent title and abstract screening. After title and abstract screening, 21 reports were sought for retrieval, and full-text screening was performed on 21 articles. After full-text screening, nine articles were used to conduct a narrative summary of the literature concerning *ZNF711*-related intellectual disability.

All of the works reporting on *ZNF711* in the field of ID and NDDs were case reports or case series, namely nine of them [5,8,9,11–15,22], for a total of 39 cases described worldwide.

A summary of the clinical findings reported in previous case reports is given in Table 1. A case-by-case count, reporting individual patients, their variants, and the severity of their ID, is reported in Supplementary Table S1.

Table 1. A short summary of previous findings. A thorough appraisal of the case series is reported in the Discussion section.

Study	Number of Subjects Carrying a *ZNF711* Variant	Variant Described	Main Findings
Tarpey et al., 2009 [5]	10/208	*ZNF711* NM_001330574.2:c.2265T>A p.(Cys709*); NM_001330574.2:c.1543A>T p.(Arg515*)	208 cases of XLID. In 2 unrelated families, 10 members were found to carry a truncating *ZNF711* mutation, not present in healthy controls. ID was moderate. One case was suspected to carry the same variant but was not genotyped
Niranjan et al., 2015 [14]	1/82	NM_001330574.2:c.1940A>G p.(Asn601Ser)	*ZNF711* was confirmed to cause XLID in one additional case.

Table 1. *Cont.*

Study	Number of Subjects Carrying a *ZNF711* Variant	Variant Described	Main Findings
Van der Werf et al., 2017 [8]	11	NM_001330574.2:c.2192T>C p.(Phe685Serfs*7) NM_001330574.2:c.731T>C p.(Ile244Thr)	Two families carrying *ZNF711* mutations, for a total of 11 cases. 5/11 presented moderate ID, 6/11 presented mild ID.
Liang et al., 2017 [13]	1	8.05 Mb deletion at Xq21.1-21.31	17-year-old male with choroideremia, deafness, and ID. The patient carries an 8.05 Mb deletion in Xq21, spanning 12 OMIM genes. *ZNF711* might contribute to ID.
Wang et al., 2022 [9]	20	NM_001330574.2;c.2254T>C p.(Cys706Arg) NM_001330574.2:c.2299C>T p.(Arg721*) NM_001330574.2:c.1693G>T p.(Glu519*) NM_001330574.2:c.2365C>T p.(Arg743*) NM_001330574.2:c.2265T>A p.(Cys709*); NM_001330574.2:c.1543A>T p.(Arg515*)	20 cases. 17 had mild ID, 1 had moderate ID, 1 had above-average IQ; data were unavailable in 1. The authors describe both new cases and more kindreds from the two families in Tarpey et al.
Sahajpal et al., 2024 [22]	1	Duplication, genomic coordinates: 84,000,996-84,536,911 (hg19)	Microcephaly, inguinal hernia, seizures, attention deficit and hyperactivity disorder (ADHD), motor clumsiness.
Minerva et al., 2025 [12]	2	NM_001330574.2:c.65T>C p.(Ile22Thr)	Epilepsy reported as part of the clinical picture in *ZNF711*-related ID in two brothers.
Urciuoli et al., 2026 [11]	2	c NM_001330574.2:c.65T>C p.(Ile22Thr)	Two brothers. One has normal IQ, ASD, and isolated epileptiform abnormalities. His older brother is affected by epilepsy, moderate ID and speech delay.
Liu et al., 2026 [15]	1	NM_001330574.2:c.205G>T p.(Glu69*)	Moderate ID, ASD, hypotonia

The SANRA scale [23] is reported in Supplementary Figure S1.

3.1. Clinical History

Our patient, a 5-year-old male, is the only child of unrelated Italian parents. Maternal age at birth was 47; paternal age was 49. As for the family history, our patient's mother reported a brother affected by ID, which was initially of unknown origin, later discovered to be due to the same mutation harbored by our patient. The uncle, now over 50, still lives with his mother and does not have a job. His developmental milestones were reported as delayed, with independent walking reached at 18 months and speech reported as delayed, though his sister could not remember the exact age of first words.

The uncle was unavailable for clinical evaluation.

The mother also had an uncle with ID, whose genetic profile was never analyzed. The pregnancy was described as uneventful; delivery happened through C-section at 38 weeks and 5 days; the Apgar score at 1 and 5 min was 9, weight 2500 g and length 49 cm. No major complications were described during the perinatal period. No difficulties in nursing or weaning were noted, and no difficulties in chewing and swallowing were reported. A patent ductus arteriosus with no hemodynamic impact was discovered soon after birth, and follow-up with cardiac ultrasounds was recommended.

Our patient showed mild delay in reaching developmental milestones; independent sitting was reached at 11 months of age, and independent walking was reached at 18 months. First words emerged at 24 months of age. No anomalies in eye contact were observed by

the parents. The patient first reached clinical attention at 15 months of age, when a neuropsychologist determined a mental age of 9 months using the Griffiths-III developmental scale (GMDS-ER [24]). He thus started attending physiotherapy, psychomotor treatment and speech therapy.

3.2. Genetic Studies

The family first received genetic counseling at the genetics department of Perugia Hospital; he later reached the attention of our clinical geneticist at age 5.

At age 3, the patient underwent *FMR1* trinucleotide repeat analysis and arrayCGH analysis, both of which yielded normal results. Subsequently, the patient underwent whole-exome sequencing. This analysis identified the hemizygous c.937C>T, p.(Arg313Ter) variant in the *ZNF711* gene (GnomAD f = 0). This variant lies in exon 7, and it is not listed on LOVD. Subsequent segregation analysis established that this variant was maternally inherited. Co-segregation with the affected maternal uncle and novelty of the mutation support PM2 at supporting strength. As heterozygous carrier findings, the following heterozygous variants were identified: NM_016580.4:c.2038del p.(Gln680Argfs*12) in the *PCDH12* gene, and NM_001329943.3:c.428del p.(Phe144Leufs*4) in the *KIAA0586* gene; the c.428del in *KIAA0586* is a recurrent Joubert allele with recurrence-risk implications. Following dedicated genetic counseling, these variants were interpreted as non-contributory to the patient's clinical phenotype.

The familial pedigree is reported in Figure 1.

The c.937C>T variant in the *ZNF711* gene is a nonsense variant that introduces a premature translation termination codon at amino acid position 313 of a total of 761 amino acids (Figure 2); we also report the Sanger chromatogram (Figure 3). It results in a truncating transcript and loss of function of the protein, which is a known mechanism of the X-linked disease. Review, classification, and interpretation of the variant were made according to the American College of Medical Genetics and Genomics (ACMG/AMP) guidelines (Pathogenic, PVS1, PM2, PP1) [25].

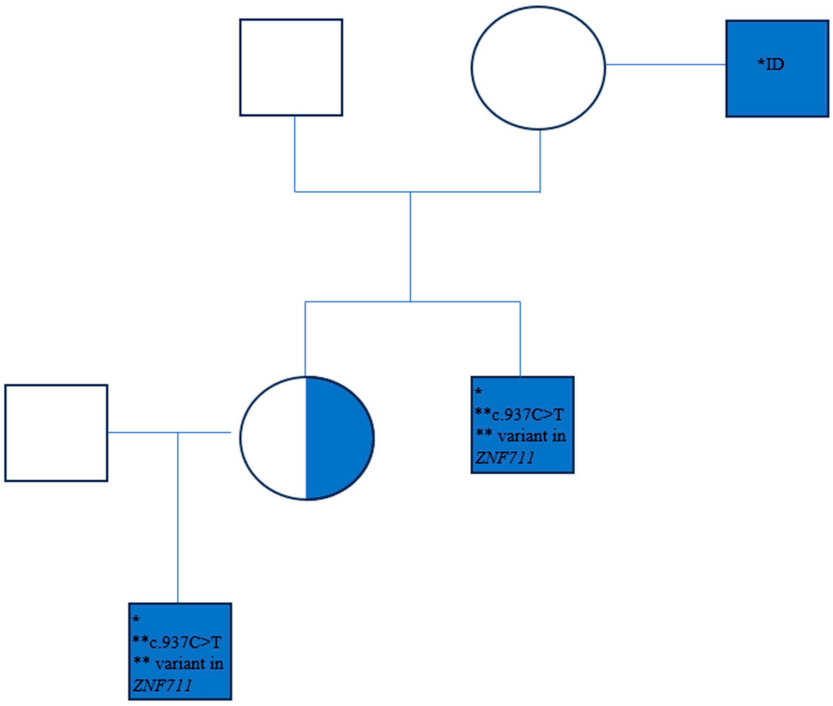

Figure 1. The familial pedigree of our patient, showing X-linked inheritance of ID. *: indicates that the patient is affected by ID **: indicates that the patient was found to harbour a mutation in *ZNF711*.

Clinical and genetic analyses were conducted in accordance with the principles of the Declaration of Helsinki and its 2024 implementation [26]. Having obtained parental informed consent, genomic DNA was purified from peripheral blood samples. Total genomic DNA of the patient and his parents was analyzed with a 150 bp paired-end protocol on a NovaSeq6000 sequencer (Illumina Inc., San Diego, CA, USA). Whole-exome sequencing (WES) was performed, and DNA libraries were prepared for each DNA sample using the SureSelect Human All Exon V7 system (Agilent Technologies, Santa Clara, CA, USA) in accordance with the manufacturer's instructions. Reads were mapped against the hg19 reference genome with the Burrows–Wheeler aligner, and variants were called with HaplotypeCaller from the GATK suite v.4.0 (Broad Institute, Cambridge, MA, USA). Exome data were analyzed using the enGenome-eVai (https://evai.engenome.com, accessed on 10 February 2026, v.3.1) and Integrative Genomic Viewer (IGV; http://igv.org/, accessed on 10 February 2026) tools. Variant filtering was carried out by selecting from the database non-synonymous single nucleotide variations (SNVs) and insertions-deletions (indels), with a minor allele frequency (MAF) < 1%. Successive variant filtering was performed based on the absence of selected SNVs and indels in unrelated database samples and on the conservation of both types of variations, leading to a final selection of rare, possibly causative, variations. The pathogenicity of each variant was evaluated by gathering evidence from multiple sources, including population data, computational and predictive data, functional, and segregation data, in accordance with the guidelines of the American College of Medical Genetics and Genomics [25].

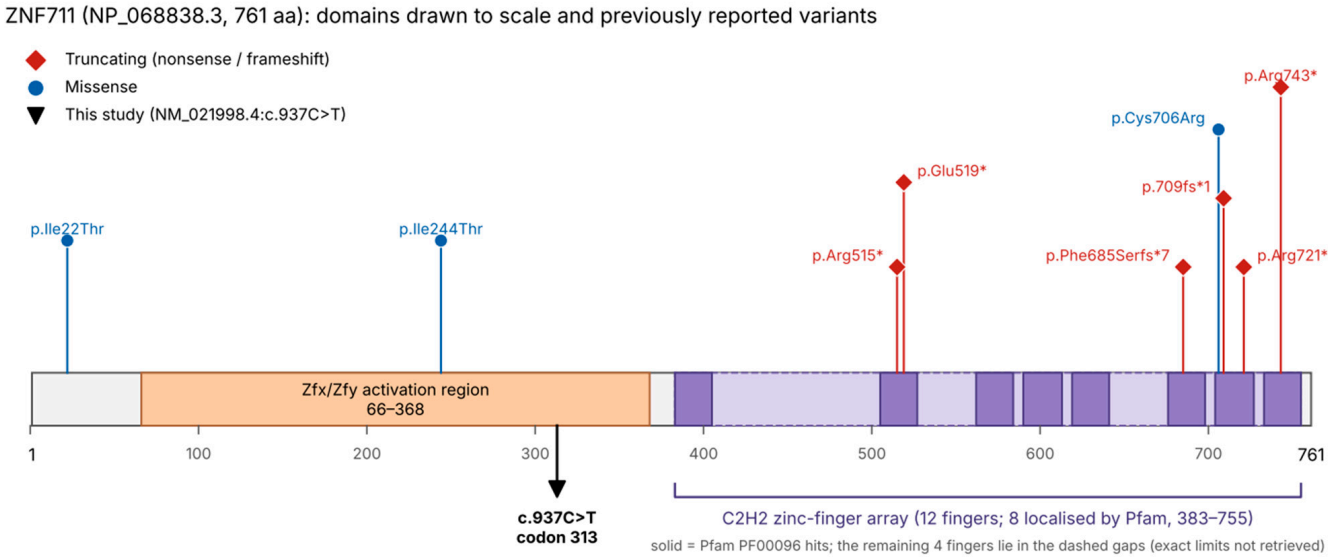

Figure 2. Schematic of the *ZNF711* protein (UniProt Q9Y462; NP_068838.3; 761 amino acids) drawn to scale. Numbering follows NM_021998.4. The N-terminal Zfx/Zfy transcription activation region (residues 66–368, orange) is followed by an array of 12 C2H2-type zinc fingers in the C-terminal half of the protein (residues ~383–755, purple). Solid purple boxes indicate the eight fingers annotated in Pfam (PF00096); the remaining four fingers lie within the intervening shaded regions. Lollipops mark variants previously reported in individuals with X-linked intellectual disability (XLID97): missense variants (circles; p.Ile22Thr, p.Ile244Thr, p.Cys706Arg) and truncating variants (diamonds; p.Arg515*, p.Glu519*, p.Phe685Serfs*7, p.709fs*1, p.Arg721*, p.Arg743*). The variant identified in this study, c.937C>T (arrowhead), affects codon 313, which lies within the activation region, upstream of the zinc-finger array. Variants originally described using the 771-residue numbering [5] were converted to the 761-residue numbering. Domain boundaries are from Pfam/InterPro.

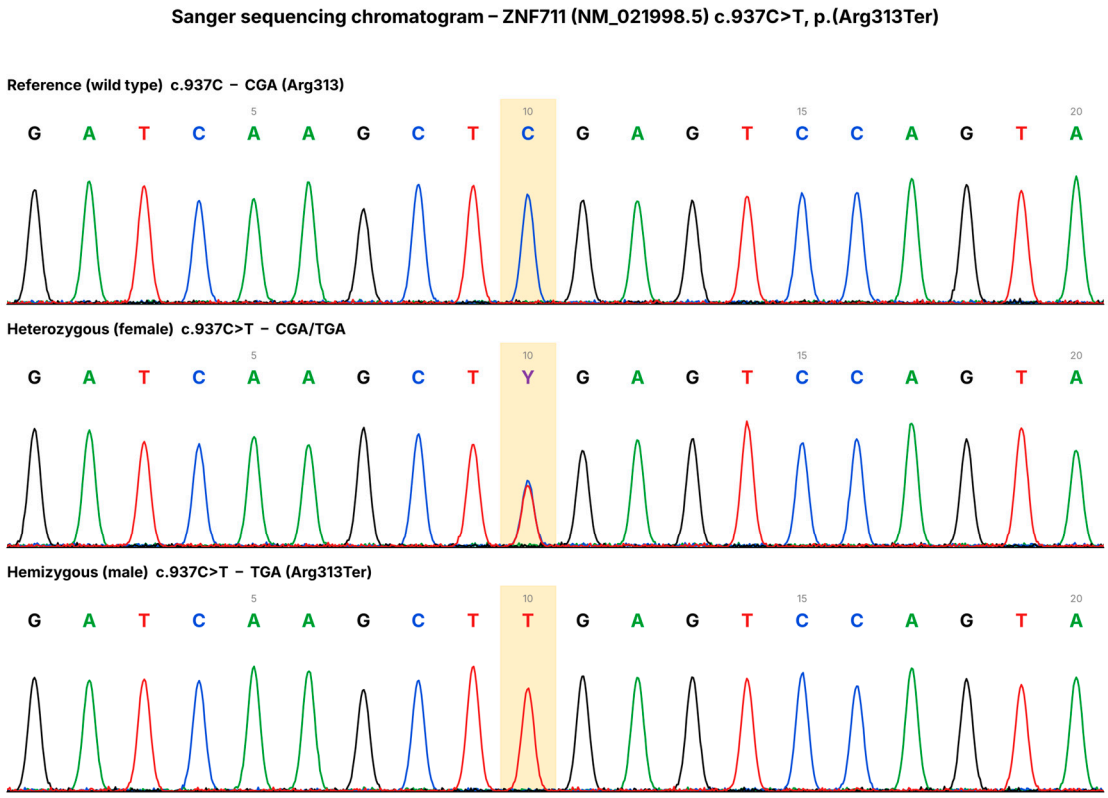

Figure 3. Sanger sequencing chromatograms of the *ZNF711* c.937C>T variant. Electropherograms showing the region surrounding c.937 (NM_021998.4) in (**top**) a wild-type control, (**middle**) a heterozygous female carrier, and (**bottom**) a hemizygous affected male. The shaded box marks the variant position. The C>T substitution converts the Arg313 codon (CGA) into a premature stop codon (TGA), resulting in p.(Arg313Ter). In the heterozygous individual, overlapping C and T peaks are observed (IUPAC code Y), whereas the hemizygous male shows a single T peak, consistent with X-linked inheritance. Peak colors: A, green; C, blue; G, black; T, red.

3.3. Functional and Instrumental Assessment

Our group first met the patient at 5 years of age, after receiving the genetic diagnosis. The parents highlighted concerns about limited independence, not yet having achieved continence, and cognitive impairment. No episodes consistent with seizures were reported.

He had recently undergone an eye examination showing 20/20 vision, no extrinsic ocular motility impairment, normal fundus oculi, preserved stereopsis and normal anterior segments.

Having met no prior cases of the disorder, and due to the lack of studies on the matter, our clinical team decided to perform a functional and instrumental check-up, comprising neurological physical examination, psychomotor and psychological evaluation, speech and language assessment, brain magnetic resonance imaging (MRI), and electroencephalography (EEG).

Upon inspection, the patient presented hypertelorism, deep-set eyes with downslanting palpebral fissures, prominent forehead, flat feet, small, spaced teeth and pectus excavatum. Cranial circumference was 53 cm (85th percentile). No anomalies were observed during the neurological examination. After psychomotor observation by our psychomotor therapist, mild motor incoordination was noted.

A thorough psychological evaluation was conducted, and the cognitive profile was analyzed using the Wechsler Preschool and Primary Scale of Intelligence—Fourth Edition (WPPSI-IV) [18] and referring to Italian norms. The child showed distractibility and an

increased latency in responding. The patient's Full-Scale Intelligence Quotient (FSIQ) was 80, indicating overall cognitive functioning in the low-average range.

Performance was relatively stronger in the Fluid Reasoning Index (FRI = 89), although the FRI subtests showed marked variability, with a weighted score of 11 on Matrix Reasoning and 5 on Picture Concepts.

The Verbal Comprehension Index (VCI) was 83, also within the low-average range. As observed for the FRI, performance across VCI subtests was heterogeneous, with weighted scores of 5 on Information and 9 on Similarities.

The Working Memory Index (WMI) was 80, reflecting low-average performance. In contrast to the FRI and VCI, performance across the WMI subtests was relatively homogeneous, with weighted scores of 7 on Picture Memory and 6 on Zoo Locations.

The Visual Spatial Index (VSI) was 79, also reflecting low-average performance. The subtests were again homogeneous, with weighted scores of 7 on block design and 6 on object assembly.

The Processing Speed Index (PSI) was more significantly impaired, with a score of 59, informed by homogeneous performances in bug search (weighted score 4) and cancellation (weighted score 3).

The adaptive profile was evaluated using the Vineland Adaptive Behavior Scale -II (VABS-II) [17] interview, administered by C.A. to the patient's mother. The child showed poor adaptive functioning overall, with the following scores: Adaptive Behavior Composite (ABC) = 62 (below 1st percentile); Socialization = 79 (8th percentile); Motor Skills = 61 (below 1st percentile); Daily Living Skills = 62 (below 1st percentile); and Communication = 67 (below 1st percentile). Currently, his adaptive difficulties appear disproportionate to his overall cognitive level, suggesting challenges in the practical application of skills in everyday life.

We also administered the Italian versions of the Child Behavior Checklist (CBCL) for Ages 1.5-5 [27], Social Communication Questionnaire–Lifetime (SCQ-L) [28], and Conners Rating Scale–Revised (CRS-R) [29] to both parents. No CBCL scores reached the clinical range. At the syndrome scale level, parents reported subclinical elevations in the "Withdrawn" scale (T = 67) and in the "Pervasive Developmental Problems" scale (T = 68) of the DSM-oriented scales. The score on the SCQ-L was 14, below the conventional cutoff for clinical concern. When it comes to the CRS-R, parents reported only a subclinical elevation in the ADHD Index (T = 65), whereas scores for Hyperactivity (T = 52), Cognitive Problems (T = 53), and Oppositionality (T = 48) were within the non-clinical range.

Sentence repetition was deemed adequate for chronological age using a standardized test for the Italian language [19]. Expressive vocabulary, in contrast, was found to be delayed, at the 5th percentile on a standardized Italian test [20]. Grammar comprehension was at the lower limits of the norm [21].

As for the general clinical workup, the patient underwent an ECG, which was normal. He underwent routine blood work, which in our hospital comprises creatine kinase measurement, full blood count, blood urate, cholesterol, glycemia, amylase, azotemia, transaminases, vitamin D, creatine and serum electrolytes. All the values analyzed were in the normal range for his age.

Although no history consistent with epilepsy was reported, we attempted to perform EEG, given previous reports of EEG anomalies and epilepsy in the disorder [11,12]. The exam, however, was poorly tolerated, causing a tantrum during the application of electrodes. Since the exam was of dubious clinical need, it was quickly interrupted, and we advised the family to reschedule the exam in case of presentation of symptoms compatible with seizures.

A brain MRI comprising T1-weighted images, T2-weighted images, susceptibility-weighted imaging (SWI), fluid-attenuated inversion recovery (FLAIR) images, and

diffusion-weighted imaging (DWI) was performed using a clinical 3T machine. Single-voxel short echo proton magnetic resonance spectroscopy (MRS) was also performed in the parieto-occipital cortex. The examination was conducted under sedation with inhaled Sevoflurane. Apart from right plagiocephaly and a slight asymmetry of the lateral ventricles, no anatomical anomalies were observed. SWI showed no abnormal iron deposition, no diffusion restrictions were observed, no FLAIR-T2 hyperintensities were noted and spectroscopy was normal. Selected MRI scans are reported in Figure 4.

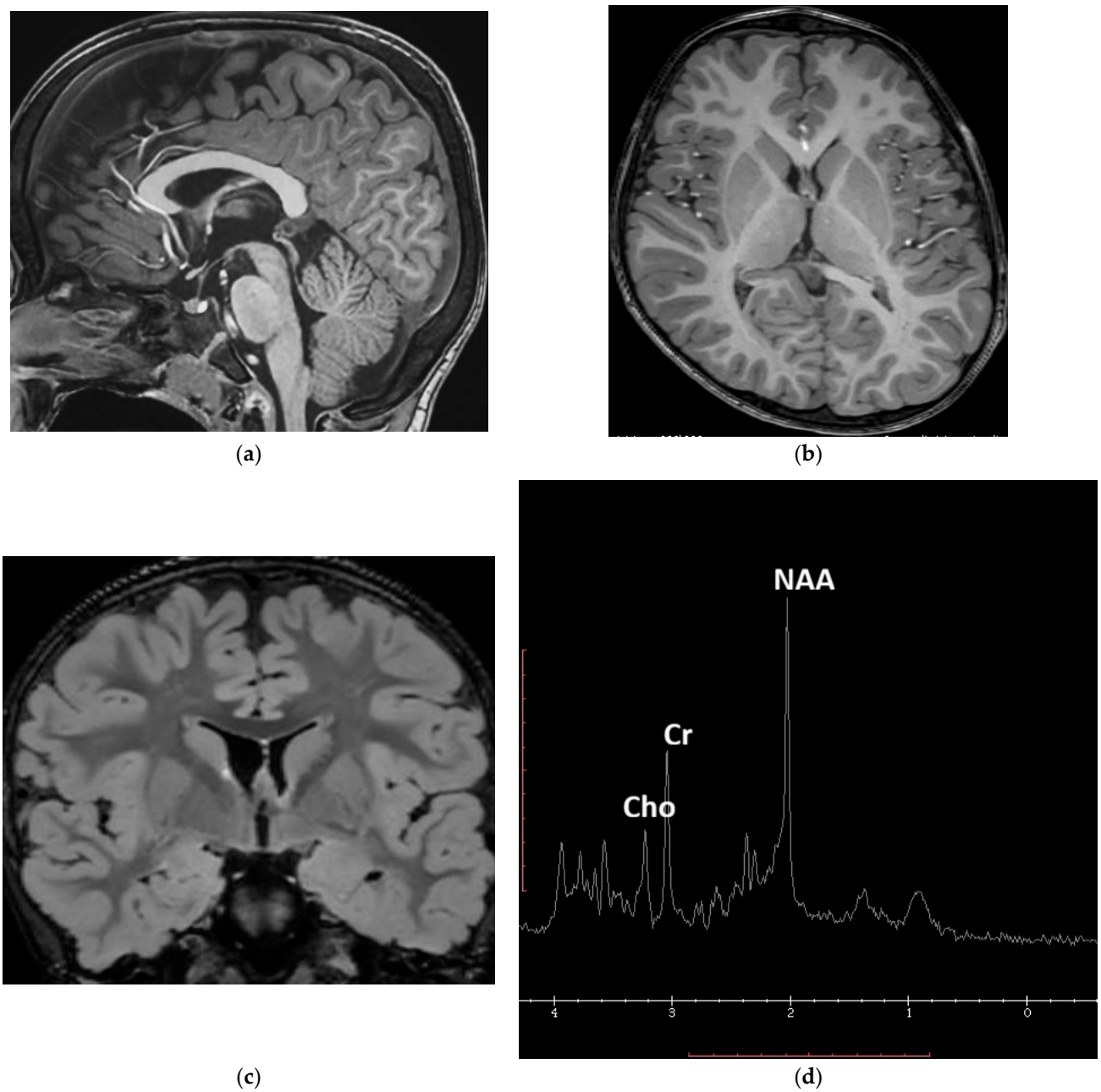

Figure 4. Brain MRI of our patient. (**a**) Sagittal and (**b**) axial T1-weighted images showing no major anatomical anomaly, normal corpus callosum, normal cortical gyration, and normal cerebellar vermis. Right plagiocephaly is observable in (**b**). (**c**) Coronal FLAIR scan showing no signal alterations. (**d**) Single-voxel short echo proton MRS in the parieto-occipital cortex showing normal sizes of N-acetylaspartate (NAA), creatine (Cr) and choline (Cho) peaks.

After 5 days of observation, our patient was discharged with a diagnosis of developmental coordination disorder and expressive language disorder. No pharmacological therapy was prescribed; rehabilitation was advised.

Figure 5 summarizes the clinical history of our patient.

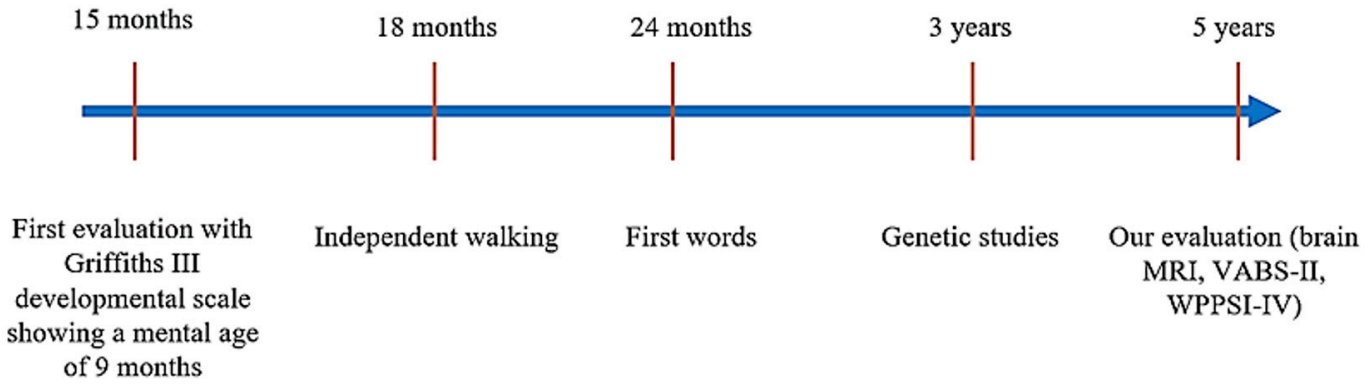

Figure 5. A brief summary of the clinical history of our patient.

4. Discussion

Tarpey et al. [5] pioneered the discovery of *ZNF711*-related XLID by conducting a large-scale systematic sequencing of coding exons of the X chromosome in 208 families with XLID. In two families, truncating *ZNF711* mutations were discovered and clustered with members showing moderate ID without consistent additional distinctive features.

Niranjan et al. [14] later conducted a similar study on 56 additional XLID families and found a patient harboring a p.N601S mutation in *ZNF711*, resulting in a damaged protein.

ZNF711 was convincingly related to XLID in 2017 by Van der Werf and colleagues [8]. The authors described two familial pedigrees in which 11 males presented with XLID; the age range was 6.5 to 56 years. ID was moderate in 5/11 patients and mild in the remaining 6. The patients also had poor speech, inconsistently accompanied by autistic features and non-specific, mild facial dysmorphology. In one of the families, the mutation was a single base-pair deletion, resulting in a frameshift with a premature stop codon. In the other one, members carried a missense mutation predicted to have deleterious effects on the protein and causative of the phenotype.

Liang et al. [13] described a 17-year-old patient with choroideremia, deafness, and ID, arguing that the latter was likely due to a deletion in the *ZNF711* gene. The patient, however, presented a large 8.05 Mb deletion involving multiple contiguous genes (namely *POU3F4*, *CYLC1*, *RPS6KA6*, *HDX*, *APOOL*, *SATL1*, *ZNF711*, *POF1B*, *CHM*, *DACH2*, *KLHL4*, and *CPXCR1*) which might have contributed to the clinical picture.

Wang et al. [9] completed the phenotypic characterization of cases originally described by Van der Werf et al. [8] and provided the genotypic characterization of three additional members of families previously reported by Tarpey et al. [5].

Additionally, the authors described four additional families with *ZNF711* alterations. In their sample, *ZNF711*-mutated hemizygotes were found to have a cognitive function that varied significantly across subjects. In particular, they described one case with moderate ID and 17 cases with mild ID. Interestingly, one subject had above-average IQ, with a General Ability Index of 131, and was later diagnosed with Asperger's syndrome. No consistent facial phenotypes were observed. Some of the males were reported to resemble the Fragile-X syndrome's facies, while others had unremarkable facial features. No specific correlation to other medical problems was found either. Motor milestones were typically reached in range or only slightly delayed, whereas speech acquisition was delayed more frequently and to

a greater extent. Of note, the authors reported on the youngest case to date, a 3-year-old male with global developmental delay. This patient was also the first case with a *ZNF711* ascertained mutation in which brain MRI was available, showing no anomaly.

Sahajpal et al. [22] compiled a case series of XLID cases caused by duplications in the X chromosome. They briefly describe a case of *ZNF711*-related NDD due to a duplication in the genomic region 84,000,996-84,536,911 (hg19). The patient was reported to have microcephaly, seizures, ADHD, and motor clumsiness. His intelligence quotient was not disclosed in the paper.

Minerva et al. [12] described comorbid seizures in two siblings affected by *ZNF711*-related ID. Both brothers had unremarkable pregnancy histories. The elder presented with moderate ID, language delay, motor stereotypies, and generalized seizures. He also showed clumsiness. His facial features included macrocephaly, deep-set eyes, a flat philtrum, small and spaced teeth, and flat feet. Similarly, the younger showed a slight delay in motor milestones and language delay, autistic features, motor clumsiness, and motor stereotypies. His facial features also included deep-set eyes, flat philtrum, small/spaced teeth, and flat feet. Seizure onset occurred at the age of 4, with generalized tonic–clonic seizures. Both children underwent brain MRI, which was unremarkable in both cases.

Urciuoli et al. [11] described an additional sibling pair. Clinically, the two siblings exhibited variable severity of their clinical features: one patient is affected by epilepsy, ASD, moderate ID and speech delay. Brain magnetic resonance imaging (MRI) performed at the age of 13 showed normal findings except for an incomplete inversion of the left hippocampus. His brother presents with a milder ASD phenotype and has had no seizures, though he shows epileptiform abnormalities on EEG.

Lastly, Liu et al. [15] reported the most recent case of *ZNF711*-related ID. The authors describe a male patient with facial dysmorphisms, hypotonia, ASD, speech delay, global developmental delay and moderate ID. Interestingly, other than a mutation in *ZNF711*, the patient harbored a likely pathogenic variant in *SRCAP*, which likely contributed to the behavioral abnormalities, the hypotonia and global developmental delay.

When compared to previously described cases, the clinical presentation of our patient confirms many of the reported findings. Specifically, we observed a phenotype comparable to what Wang et al. [9], and Urciuoli et al. [11] described: hypertelorism, deep-set eyes with downslanting palpebral fissures, prominent forehead, flat feet, and small, spaced teeth. We also observed pectus excavatum and were informed of a mild cardiac anomaly, namely a patent ductus arteriosus.

As most of the aforementioned studies stated, clinical history was unremarkable. Motor developmental milestones were reached with a mild delay, whereas a more significant delay was noted in language development. We noticed motor incoordination, consistent with what Minerva et al. [12] reported. As the other studies seem to suggest, language impairment was significant. In our case specifically, language impairment was reported as one of the biggest worries by the parents, and poor expressive vocabulary was documented on a standardized test.

No medical complications or abnormalities in routine blood work and general medical assessment were noted. Brain MRI showed no significant findings. We were unable to produce clinically interpretable results when it comes to EEG.

Contrary to most previously reported subjects, our patient did not present with ID, defined as an intelligence quotient (IQ) below 70 in the presence of adaptive difficulties [30]. Our patient did, however, show an IQ in the low-average range (80). Importantly, he also showed considerable impairment of adaptive functioning, with an Adaptive Behavior Composite score below the 1st percentile, which appears, at this developmental stage, to be disproportionate to his IQ.

Given the observed discrepancy between adaptive functioning and IQ, it would be interesting to determine whether this finding is replicated in larger cohorts. It would also be interesting to determine whether this finding is replicated at different developmental stages and with different cognitive tests.

When it comes to developmental trajectory, we saw an improvement between the scores reported by the Griffiths scale at 15 months and those we measured. We hypothesize that the developmental trajectory benefited from the rehabilitative treatment; however, the observed marked improvement in the IQ and adaptive profile was also influenced by the different scales utilized, one—the Griffiths-III—highly influenced by the motor skills and the second—WPPSI-IV—less influenced by them.

With our work, we bring the total number of cases described worldwide to 40 (notwithstanding the child's uncle and great-uncle whom we did not encounter). However, individuals AII.9 and AIII.10 from Van der Werf et al. were not genotyped, and subjects in Liang and Liu had conflicting diagnoses that might have influenced the degree of ID severity. The cases reasonably and exclusively attributable to variants in *ZNF711* are thus 36, including our case.

Though no formal data analysis can be performed due to the paucity of studies, mild ID was reported in 22/36 cases, moderate ID in 8/36, three cases had ID of unknown severity, and 3/36 showed normal or low-average IQ. Though no conclusion can be made on the basis of these sparse data, it seems that in *ZNF711*-related disorders, IQ tends to fall in the low-average to mildly impaired range. Moderate to severe ID seems slightly less common.

Regarding the additional phenotypic manifestations of the disorder, drawing definitive conclusions is challenging due to both the rarity of the disorder and the fact that some publications did not provide a sufficiently detailed description of the subjects' phenotypes. We excluded the two cases [13,15] with competing diagnoses.

With these caveats in mind, the additional phenotypic features identified and their respective frequencies were as follows: microcephaly 1/36, macrocephaly 6/36, dolichocephaly 4/36, large ears 12/36, hypertelorism 4/36, pes planus (flat feet) 3/36, deep-set eyes 9/36, small and widely spaced teeth 3/36, autistic features 15/36, motor delay 7/36, speech delay 15/36, motor clumsiness 4/36, and seizures 5/36.

No clear genotype–phenotype correlation has emerged yet; see Supplementary Table S1, where no conclusion on a putative link between the type of mutation and phenotype can be drawn. Considerable variability even within a family can be observed, as reported by Urciuoli et al. [11].

Through our review of the current knowledge on this rare disorder, we hope to have offered a viable summary of the known phenotypic presentation of the disorder that might help future clinicians who are to be challenged by this condition. *ZNF711*-related disorders seem to have a heterogeneous presentation; no specific sign can raise high clinical suspicion. Our findings underscore the importance of comprehensive functional assessment and careful pedigree analysis in the diagnostic evaluation of boys with ID or other NDDs. Clinical geneticists should maintain a high index of suspicion in families with multiple individuals affected by XLID or other NDDs showing an X-linked pattern of inheritance, even in the absence of distinctive dysmorphic features or severe clinical manifestations. Importantly, when variants of uncertain significance are encountered, the presence of an episignature should be investigated [9]. It would be interesting to see whether a portion of previously unsolved XLID cases are attributable to *ZNF711* mutations. In such cases, after targeted *FMR1* short tandem repeat study and/or CGH-array studies, X-chromosome exome sequencing may be warranted to exclude, among other conditions, *ZNF711*-related disorders.

Future studies are needed to establish genotype–phenotype correlations and to expand the number of cases described in order to reach stronger conclusions on the clinical approach to these patients.

5. Conclusions

The clinical picture in *ZNF711*-related ID seems to be highly variable, and no genotype–phenotype association has emerged yet. Although some mild facial dysmorphisms (deep-set eyes, flat philtrum, small/spaced teeth, and flat feet) could theoretically give a clue to the disease, those are rather non-specific and no consistent phenotype can give significant clues to the underlying disorder. Three recent reports have described an association between *ZNF711* mutations and epilepsy; however, data regarding the prevalence and characteristics of epileptic comorbidity in this disorder remain scarce. Therefore, EEG should be performed when clinically indicated. In contrast, there are no known anatomical brain anomalies in the disorder, and brain MRI should be performed according to clinical suspicion. The patent ductus arteriosus observed in our patient may be either an incidental finding or part of the disorder's phenotypic spectrum.

Supplementary Materials: The following supporting information can be downloaded at: https://www.mdpi.com/article/10.3390/children13121639/s1, Table S1: Additional information for each individual reported in the current literature; Figure S1: Scale for the Assessment of Narrative Review Articles–SANRA.

Author Contributions: Conceptualization, R.B., G.A. and C.A.; methodology, C.A.; software, S.P. and F.M.S.; validation, R.B. and G.A.; formal analysis, C.A.; investigation, R.P., F.B., G.A., C.A., M.B. and L.P.; resources, R.B., R.P. and F.M.S.; data curation, S.P.; writing—original draft preparation, C.A.; writing—review and editing, G.A.; visualization, S.P. and F.M.S.; supervision, R.B.; project administration, R.B.; funding acquisition, C.A., G.A., F.M.S., S.P., R.B., R.P., M.B., L.P. and F.B. All authors have read and agreed to the published version of the manuscript.

Funding: This research was partially supported by funds RC 2025 from the Italian Ministry of Health for IRCCS Stella Maris Foundation.

Institutional Review Board Statement: The study was conducted in accordance with the Declaration of Helsinki. This study was conducted as part of a larger project approved by the Pediatrics Ethics Committee of Tuscany (Comitato Etico Regione Toscana–Pediatrico CERT-P) and promoted by IRCCS Fondazione Stella Maris (protocol Rare 1.0, approved on 11 November 2025).

Informed Consent Statement: Written informed consent has been obtained from the legal guardians of the patient to publish this paper.

Data Availability Statement: Data are unavailable due to privacy restrictions.

Acknowledgments: We express our deepest gratitude to the family and to our colleagues at the Genetics Department of Perugia Hospital.

Conflicts of Interest: The authors declare no conflicts of interest.

Abbreviations

The following abbreviations are used in this manuscript:

XLID	X-linked Intellectual Disability
ID	Intellectual Disability
IQ	Intelligence Quotient
EEG	Electroencephalography
ECG	Electrocardiogram
MRI	Magnetic Resonance Imaging
CBCL	Child Behavior Checklist
CRS-R	Conners Rating Scale–Revised
SCQ-L	Social Communication Questionnaire–Lifetime

References

1. Ni, W.; Perez, A.A.; Schreiner, S.; Nicolet, C.M.; Farnham, P.J. Characterization of the ZFX Family of Transcription Factors That Bind Downstream of the Start Site of CpG Island Promoters. *Nucleic Acids Res.* **2020**, *48*, 5986–6000. [CrossRef] [PubMed]
2. Kleine-Kohlbrecher, D.; Christensen, J.; Vandamme, J.; Abarrategui, I.; Bak, M.; Tommerup, N.; Shi, X.; Gozani, O.; Rappsilber, J.; Salcini, A.E.; et al. A Functional Link between the Histone Demethylase PHF8 and the Transcription Factor ZNF711 in X-Linked Mental Retardation. *Mol. Cell* **2010**, *38*, 165–178. [CrossRef] [PubMed]
3. Poeta, L.; Padula, A.; Attianese, B.; Valentino, M.; Verrillo, L.; Filosa, S.; Shoubridge, C.; Barra, A.; Schwartz, C.E.; Christensen, J.; et al. Histone Demethylase KDM5C Is a SAHA-Sensitive Central Hub at the Crossroads of Transcriptional Axes Involved in Multiple Neurodevelopmental Disorders. *Hum. Mol. Genet.* **2019**, *28*, 4089–4102. [CrossRef] [PubMed]
4. Al-Naama, N.; Mackeh, R.; Kino, T. C_2H_2-Type Zinc Finger Proteins in Brain Development, Neurodevelopmental, and Other Neuropsychiatric Disorders: Systematic Literature-Based Analysis. *Front. Neurol.* **2020**, *11*, 32. [CrossRef] [PubMed]
5. Tarpey, P.S.; Smith, R.; Pleasance, E.; Whibley, A.; Edkins, S.; Hardy, C.; O'Meara, S.; Latimer, C.; Dicks, E.; Menzies, A.; et al. A Systematic, Large-Scale Resequencing Screen of X-Chromosome Coding Exons in Mental Retardation. *Nat. Genet.* **2009**, *41*, 535–543. [CrossRef] [PubMed]
6. Sobering, A.K.; Bryant, L.M.; Li, D.; McGaughran, J.; Maystadt, I.; Moortgat, S.; Graham, J.M.; Van Haeringen, A.; Ruivenkamp, C.; Cuperus, R.; et al. Variants in PHF8 Cause a Spectrum of X-Linked Neurodevelopmental Disorders and Facial Dysmorphology. *Hum. Genet. Genom. Adv.* **2022**, *3*, 100102. [CrossRef] [PubMed]
7. Chen, X.; Wang, S.; Zhou, Y.; Han, Y.; Li, S.; Xu, Q.; Xu, L.; Zhu, Z.; Deng, Y.; Yu, L.; et al. Phf8 Histone Demethylase Deficiency Causes Cognitive Impairments through the mTOR Pathway. *Nat. Commun.* **2018**, *9*, 114. [CrossRef] [PubMed]
8. Van Der Werf, I.M.; Van Dijck, A.; Reyniers, E.; Helsmoortel, C.; Kumar, A.A.; Kalscheuer, V.M.; De Brouwer, A.P.; Kleefstra, T.; Van Bokhoven, H.; Mortier, G.; et al. Mutations in Two Large Pedigrees Highlight the Role of ZNF711 in X-Linked Intellectual Disability. *Gene* **2017**, *605*, 92–98. [CrossRef] [PubMed]
9. Wang, J.; Foroutan, A.; Richardson, E.; Skinner, S.A.; Reilly, J.; Kerkhof, J.; Curry, C.J.; Tarpey, P.S.; Robertson, S.P.; Maystadt, I.; et al. Clinical Findings and a DNA Methylation Signature in Kindreds with Alterations in ZNF711. *Eur. J. Hum. Genet.* **2022**, *30*, 420–427. [CrossRef] [PubMed]
10. Lubs, H.A.; Stevenson, R.E.; Schwartz, C.E. Fragile X and X-Linked Intellectual Disability: Four Decades of Discovery. *Am. J. Hum. Genet.* **2012**, *90*, 579–590. [CrossRef] [PubMed]
11. Urciuoli, G.; Simeone, N.; Rubino, M.; Madia, F.; Bilo, L.; Comegna, M.; De Vita, G.; Coppola, A. Expanding the Phenotypic Spectrum of ZNF711: Autism and Epilepsy in Two Siblings. *Epilepsy Behav. Rep.* **2026**, *35*, 100878. [CrossRef] [PubMed]
12. Minerva, M.; Perilli, L.; Carbone, S.; Rossi, M.M.; Lotti, F.; Lonoce, L.; Curcio, M.R.; Grosso, S. Electroencephalographic and Epilepsy Findings in ZNF711 Variants: A Case Series of Two Siblings. *Neurol. Int.* **2025**, *17*, 14. [CrossRef] [PubMed]
13. Liang, S.; Jiang, N.; Li, S.; Jiang, X.; Yu, D. A Maternally Inherited 8.05 Mb Xq21 Deletion Associated with Choroideremia, Deafness, and Mental Retardation Syndrome in a Male Patient. *Mol. Cytogenet.* **2017**, *10*, 23. [CrossRef] [PubMed]
14. Niranjan, T.S.; Skinner, C.; May, M.; Turner, T.; Rose, R.; Stevenson, R.; Schwartz, C.E.; Wang, T. Affected Kindred Analysis of Human X Chromosome Exomes to Identify Novel X-Linked Intellectual Disability Genes. *PLoS ONE* **2015**, *10*, e0116454. [CrossRef] [PubMed]
15. Liu, T.; Huang, M.; Dai, M.; Liang, Y.; Zhang, C.; Tan, J.; Qiao, F.; Wang, Y. Identification of Novel Co-Occurring ZNF711 and SRCAP Variants in a Child with Neurodevelopmental Disorders Through Exome Sequencing. *Appl. Clin. Genet.* **2026**, *19*, 625023. [CrossRef] [PubMed]
16. Covidence Systematic Review Software. 2023. Available online: https://app.covidence.org/reviews/active (accessed on 30 October 2026).
17. Balboni, G.; Belacchi, C.; Bonichini, S.; Coscarelli, A. *Vineland-II: Vineland Adaptive Behavior Scales, Second Edition (Survey Forms)*; Giunti O.S. Organizzazioni Speciali: Florence, Italy, 2016.
18. Wechsler, D. *Wechsler Preschool and Primary Scale of Intelligence—Fourth Edition (WPPSI-IV)*, 4th ed.; Pearson: Singapore, 2012.
19. Marini, A.; Marotta, L.; Bulgheroni, S.; Fabbro, F. *Batteria per La Valutazione Del Linguaggio in Bambini Dai 4 Ai 12 Anni*, 2015th ed.; Giunti O.S.: Florence, Italy, 2015.
20. Vicari, S.; Marotta, L.; Luci, A. *TFL Test Fono-Lessicale Valutazione Delle Abilità Lessicali in Età Prescolare*; Erickson: Quarry Bay, Hong Kong, 2007.
21. Bishop, D.V.M. *Test for Reception of Grammar*, 2nd ed.; Pearson: Singapore, 2003.
22. Sahajpal, N.; Ziats, C.; Chaubey, A.; DuPont, B.R.; Abidi, F.; Schwartz, C.E.; Stevenson, R.E. Clinical Findings in Individuals with Duplication of Genes Associated with X-linked Intellectual Disability. *Clin. Genet.* **2024**, *105*, 173–184. [CrossRef] [PubMed]
23. Baethge, C.; Goldbeck-Wood, S.; Mertens, S. SANRA—A Scale for the Quality Assessment of Narrative Review Articles. *Res. Integr. Peer Rev.* **2019**, *4*, 5. [CrossRef] [PubMed]
24. Strisciuglio, P.; De Toni, L.; Griffiths, R. *Griffiths III—Scale Griffiths Dello Sviluppo Del Bambino. Manuale*; Hogrefe: Firenze, Italy, 2016.

25. Richards, S.; Aziz, N.; Bale, S.; Bick, D.; Das, S.; Gastier-Foster, J.; Grody, W.W.; Hegde, M.; Lyon, E.; Spector, E.; et al. Standards and Guidelines for the Interpretation of Sequence Variants: A Joint Consensus Recommendation of the American College of Medical Genetics and Genomics and the Association for Molecular Pathology. *Genet. Med.* **2015**, *17*, 405–424. [CrossRef] [PubMed]
26. World Medical Association. World Medical Association Declaration of Helsinki: Ethical Principles for Medical Research Involving Human Participants. *JAMA* **2025**, *333*, 71. [CrossRef] [PubMed]
27. Achenbach, T.M.; Rescorla, L.A. *Manual for the ASEBA Preschool Forms & Profiles*; University of Vermont, Research Center for Children, Youth, and Families: Burlington, VT, USA, 2000.
28. Rutter, M.; Bailey, A.; Lord, C. *The Social Communication Questionnaire: Manual*; Western Psychological Services: Melton South, Australia, 2003.
29. Nobile, M.; Alberti, B.; Zuddas, A. *CRS-R: Conners' Rating Scales—Revised: Manuale. Adattamento Italiano*; Giunti O.S.: Florence, Italy, 2007.
30. Lee, K.; Cascella, M.; Marwaha, R. Intellectual Disability. In *StatPearls*; StatPearls Publishing: Treasure Island, FL, USA, 2026.

Disclaimer/Publisher's Note: The statements, opinions and data contained in all publications are solely those of the individual author(s) and contributor(s) and not of MDPI and/or the editor(s). MDPI and/or the editor(s) disclaim responsibility for any injury to people or property resulting from any ideas, methods, instructions or products referred to in the content.