children

MDPI

Article

Documented Failure Patterns of Prefabricated Zirconia Crowns on Pulpectomized Maxillary Primary Incisors in Children Treated Under General Anesthesia: A Retrospective Study

Munevver Coruh Kılıc [1], Ayşe Mete [2], Dilek Özge Yılmaz [3], Kenan Cantekin [4,*] and Oğuzhan Maden [5]

[1] Department of Pediatric Dentistry, Faculty of Dentistry, Biruni University, Istanbul 34015, Turkey
[2] Department of Pediatric Dentistry, Gulhane Faculty of Dentistry, University of Health Science, Ankara 06018, Turkey
[3] Özel Dent Pozitif Ağız ve Diş Sağlığı Polikliniği, Istanbul 34295, Turkey
[4] Faculty of Dentistry, Sakarya University, Sakarya 54050, Turkey
[5] Department of Periodontology, Faculty of Dentistry, Igdır Üniversitesi, Igdır 76000, Turkey
* Correspondence: kenancantekin@sakarya.edu.tr

Abstract

Background: Prefabricated zirconia crowns are used to restore extensively damaged primary incisors, including in children undergoing comprehensive dental treatment under general anesthesia. Clinical documentation of the types and timing of subsequent restoration-related complications is useful, but follow-up ascertainment must be considered when interpreting event frequencies. **Objective:** To describe recorded failure types and their timing among prefabricated zirconia crowns placed after pulpectomy on maxillary primary central and lateral incisors in children treated under general anesthesia. **Methods:** In this retrospective chart review, 113 patient records were screened. Two records contained no documented maxillary primary incisor crowns, and two further records were excluded in full because their tooth-group counts exceeded the anatomically possible number of maxillary primary incisors and could not be reconciled with source charts. The resulting analysis dataset comprised 109 children with 396 recorded eligible maxillary primary incisor crowns (205 central and 191 lateral). All included teeth underwent pulpectomy before crown placement. Documented debonding and trauma-related loss of the tooth–crown complex were distinguished. Individual dates of event-free review and censoring were unavailable, precluding valid Kaplan–Meier analysis. **Results:** After excluding two records with no documented eligible incisor crown and two records with irreconcilable tooth-count inconsistencies, the revised analysis includes 109 children and 396 recorded maxillary primary incisor crowns (205 central and 191 lateral). There were 48 girls and 61 boys. Five documented failures occurred within 18 months (three debondings and two trauma-related events), and two additional events occurred at 41 and 49 months. These frequencies do not establish a fixed-time risk or survival estimate. **Conclusions:** The available clinical records identified loss of crown retention and traumatic injury to the restored tooth–crown complex as distinct documented failure modes after zirconia crown placement on pulpectomized maxillary primary incisors. Incomplete restoration-specific follow-up records preclude reliable estimation of crown survival or cumulative failure risk. Prospective restoration-level follow-up is needed to quantify longevity.

Keywords: primary incisors; pediatric dentistry; prefabricated zirconia crown; pulpectomy; general anesthesia; retrospective study; debonding; dental trauma

Check for updates

Academic Editor: Lidia Gavic

Received: 24 September 2026
Revised: 22 October 2026
Accepted: 29 October 2026
Published: 30 October 2026

Copyright: © 2026 by the authors. Licensee MDPI, Basel, Switzerland. This article is an open access article distributed under the terms and conditions of the Creative Commons Attribution (CC BY) license.

1. Introduction

Early childhood caries (ECC) remains highly prevalent worldwide and represents a substantial pediatric oral health burden [1]. Untreated ECC is consistently associated with poorer oral health-related quality of life in preschool children [2]. Consequently, the prevention and effective management of ECC remain major priorities in pediatric oral health care.

Significant breakdown of tooth structure in the maxillary primary anterior teeth represents an important clinical consequence of ECC. Primary anterior teeth contribute to esthetics, phonation, and anterior function, and premature loss can have functional and psychosocial consequences [3]. Therefore, restoration of severely compromised primary anterior teeth should aim not only to restore appearance, but also to maintain function and support the child's well-being.

The restorative management of severely damaged primary anterior teeth includes composite strip crowns and prefabricated full-coverage restorations. Contemporary systematic reviews indicate that both composite strip crowns and prefabricated zirconia crowns can achieve clinically acceptable outcomes [4–6]. Prefabricated zirconia crowns generally demonstrate favorable retention and lower restoration-failure rates than composite strip crowns [5,6], although they require more extensive tooth preparation [4,5].

Prefabricated zirconia crowns have emerged as an esthetic full-coverage restorative option for primary anterior teeth. Yttria-stabilized zirconia exhibits favorable mechanical strength, biocompatibility, and tooth-colored esthetic properties [7]. Recent pediatric evidence syntheses also report favorable retention and generally favorable gingival and esthetic outcomes with prefabricated zirconia crowns [5,6].

For some children with ECC, conventional outpatient dental treatment may not be feasible because of limited cooperation, dental anxiety, behavioral or medical conditions, or extensive treatment needs. Current American Academy of Pediatric Dentistry guidance recognizes general anesthesia (GA) as an advanced behavior-guidance option for appropriately selected pediatric patients when treatment needs and patient factors warrant it [8]. Comprehensive dental rehabilitation under GA permits multiple procedures to be completed in a single session. Because this setting involves a distinct patient population and treatment context, outcome data derived specifically from GA-treated children are important when evaluating restorative longevity.

Although favorable outcomes have been reported for prefabricated zirconia crowns in primary anterior teeth, longitudinal survival evidence from children treated under GA remains limited. The available GA-based cohorts have differed in sample size, follow-up duration, clinical variables, and outcome definitions, complicating direct comparison of survival estimates and failure patterns [9,10]. In particular, data describing the timing and causes of failure within larger GA-treated cohorts remain limited. Therefore, the present retrospective study aimed to describe the types and timing of documented failures of prefabricated zirconia crowns placed on pulpectomized maxillary primary incisors in children treated under general anesthesia. Owing to incomplete restoration-specific event-free follow-up and censoring dates in the retained records, cumulative survival was not estimated.

2. Materials and Methods

2.1. Study Design and Setting

This retrospective clinical record review was conducted in the Department of Pediatric Dentistry, Faculty of Dentistry, Biruni University. Dental procedures under general anesthesia were performed between 25 January 2022 and 27 April 2026. The stated data-lock date was 14 September 2026. The study was based on records generated during routine

care; no additional research-specific clinical intervention was performed. During this period, the institution's general-anesthesia dental service accepted systemically healthy children; children with known systemic diseases were referred to appropriately equipped centers for further assessment and treatment, according to the treating team's description of institutional practice.

The dental treatments were provided as routine clinical care before this retrospective research was planned. The study was subsequently approved as a retrospective archival review of existing clinical and imaging records by the Biruni University Scientific Research Ethics Committee (Approval No. 2024-BİAEK/24-24; 16 September 2026), following revisions requested during the ethics application process. The data-lock date of 14 September 2026 defined the eligible clinical record period; it was not the ethics approval date. The manuscript was first submitted on 24 September 2026. Parental consent for routine clinical dental treatment under general anesthesia was obtained. Separate research-specific informed consent was not obtained for this later-planned retrospective review. The ethics approval document does not explicitly grant a waiver of research-specific informed consent, and no such waiver is claimed. No additional clinical intervention was performed for research purposes. Representative clinical photographs were selected from routine-care archival records, do not display patients' faces or direct personal identifiers, and were used only to illustrate recorded clinical events.

2.2. Study Population and Eligibility

The source spreadsheet contained 113 patient records. Two patients had no maxillary primary central or lateral incisor crown recorded and were ineligible for this incisor-specific analysis. Two further patient records contained anatomically impossible counts (two central plus three lateral crowns in one; four central crowns in another). Original tooth-specific charts were not available to adjudicate the anomalous counts. Consequently, both affected patient records were excluded in full, without making assumptions about which individual tooth entries were erroneous. These four exclusions yielded a revised analysis dataset of 109 children and 396 recorded maxillary primary incisor crowns (205 central, 191 lateral). This record-level exclusion rule avoids assigning unverified individual tooth identities.

Eligibility required treatment under general anesthesia at the study institution and at least one documented prefabricated zirconia crown on a maxillary primary central or lateral incisor. During the study period, the institutional general-anesthesia dental service treated systemically healthy children, while children with known systemic diseases were referred to appropriately equipped centers. All included children had no known systemic illness according to the treating clinicians. Primary canines and molars were outside the incisor-specific study scope. Two patients with no incisor crowns and two with irreconcilable tooth-count inconsistencies were excluded. The total number of children treated or referred outside the spreadsheet could not be reconstructed, and detailed preoperative tooth-condition variables were not consistently available for analysis.

2.3. Clinical Protocol

All zirconia crown procedures were performed by two experienced pediatric dentists as part of comprehensive dental rehabilitation under general anesthesia. Comprehensive clinical and radiographic examinations were performed before treatment, and individualized treatment plans were formulated. All included maxillary primary incisors underwent pulpectomy before crown placement, as confirmed by the treating author. Prefabricated zirconia crowns (Prof ZR Crowns; HDC Dental, Ankara, Türkiye) were used. Tooth preparation followed the manufacturer's recommendations and included caries removal, circumferential reduction, and adequate incisal reduction. Crown size was selected individually

for each tooth. All crowns were cemented using resin-modified glass ionomer cement (GC FujiCEM Evolve; GC Corporation, Tokyo, Japan) according to the manufacturer's instructions. Occlusal and proximal contacts were evaluated, and final crown fit was clinically verified before completion of treatment.

The same two experienced pediatric dentists performed the routine clinical follow-up examinations. Formal examiner calibration was not performed for those routine clinical assessments. Standardized postoperative radiographic outcomes and sufficiently detailed tooth-level preoperative variables were not retained in the study dataset for prognostic comparisons.

2.4. Outcomes and Follow-Up

Documented crown-related complications were categorized as loss of retention (debonding), trauma-related loss or fracture of the restored tooth–crown complex, or intrinsic fracture of zirconia crown material. Physiological exfoliation was not classified as restoration failure. The original study described clinical review opportunities at approximately 6, 12 and 18 months, but the retained record set preferentially captured crown loss and failure rather than tooth-specific dated negative examinations.

Consequently, patient treatment dates may establish the opportunity for a period of follow-up but cannot establish the date to which each individual crown was confirmed in situ. Events documented within the first 18 months were described separately from those recorded later. A Kaplan–Meier analysis was not retained because individual event-free observation and censoring times could not be reconstructed with adequate validity.

2.5. Demographic and Socioeconomic Variables

Demographic data, parental education level, and household income were obtained before treatment using a structured questionnaire. Age at treatment was calculated from each child's date of birth and the date of the general-anesthesia procedure. These variables were used to characterize the included population.

2.6. Statistical Analysis

The originally submitted statistical analysis was conducted using SPSS version 26.0 (IBM Corp., Armonk, NY, USA). In the revised descriptive presentation, eligible patient and crown entry counts and documented events were described using absolute frequencies and percentages. Two patient records with irreconcilable anatomical count inconsistencies were excluded in full before computing the revised analysis sample (109 children, 396 maxillary primary incisor crown entries). The clinical author confirmed these patients had no reported failures. For transparency, both the original 113-record extraction and the reason for four patient exclusions are reported. Because individual restoration-specific dates of event-free review and censoring were unavailable, time-to-event survival probabilities, confidence intervals and risk-set sizes could not be validated and were removed. No cluster-adjusted survival or bootstrap analysis could be supported. Descriptive event proportions use recorded events divided by recorded crowns and do not represent survival probabilities or cumulative incidence at 18 months.

3. Results

3.1. Analytic Sample, Demographics and Crown Distribution

The spreadsheet contained 113 patient records and 405 recorded incisor crown entries. Two patients had no eligible incisor crown entry, and two records contained irreconcilable, anatomically excessive counts (together nine recorded crowns: six central and three lateral). Exclusion of those four patients yielded a revised analytic sample of 109 children with

396 recorded eligible crowns (205 central and 191 lateral). The cohort included 48 girls (44.0%) and 61 boys (56.0%). The mean age at treatment among the 109 included children, calculated from recorded dates of birth and treatment, was 4.01 ± 1.35 years.

Twenty-four of the 109 included children (22.0%) were aged 5 years or older at the time of treatment under general anesthesia. Ages were calculated from birth and treatment dates, not current age. The observed date-derived age range was 1.37–7.96 years (calculated from the dates available in the retained worksheet). The demographic characteristics of the study population are presented in Table 1, while the distribution of maxillary primary incisor crowns is summarized in Table 2.

Table 1. Baseline demographics of the revised analytic sample (N = 109).

Characteristic	*n* (%) or Value
Participants	109
Female	48 (44.0%)
Male	61 (56.0%)
Age at treatment, mean ± SD (years; n = 109)	4.01 ± 1.35
Parental education: primary/secondary school	15 (13.8%)
Parental education: high school	29 (26.6%)
Parental education: university/postgraduate	65 (59.6%)
Household income: ≤minimum wage	7 (6.4%)
Household income: 30,000–50,000 TRY	14 (12.8%)
Household income: 50,000–100,000 TRY	35 (32.1%)
Household income: 100,000–200,000 TRY	42 (38.5%)
Household income: >200,000 TRY	11 (10.1%)

Table 2. Distribution of maxillary primary incisor crown records after exclusions (N = 396).

Tooth Group	Crown Entries	% of 396
Maxillary primary central incisors	205	51.8%
Maxillary primary lateral incisors	191	48.2%
Total	396	100.0%

3.2. Documented Complications

Five documented crown failures occurred within the first 18 months among four children: three debondings (60.0% of early events) and two trauma-related failures of the restored tooth–crown complex (40.0%). Event times were 1.9, 2.2, 8.3, 8.3 and 12.6 months. The five recorded events divided by the 396 crown entries correspond to a descriptive event-to-entry fraction of 1.26%; this is not an 18-month cumulative incidence or survival estimate because observation durations were not established for all crowns. Two further failures (one debonding, one trauma-related) were documented at 41 and 49 months. Seven events among six children were documented over all available records (7/396 = 1.77% as an unadjusted event-to-entry fraction, not long-term risk). No intrinsic fracture of crown material was reported. Two exfoliation-related observations were not classified as failures. Of the two physiological exfoliation-related observations, tooth 51 exfoliated at approximately 7 months. At 12.6 months, tooth 61, already in an advanced stage of physiological exfoliation, was lost during the same traumatic episode in which tooth 62 fractured at the cervical level

while its zirconia crown remained attached to the coronal fragment. Tooth 61 was treated as physiological exfoliation rather than restoration failure; tooth 62 was classified as trauma-related tooth–crown complex failure. The documented failure modes are summarized in Table 3, and the chronological distribution of individual failure events is presented in Table 4. Representative clinical findings are illustrated in Figure 1.

Table 3. Documented failure modes (event counts only).

Failure Mode	≤18 Months	>18 Months	All Recorded
Debonding	3	1	4
Trauma-related tooth–crown complex failure	2	1	3
Total	5	2	7

Table 4. Chronology of documented failure events.

Patient ID	FDI Tooth	Documented Event	Time
P7	62	Trauma-related failure	1.9 months (58 days)
P3	51	Debonding	2.2 months (67 days)
P1	51	Debonding	8.3 months (254 days)
P1	61	Debonding	8.3 months (254 days)
P5	62	Trauma-related failure	12.6 months (383 days)
P6	52	Debonding	41 months
P4	62	Trauma-related failure	49 months

Note: Patient identifiers are anonymized; P1 experienced two separate crown failures at 8.3 months. Tooth numbers follow the FDI notation. The treating author confirmed that neither patient excluded for inconsistent tooth counts experienced a documented failure. Physiological exfoliation was not classified as a failure.

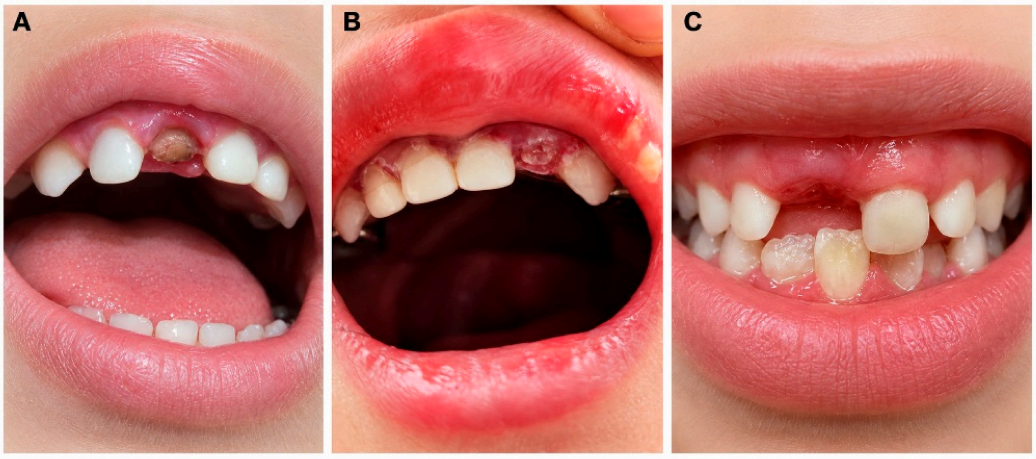

Figure 1. Representative clinical appearances during follow-up: (**A**) debonding of a prefabricated zirconia crown; (**B**) trauma-related failure involving the restored maxillary primary anterior region; and (**C**) physiological exfoliation. Physiological exfoliation was not counted as restoration failure.

4. Discussion

This retrospective study describes documented failure modes and their timing among prefabricated zirconia crowns placed on maxillary primary incisors in children undergoing comprehensive dental treatment under general anesthesia. Five failures were documented within 18 months of placement in four children; three involved loss of crown retention

and two were associated with traumatic injury to the restored tooth–crown complex. Two additional failures were recorded at 41 and 49 months. These observations characterize the modes and timing of recorded complications but do not provide a validated estimate of restoration survival, because restoration-specific event-free follow-up and censoring times could not be reconstructed from the retained dataset. Previous studies used different clinical designs and endpoints: Alrashdi examined zirconia crowns with and without pulpotomy (not pulpectomy), whereas Elheeny and Sermani compared zirconia crowns with composite strip crowns [11,12].

The predominance of debonding among documented restoration-related events is clinically relevant. Three debonding events occurred during the first 18 months, including two crowns in a single child at approximately 8.3 months; a further debonding event was recorded at 41 months. Such events may reflect a combination of retention-related factors, tooth morphology, available bonding surface, cementation, and clinical loading. The current records do not support attribution of the observed events to any individual mechanism. Although the same crown system and resin-modified glass-ionomer luting cement were reportedly used, detailed tooth-level preparation and cementation variables were not available for exploratory comparison. Zirconia is a silica-free polycrystalline ceramic; therefore, conventional hydrofluoric-acid etching and silane-based protocols designed for silica-containing ceramics do not provide predictable adhesion to zirconia. Preparation design, appropriate surface treatment, and cement selection remain relevant to retention [13,14]. These general principles, however, do not establish the cause of any particular failure in this pediatric cohort.

Trauma-related failures should be distinguished from intrinsic crown fracture or loss of retention. In the documented event at 12.6 months, the affected primary incisor fractured in the cervical region while the zirconia crown remained attached to the coronal tooth fragment. This represents traumatic damage to the restored tooth–crown complex, not evidence that the zirconia material fractured. No intrinsic fracture of the zirconia crown material was documented among the recorded events. However, absence of a documented intrinsic fracture should not be interpreted as proof of a zero material-fracture risk. Traumatic dental injuries in primary teeth are described in epidemiologic research and primary-dentition trauma guidelines [15,16]. Zirconia has established mechanical properties, but these cannot establish material-specific failure risk from the present incomplete follow-up records [17].

Physiological exfoliation is expected during the transition from the primary to the permanent dentition and is particularly important when evaluating restored maxillary incisors in older children. Two exfoliation-related observations were described in the original clinical report and were not counted as restoration failures. In the original time-to-event analysis, these observations had been censored; nevertheless, age- and developmental-stage-related exfoliation may be informative rather than independent of restoration observation time. Because individual last-event-free review dates and time-to-exfoliation data were not retained for the full cohort, neither age-specific survival nor a competing-risks analysis could be supported. Consequently, the present interpretation is restricted to documented event patterns. Specifically, the tooth 51 event was documented at approximately 7 months, whereas the tooth 61 exfoliation-related loss was recorded at 12.6 months during the traumatic episode involving tooth 62. These case-level classifications were retained, but the absence of individual event-free follow-up times precludes time-to-event censoring analysis.

Chronological age is not a direct measure of dental developmental stage. Physiological exfoliation of maxillary primary incisors is relevant in older children, but the timing varies between individuals. Therefore, age above 5 years was not itself an exclusion criterion when an eligible maxillary primary incisor crown had been recorded at the time of treatment. Nevertheless, tooth-level root-resorption stages were not available to establish remaining

functional lifespan, and the impact of age-related exfoliation on observation time cannot be quantified from the retained dataset.

All study-eligible restored maxillary primary incisors were reported by the authors to have undergone pulpectomy before crown placement. The findings therefore apply specifically to crowns placed following pulpectomy, rather than to primary incisor crowns generally. Because pulpectomy status did not vary within this population, its independent effect on crown retention or other outcomes cannot be estimated. Moreover, the available follow-up records were not designed to document serial radiographic signs of periapical or root pathology; restoration-event documentation should not be conflated with endodontic treatment success.

Previous clinical studies provide important context for interpretation. Seminario et al. [9] reported Kaplan–Meier zirconia crown survival probabilities of 93%, 85%, and 76% at 12, 24, and 36 months, respectively, in primary maxillary incisors treated under general anesthesia. Alhissan and Pani [10] reported a 94.3% symptom-free rate at two years, whereas clinical success was 80% when bond failures were considered. Alrashdi [11] investigated crown survival in teeth with and without pulpotomy, which differs from the pulpectomy-treated population examined here. Elheeny and Sermani [12] compared prefabricated zirconia crowns with resin-bonded composite strip crowns over 36 months. Contemporary systematic reviews also describe favorable clinical performance of anterior zirconia crowns [5,6]. Nevertheless, direct numerical comparison with the present recorded event counts would be inappropriate: these studies differ in eligibility criteria, outcome definitions, observation periods and time-to-event data availability. The present study documents failure modes and their recorded timing, not an estimated restoration survival probability.

Continued monitoring after comprehensive dental rehabilitation under general anesthesia remains clinically relevant beyond restoration-specific outcomes. Research on repeated dental treatment under general anesthesia has examined follow-up attendance in relation to subsequent treatment needs [18]. These findings provide context for the importance of clinical review but do not establish the survival of zirconia crowns in this cohort.

The documentation of two events after the initial 18-month period illustrates that complications can be recorded later in the clinical course. However, the late events were identified through nonuniform available observation and should be presented as individual recorded occurrences, not as evidence for a particular late-failure incidence or a temporal increase in risk. Future prospective studies with restoration-level recording of tooth characteristics, pulpectomy details, scheduled review attendance, exfoliation, and radiographic outcomes would enable more reliable estimation of retention, tooth-related failure, and competing outcomes.

Limitations

This study has important limitations. First, it is a single-center retrospective analysis dependent on the completeness of routine clinical records. Although scheduled clinical reviews were reportedly performed, the retained study dataset primarily documented failures or absent crowns and did not preserve restoration-specific dates of event-free review or censoring. Therefore, follow-up duration cannot be reliably reconstructed for all restorations, and the originally reported Kaplan–Meier survival estimates, confidence intervals, and risk sets cannot be independently validated. The revised analysis consequently reports recorded events descriptively and does not estimate survival or cumulative failure risk.

Second, two patient records contained no eligible incisor crown, while two further records had anatomically implausible tooth-group counts. The latter records were excluded in full because the original tooth-specific charts could not be retrieved to resolve the discrep-

ancies. Exclusion of these records reduces the risk of including misclassified crown entries but may introduce selection bias. The revised cohort is therefore based on a transparent record-level eligibility rule rather than independent verification of every tooth identity.

Third, selection bias remains possible because the complete number of otherwise eligible children who did not participate in routine follow-up is unknown; the retained spreadsheet is not a comprehensive screening log. Fourth, multiple crowns were placed within individual children, and within-child correlation could not be accommodated in time-to-event inference because restoration-level censoring dates were unavailable.

Fifth, physiological exfoliation varies with age and dental development and may affect the opportunity to document restoration outcomes. Individual root-resorption and exfoliation histories were insufficient for age-stratified time-to-event or competing-risk analyses. Sixth, detailed pretreatment tooth characteristics, pulpectomy-related factors, and standardized radiographic outcomes were not consistently available; because all included teeth underwent pulpectomy, its independent association with restoration outcomes could not be estimated. Seventh, the absence of a concurrent comparison group prevented direct comparison with other anterior restorative approaches, including composite strip crowns and preveneered stainless-steel crowns. Eighth, routine assessments were performed by the treating clinicians without formal calibration, introducing potential observer-related variability. Ninth, general-anesthesia treatment at the study institution was restricted to systemically healthy children, which limits generalizability to children with systemic diseases treated in specialized centers.

5. Conclusions

In this retrospective review of zirconia crowns placed on pulpectomized maxillary primary incisors during treatment under general anesthesia, the available records documented five failures within 18 months and two additional later failures. Debonding and trauma-related damage to the restored tooth–crown complex represented distinct documented outcomes; no intrinsic zirconia crown fracture was recorded. Because event-free follow-up and censoring dates were not reliably available for all restorations, these observations should not be interpreted as estimates of survival, failure incidence, or long-term durability. The findings emphasize the importance of distinguishing restoration-related and tooth-related complications and of systematic restoration-level documentation in future research.

Author Contributions: Conceptualization, M.C.K.; methodology, M.C.K.; software, A.M. and D.Ö.Y.; validation, K.C. and M.C.K.; formal analysis, O.M.; writing—original draft preparation, A. M and M.C.K.; writing—review and editing, M.C.K. and K.C. All authors have read and agreed to the published version of the manuscript.

Funding: This research received no external funding.

Institutional Review Board Statement: The study was conducted in accordance with the Declaration of Helsinki and approved by the Scientific Research Ethics Committee of Biruni University (approval number: 2024-BİAEK/24-24; date of approval: 16 September 2026).

Informed Consent Statement: Written informed consent was obtained from the parents or legal guardians of all children participating in the study.

Data Availability Statement: The data supporting the findings of this study are available from the corresponding author upon reasonable request. The data are not publicly available due to patient privacy and ethical restrictions.

Conflicts of Interest: The authors declare no conflict of interest.

References

1. Uribe, S.E.; Innes, N.; Maldupa, I. The global prevalence of early childhood caries: A systematic review with meta-analysis using the WHO diagnostic criteria. *Int. J. Paediatr. Dent.* **2021**, *31*, 817–830. [CrossRef] [PubMed]
2. Piekoszewska-Ziętek, P.; Turska-Szybka, A.; Szczepanik, A.; Olczak-Kowalczyk, D. Early childhood caries and oral health-related quality of life in preschool children: A systematic review. *J. Clin. Med.* **2026**, *15*, 4314. [CrossRef] [PubMed]
3. Nadelman, P.; Magno, M.B.; Pithon, M.M.; de Castro, A.C.R.; Maia, L.C. Does the premature loss of primary anterior teeth cause morphological, functional and psychosocial consequences? *Braz. Oral. Res.* **2021**, *35*, e092. [CrossRef] [PubMed]
4. Oliveira, R.C.; Garbim, J.R.; Passaro, A.L.; Tedesco, T.K.; Raggio, D.P. Restorative strategies for deciduous anterior teeth: A systematic review and meta-analysis. *Evid. Based Dent.* **2025**, *26*, 149. [CrossRef] [PubMed]
5. Khalil, A.S.; Alrehaili, R.S. Prefabricated zirconia crowns versus alternative full-coverage restorations for primary anterior teeth: A systematic review of clinical outcomes. *Eur. Arch. Paediatr. Dent.* **2026**, *27*, 983–995. [CrossRef] [PubMed]
6. Chen, Y.; Pu, H.; Xu, R.; Zeng, R. Effectiveness of prefabricated zirconia crowns and resin-bonded composite strip crowns in the restoration of pediatric primary anterior teeth: A systematic review and meta-analysis. *BMC Oral Health* **2026**, *26*, 369. [CrossRef] [PubMed]
7. Han, M.K. Advances and challenges in zirconia-based materials for dental applications. *J. Korean Ceram. Soc.* **2024**, *61*, 783–799. [CrossRef]
8. American Academy of Pediatric Dentistry. Behavior guidance for the pediatric dental patient. In *The Reference Manual of Pediatric Dentistry*; American Academy of Pediatric Dentistry: Chicago, IL, USA, 2025; pp. 379–399.
9. Seminario, A.L.; Garcia, M.; Spiekerman, C.; Rajanbabu, P.; Donly, K.J.; Harbert, P. Survival of zirconia crowns in primary maxillary incisors at 12-, 24- and 36-month follow-up. *Pediatr. Dent.* **2019**, *41*, 385–390. [PubMed]
10. Alhissan, A.S.; Pani, S.C. Factors influencing the survival of preformed zirconia crowns in children treated under general anesthesia. *Int. J. Dent.* **2021**, *2021*, 5515383. [CrossRef] [PubMed]
11. Alrashdi, M. Survival analysis of prefabricated zirconia crowns with and without pulpotomy in primary teeth: A retrospective cohort study. *Children* **2024**, *11*, 1402. [CrossRef] [PubMed]
12. Elheeny, A.A.H.; Sermani, D.I. Prefabricated zirconia crown versus resin-bonded composite strip crown in the restoration of primary incisors: A 36-month parallel randomized controlled trial. *Pediatr. Dent. J.* **2024**, *34*, 19–26. [CrossRef]
13. Sulaiman, T.A.; Suliman, A.A.; Abdulmajeed, A.A.; Zhang, Y. Zirconia restoration types, properties, tooth preparation design, and bonding. A narrative review. *J. Esthet. Restor. Dent.* **2024**, *36*, 78–84. [CrossRef] [PubMed]
14. Chatterjee, N.; Ghosh, A. Current scenario on adhesion to zirconia; surface pretreatments and resin cements: A systematic review. *J. Indian Prosthodont. Soc.* **2022**, *22*, 13–20. [CrossRef] [PubMed]
15. Patnana, A.K.; Chugh, A.; Chugh, V.K.; Kumar, P.; Vanga, N.R.V.; Singh, S. The prevalence of traumatic dental injuries in primary teeth: A systematic review and meta-analysis. *Dent. Traumatol.* **2021**, *37*, 383–399. [CrossRef] [PubMed]
16. Day, P.F.; Flores, M.T.; O'Connell, A.C.; Abbott, P.V.; Tsilingaridis, G.; Fouad, A.F.; Cohenca, N.; Lauridsen, E.; Bourguignon, C.; Hicks, L.; et al. International Association of Dental Traumatology guidelines for the management of traumatic dental injuries: 3. Injuries in the primary dentition. *Dent. Traumatol.* **2020**, *36*, 343–359. [CrossRef] [PubMed]
17. Chopra, D.; Guo, T.; Gulati, K.; Ivanovski, S. Load, unload and repeat: Understanding the mechanical characteristics of zirconia in dentistry. *Dent. Mater.* **2024**, *40*, e1–e17. [CrossRef] [PubMed]
18. Vafaei, A.; Alagheband, S.; Ahmadinia, Y.; Sajjadi, S.S.; Teimoory, N.; Fattahi, S.; Khosroshahi, A.R.J. Reasons for repeated general anesthesia for dental treatments of uncooperative children. *Maedica* **2024**, *19*, 66–71. [CrossRef] [PubMed]

Disclaimer/Publisher's Note: The statements, opinions and data contained in all publications are solely those of the individual author(s) and contributor(s) and not of MDPI and/or the editor(s). MDPI and/or the editor(s) disclaim responsibility for any injury to people or property resulting from any ideas, methods, instructions or products referred to in the content.