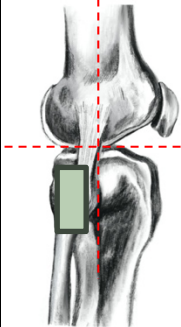
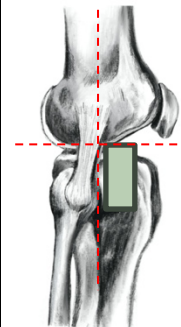
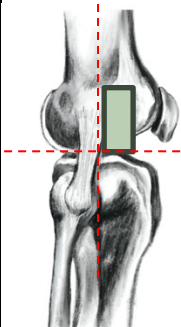
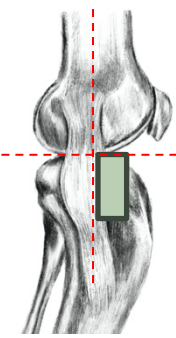
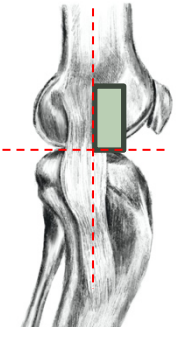
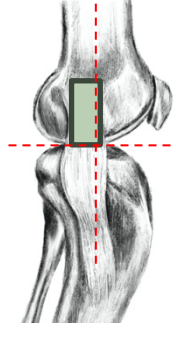



# Image Guide

## Reliability of two recently developed procedures assessing biological maturity by ultrasound imaging

Position 1	<b>Epiphysis Fibula</b> 
Position 2	<b>Epiphysis Tibia lateral</b> 
Position 3	<b>Epiphys Femur lateral</b> 

Position 4	Epiphysis <b>Tibia medial</b> 
Position 5	Epiphysis <b>Femur medial</b> 
Position 6	Ossification ratio <b>Femur medial</b> 

 = placement of the US-probe

References:

- 1) Own images