biomedicines

MDPI

Perspective

Cardiomyopathies: Temporal Review and Genetic Determination

Gaetano Thiene *, Stefania Rizzo and Cristina Basso

Department of Cardiac, Thoracic, Vascular Sciences and Public Health, University of Padua, 35121 Padova, Italy; s.rizzo@unipd.it (S.R.); cristina.basso@unipd.it (C.B.)
* Correspondence: gaetano.thiene@unipd.it; Tel.: +39-337386756

Abstract

Cardiomyopathies are a heterogeneous group of diseases of the myocardium associated with dysfunction, with or without a structural substrate. They are frequently genetically determined. The dysfunction may be mechanical, both of the systole and diastole, or electrical, including arrhythmias or conduction disorders. Originally, only dilated, hypertrophic, restrictive–obliterative and arrhythmogenic dysfunctions were considered cardiomyopathies. Nowadays, since dysfunction can also be electric, disorders affected by electrical dysfunction without a structural substrate can be regarded as cardiomyopathies as well. This is the case of channellopathies and ryanodine receptors. This paper is a review of the history of cardiomyopathies, including the issues of their classification and nomination, genetic background and gene therapy.

Keywords: cardiomyopathies; genetics; heart transplant; pathology; sudden death

1. Introduction

In 1980, John F. Goodwin (1918–2001) (Figure 1), Professor of Cardiology at the Westminster Hospital in London and chair of a committee of the WHO, introduced the term cardiomyopathy to describe heart muscle disease of unknown cause and specific heart muscle disease in which the myocardium is associated with multiorgan involvement.



Figure 1. John F. Goodwin, the father of the classification, definition and nomination of cardiomyopathies. He used the term cardiomyopathy for heart muscle diseases of unknown cause and specific heart muscle diseases associated with morbidities of other systems. Modified from [1].

Goodwin's paper was published in the *British Heart Journal* with the title "Report of the WHO/ISFC task force on the definition and classification of cardiomyopathies" [2]. Disorders of the myocardium due to systemic or pulmonary hypertension, coronary artery, cardiac valves and congenital heart diseases were ruled out.

check for updates

Academic Editor: Régis Guieu

Received: 31 July 2025
Revised: 22 September 2025
Accepted: 30 September 2025
Published: 10 October 2025

Citation: Thiene, G.; Rizzo, S.; Basso, C. Cardiomyopathies: Temporal Review and Genetic Determination. *Biomedicines* **2025**, *13*, 2470. https://doi.org/10.3390/biomedicines13102470

Copyright: © 2025 by the authors. Licensee MDPI, Basel, Switzerland. This article is an open access article distributed under the terms and conditions of the Creative Commons Attribution (CC BY) license (https://creativecommons.org/licenses/by/4.0/).

2. Historical Overview

Cardiomyopathies were initially classified as dilated (Figure 2a), hypertrophic (Figure 2b) and restrictive–obliterative (Figure 2c), the latter meaning obliteration of ventricular cavities by eosinophilic endomyocardial inflammation with thrombosis (Loeffler heart disease) (Figure 3). Eosinophilia may be due to eosinophil leukemia or due to intestinal infection by helminths, known in Africa by the name of Davies disease.

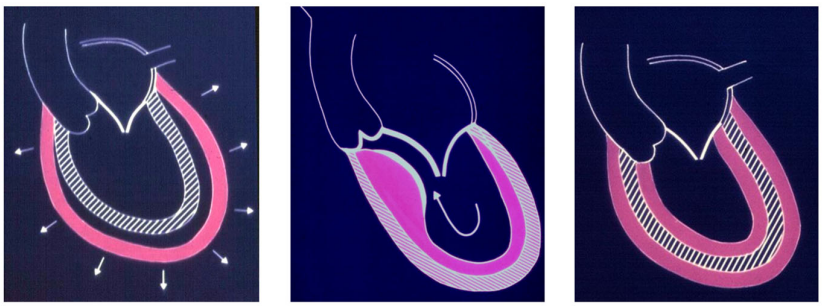

Figure 2. The original classification of cardiomyopathies by John Goodwin [2] was as follows: (**a**) dilated, when the ventricular cavities appear increased in size; The arrows indicate the progressive enlargement of the ventricles in dilated cardiomyopathy; (**b**) hypertrophic, when the free wall or septum are thickened in an asymmetric way; (**c**) restrictive, when the ventricular cavities are reduced in size or even obliterated, with a thickened endocardium and thrombus. The problem is the reduced ventricular cavity, not the stiffness of the ventricular wall, hindering diastolic relaxation [1]. From [1] with permission.

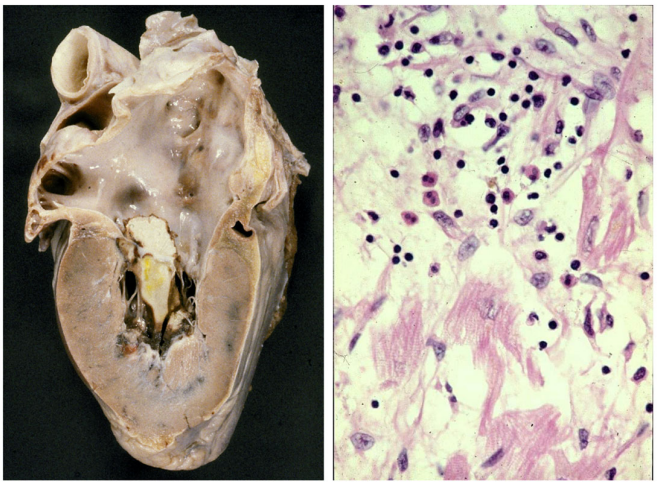

Figure 3. Obliterative cardiomyopathy (**a**) due to endomyocardial eosinophilic inflammation (haematoxylin–eosin stain) (**b**), with thrombosis, known by the name of Loeffer cardiomyopathy in the setting of eosinophil leukemia or by the name of Davies disease when due to intestinal helminth infection with allergic eosinophil inflammation. From [3] with permission.

Concerning dilated cardiomyopathy, ventricular dilatation (Figures 2a and 4a) can be due to poor contractility caused by myocytolysis (Figure 4b) or previous viral myocarditis with scarring from necrosis (Figure 5).

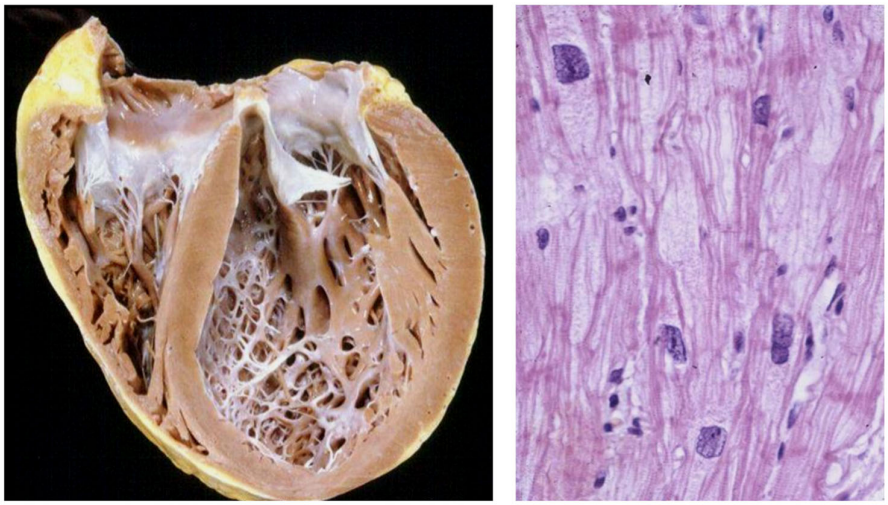

Figure 4. Example of a heart with dilated cardiomyopathy, gross view (**a**), and myocytolysis of cardiomyocytes on histology (**b**), haematoxylin–eosin stain. From [3] with permission.

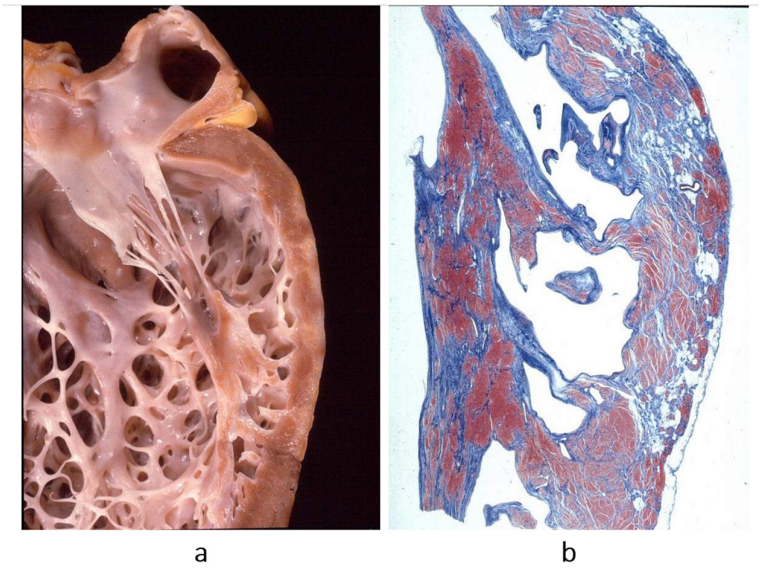

Figure 5. Another type of dilated cardiomyopathy (**a**) with severe, non-ischemic myocardial fibrosis (**b**). The patient previously had viral myocarditis, which accounted for myocyte necrosis and scarring. Azan Mallory stain. From [3] with permission.

As for hypertrophic cardiomyopathy (Figure 2b), it is characterized by asymmetric hypertrophy of the left ventricle, with myocardial disarray at histology (Figure 6), a bizarre tridimensional arrangement of cardiomyocytes initially interpreted as cardiac hamartoma [1].

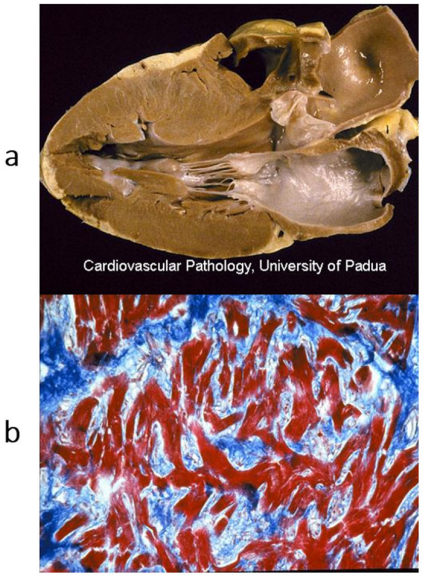

Figure 6. (**a**) Heart specimen with hypertrophic cardiomyopathy due to asymmetric ventricular septum thickness. Hypertrophy, long-axis view. (**b**) Disarray of cardiomyocytes on histology. Originally, the disarray was interpreted as a benign tumour (heart hamartoma). Azan Mallory stain. From [4] with permission.

3. Pathophysiological Classification of Specific Cardiomyopathies

Among specific heart muscle diseases, a series of morbid entities were included [2]:

1. Myocarditis [5].
2. Metabolic diseases (endocrine, storage, amyloid).
3. General system diseases (connective tissue disorders, sarcoidosis, leukemia).
4. Heredofamilial (muscular dystrophies, neuromuscular disorders).
5. Sensitivities and toxic reactions (sulphonamides, alcohol, anthracyclines, irradiation).

Regarding inflammatory myocardial diseases, Fiedler myocarditis [6] (Figure 7) was named "isolated", because only the heart was affected, and "interstitial" because the myocardial interstitium was infiltrated by inflammatory cells, unlike diphtheric myocarditis, in which the damage was only parenchymal. In Fiedler myocarditis, the lymphocytic inflammatory infiltrate (Figure 7a) was most probably due to a viral infection; however, at that time, molecular diagnosis for viral detection was not yet available. A giant cell pattern was also observed in Fiedler myocarditis (Figure 7b), probably ascribable to immune reaction. Sarcoid myocarditis, with non-caseous granuloma, is also most probably immune-related in terms of pathophysiology (Figure 8). It may involve the lymph nodes and other organs like the lungs.

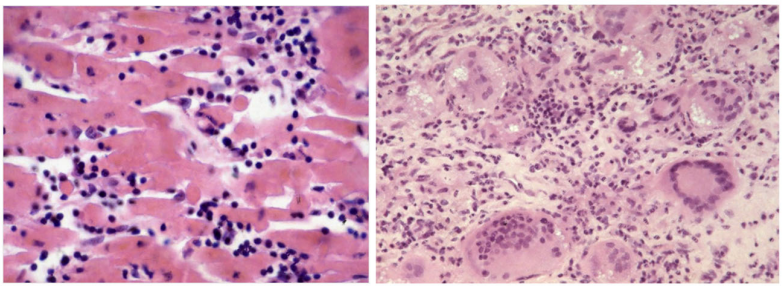

Figure 7. Fiedler's myocarditis on microscopy. A review of the original slides demonstrates two histology patterns: (**a**) lymphocytic inflammatory infiltrates, most probably due to a virus (molecular analysis was not available in that time); (**b**) immunological inflammation of giant cells. Haematoxylin–eosin stain. From [5] with permission.

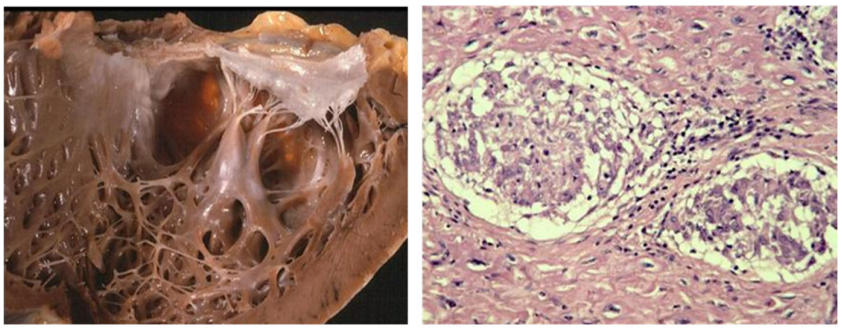

a b

Figure 8. Non-caseous granuloma, typical of sarcoid myocarditis. (**a**) Aneurysm of the left ventricle; (**b**) giant cells in the setting of non-caseous granuloma. Haematoxylin–eosin stain. From [3] with permission.

4. Storage- and Interstitial-Specific Cardiomyopathies

Intracellular storage occurs in hemochromatosis (Figure 9), glycogenosis (Figure 10) and Fabry's disease. Amyloidosis deposits occur (Figure 11) in the interstitium and in the small vessel wall.

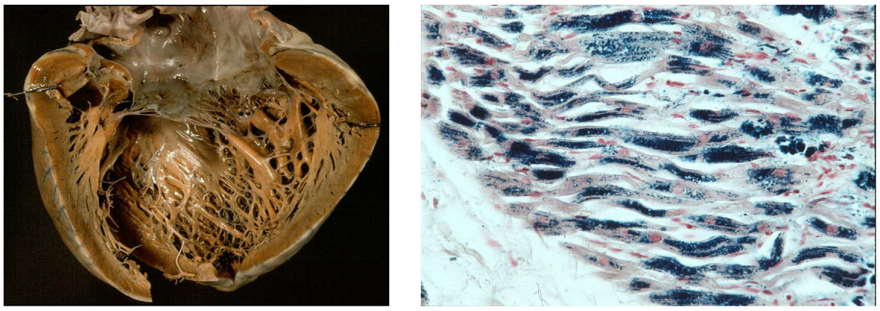

a b

Figure 9. Hemochromatosis cardiomyopathy due to multiple blood infusions. (**a**) The left ventricle shows a brown colour; (**b**) intracellular iron storage. Iron histochemical staining (personal archive).

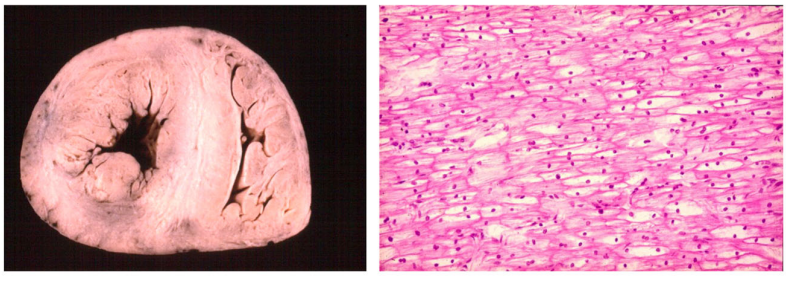

a b

Figure 10. Glycogenosis: (**a**) concentric ventricular hypertrophy with a pale myocardium, cut in short-axis view; (**b**) cardiomyocytes appear empty because glycogen storage was mostly removed by technical procedures (personal archive).

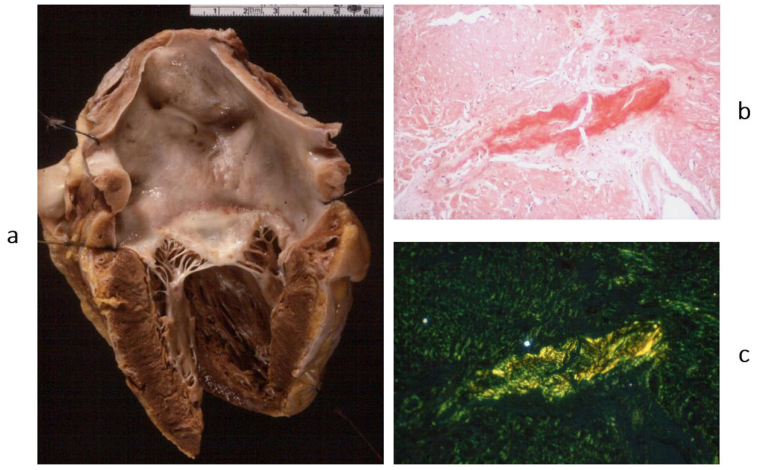

Figure 11. Amyloid deposits in the interstitium of the ventricular myocardium: (**a**) The left cardiac chamber appears dilated and stiff, particularly the left atrium. The patient suffered from atrial fibrillation. (**b**) The amyloid deposits were extracellular within the interstitium and stained with Congo Red and (**c**) Thioflavin-T stain. From [3] with permission.

5. Chronology of WHO Classification

After the WHO classification of 1980 [7], another two cardiomyopathies were discovered: arrhythmogenic right ventricular [8] (Figure 12) and, more recently, arrhythmogenic left ventricular (Figure 13). They are characterized by fibrofatty replacement of the myocardium in the subepicardium and are at high risk of arrhythmic sudden death.

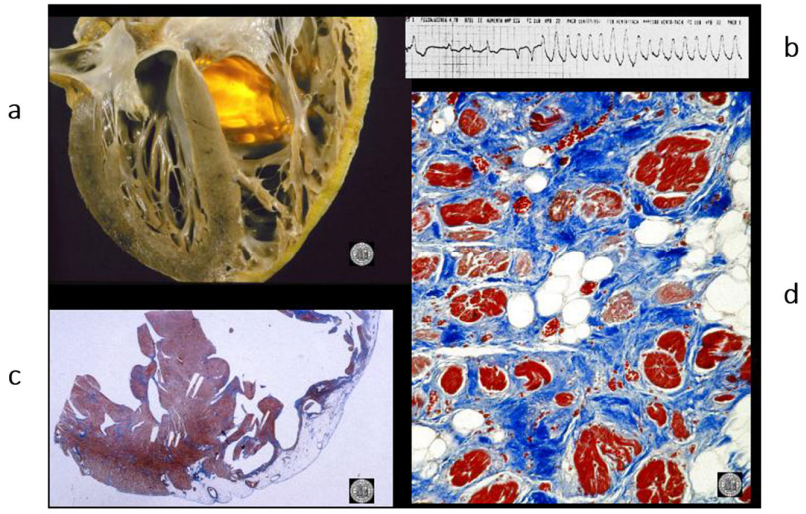

Figure 12. A case of an athlete who died suddenly from right ventricular arrhythmogenic cardiomyopathy during tennis play. (**a**) Four-chamber cut. Gross appearance of the right ventricle with transmural fibrofatty replacement and translucent free wall. (**b**) ECG recording ventricular tachyarrhythmia. (**c**) Compare the histology of the left and right ventricles. The former has an intact myocardium; the latter has transmural fibrofatty tissue. Also, the ventricular septum is intact (Azan Mallory stain). (**d**) Histology of the right ventricle at higher magnification, with fibrofatty replacement (Azan Mallory stain). From [4] with permission.

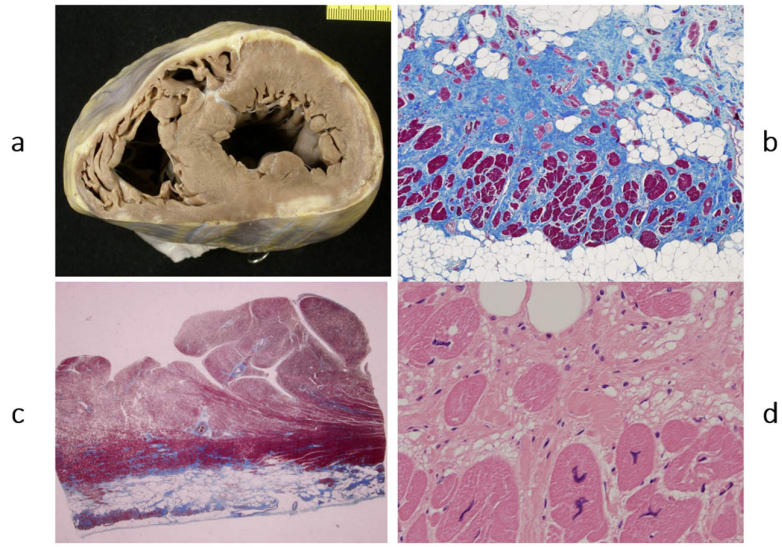

Figure 13. Sudden death from arrhythmogenic cardiomyopathy of the left ventricle. It occurred in a 27-year-old hockey player. (**a**,**b**) Spots of fibrofatty replacement of the myocardium of the subepicardium of the left ventricle, gross and histologic views. (**c**,**d**) Other histologic slides at high magnification, showing fibrofatty replacement. Azan Mallory stain (personal archive).

The second novel type of cardiomyopathy is restrictive, not obliterative, characterized by stiff diastole with poor ventricular relaxation and by atrial dilatation in the absence of ventricular hypertrophy. The heart is small, and the diastolic ventricular filling is hindered by severe congestive heart failure. When compared with dilated cardiomyopathy, restrictive cardiomyopathy represents the paradox of a small heart requiring transplantation (Figure 14). The histology of the ventricular myocardium shows myocardial disarray, like in hypertrophic cardiomyopathy (Figure 15b). Myocardial disarray accounts for impairment of diastolic ventricular filling. This is the reason why both cardiomyopathies are characterized by atrial fibrillation. Restrictive cardiomyopathy is nowadays jokingly called "hypertrophic cardiomyopathy without hypertrophy".

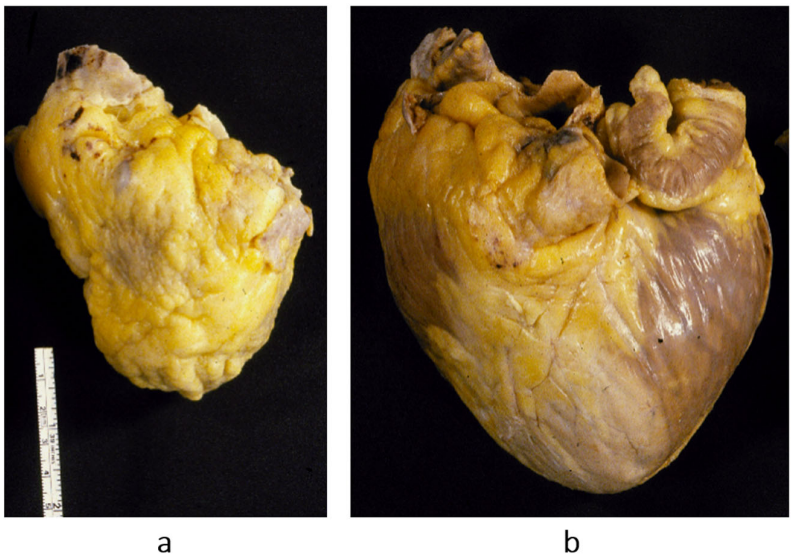

Figure 14. The paradox of a small heart with restrictive cardiomyopathy (**a**), compared with dilated cardiomyopathy (**b**). Both were patients with severe congestive heart failure requiring transplant. From [1] with permission.

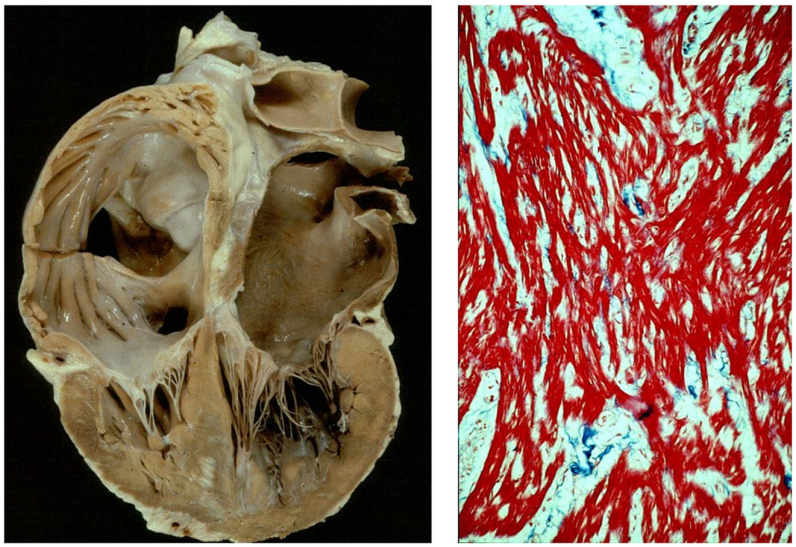

Figure 15. Restrictive cardiomyopathy (not obliterative). (**a**) Gross view of four-chamber section showing dilated atria. Note that the ventricular chambers do not exhibit obliteration. The hindered ventricular diastole-like appendages of the ventricles are due to stiff ventricular walls. (**b**) Histology show myocardial disarray, similar to that in hypertrophic cardiomyopathy. Azan Mallory stain.

The discovery of arrhythmogenic cardiomyopathy [8] and restrictive cardiomyopathy [1] required a review of the WHO classification. In June 1995, the WHO committee met in Genève, chaired by Paul Richardson. A new definition and classification was advanced [9].

6. Storytelling of Definition and Classification of Cardiomyopathies

Tables 1 and 2 compare the definitions and classifications of 1980 vs. 1996. As for the definition of cardiomyopathy, it was changed from "heart muscle disease of unknown cause" to "disease of the myocardium associated with cardiac dysfunction". And the definition of specific heart disease was changed in specific cardiomyopathy, so that the term cardiomyopathy was employed for any heart muscle disease (Table 1).

Table 1. Definitions: 1980. vs. 1996.

1980	1996
Cardiomyopathy, definition	Cardiomyopathy, definition
Heart muscle disease of unknown cause	Disease of the myocardium associated with cardiac dysfunction
Specific heart muscle disease, definition	Specific cardiomyopathy, definition
Heart muscle disease of unknown cause or associated with disorders of other systems	Heart muscle disease associated with specific systemic disorders

Table 2. Update of the WHO classification of cardiomyopathies: 1980 vs. 1996.

1980 Classification	1996 Classification
Dilated	Dilated
Hypertrophic	Hypertrophic
Obliterative	Restrictive
	Arrhythmogenic right ventricular

New entities (arrhythmogenic and restrictive non obliterative) were added to the cardiomyopathy classification (Table 2). The new classification was published in *Circulation* in 1996 [9].

Some cardiomyopathies remained unclassified (Table 3).

Table 3. WHO unclassified cardiomyopathies.

1980 Unclassified	1996 Unclassified
Endocardial fibroelastosis	Endocardial fibroelastosis
Histiocytoid cardiomyopathy	Non compacted myocardium
Fiedler's myocarditis	Mitochondrial cardiomyopathy

Endocardial fibroelastosis (=dilated cardiomyopathy in children) (Figure 16) appears among unclassified cardiomyopathies both in 1980 and 1995 (Table 3).

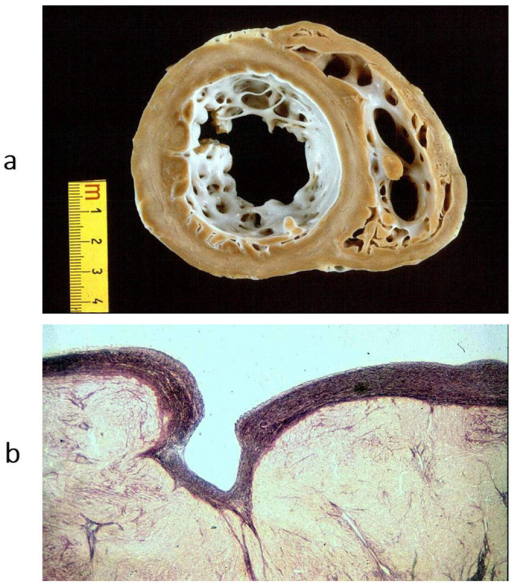

Figure 16. Endocardial fibroelastosis, considered for years an unclassified cardiomyopathy. The trouble was whether to consider it a congenital heart disease (because it is due to prenatal infection) or an early onset of cardiomyopathy. Eventually, it was discovered that it is the consequence of an infection with mumps virus, transmitted at the time of conception by the parents. (**a**) A thick, white endocardium is visible on the cross-section of the left ventricles. (**b**) Close-up of the endocardium on histology; it appears thickened by proliferation of elastic fibres. Weigert–Van Gieson stain. From [3] with permission.

More recently, in 1997, the aetiology of endocardial fibroelastosis was determined to be an infection in the uterus due to mumps virus of the myocardium thanks to molecular investigation [10,11].

Histiocytoid cardiomyopathy was definitively interpreted as a tumour of Purkinje cells (Purkinjoma) (Figure 17) [12].

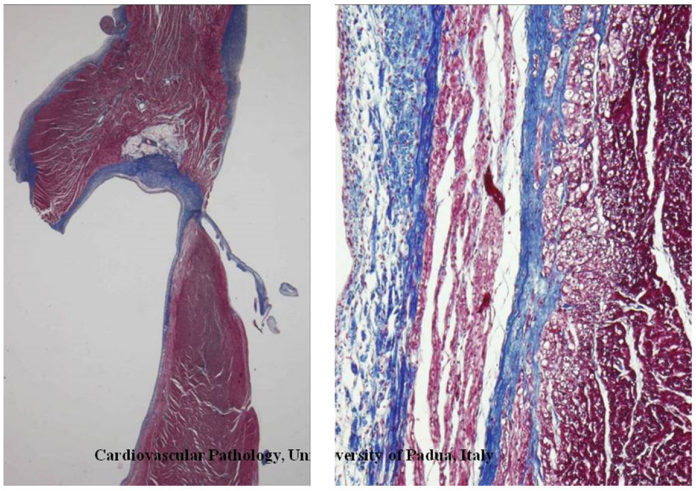

Figure 17. Proliferation of Purkinje cells: cardiomyopathy, congenital heart disease or multifocal tumour of conduction tissue? The histology clearly shows an exuberant number of Purkinje cells, in keeping with a neoplastic phenomenon. (**a**) Histologic section of the atrioventricular junction and the AV conduction system; (**b**) proliferation of Purkinje cells. Azan Mallory stain (personal archive).

In 1996, a non-compacted left ventricular myocardium (Figure 18) was still considered an unclassified cardiomyopathy. Lack of ventricular wall compaction is an embryological defect, so the disease should be considered a congenital heart disease [13].

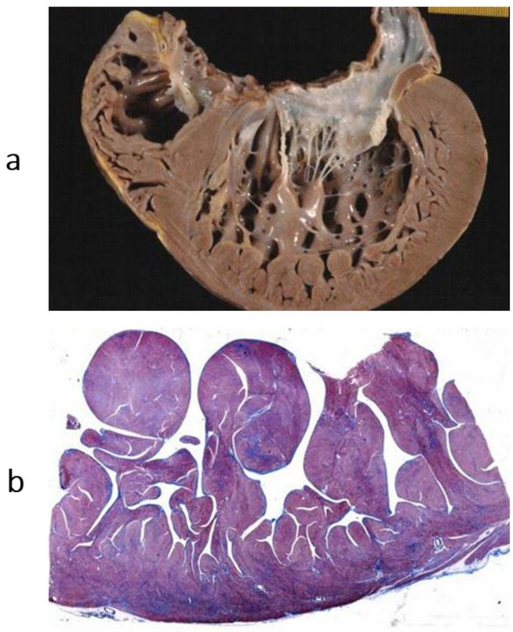

Figure 18. Non-compacted left ventricle. (**a**) Gross view of the left ventricular cavity, seen in the four-chamber section. The cavity is full of coarse trabeculae. On echo, the diagnosis that was put forward was dilated cardiomyopathy with mural thrombi. The patient underwent successful cardiac transplantation. (**b**) The histology of the trabeculae shows the endocardium almost touching the epicardium. The disease is a congenital heart disease because of embryological failure that occurred due to compacting myocardial trabeculae of the left ventricle. Haematoxylin–eosin stain. From [14] with permission.

Nowadays, Fiedler's myocarditis [6] is considered a cardiomyopathy, as any other viral or immunological myocarditis.

In 2006, the definition and classification of cardiomyopathies also attracted the interest of the American Heart Association [15]. Table 4 reports the 2006 AHA definition of cardiomyopathies. The goals of the 2006 AHA classification were as follows:

1. Electrical heart dysfunction is a myocardial dysfunction, so channelopathies are cardiomyopathies.
2. When myocardial dysfunction is the consequence of other cardiovascular diseases (valve, hypertension, congenital, coronary artery), it is excluded from the classification of cardiomyopathies.
3. Myocarditis is a cardiomyopathy.

Table 4. The 2006 AHA definition of cardiomyopathies.

2006 AHA Definition of Cardiomyopathies	Cardiomyopathies are a heterogeneous group of diseases of the myocardium associated with mechanical and/or electrical dysfunction that usually (but not invariably) exhibit inappropriate ventricular hypertrophy or dilatation and are due to a variety of causes, which are frequently genetic.

Cardiomyopathies are a major cause of severe heart failure requiring cardiac transplantation (Table 5). In the experience (1985–2015) of the University of Padua, cardiomyopathies accounted for 51.4% of heart recipients (Table 5) [3].

Table 5. Cardiomyopathy in 876 cases of patients who underwent orthotopic cardiac transplantation (1985–2015).

	%
Dilated Cardiomyopathy	38.7
Hypertrophic Cardiomyopathy	3.0
Restrictive Cardiomyopathy	2.6
Arrhythmogenic Cardiomyopathy	4.2
Myocarditis	2.9
TOTAL	**51.4**

Among cases of sudden death in 650 young people, 31.3% of patients died because they were affected by cardiomyopathies: hypertrophic cardiomyopathy, arrhythmogenic cardiomyopathy and myocarditis (Table 6) [3].

Table 6. Cardiomyopathies among 650 cases of sudden cardiac death in the young (1980–2016).

	%
Dilated Cardiomyopathy	0.3
Hypertrophic Cardiomyopathy	9.0
Restrictive Cardiomyopathy	0.0
Arrhythmogenic Cardiomyopathy	10.0
Myocarditis	12.0
TOTAL	**31.3**

7. Genetic Background of Cardiomyopathies

Cardiomyopathies are usually genetically determined. Hippocrates stated that diseases may be handed down from parents to offspring from the very moment of conception. Table 7 reports the classification of inherited cardiomyopathies caused by defective genes and wrong-coded proteins: cytoskeleton, sarcomere, desmosome, and ion channels.

Table 7. Genetical determined cardiomyopathies.

Name	Phenotypic Expression
Dilated	=cytoskeleton cardiomyopathy
Hypertrophic and restrictive	=sarcomere cardiomyopathy
Arrhythmogenic RV, Naxos diseases	=desmosomal cardiomyopathy
Long and short QT syndromes, Brugada syndrome, catecholaminergic polymorphic VT, Lenegre disease	=ion channel, cardiomyopathy =ryanodine receptor

1. Dilated cardiomyopathy is mostly related to gene defects of cytoskeleton proteins of the nuclear and cell membranes. Missense mutation of lamin A/C and truncation of titin give origin to genetically determined cardiomyopathies, the former also accounting for AV conduction disturbances.
2. Hypertrophic and restrictive cardiomyopathy are both due to mutations of genes coding sarcomere proteins [16,17].
3. Arrhythmogenic cardiomyopathy is the consequence of mutations of genes coding desmosome proteins (Figure 19) [18].

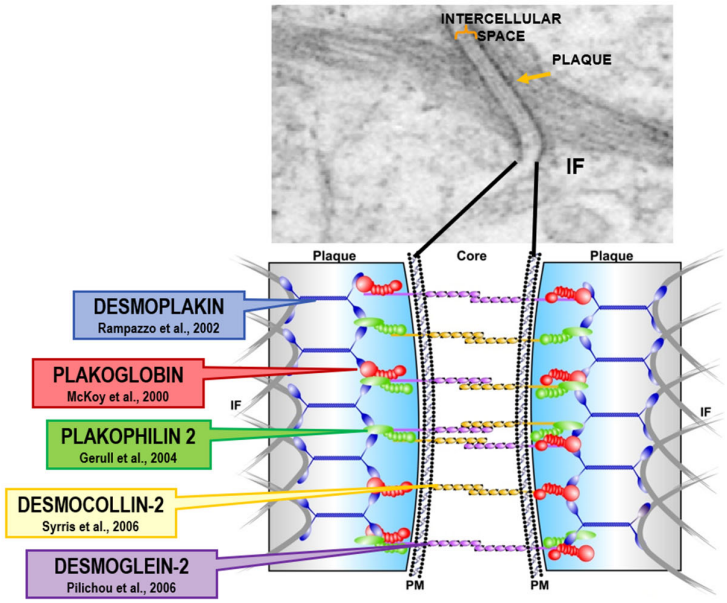

Figure 19. Arrhythmogenic cardiomyopathy is a genetically determined cardiomyopathy caused by missense dominant mutations of genes coding desmosomal proteins of the intercellular junction. Recessive arrhythmogenic cardiomyopathy of the Naxos isle is due to deletion of Plakoglobin gene. From [19] with permission.

4. Long QT (Figure 20a), short QT (Figure 20b), Brugada syndrome with non-ischemic ST elevation (Figure 20c), polymorphic catecholaminergic ventricular tachycardia (Figure 20d) and Lenegre disease (Figure 21) are ion channel and ryanodine receptor cardiomyopathies.

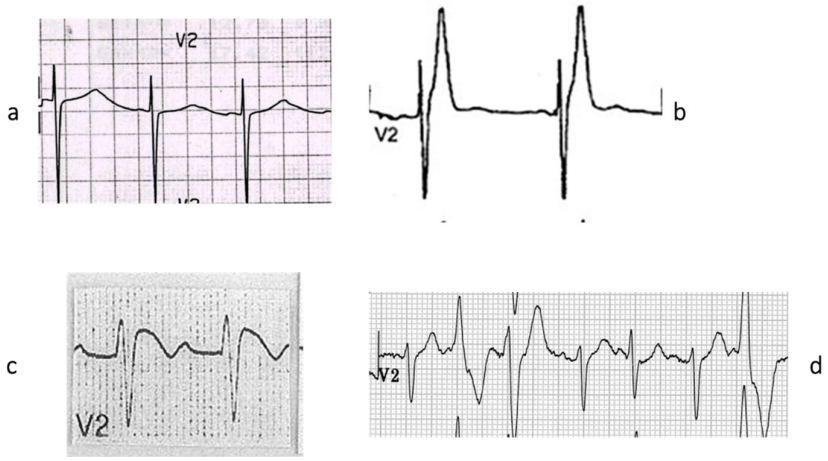

Figure 20. There are genetically determined cardiomyopathies without structural substrate and electrical dysfunction. This is the case of long QT (**a**) and short QT (**b**) interval and non-ischemic ST segment elevation in Brugada syndrome (**c**), called channelopathies of sodium, potassium, and polymorphic ventricular tachycardia caused by calcium ryanodinic receptor due to their electro-anatomic mechanical association (**d**) (personal archive).

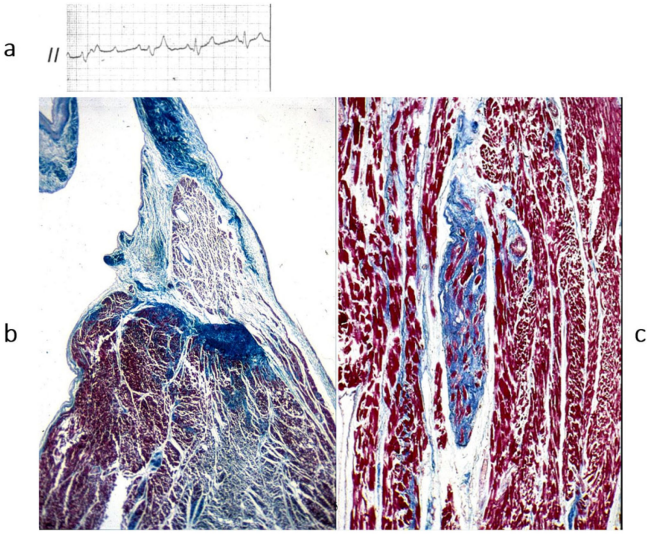

Figure 21. Also, AV block may be to a sodium channelopathy. (**a**) AV block on ECG; (**b**) fibrotic disruption of bundle of His bifurcation; (**c**) right bundle branch is replaced by fibrosis. Azan Mallory stain. The inherited AV block of Lenegre should be considered a cardiomyopathy of the conduction system. From [4] with permission.

Also, complete AV block may be inherited, with the name of Lenegre disease (Figure 21).

Thus, mutations of sodium "channel I5" account for long QT, Brugada syndrome and Lenegre disease. The latter is an example of a genetically determined cardiomyopathy of the conduction tissue (Figure 21).

They should be considered cardiomyopathies, regardless of the type of cardiac dysfunction: contractile, electric, intercellular junction, electromechanical association or electric stimulus conduction.

Refs. [17,18,20–28] deal with the discoveries of the genetic background of cardiomyopathies. A proposal was advanced of a genetic classification for inherited cardiomyopathies.

8. Is It Time for Gene Therapy?

Genetically determined cardiomyopathies are caused by mutations or deletions of DNA.

Recent studies suggested that gene therapy may be a potent molecular option for the treatment of genetically determined cardiomyopathies, like for hypertrophic cardiomyopathy due to myosin mutations and for catecholaminergic polymorphic ventricular tachycardia. Gene therapy is based upon the introduction of genetic material into cardiomyocytes.

There are several strategies involving DNA and RNA messengers.

9. DNA Action Strategies for Genetic Therapy [29]

1. Gene replacement by viral vector, with the delivery of a healthy gene copy, introduced into the cardiomyocyte by a viral vector. DNA adenovirus is the most used. However, adenovirus is a frequent etiology of viral myocarditis, so using this vector may result in a huge inflammatory response, with a risk of iatrogenic death.
2. Modification of signal pathways.
3. Inactivation of mutant gene by cleavage of the endogenous DNA to prevent its expression.
4. Mutation repair by restoring healthy genes after cleavage.
5. Oligonucleotides are short DNA or RNA molecules that can be used to perturb gene expression in target cells. They may be expressed by viral vectors or chemically synthesized and delivered systemically.
6. Modified RNA messengers may be synthesized by in vitro transcription using modified nucleotides, designed to allow them to enter inside the cardiomyocytes without immune reaction and rapid translation into protein.

10. Final Reflections

Thanks to the discovery of DNA by James Watson and Francis Crick (Figure 22) [30] and the invention of polymerase chain reaction by Kary Banks Mullis (Figure 23) [31], molecular diagnosis of inherited heart disease is feasible even at autopsy and can be specific. Gene therapy is a life-saving novelty that can prevent the transmission of inherited disease to offspring.

Just like vaccinations led to the disappearance of lethal infective diseases like smallpox, with gene therapy, diseases transmissible to the offspring may also disappear.

Indeed, the dream is the disappearance of every genetic disease in the future, including genetically determined cardiomyopathies (Figure 24), both with and without (Figures 25 and 26) structural defects, both of which pose an equal risk of sudden death.

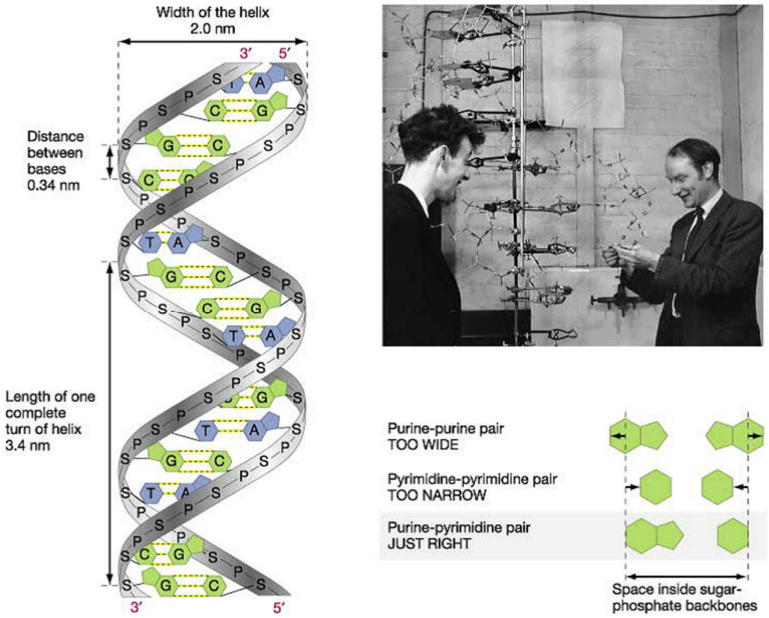

Figure 22. In 1953, James Watson and Francis Crick co-discovered the DNA double helix (public domain).



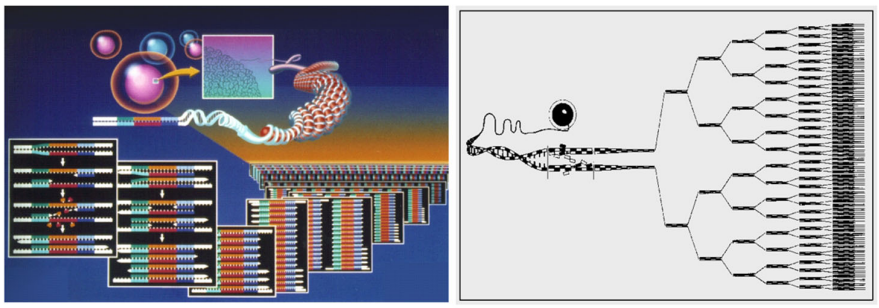

Figure 23. In 1985, Kary Banks Mullis invented the polymerase chain reaction (PCR), a revolution for investigating genetic diseases. From [14] with permission.

In 1894, Karl von Rokitansky and Rudolph Virchow attended a meeting on "Morgagni and the Anatomic Concept" in Rome. Virchow raised the following questions: "…Any anatomic modification is material, but is any material modification anatomic? Why not molecular? Can a profound molecular modification occur in the setting of an apparently normal structure? These modifications belong more to physiology than to anatomy, they are functional-dynamic… the method of investigation will never be morphological".

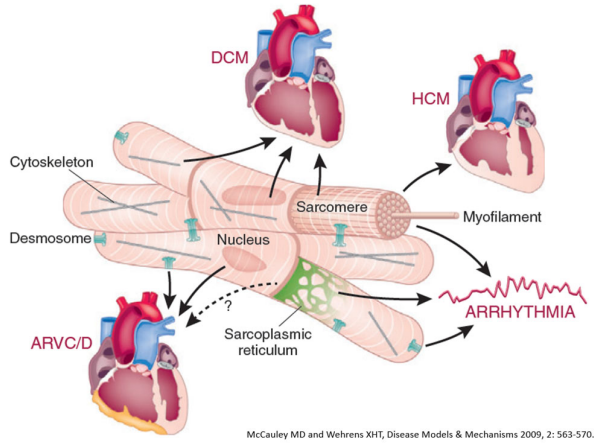

Figure 24. Inherited cardiomyopathies with structural abnormalities: dilated cardiomyopathy (DCM), hypertrophic cardiomyopathy (HCM) and arrhythmogenic right ventricular cardiomyopathy (ARVCM). From [32] with permission.

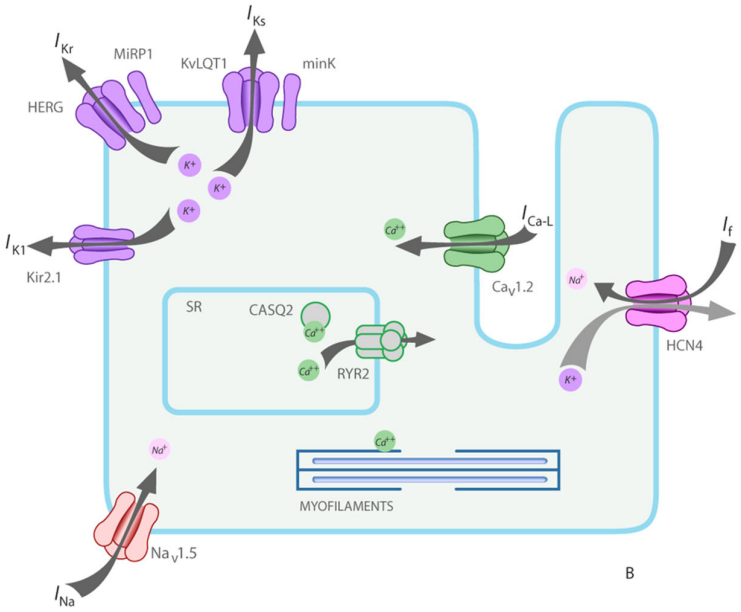

Figure 25. Inherited cardiomyopathies without structural abnormalities due to gene mutation of ion channels and ryanodine receptor. From [33] with permission.

Refs. [34–39] provide further contributions on gene therapy for inherited and genetically determined cardiomyopathies.

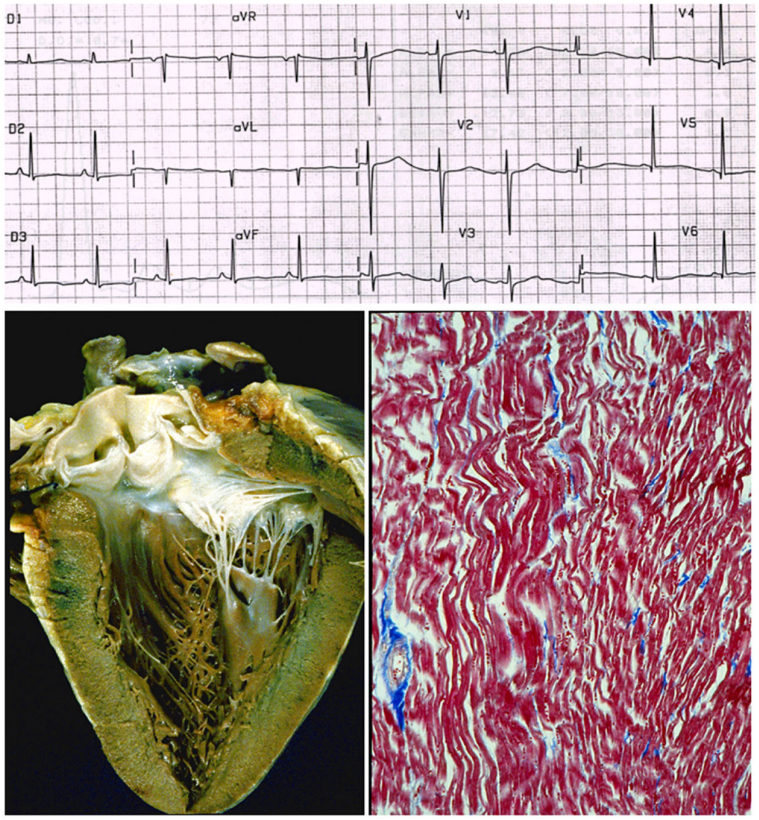

Figure 26. A case of sudden death in a young person due to long QT without structural defects. The ECG shows the long QT, the heart specimen does not exhibit structural defects, and the histology of the myocardium is normal. Azan Mallory stain. Is it a cardiomyopathy? Is long QT a congenital heart disease? From [4] with permission.

Author Contributions: All the authors sharing conceptualization and writing original draft preparation. All authors have read and agreed to the published version of the manuscript.

Funding: This study was supported by the Cardio-Cerebro-Vascular Pathology Registry, Veneto Region, Venice, and by ARCA Foundation, Padua, Italy.

Data Availability Statement: No new data were created or analyzed in this study.

Conflicts of Interest: The authors declare no conflicts of interests.

References

1. Thiene, G.; Calore, C.; De Gaspari, M.; Basso, C. Storytelling of Hypertrophic Cardiomyopathy Discovery. *J. Cardiovasc. Dev. Dis.* **2024**, *11*, 300. [CrossRef]
2. Goodwin, J.F. The frontiers of cardiomyopathy. *Br. Heart J.* **1982**, *48*, 1–18. [CrossRef]
3. McKenna, W.J.; Maron, B.J.; Thiene, G. Classification, Epidemiology, and Global Burden of Cardiomyopathies. *Circ. Res.* **2017**, *121*, 722–730. [CrossRef] [PubMed]
4. Thiene, G.; Corrado, D.; Basso, C. (Eds.) *Sudden Cardiac Death in the Young and Athletes*; Springer: Milano, Italy, 2016; ISBN 978-88-470-5775-3.
5. Thiene, G. Storytelling of Myocarditis. *Biomedicines* **2024**, *12*, 832. [CrossRef] [PubMed]
6. Fiedler KLA. Über akute interstitielle Myokarditis. Dresden, W. Baensch. *Zentralblatt für innere Medizin* **1900**, *21*, 212–213.
7. Report of the WHO/ISFC task force on the definition classification of cardiomyopathies. *Br. Heart J.* **1980**, *44*, 672–673. [CrossRef]
8. Thiene, G.; Nava, A.; Corrado, D.; Rossi, L.; Pennelli, N. Right ventricular cardiomyopathy and sudden death in young people. *N. Engl. J. Med.* **1988**, *318*, 129–133. [CrossRef]
9. Richardson, P.; McKenna, W.; Bristow, M.; Maisch, B.; Mautner, B.; O'Connell, J.; Olsen, E.; Thiene, G.; Goodwin, J.; Gyarfas, I.; et al. Report of the 1995 World Health Organization/International Society and Federation of Cardiology Task Force on the Definition and Classification of cardiomyopathies. *Circulation* **1996**, *93*, 841–842. [CrossRef]

10. Ni, J.; Bowles, N.E.; Kim, Y.H.; Demmler, G.; Kearney, D.; Bricker, J.T.; Towbin, J.A. Viral infection of the myocardium in endocardial fibroelastosis. Molecular evidence for the role of mumps virus as an etiologic agent. *Circulation* **1997**, *95*, 133–139. [CrossRef]
11. Calabrese, F.; Rigo, E.; Milanesi, O.; Boffa, G.M.; Angelini, A.; Valente, M.; Thiene, G. Molecular diagnosis of myocarditis and dilated cardiomyopathy in children: Clinicopathologic features and prognostic implications. *Diagn. Mol. Pathol.* **2002**, *11*, 212–221. [CrossRef]
12. Rizzo, S.; Basso, C.; Buja, G.; Valente, M.; Thiene, G. Multifocal Purkinje-like hamartoma and junctional ectopic tachycardia with a rapidly fatal outcome in a newborn. *Heart Rhythm* **2014**, *11*, 1264–1266.
13. Visonà, S.D.; Thiene, G.; Mannarino, S.; Corana, G.; Osculati, A.; Angelini, A.; Rizzo, S. Noncompaction cardiomyopathy in Hirschsprung's disease: A case report. *Cardiovasc. Pathol.* **2017**, *27*, 51–53. [CrossRef]
14. Thiene, G. Storytelling of Myocardial Biopsy. *Biology* **2025**, *14*, 306. [CrossRef] [PubMed]
15. Maron, B.J.; Towbin, J.A.; Thiene, G.; Antzelevitch, C.; Corrado, D.; Arnett, D.; Moss, A.J.; Seidman, C.E.; Young, J.B.; American Heart Association; et al. Contemporary definitions and classification of the cardiomyopathies: An American Heart Association Scientific Statement from the Council on Clinical Cardiology, Heart Failure and Transplantation Committee; Quality of Care and Outcomes Research and Functional Genomics and Translational Biology Interdisciplinary Working Groups; and Council on Epidemiology and Prevention. *Circulation* **2006**, *113*, 1807–1816. [PubMed]
16. Mogensen, J.; Kubo, T.; Duque, M.; Uribe, W.; Shaw, A.; Murphy, R.; Gimeno, J.R.; Elliott, P.; McKenna, W.J. Idiopathic restrictive cardiomyopathy is part of the clinical expression of cardiac troponin I mutations. *J. Clin. Investig.* **2003**, *111*, 209–216. [CrossRef] [PubMed]
17. Geisterfer-Lowrance, A.A.; Kass, S.; Tanigawa, G.; Vosberg, H.P.; McKenna, W.; Seidman, C.E.; Seidman, J.G. A molecular basis for familial hypertrophic cardiomyopathy: A beta cardiac myosin heavy chain gene missense mutation. *Cell* **1990**, *62*, 999–1006.
18. Rampazzo, A.; Nava, A.; Malacrida, S.; Beffagna, G.; Bauce, B.; Rossi, V.; Zimbello, R.; Simionati, B.; Basso, C.; Thiene, G.; et al. Mutation in human desmoplakin domain binding to plakoglobin causes a dominant form of arrhythmogenic right ventricular cardiomyopathy. *Am. J. Hum. Genet.* **2002**, *71*, 1200–1206. [CrossRef]
19. Thiene, G.; Basso, C.; Pilichou, K.; Bueno Marinas, M. Desmosomal Arrhythmogenic Cardiomyopathy: The Story Telling of a Genetically Determined Heart Muscle Disease. *Biomedicines* **2023**, *11*, 2018. [CrossRef]
20. Herman, D.S.; Lam, L.; Taylor, M.R.; Wang, L.; Teekakirikul, P.; Christodoulou, D.; Conner, L.; DePalma, S.R.; McDonough, B.; Sparks, E.; et al. Truncations of titin causing dilated cardiomyopathy. *N. Engl. J. Med.* **2012**, *366*, 619–628.
21. Fatkin, D.; MacRae, C.; Sasaki, T.; Wolff, M.R.; Porcu, M.; Frenneaux, M.; Atherton, J.; Vidaillet, H.J., Jr.; Spudich, S.; De Girolami, U.; et al. Missense mutations in the rod domain of the lamin A/C gene as causes of dilated cardiomyopathy and conduction-system disease. *N. Engl. J. Med.* **1999**, *341*, 1715–1724. [CrossRef]
22. Chen, Q.; Kirsch, G.E.; Zhang, D.; Brugada, R.; Brugada, J.; Brugada, P.; Potenza, D.; Moya, A.; Borggrefe, M.; Breithardt, G.; et al. Genetic basis and molecular mechanism for idiopathic ventricular fibrillation. *Nature* **1998**, *392*, 293–296. [CrossRef]
23. Wang, Q.; Shen, J.; Splawski, I.; Atkinson, D.; Li, Z.; Robinson, J.L.; Moss, A.J.; Towbin, J.A.; Keating, M.T. SCN5A mutations associated with an inherited cardiac arrhythmia, long QT syndrome. *Cell* **1995**, *80*, 805–811. [CrossRef]
24. Curran, M.E.; Splawski, I.; Timothy, K.W.; Vincent, G.M.; Green, E.D.; Keating, M.T. A molecular basis for cardiac arrhythmia: HERG mutations cause long QT syndrome. *Cell* **1995**, *80*, 795–803. [CrossRef]
25. Schott, J.J.; Alshinawi, C.; Kyndt, F.; Probst, V.; Hoorntje, T.M.; Hulsbeek, M.; Wilde, A.A.; Escande, D.; Mannens, M.M.; Le Marec, H. Cardiac conduction defects associate with mutations in SCN5A. *Nat. Genet.* **1999**, *23*, 20–21. [CrossRef] [PubMed]
26. Brugada, R.; Hong, K.; Dumaine, R.; Cordeiro, J.; Gaita, F.; Borggrefe, M.; Menendez, T.M.; Brugada, J.; Pollevick, G.D.; Wolpert, C.; et al. Sudden death associated with short-QT syndrome linked to mutations in HERG. *Circulation* **2004**, *109*, 30–35. [CrossRef] [PubMed]
27. Priori, S.G.; Napolitano, C.; Tiso, N.; Memmi, M.; Vignati, G.; Bloise, R.; Sorrentino, V.; Danieli, G.A. Mutations in the cardiac ryanodine receptor gene (hRyR2) underlie catecholaminergic polymorphic ventricular tachycardia. *Circulation* **2001**, *103*, 196–200. [CrossRef] [PubMed]
28. McKoy, G.; Protonotarios, N.; Crosby, A.; Tsatsopoulou, A.; Anastasakis, A.; Coonar, A.; Norman, M.; Baboonian, C.; Jeffery, S.; McKenna, W.J. Identification of a deletion in plakoglobin in arrhythmogenic right ventricular cardiomyopathy with palmoplantar keratoderma and woolly hair (Naxos disease). *Lancet* **2000**, *355*, 2119–2124. [CrossRef]
29. Bezzerides, V.J.; Prondzynski, M.; Carrier, L.; Pu, W.T. Gene therapy for inherited arrhythmias. *Cardiovasc. Res.* **2020**, *116*, 1635–1650. [CrossRef]
30. Watson, J.D.; Crick, F.H. Molecular structure of nucleic acids; a structure for deoxyribose nucleic acid. *Nature* **1953**, *171*, 737–738. [CrossRef]
31. Mullis, K.B.; Erlich, H.A.; Gelfand, D.H.; Horn, G.; Saiki, R.K. Process for Amplifying, Detecting, and/or-Cloning Nucleic Acid Sequences. U.S. Patent 4,683,195, 27 November 1990.
32. McCauley, M.D.; Wehrens, X.H. Animal models of arrhythmogenic cardiomyopathy. *Dis. Model Mech.* **2009**, *2*, 563–570. [CrossRef]

33. Thiene, G.; Fedrigo, M. Congenital Heart Disease from Infancy to Adulthood: Pathology and Nosology. *Biomedicines* **2025**, *13*, 875. [CrossRef]
34. Aiuti, A.; Pasinelli, F.; Naldini, L. Ensuring a future for gene therapy for rare diseases. *Nat. Med.* **2022**, *28*, 1985–1988. [CrossRef]
35. Greenberg, B.; Taylor, M.; Adler, E.; Colan, S.; Ricks, D.; Yarabe, P.; Battiprolu, P.; Shah, G.; Patel, K.; Coggins, M.; et al. Phase 1 Study of AAV9.LAMP2B Gene Therapy in Danon Disease. *N. Engl. J. Med.* **2025**, *392*, 972–983. [CrossRef] [PubMed]
36. Henneman, L. Genetic Carrier Screening—Call for a Global Mission. *N. Engl. J. Med.* **2024**, *391*, 1947–1948.
37. Kirk, E.P.; Delatycki, M.B.; Archibald, A.D.; Tutty, E.; Caruana, J.; Halliday, J.L.; Lewis, S.; McClaren, B.J.; Newson, A.J.; Dive, L.; et al. Nationwide, Couple-Based Genetic Carrier Screening. *N. Engl. J. Med.* **2024**, *391*, 1877–1889. [CrossRef]
38. Musunuru, K. A Milestone for Gene-Editing Therapies. *N. Engl. J. Med.* **2025**, *392*, 508–509.
39. Van Voorhis, B.J. Clinical practice. In vitro fertilization. *N. Engl. J. Med.* **2007**, *356*, 379–386.

Disclaimer/Publisher's Note: The statements, opinions and data contained in all publications are solely those of the individual author(s) and contributor(s) and not of MDPI and/or the editor(s). MDPI and/or the editor(s) disclaim responsibility for any injury to people or property resulting from any ideas, methods, instructions or products referred to in the content.