biomedicines

MDPI

Review

Desmosomal Arrhythmogenic Cardiomyopathy: The Story Telling of a Genetically Determined Heart Muscle Disease

Gaetano Thiene *, Cristina Basso, Kalliopi Pilichou and Maria Bueno Marinas

Department of Cardiac, Thoracic, Vascular Sciences and Public Health, Medical School, University of Padua, 35121 Padova, Italy; cristina.basso@unipd.it (C.B.); kalliopi.pilichou@unipd.it (K.P.); maria.bueno.m@gmail.com (M.B.M.)

* Correspondence: gaetano.thiene@unipd.it; Tel.: +39-337386756

Abstract: The history of arrhythmogenic cardiomyopathy (AC) as a genetically determined desmosomal disease started since the original discovery by Lancisi in a four-generation family, published in 1728. Contemporary history at the University of Padua started with Dalla Volta, who haemodynamically investigated patients with "auricularization" of the right ventricle, and with Nava, who confirmed familiarity. The contemporary knowledge advances consisted of (a) AC as a heart muscle disease with peculiar electrical instability of the right ventricle; (b) the finding of pathological substrates, in keeping with a myocardial dystrophy; (c) the inclusion of AC in the cardiomyopathies classification; (d) AC as the main cause of sudden death in athletes; (e) the discovery of the culprit genes coding proteins of the intercalated disc (desmosome); (f) progression in clinical diagnosis with specific ECG abnormalities, angiocardiography, endomyocardial biopsy, 2D echocardiography, electron anatomic mapping and cardiac magnetic resonance; (g) the discovery of left ventricular AC; (h) prevention of SCD with the invention and application of the lifesaving implantable cardioverter defibrillator and external defibrillator scattered in public places and playgrounds as well as the ineligibility for competitive sport activity for AC patients; (i) genetic screening of the proband family to unmask asymptomatic carriers. Nondesmosomal ACs, with a phenotype overlapping desmosomal AC, are also treated, including genetics: Transmembrane protein 43, SCN5A, Desmin, Phospholamban, Lamin A/C, Filamin C, Cadherin 2, Tight junction protein 1.

Keywords: cardiomyopathies; genetic disease; sudden death

check for updates

Citation: Thiene, G.; Basso, C.; Pilichou, K.; Bueno Marinas, M. Desmosomal Arrhythmogenic Cardiomyopathy: The Story Telling of a Genetically Determined Heart Muscle Disease. *Biomedicines* **2023**, *11*, 2018. https://doi.org/10.3390/biomedicines11072018

Academic Editors: Bart De Geest and Marie-Louise Bang

Received: 29 April 2023
Revised: 28 June 2023
Accepted: 10 July 2023
Published: 18 July 2023

Copyright: © 2023 by the authors. Licensee MDPI, Basel, Switzerland. This article is an open access article distributed under the terms and conditions of the Creative Commons Attribution (CC BY) license (https://creativecommons.org/licenses/by/4.0/).

1. The Discovery of Arrhythmogenic Cardiomyopathy

The discovery of arrhythmogenic cardiomyopathy (AC) dates back to the XVIII century [1] when, in 1728, the book *De motu cordis et aneurysmatibus* [2] by Giovanni Maria Lancisi (1654–1720) (Figure 1) was published posthumously.

He reported in four generations of a family exhibiting palpitations, heart failure and sudden cardiac death (SCD). The great-grandfather (first generation) died suddenly and, at autopsy, was found to have an aneurysm of the right ventricle. The grandfather (second generation) complained of palpitations of the heart, dyspnea, swollen feet and wavelike motion of the jugular veins. At dissection, the right ventricle was found to be larger than a clenched fist. The brother of the father (third generation), at over forty years old, was still living and complained of an annoying pulsation in the right side of the chest. Lancisi commented: 'I can only hope that he may not going to end in the same way'. The proband index child (fourth generation) died of epilepsy (syncopal seizures followed by cardiac arrest?). Lancisi opened the cadaver and found the same hereditary weakness of the precordium. The four generations of the family tree were reconstructed (Figure 2) in keeping with a hereditary dominant disease. Clinical and pathological findings were pathognomic for the contemporary AC. The following assertion of Lancisi was visionary: 'It may well be that what I had so far observed only in the right cavities of the heart can also occur in other cavities of the blood as well'.

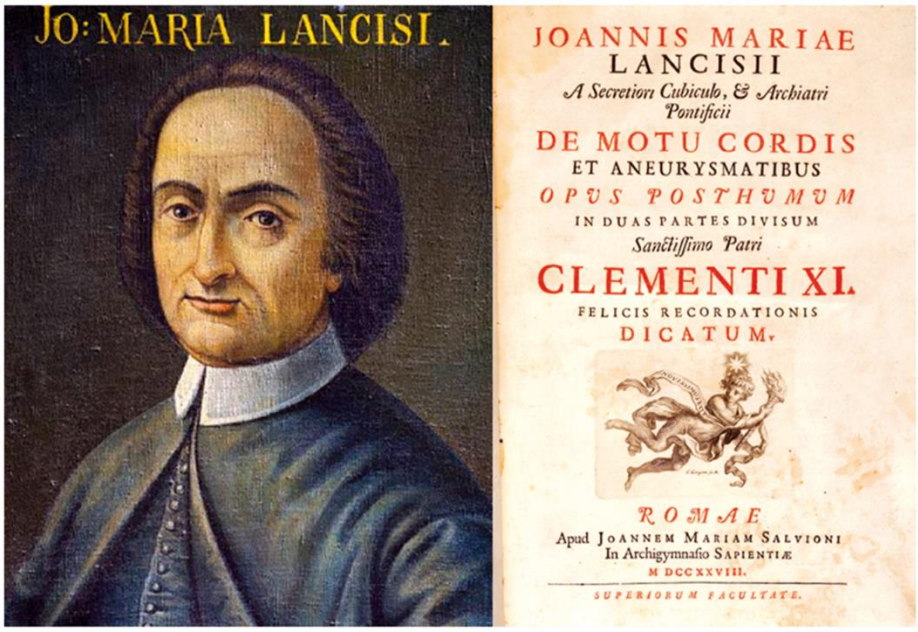

Figure 1. Portrait of Giovanni Maria Lancisi (1654–1720) and title page of his book *De motu cordis et aneurysmatibus*, published posthumously in 1728. From [1].

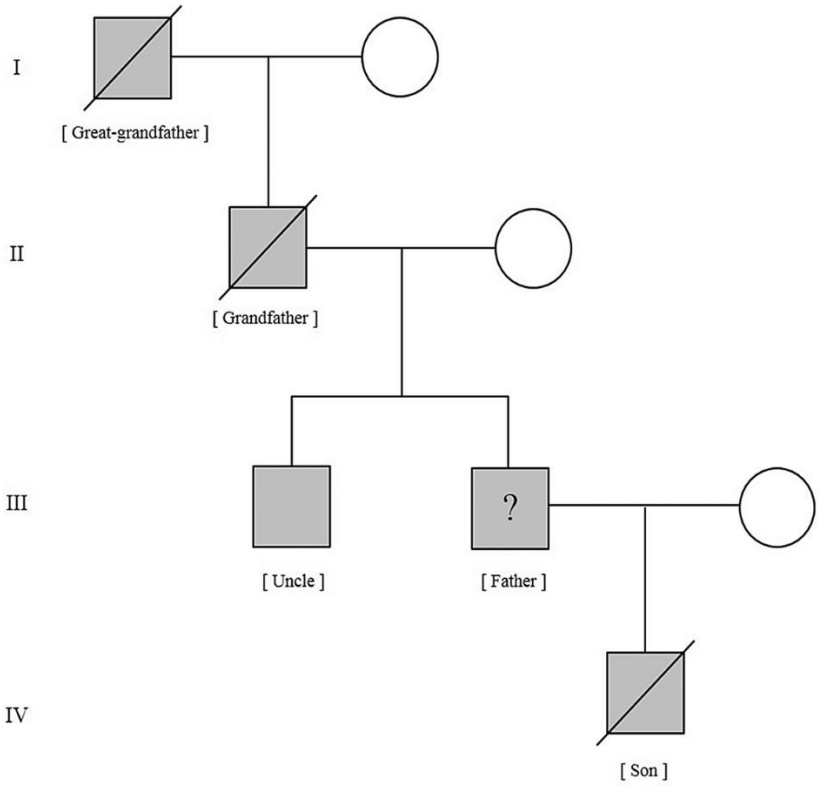

Figure 2. A four-generation family tree, reported by Lancisi, in keeping with a hereditary dominant genetically determined disease. From [1].

In 1736 Lancisi's book was republished by his heirs, with Chapter V entitled *An hereditary predisposition to cardiac aneurysm and bulging* [3].

Moreover, referring to cardiac aneurysms, Lancisi wrote: 'An important sign of that hereditary trouble is a certain pulsation of the right side of the heart. Those who suffer

from it, though in other respects are in good health, assert that they can distinctly feel this after violent physical exertion'.

In chapter VI, Lancisi mentions Hippocrates, the Father of Medicine: 'In Hippocrates it is distinctly taught that diseases may be handed down from parents to children. Therefore no one will deny that disorders of the heart can be handed down from the very moment of conception' [4].

Later, Gregor Mendel (1822–1884) discovered the laws of dominant and recessive inheritance through groundbreaking trait experiments.

One century later, in 1819, René Laennec (1781–1826) (Figure 3) published in Paris the book *De l'auscultation mediate*, a treatise on the diagnosis of chest diseases using the stethoscope. In Book II, Chapter XV, devoted to the accumulation of fat around the heart, he noted: 'In medical writings we find many examples of the heart being overloaded with fat [. . .] and even the sudden death [. . .]. The fatter the heart is, the thinner are its walls. Sometimes these are extremely thin, being reduced almost to nothing, especially at the apex of the heart and the posterior side of the right ventricle. On examining ventricles, the scalpel seems to reach the cavity without encountering almost any muscular substance' [5].

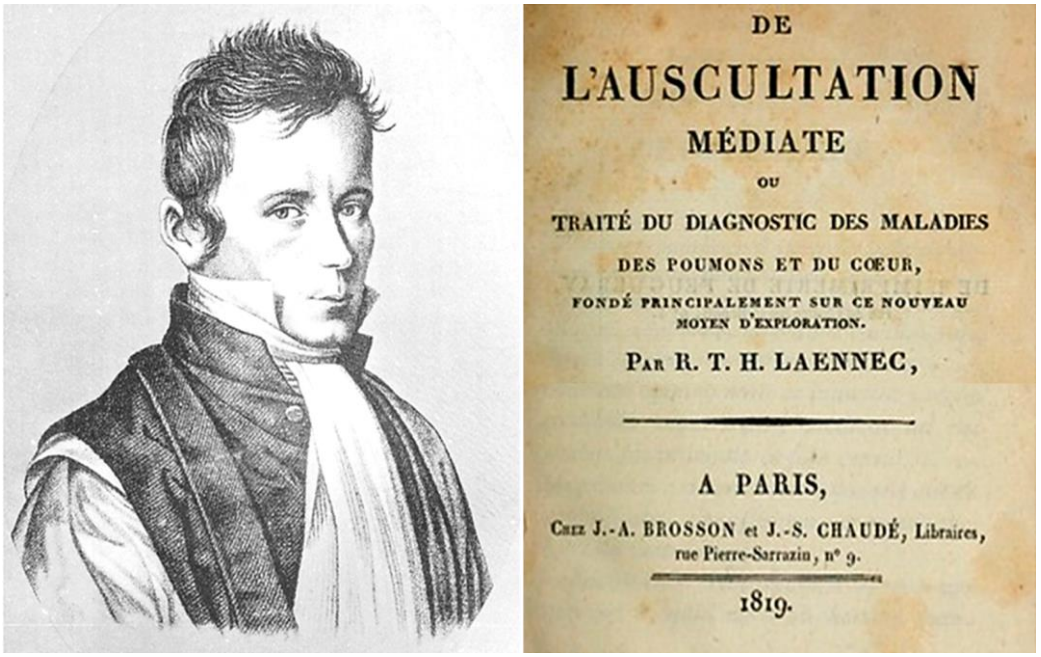

Figure 3. Portrait of René Laennec (1781–1826) and the title page of his book *De l'auscultation mediate*, 1819. From [6].

The description of Laennec is unequivocal: the lesions are located in topographic sites, known nowadays as the 'triangle of dysplasia' [7] and confirmed by subsequent pathological studies [8].

George Eliot (1819–1880), in 1871, published the book *Middlemarch*, where the protagonist Dr. Lydgate, talking with one of his patients, said: 'I believe that you are suffering from what is called fatty degeneration of the heart, a disease which was first divined and explored by Laennec, the man who gave us the stethoscope, not so many years ago. It is my duty to tell you that death from this disease is often sudden. At the same time, no such result can be predicted' [9].

The concept of fatty heart (=adipositas cordis) was also known to Charles Dickens (1812–1870), who described an obese, dyspnoeic and sleepy boy ('the fatty Joe') in his famous book *Pickwick Circle* of 1836–1837 [10].

In the classical textbook of pathology, "*Treatise of special pathological anatomy*", published in 1896 by Eduard Kauffman (1860–1931), lipomatosis, adipositas or obesitas cordis ('Fet-

therz') of the RV received peculiar attention, being observed in subjects dying suddenly [11]. Nowadays, adipositas cordis is classified separately from AC [12].

In 1905, William Osler (1849–1919) (Figure 4A) reported in the VI edition of his famous treatise *The principles and practice of Medicine*, an amazing heart specimen that is now in the McGill College Museum, showing a "parchment-like" thinning of the ventricular walls, uniform dilatation of right auricle and right ventricle, with only epicardium remaining [13] (Figure 4B).

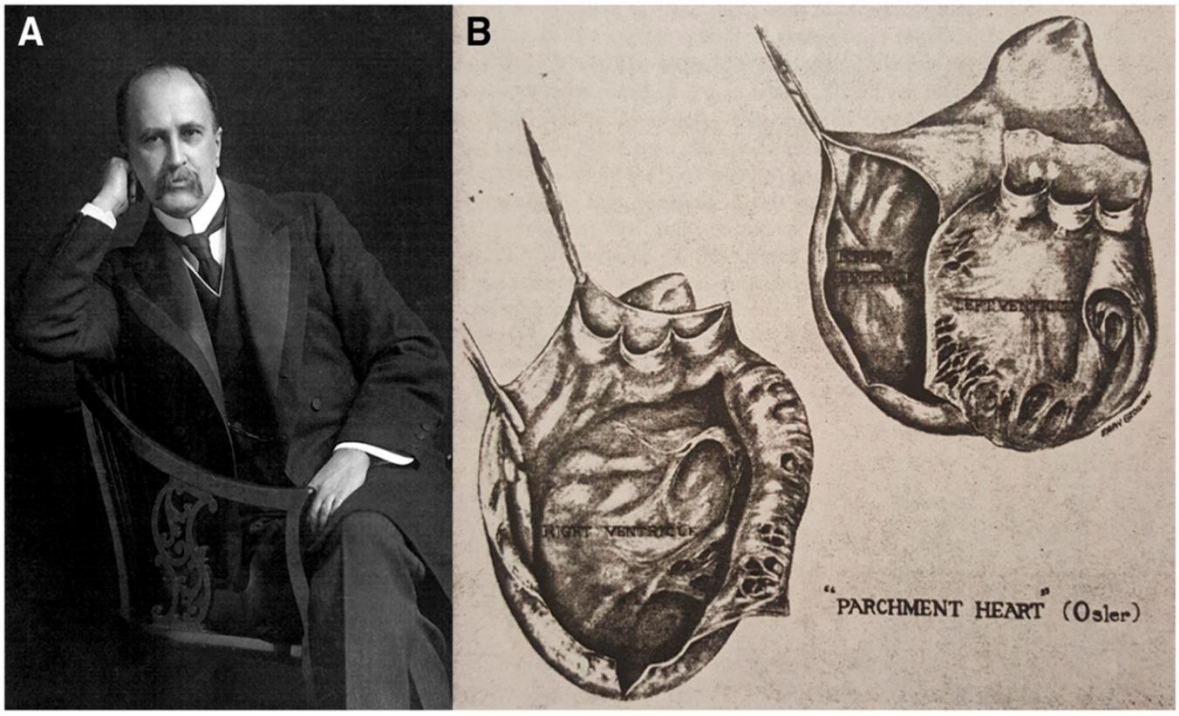

Figure 4. (**A**) Portrait of William Osler (1849–1919). (**B**) The Osler parchment heart. From [1].

The pathologist Maude Abbott (1869–1940), curator of the McGill College Museum, found the aforementioned specimen among those donated by Osler during his professorship in Montreal (1874–1884). Unfortunately, the specimen was not accompanied by clinical and autopsy records. She vaguely remembered that it belonged to a man who had died suddenly while climbing a steep hill. Abbott, in the book of her memoirs written by MacDermot in 1941, told that Osler, having returned to Montreal and visiting the McGill College Museum, might have seen the specimen again and mentioned it in the new edition of his treatise [14].

Harold Segall (1897–1990) had the opportunity to examine the original specimen, preserved in a formalin-filled jar, which appeared as a large cyst (Figure 4B). The coronary arteries were patent so that an ischaemic substrate could be ruled out. Both ventricular walls appeared "parchment-like". The ventricular septum was spared, and the heart weight was only 168 g. Histology disclosed very rare cardiomyocytes in paper-thin ventricular walls. Segall advanced the hypothesis of myocardial dystrophy in a person with generalized muscular dystrophy, such as Duchenne and Becker diseases. However, it is difficult to believe that a patient, able to climb a hill, could be affected by a generalized skeletal muscle dystrophy. He coined the term 'Osler parchment heart' [15].

A controversial case, which has been the source of subsequent misconceptions, was the one observed in 1952 by Henry Uhl (1921–2009) at the Johns Hopkins Hospital in Baltimore in an 8-month-old female infant who died of congestive heart failure in the absence of arrhythmias. The case was published with the title *A previously undescribed congenital malformation of the heart: almost total absence of the myocardium of the right ventricle* [16]. The description deserves to be mentioned: 'Externally the heart appears greatly enlarged, almost

the entire dilated chamber (RV) was occupied by a large laminated mural thrombosis which adhered firmly to the endocardium along the anterior wall of the ventricle. Examination of the cut edge of the ventricle wall revealed it to be paper-thin with no myocardium visible. In the RV wall, epicardium and endocardium lay adjacent to each other with no intervening cardiac muscle. No fibro-fatty tissue in the RV free wall was observed' (Figure 5). The early age of the infant and the peculiar pathological description point to a structural heart disease present at birth (congenital anomaly), as emphasized in the title itself. Whether the disease was a genetically determined AC developed during the fetal period or not remains intriguing. The clinical phenotype was characterized neither by cardiac arrhythmias nor by a family history of heart disease.

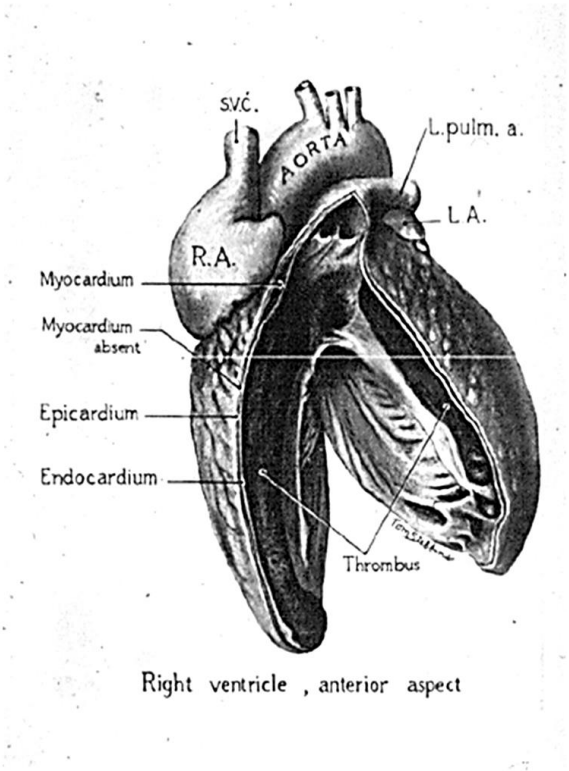

Figure 5. The heart reported by Henry Uhl (1921–2009) with almost total absence of the myocardium of the right ventricle. From [1].

2. Contemporary History of Arrhythmogenic Cardiomyopathy

Adult cases with paper-thin ventricular walls (including Osler's case) unfortunately have been reported with the eponym of Uhl's anomaly, clearly a misnomer because the parchment heart in adults is the end stage of a late progressive loss of the myocardium followed by fibro-fatty replacement [8,12].

French investigators (Robert Froment (cardiologist) and Robert Loire (pathologist)), reported in 1968 cases of 'ventricule droit papyrace' ecg [17]. They were the first to demonstrate that fibro-fatty infiltration of the RV was associated with inverted T waves in the right precordial leads of the ECG.

On the contrary, the cases reported in the literature of infants under the age of 15 months with the eponym of Uhl's anomaly all featured congestive heart failure and isolated RV involvement (whether segmental or diffuse) without arrhythmias, in keeping with the original description by Uhl [12,18].

Since the early 1960s, the University of Padua set milestones in the history of AC. Sergio Dalla Volta, Professor of Cardiology, described 'auricularization of the right ventricular pressure' in six cases using right cardiac catheterization in the absence of an effective RV contraction. The blood was directly pushed into the pulmonary artery by atrial systole [19].

The autopsy finding in two cases with 'sclerosis of the right ventricle' was interpreted as a consequence of myocardial infarction without coronary obstruction, clearly a misdiagnosis [20]. The concept of non-ischaemic cardiomyopathy was still to be conceived. Interestingly enough, out of the six documented cases, ranging from 21 to 40 years old, two had clinically ventricular arrhythmias, five inverted T waves in the precordial leads and four congestive heart failures [20]. One of the latter, a 21-year-old woman in 1996, developed ventricular tachycardia with left bundle branch block (LBBB) morphology and right ventricular failure. She underwent cardiac transplantation, and the removed heart showed an extremely dilated RV with a parchment-like wall (Figure 6).

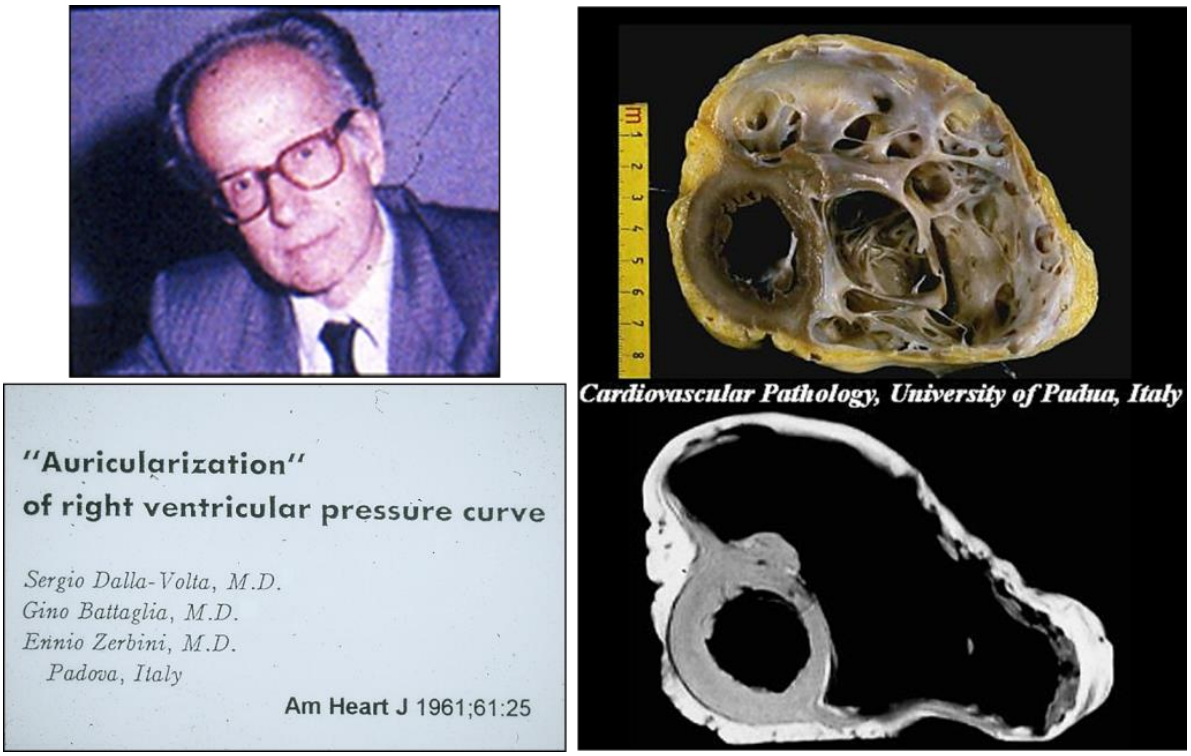

Figure 6. The case published by Sergio Dalla Volta in 1961, with huge dilatation of the right ventricular cavity and paper-thin free wall. In 1996 the patient underwent cardiac transplantation to treat congestive heart failure. From [1], in part.

In 1970 Vito Terribile Wiel Marin (1939–2015), a cardiac pathologist at the Institute of Pathological Anatomy, University of Padua, performed a post-mortem of a 43-year-old lady with a clinical history of palpitations and congestive heart failure, who died of pulmonary thromboembolism. In the autopsy report, he described extreme dilatation, fibro-fatty replacement and mural thrombosis of the RV in association with left ventricular 'myocardial sclerosis' (Figure 7), all features in keeping with what today we call biventricular AC.

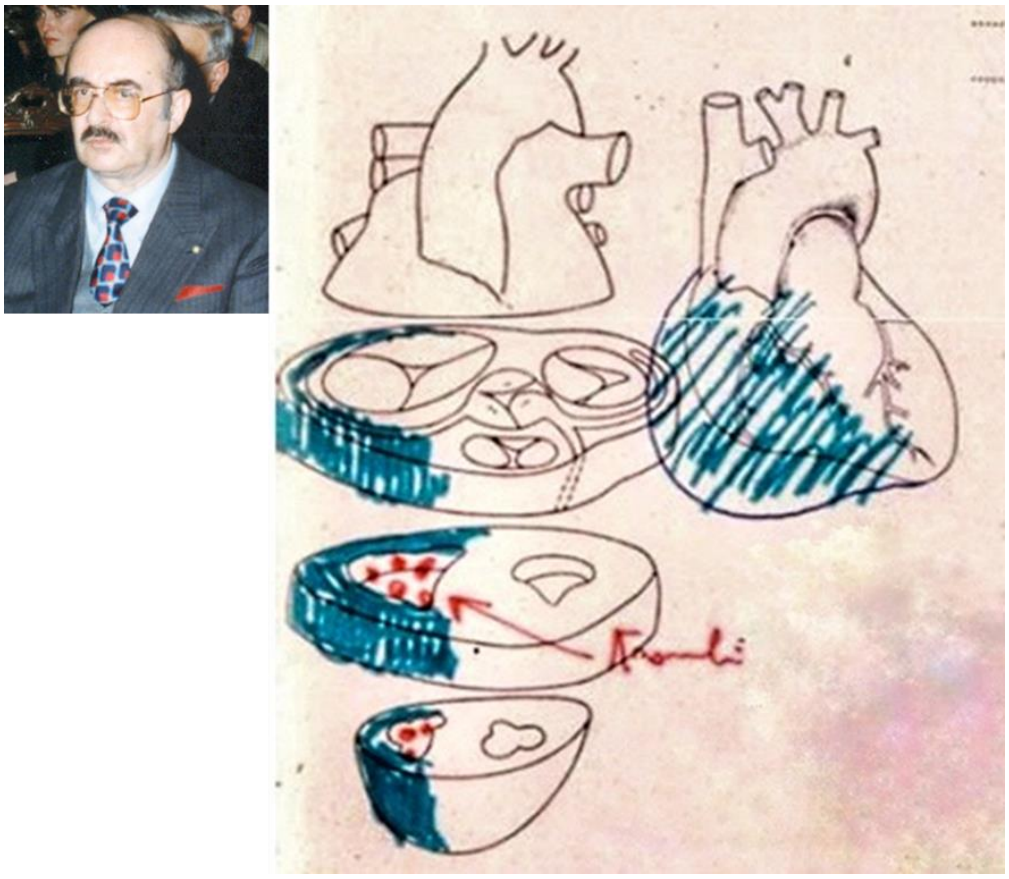

Figure 7. An autopsy case of arrhythmogenic cardiomyopathy of a patient that died in 1970 from pulmonary thromboembolism with mural thrombosis and fibro-fatty replacement of the right ventricle (original drawing from the autopsy report). The red arrow indicates endocardial thrombi, the blue means fibro-fatty replacement. From [6], modified.

3. AC Is a Heart Muscle Disease with Peculiar Electrical Instability

Guy Fontaine, in the late-1970s, realized that the right ventricle (RV) might be the source of ventricular arrhythmias, with LBBB morphology on the ECG [21,22].

In 1982, Frank Marcus et al. reported a series of adult patients [7] affected by a new syndrome characterized by a remodeling of the RV, with aneurysms located in the inflow, apex and outflow, due to a fibro-fatty replacement, which they called right ventricle dysplasia, believing it to be due to a cell dysplastic congenital phenomena (Figure 8). The ECG became fundamental for diagnosis, with inverted T waves in the right precordial leads, wide QRS, post-excitation epsilon wave due to delayed electrical impulse transmission in the RV outflow tract ("late potentials") (Figure 9), premature ventricular beats and ventricular tachycardia with LBBB morphology.

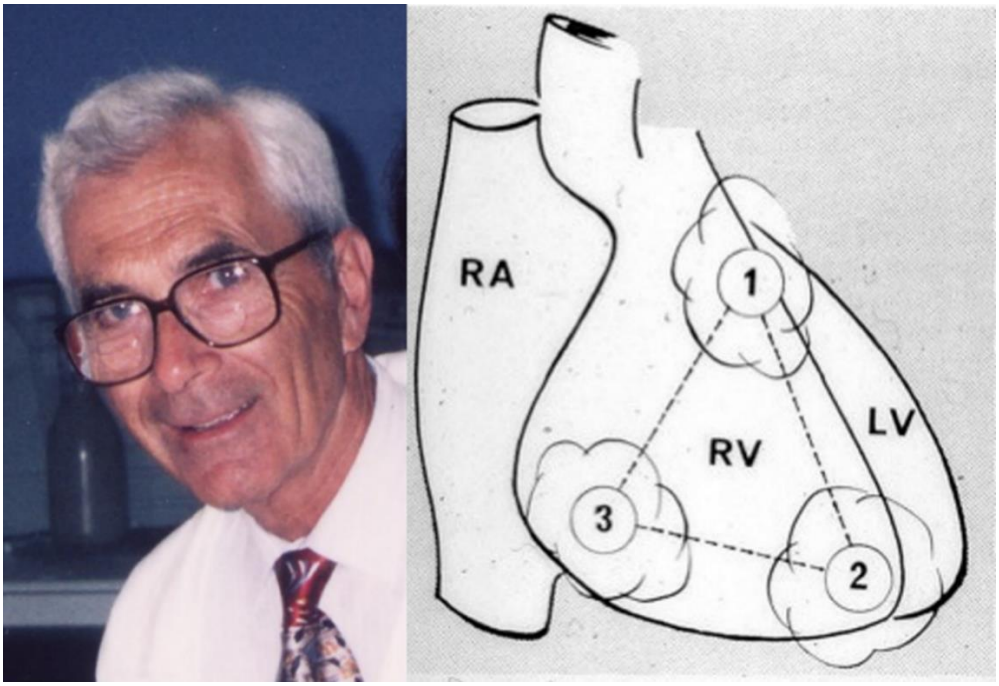

Figure 8. Frank Marcus and the triangle of right ventricular dysplasia with aneurysm of the right ventricle (1, 2, 3). From [23], modified.

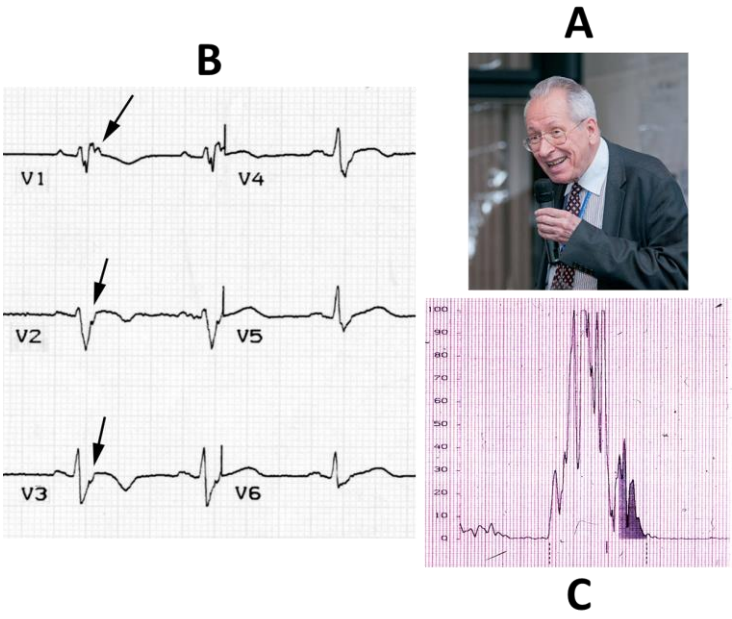

Figure 9. Guy Fontaine (**A**), epsilon waves (arrows) (**B**) and late potentials (**C**).

4. Pathological Substrates

Pathological studies demonstrated fibro-fatty replacement of the RV-free wall, starting in the subepicardium and extending along the wavefront to the subendocardium (Figure 10).

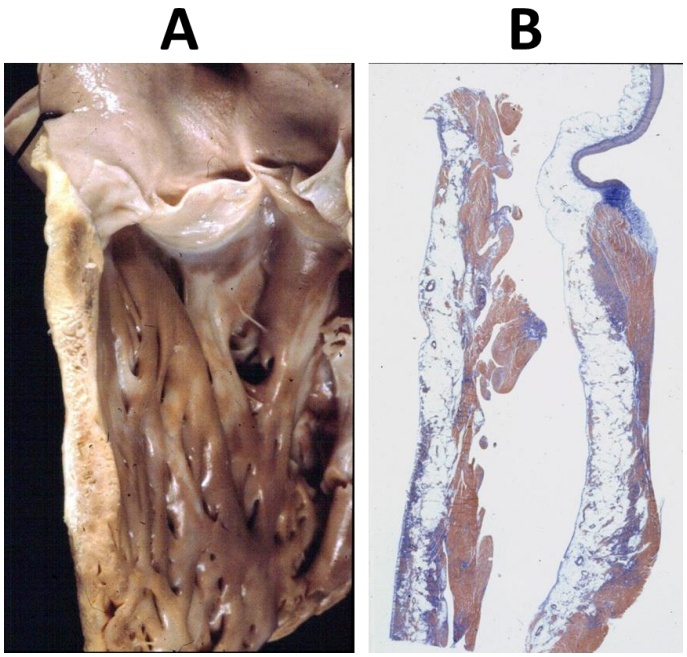

Figure 10. Sudden death in a 17-year-old boy: fibro-fatty replacement of the infundibular right ventricular free wall, extending along the wave-front from the epicardium to the endocardium (**A**,**B**). Azan Mallory, original magnification ×3.

Microscopic investigation showed a loss of the myocardium, with a fibro-fatty replacement that was frequently biventricular (Figure 11), as a consequence of an ongoing, non-ischemic myocardial cell death and repair [8] (Figure 12).

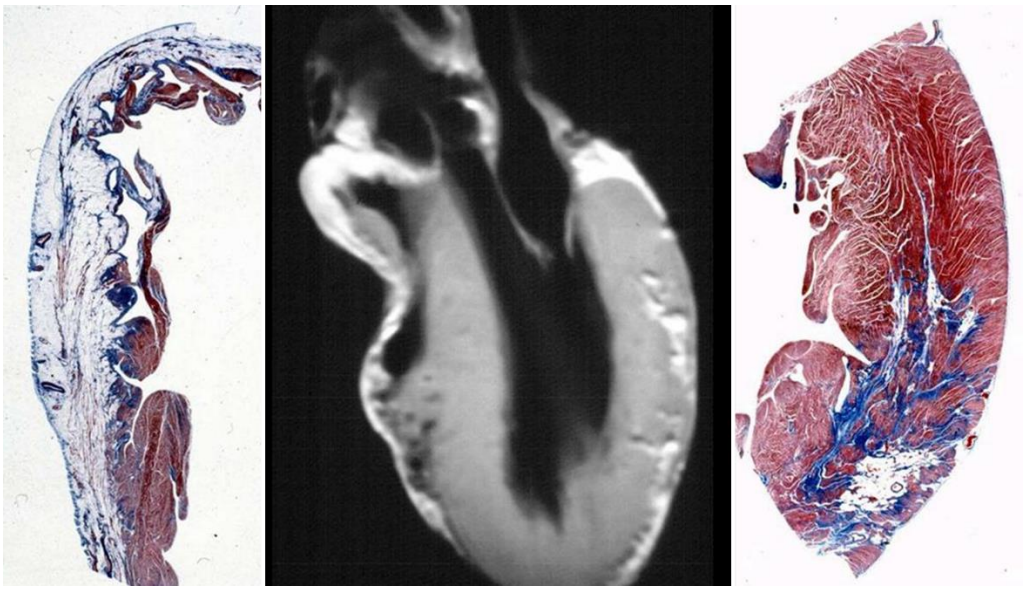

Figure 11. Arrhythmogenic cardiomyopathy by biventricular involvement with fibro-fatty replacement. Note that the interventricular septum is spared. Azan Mallory, original magnification ×4.0. From [6].

Electron microscopy demonstrated disruption of the intercalated disc as a final common pathway of cell death [24] (Figure 13). Cardiomyocyte death occurs in the form of apoptosis [25] (Figure 14), associated with myocardial inflammation (Figure 15). Whether the latter is a reaction to cell death [26] or an immune phenomenon [27] remains controversial.

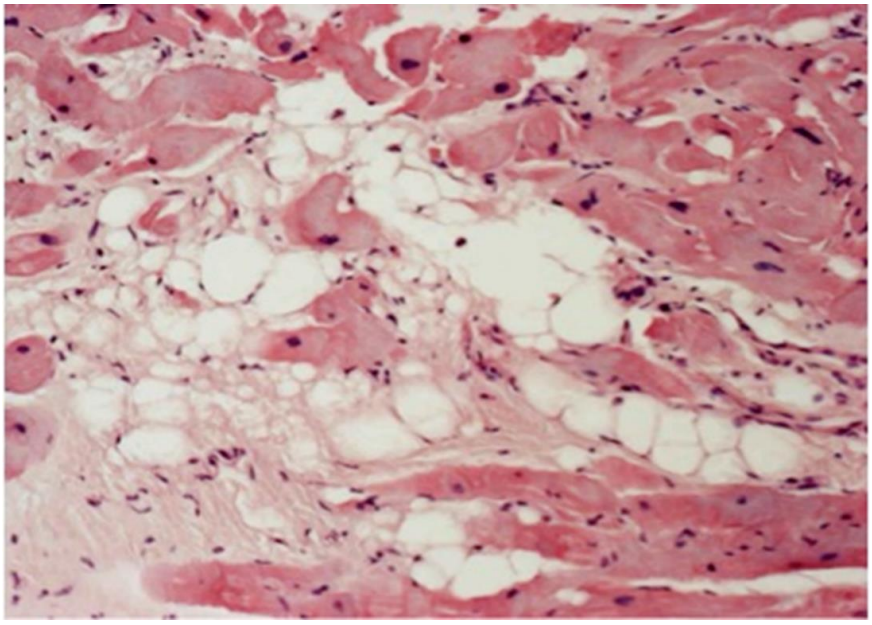

Figure 12. AC: close up of fibro-fatty tissue replacing dead myocardium. Hematoxylin–eosin, original magnification ×60. From [23], modified.

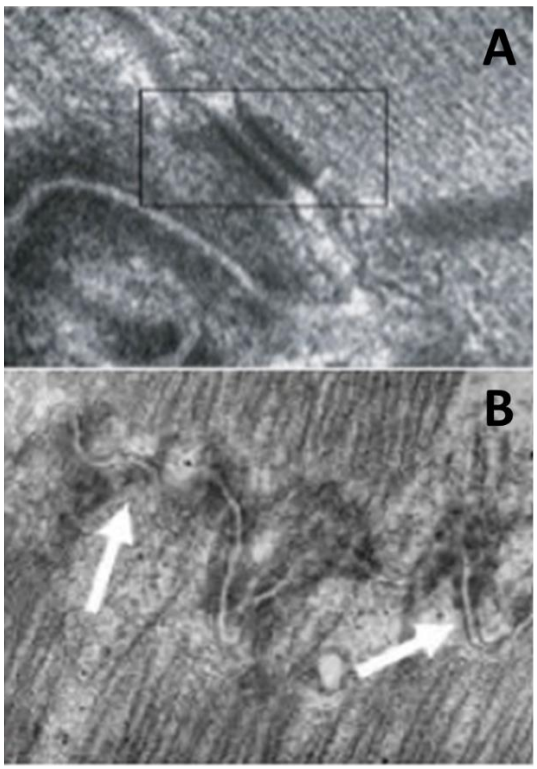

Figure 13. Transmission electron microscopy of disrupted intercalated disc in AC (**B**) compared to desmosome in a cavital (**A**). Original magnification, (**A**) ×30.000; (**B**) ×5. The rectangular block includes a normal desmosome, whereas arrows indicate disrupted desmosomes in AC.



Figure 14. Transmission electron microscopy of myocardial apoptosis in AC. Original magnification, ×14.500. From [25].

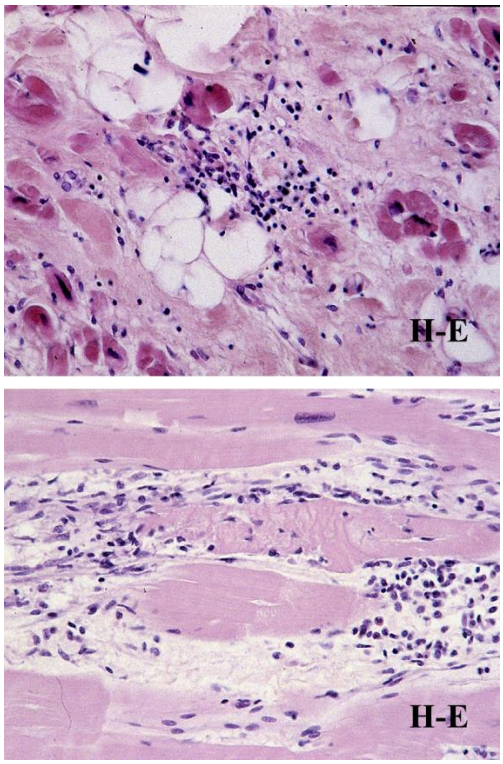

Figure 15. Myocarditis and cell death associated with fibro-fatty replacement in AC patient. Hematoxylin-eosin, original magnification ×40.

The origin of the adipocytes is neither a fatty-tissue infiltration from the subepicardium (adipositas cordis) [12] nor a fatty metaplasia of cardiomyocyte [28].

Mesenchymal cells are the source of adipocytes and fibroblasts, accounting for fibro-fatty tissue repair of cardiomyocyte death [29]. The phenomenon resembles dystrophy more than myocarditis or congenital dysplasia [8].

5. Nomenclature and Classification

Different terms have been employed in the past to give a name to this heart muscle disease: right ventricular dysplasia [7], right ventricular cardiomyopathy [30] and arrhythmogenic right ventricular cardiomyopathy/dysplasia [31].

In 1996, heart disease was definitively introduced in the classification of cardiomyopathies by the World Health Organization with the name arrhythmogenic right ventricular cardiomyopathy [32]. With the discovery of the left ventricular variant, the term arrhythmogenic cardiomyopathy (AC or ACM) has been introduced [33].

6. Arrhythmogenic Cardiomyopathy as a Cause of Sudden Cardiac Death

On 14 May 1979, a young cycling champion died suddenly during a tennis match in Mirano, Venice (Figure 16). He stopped playing, took his pulse, moved towards the back of the tennis court, collapsed and died suddenly. Transmural fibro-fatty replacement of the RV-free wall was found at autopsy. He was a physician, and a detailed note was found in his diary, dated 4 October 1978: ventricular tachycardia with LBBB (Figure 16). It was an ECG taken during an episode of palpitation. He represents 'patient zero' of a series of sudden deaths by AC in young adults published in the New England Journal of Medicine [30] (Figure 17A). The paper was the first description of a novel disease responsible for causing sudden death in the young (Figure 17B).

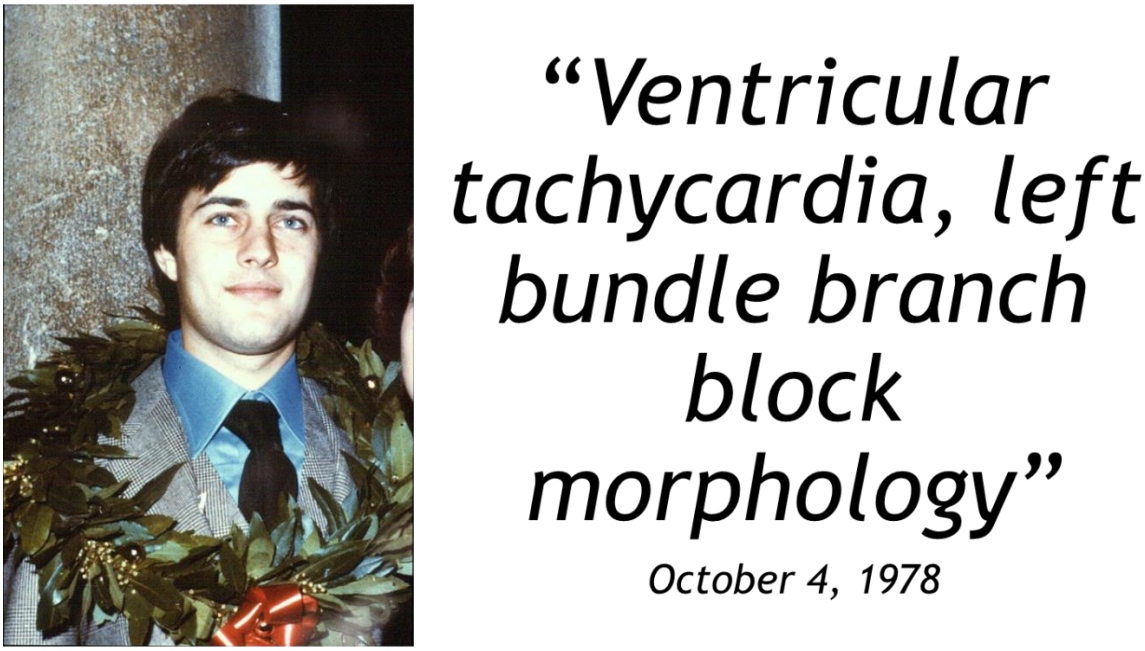

Figure 16. Case "0" of the Veneto Region experience of sudden death by arrhythmogenic cardiomyopathy, with the note in his diary. He was a young physician who died suddenly during a tennis match. From [23], modified.

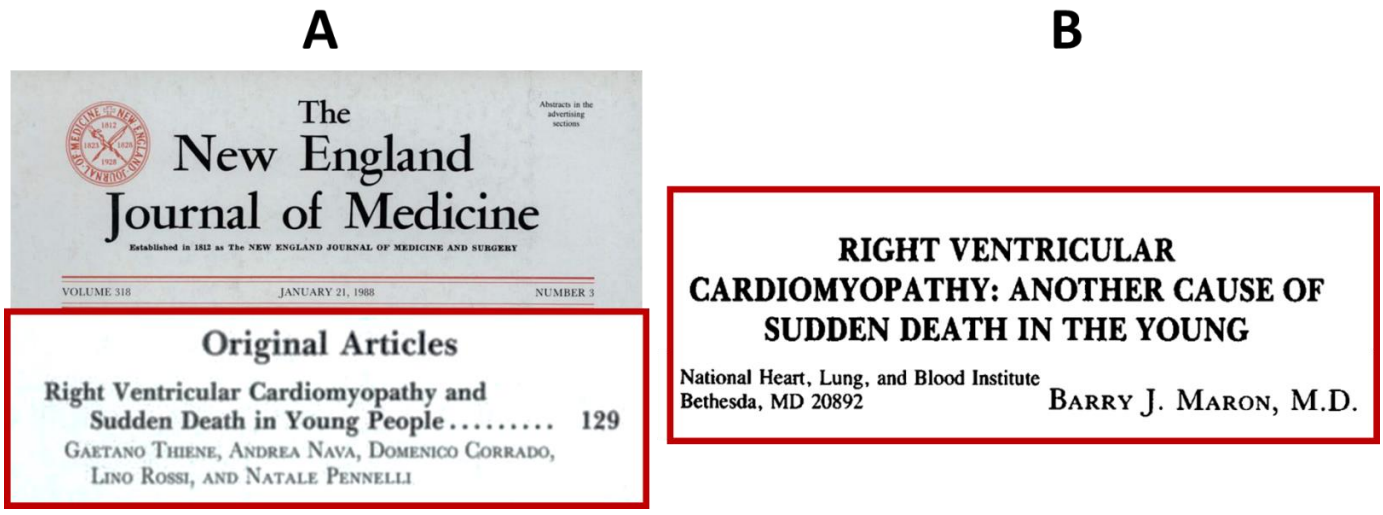

Figure 17. Publication in the New England Journal of Medicine 1988 (**A**) of AC, as a new disease causing sudden death in the young (**B**).

Sports activity was proven to increase the risk of SCD [34]. Much lower prevalence was reported from other countries [35–37], probably because of misdiagnosis at post-mortem. The AC rate in Italy for sudden deaths in athletes was 27% (Figure 18), which showed a sharp decline with the use of ECG screening for sports eligibility [38] (Figure 19).

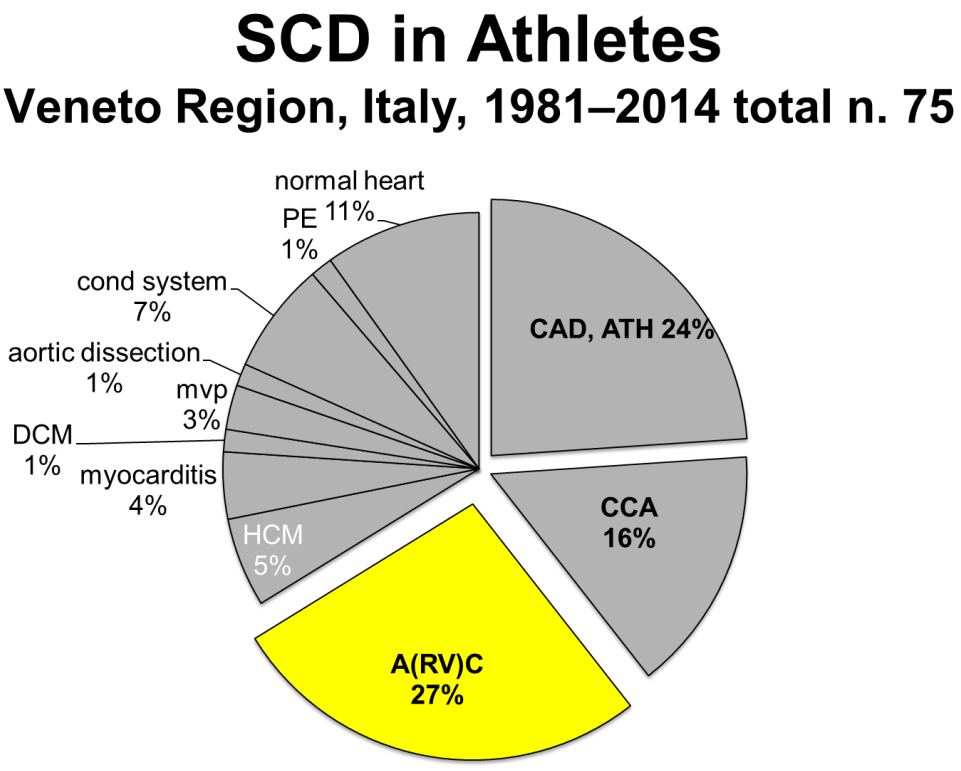

Figure 18. Arrhythmogenic cardiomyopathy (A(RV)C) appears to be the first cause (27%) of sudden cardiac death (SCD) in the Veneto Region.

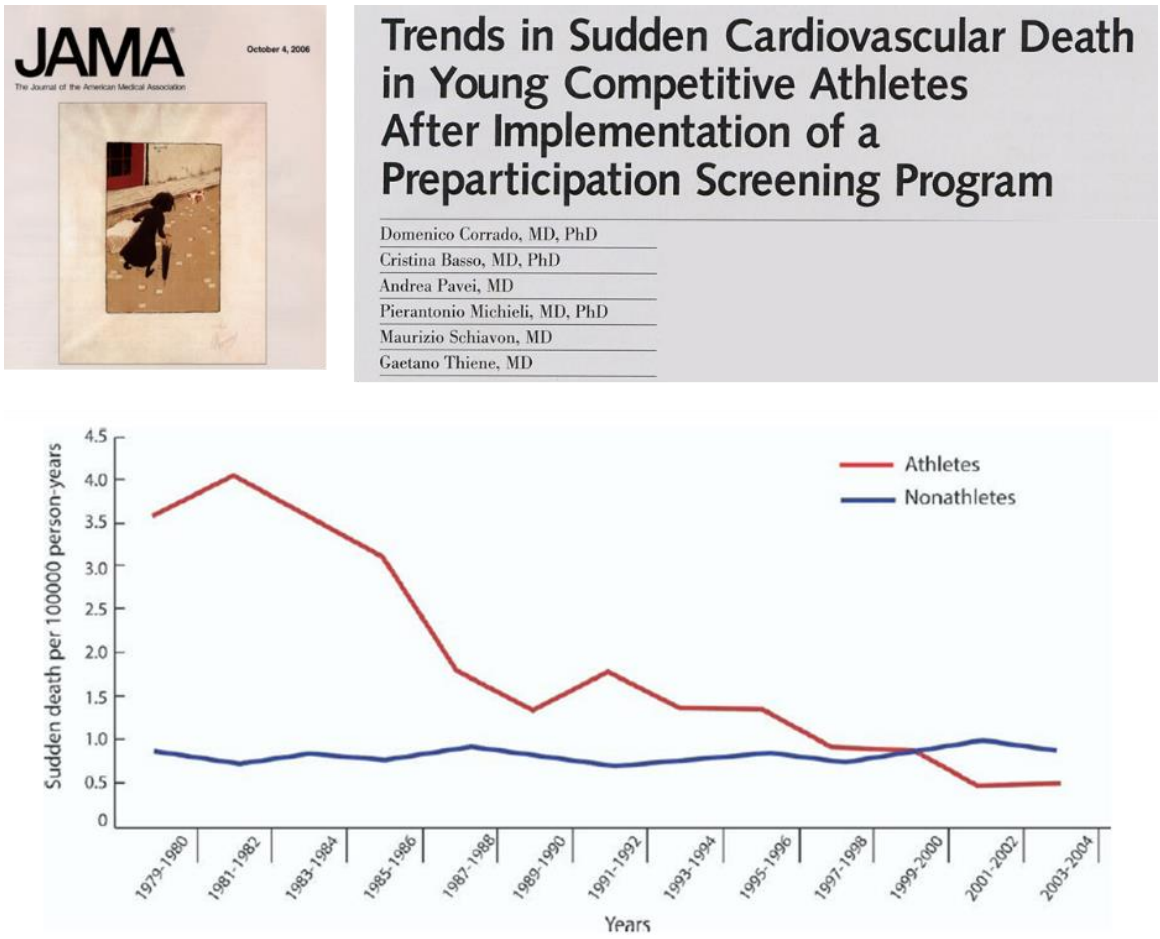

Figure 19. Sharp decline of sudden death in the young after introduction of ECG for screening for sports eligibility. From [38], modified.

7. Arrhythmogenic Cardiomyopathy: A Genetically Determined Heart Muscle Disease

A dominant form of AC was reported in the area of Piazzola, in the Veneto Region, by Andrea Nava, the leader of our team [39]. For years AC was known by the nickname "Venetian disease" as a local genetically determined cardiomyopathy. The clinical phenotype was proven to be absent at birth and becoming overt at 10–14 years of age [40].

A recessive form of AC, with keratoderma and woolly hair (cardiocutaneus syndrome), had been reported in 1986 from the Naxos island in Greece [41] (Figure 20), the island where the Greek mythology tells that Arianna was left by Teseo.

A race started to discover the gene of AC. In 1996, Ruiz et al., studying *junctional protein* (*JUP*) in knock-out mice, discovered that *JUP* absence influences the development of desmosome in the heart and that the human gene is located in chromosome 17q21 [42].

In 1998, Coonar et al., by linkage analysis, mapped the locus of the Naxos disease gene in humans to chromosome 17q21 [43]. Finally, in 2000, McKoy et al. identified a deletion of the *JUP* gene in patients with Naxos AC [44].

In Ecuador, the group of dermatologists Carvajal–Huerta found a recessive mutation of *desmoplakin* (*DSP*) in a family with dilated cardiomyopathy and cardiocutaneous syndrome [45,46].

The pathological study of the heart of a child of an affected family, who died of congestive heart failure, revealed a biventricular AC with a triangle of dysplasia of the RV [47] (Figure 21).



Figure 20. Recessive form of arrhythmogenic cardiomyopathy and woolly hair (cardiocutaneus syndrome) in the island of Naxos. Recessive transmission (**A**). Wolly hair (**B**). Palmo-plantar keratosis (**C**). From [23], modified.

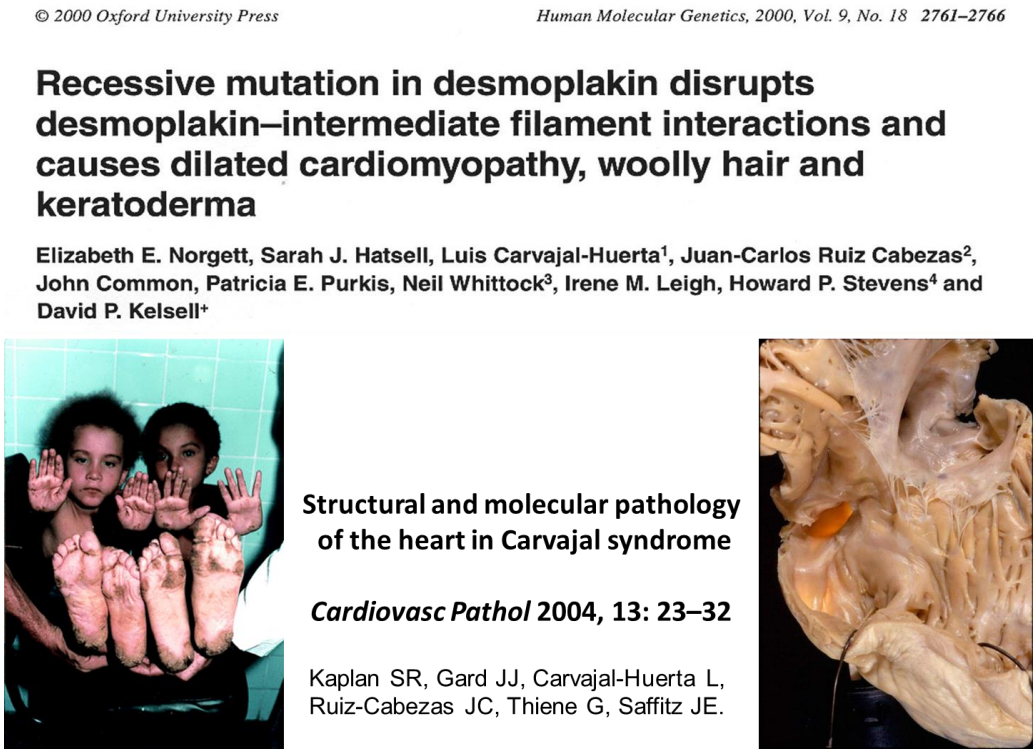

Figure 21. Carvajal syndrome, with recessive biventricular AC, due to a desmoplakin mutation [47]. Note a right ventricular aneurysm in the heart specimen.

DSP became a candidate also for the dominant AC. The molecular genetic investigation carried out in Venetian families revealed mutations of human *DSP* [48]. Genotype–phenotype correlations showed biventricular involvement [49] (Figure 22).

A cascade of mutations in genes encoding desmosomal proteins was then discovered in dominant AC families: *plakophilin-2* [50], *desmoglein-2* [51], *desmocollin-2* [52,53] and also *plakoglobin* [54] (Figure 23), confirming that AC is a desmosomal disease. Genetic screening of the proband to unmask asymmetric carriers turned out to be life-saving.

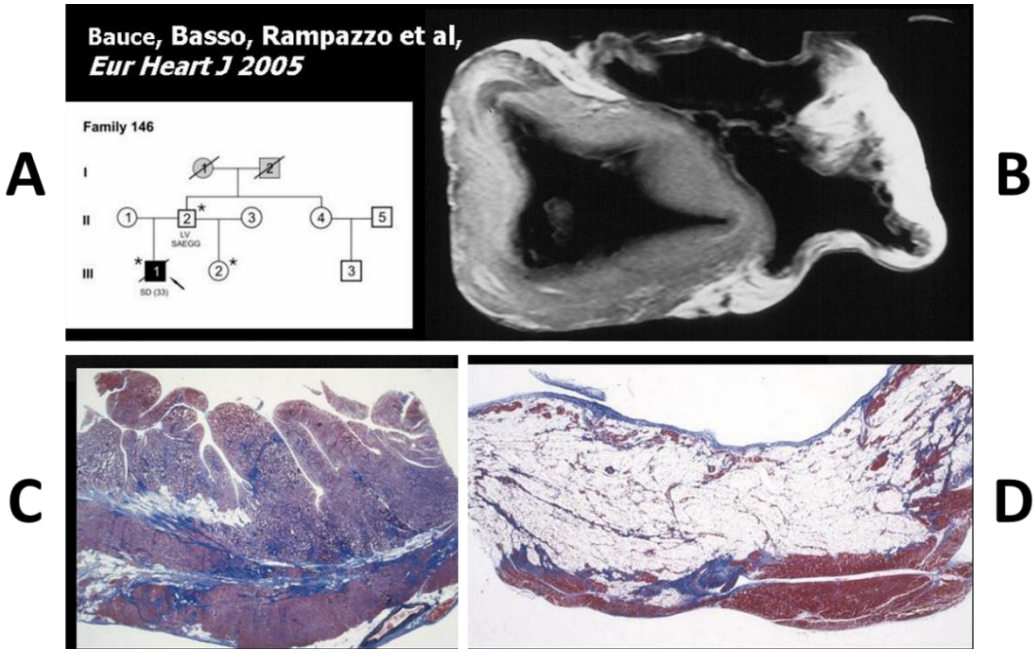

Figure 22. Desmoplakin mutation in dominant AC (**A**) with biventricular involvement (**B**–**D**). Azan Mallory stain, original magnification ×5. * Mutation carrier. From [49].

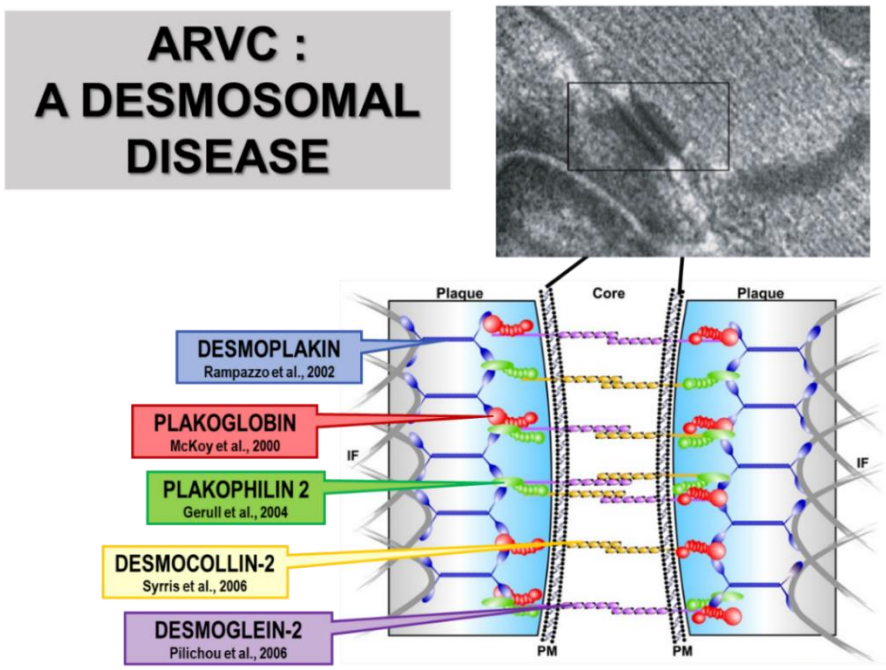

Figure 23. Mutations of proteins of the intercalated disk account for arrhythmogenic cardiomyopathy, giving rise to the name "desmosomal disease". Transmission electron microscopy ×30,000. The rectangular includes the normal desmosomes, surrounded by disrupted ones. DESMOPLAKIN [48], PLAKOGLOBIN [44], PLAKOPHILIN 2 [50], DESMOCOLLON-2 [52], DESMOGLEIN-2 [51]. From [6].

Multiple compound or heterozygous mutations were proven to entail a more severe prognosis [55]. The disease was reproduced in transgenic mice [56,57] (Figure 24) and in zebrafish [58–60]. However, electrical instability was found in the absence of a pathological substrate [61].

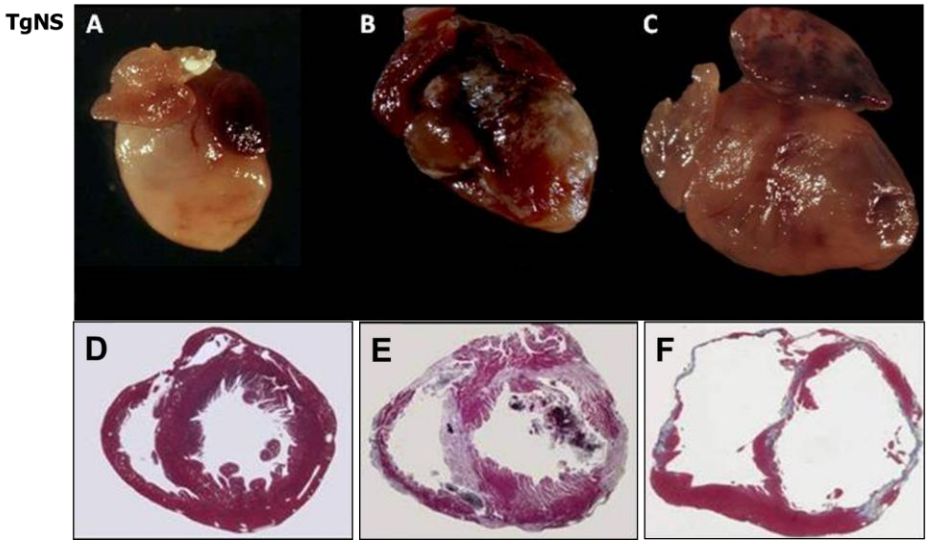

Figure 24. Gross (**A**–**C**) and histological (**D**–**F**) views of desmoglein transgenic mice. Note the progression of the disease with time. Azan Mallory stain, original magnification ×3. From [56], modified.

8. Non-Desmosomal Arrhythmogenic Cardiomyopathy

Over the years, genetic variants other than desmosomal genes have been reported to be associated with the AC phenotype. In this setting, *Transmembrane protein 43* (*TMEM43*) was linked to the disease in 2008 with the founder mutation p.(Ser385Leu) in Canada [62], with a fully penetrant pattern. More recently, other rare genetic variants in *TMEM43* have been published [63,64]. The cardiac sodium channel gene *SCN5A* was reported in a case of an AC patient in 2008 [65] and, subsequently, in other studies [66,67]. *Desmin* (*DES*) was also associated with AC in patients with the founder mutation p.(Ser13Phe) [68,69]. Over the years, other genetic variants in *DES* have been reported [70–75] that are associated with the left ventricular phenotype. *Phospholamban* (*PLN*) has been linked with the pathogenesis of both AC and dilated cardiomyopathy (DCM) in p.(Arg14del) carriers [76]. Multiple studies demonstrated that this variant is a founder mutation widespread in the Dutch population [77–80]. In 2012, *Lamin A/C* (*LMNA*), usually associated with DCM, was also linked to AC phenotype [81], followed by other studies [82–84]. Truncating variants in *Filamin C* (*FLNC*) were associated with AC for the first time in 2016 [85], and since then, rare genetic variants have been found in several cases [86–88], specifically associated with left-ventricular phenotype and characterized by late-onset presentation with typical ECG and CMR features [89].

Several genes have been associated with AC over the years due to the evolution of genetic analysis with next-generation sequencing technology. However, genetic screening in large populations of recently associated genetic variants to AC is still missing.

In 2017, two independent studies reported for the first time rare genetic variants in *Cadherin 2* gene (*CDH2*) in AC patients [90,91]. Further, a recent multicentric study reported *CDH2* genetic variants in a large AC cohort [92]. In 2018, the *Tight Junction Protein 1* gene (*TJP1*) was linked once to the disease phenotype in a mixed cohort of 40 Italian– Dutch–German AC patients [93]. Similarly, *Integrin-linked kinase* (*ILK*) was first associated with AC in knockout mice, and two missense variants were subsequently found in two families with incomplete penetrance [94,95]. Instead, a homozygous missense variant in the *LEM domain-containing protein 2* (*LEMD2*), associated with juvenile cataracts, was also linked to a unique form of arrhythmic cardiomyopathy [96]. As described in the review of Stevens et al., [97] more than ten non-desmosomal genes have been linked to AC, including *Catenin alpha 3* (*CTNNA3*), *Titin* (*TTN*) and *Ankyrin 2* (*ANK2*). However, pathogenic variants in these genes have been reported in a minority of AC patients (1–3%) [98].

The overwhelming quantity of data derived from large-scale genetic screening is leading to a huge number of variants of unknown significance resulting in "genetic noise" without clear evidence. To this regard, a recent international reappraisal of genes associated with AC has been addressed by the National Institutes of Health (NIH)-funded resource ClinGen, showing that only eight genes show definite to moderate evidence for AC, and among them, five genes encoding for the desmosomal proteins and *TMEM43*, *DES* and *PLN* [99].

9. Advances in Clinical Diagnosis

Diagnostic criteria for in vivo diagnosis were first put forward in 1994 [100] and updated in 2010 [101]. ECG and echocardiography were crucial to unmask electrical instability and mechanical dysfunction. Angiocardiography was originally employed as a gold standard to detect wall dyskinesia and aneurysms in the triangle of dysplasia [102] (Figure 25).

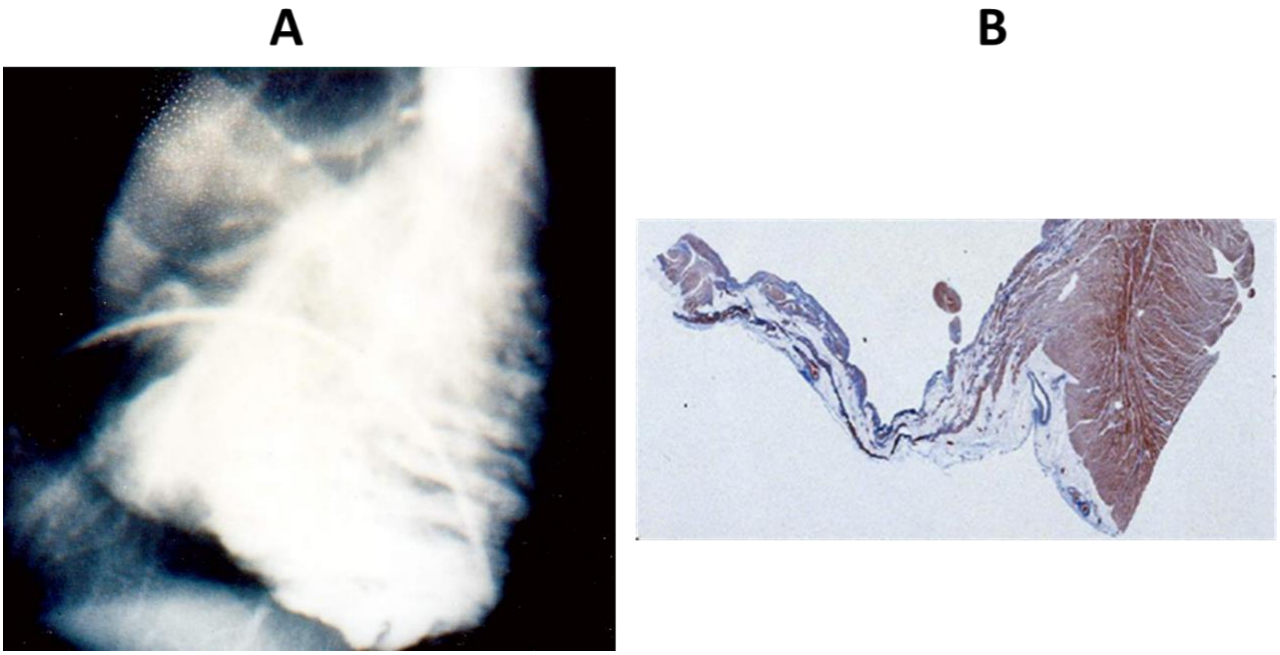

Figure 25. Triangle of dysplasia seen at angiocardiography (**A**) and compared with pathology (**B**). Azan Mallory stain, original magnification ×4. From [102], modified.

Endomyocardial biopsy (EMB) was implemented to detect in vivo the pathognomic substrate, thanks to the transmural fibro-fatty replacement [103] (Figure 26). EMB plays a crucial role in the differential diagnosis of overlapping diseases, like dilated cardiomyopathy, myocarditis, sarcoidosis and idiopathic tachycardia of the RV outflow.

The advent of cardiac magnetic resonance (CMR) with late enhancement gadolinium facilitated the detection of not only morpho-functional abnormalities but also tissue alterations. The use of CMR unveiled isolated LV involvement in the form of subepicardial fibro-fatty 'scars' [104] (Figure 27). A novel mutation of desmoplakin was found in patients with LV variants of AC [105].

As far as electrophysiology, electroanatomic mapping was invented tand used to discover fibro-fatty scars in vivo with electrical silence [106] (Figure 28).

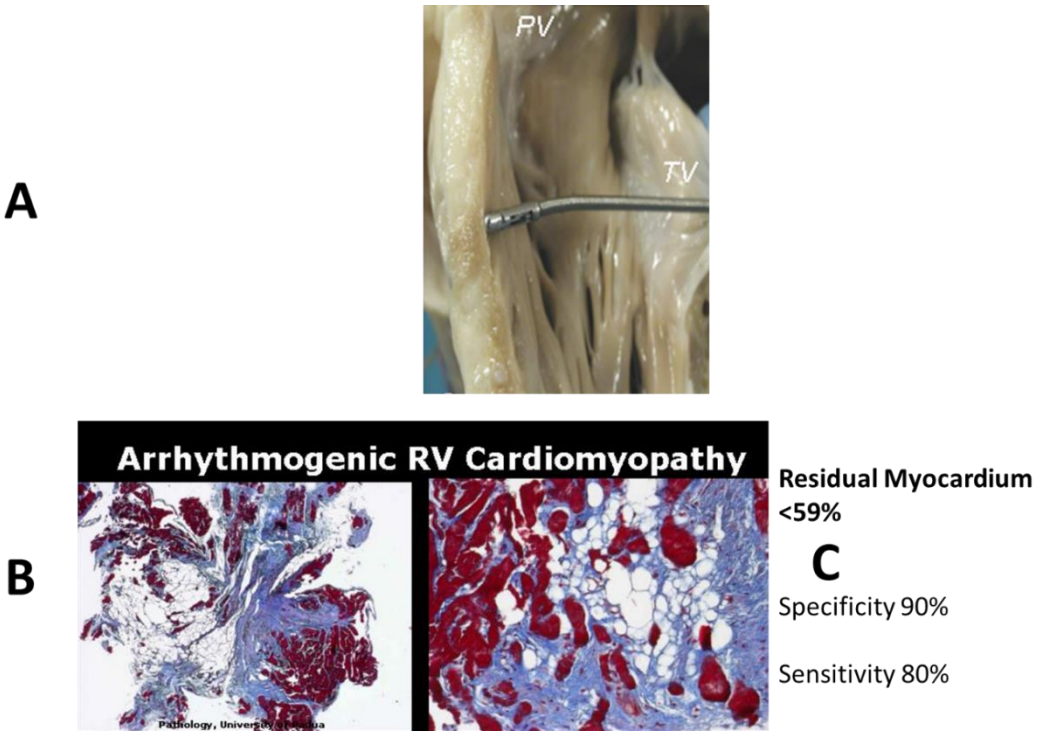

Figure 26. Right ventricular endomyocardial biopsy in AC. (**A**)The transmural fibro-fatty replacement favors the sensitivity of endocardial approach. (**B**,**C**) Histology revealed fibro-fatty specificity of the endomyocardial sampling. Azan Mallory stain, original magnification (**B**) ×20, (**C**) ×60. (**A**) From [103], modified; (**B**,**C**). From [23], modified.

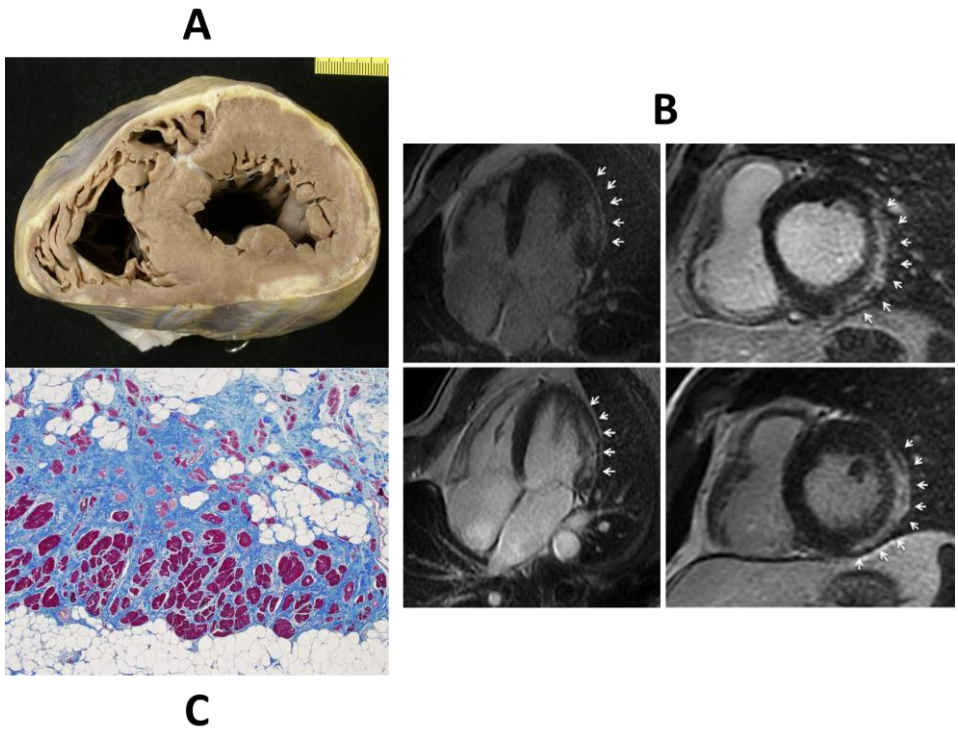

Figure 27. Left ventricular AC, seen either at gross (**A**) and histological study (**C**) and by cardiac magnetic resonance with gadolinium (**B**). Arrows indicate the fibro-fatty replacement of the left ventricle at late enhancement Cardiac Magnetic Resonance. Azan Mallory stain, original ×15.

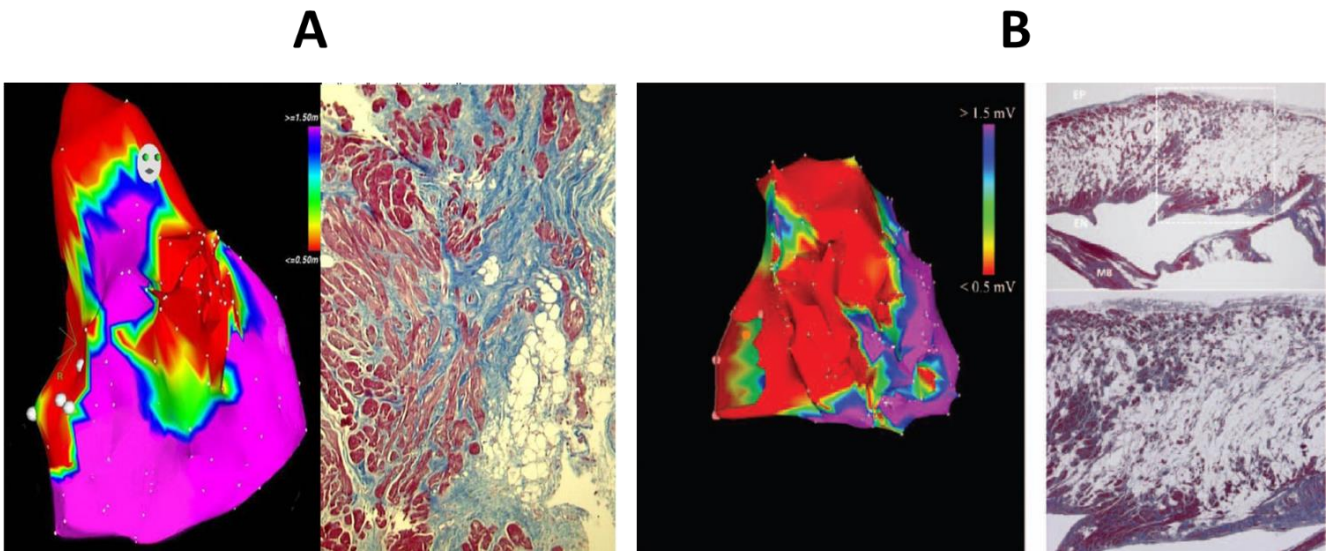

Figure 28. Electroanatomic mapping in AC (electrical scar) compared with endomyocardial biopsy (**A**) and autopsy finding (**B**). Azan Mallory stain, (**A**) ×15, (**B**) ×3 and ×10. (**B**) Right down is the amplification of the white rectangle box of the right up. (**A**) from [6]; (**B**) From [23].

The inverted T wave in the precordial leads has been confirmed to be a pathognomic marker of the disease [107].

10. Prevention of SCD

Implantable cardioverter defibrillators (ICD) have proved to be effective lifesaving devices in subjects with AC to prevent SD [108] (Figure 29). Indication for implantation depends upon risk stratification [109]. It is mandatory in patients with AC and a history of cardiac arrest, unexplained syncope and sustained ventricular tachycardia (Figure 30).

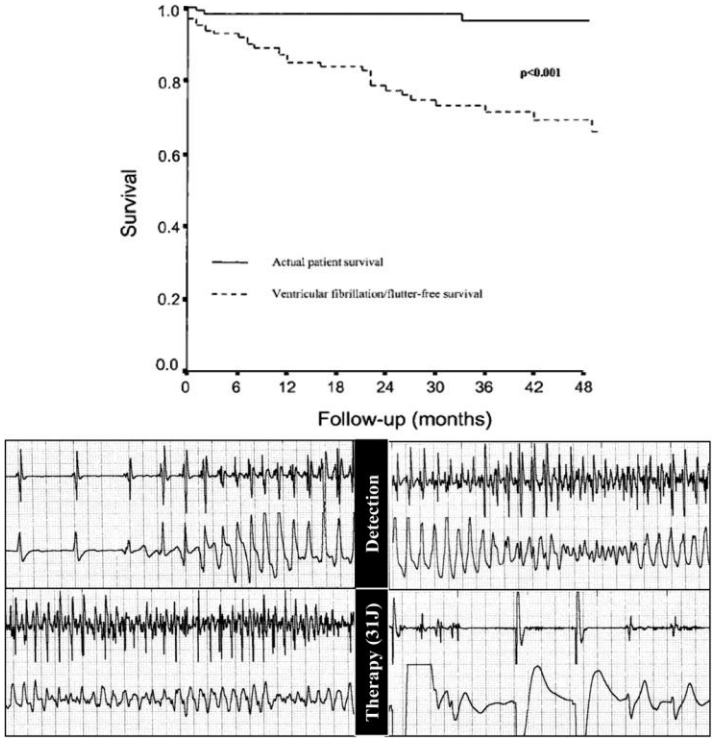

Figure 29. Efficacy of implantable cardioverter defibrillator (ICD) in AC. Survival vs. number of patients with electric shock. The difference accounts for number of saved lives. From [6].

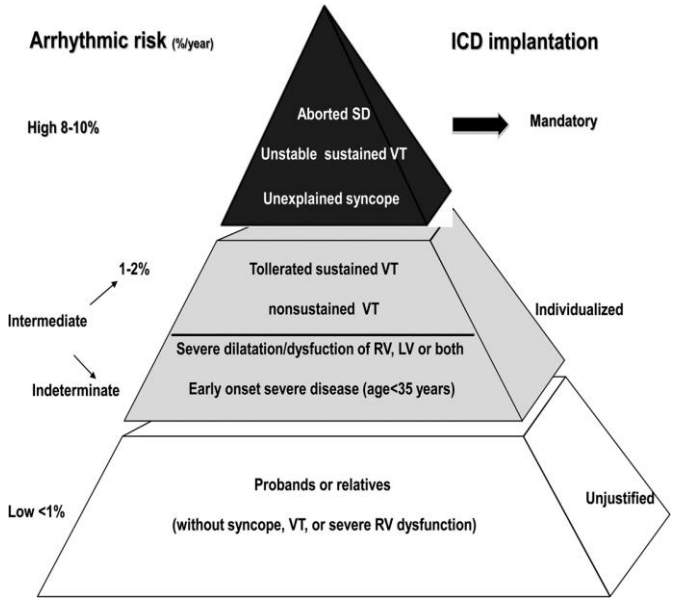

Figure 30. Risk stratification of arrhythmogenic cardiomyopathy with indication of ICD implantation. From [6].

The availability of automatic external defibrillators should be increased in public places, playgrounds and even at the homes of AC patients. The training of lay people to use is mandatory.

11. Research Globalization

The key to success in AC knowledge development was the result of an interdisciplinary approach and international collaboration. Many foreign scholars visited the University of Padua, which was considered the "mecca" of AC. Grants from the European Commission and NIH were fundamental for research and the discovery of AC genes and for setting up registries.

European meetings were held in Naxos, Baltimore, Denver and Padua, and a fruitful intercontinental collaboration was established that resulted in the publication of a monograph in 2007 [110].

Meanwhile, a great many of the main protagonists regrettably have passed away: Camerini, Dalla Volta, Fontaine, Marcus, Moss, Nava, Protonotarios and Rossi. They will remain unforgettable.

Author Contributions: Conceptualization, G.T., C.B., K.P. and M.B.M.; Data curation, G.T.; Formal analysis, C.B. and M.B.M.; Funding acquisition, G.T. and C.B.; Investigation, G.T., C.B. and K.P.; Methodology, G.T., C.B., K.P. and M.B.M.; Project administration, G.T. and C.B.; Resources, G.T. and C.B.; Supervision, G.T., C.B., K.P. and M.B.M.; Validation, G.T. and C.B.; Visualization, G.T.; Writing—original draft, G.T. and C.B.; Writing—review & editing, G.T., C.B. and M.B.M. All authors have read and agreed to the published version of the manuscript.

Funding: This study was supported by research founds by the Registry of Cardio-Cerebro-Vascular Pathology, Veneto Region, Venice, and by the ARCA Foundation, Padua, Italy.

Institutional Review Board Statement: Not applicable.

Informed Consent Statement: Not applicable.

Acknowledgments: Giulia Vangelista for secretarial assistance.

Conflicts of Interest: The authors declare no conflict of interest.

Abbreviations

2D = two-dimensional; AC = arrhythmogenic cardiomyopathy; CDH2 = cadherin 2; CMR = cardiac magnetic resonance; DES = desmin; DSP = desmoplakin; ECG = electrocardiogram; EMB = endomyocardial biopsy; FLNC = filamin C; ICD = Implantable cardioverter defibrillator; JUP = cell junctional protein; LBBB = left bundle branch block; LMNA = lamin A/C; PLN = phospholamban; RV = right ventricle; SCD = sudden cardiac death; SCN5A = sodium voltage-gated channel alpha subunit 5; TJP1 = Tight Junction Protein 1; TMEM43 = transmembrane protein 43, ILK = Integrin-linked kinase; LEMD2 = LEM domain-containing protein 2; CTNNA3 = Catenin alpha 3; TTN = Titin, ANK2 = Ankyrin 2.

References

1. Marrone, D.; Zampieri, F.; Basso, C.; Zanatta, A.; Thiene, G. History of the discovery of Arrhythmogenic Cardiomyopathy. *Eur. Heart J.* **2019**, *40*, 1100–1104. [CrossRef] [PubMed]
2. Lancisi, G.M. *De Motu Cordis et Aneurysmatibus*; Book II, Ch. VI, Par. XLVII; G.M. Salvioni: Roma, Italy, 1728.
3. Lancisi, G.M. *De Motu Cordis et Aneurysmatibus*; Caput V: Naples, Italy, 1736.
4. Hippocrates. *On Diseases*; Book I; *Sacred Disease*; Book V.
5. Laennec, R. *De L'Auscultation Médiate ou Traité du Diagnostic des Maladies des Poumons et du Coeur, Fondé Principalment sur ce Nouveau Moyen d'Exploration*; Book II, Ch. XV; Brosson & Chaudé: Paris, France, 1819.
6. Thiene, G. The research venture in arrhythmogenic right ventricular cardiomyopathy: A paradigm of translational medicine. *Eur. Heart J.* **2015**, *36*, 837–846. [CrossRef] [PubMed]
7. Marcus, F.I.; Fontaine, G.H.; Guiraudon, G.; Frank, R.; Laurenceau, J.L.; Malergue, C.; Grosgogeat, Y. Right ventricular dysplasia: A report of 24 adult cases. *Circulation* **1982**, *65*, 384–398. [CrossRef]
8. Basso, C.; Thiene, G.; Corrado, D.; Angelini, A.; Nava, A.; Valente, M. Arrhythmogenic right ventricular cardiomyopathy. Dysplasia, dystrophy, or myocarditis? *Circulation* **1996**, *94*, 983–991. [CrossRef]
9. Eliot, G. *Middlemarch. A Study of Provincial Life*; Book IV, Ch. XLII; W. Blackwood and Sons: Edinburgh-London, Scotland, 1871; p. 307.
10. Dickens, C. *The Posthumous Papers of the Pickwick Club*; Chapman and Hall: London, UK, 2014; pp. 1836–1837.
11. Kaufmann, E. *Lehrbuch der Speziellen Pathologischen Anatomie für Studirende und Ärzte*, 1st ed.; Reimer: Berlin, Germany, 1896; p. 28, *Trattato di Patologia Speciale*, 5th ed.; Vallardi: Milano, Italy, 1902; 1959; p. 125.
12. Basso, C.; Thiene, G. Adipositas cordis, fatty infiltration of the right ventricle, and Arrhythmogenic Right Ventricular Cardiomyopathy. Just a matter of fat? *Cardiovasc. Pathol.* **2005**, *14*, 37–41. [CrossRef] [PubMed]
13. Osler, W. *The principles and Practice of Medicine*, 6th ed.; D. Appleton & Co.: New York, NY, USA, 1905; p. 820.
14. MacDermot, H.E. *Maude Abbott: A Memoir*; Macmillan: Toronto, ON, Canada, 1941; p. 90.
15. Segall, H.N. Parchment heart (Osler). *Am. Heart J.* **1950**, *40*, 948–950. [CrossRef]
16. Uhl, H.S.M. A previously undescribed congenital malformation of the heart: Almost total absence of the myocardium of the right ventricle. *Bull. Johns. Hopkins Hosp.* **1952**, *91*, 197–209.
17. Froment, R.; Perrin, A.; Loire, R.; Dalloz, C.L. Ventricule droit papyracé du jeune adulte par dystrophie congénitale. *Arch. Mal. Coeur* **1968**, *61*, 477–503.
18. Shirani, J.; Berezowski, K.; Roberts, W.C. Quantitative measurement of normal and excessive (cor adiposum) subepicardial adipose tissue, its clinical significance, and its effect on electrocardiographic QRS voltage. *Am. J. Cardiol.* **1995**, *76*, 414–418. [CrossRef]
19. Dalla Volta, S.; Battaglia, G.; Zerbini, E. "Auricularization" of the right ventricular pressure. *Am. Heart J.* **1961**, *61*, 25–33. [CrossRef]
20. Dalla Volta, S.; Fameli, O.; Maschio, G. Le syndrome clinique et hémodynamique de l'auricularisation du ventricule droit. *Arch. Mal. Coeur* **1965**, *58*, 1129–1143. [PubMed]
21. Fontaine, G.; Frank, R.; Vedel, J.; Grosgogeat, Y.; Cabrol, C.; Facquet, J. Stimulation studies and epicardial mapping in ventricular tachycardia: Study of mechanisms and selection for surgery. In *Reentrant Arrhythmias*; Kulbertus, H.E., Ed.; MTP Publishing: Dalton, PA, USA, 1977; pp. 334–350.
22. Fontaine, G.; Frank, R.; Gallais-Hamonno, F.; Allali, I.; Phan-Thuc, H.; Grosgogeat, Y. Electrocardiographie des potentiels tardifs du syndrome de post-excitation [Electrocardiography of delayed potentials in post-excitation syndrome]. *Arch. Mal. Coeur Vaiss.* **1978**, *71*, 854–864. [PubMed]
23. Beffagna, G.; Zorzi, A.; Pilichou, K.; Marra, M.P.; Rigato, I.; Corrado, D.; Migliore, F.; Rampazzo, A.; Bauce, B.; Basso, C.; et al. Arrhythmogenic Cardiomyopathy. *Eur. Heart J.* **2020**, *41*, 4457–4462. [CrossRef] [PubMed]
24. Basso, C.; Czarnowska, E.; Della Barbera, M.; Bauce, B.; Beffagna, G.; Wlodarska, E.K.; Pilichou, K.; Ramondo, A.; Lorenzon, A.; Wozniek, O.; et al. Ultrastructural evidence of intercalated disc remodelling in arrhythmogenic right ventricular cardiomyopathy: An electron microscopy investigation on endomyocardial biopsies. *Eur. Heart J.* **2006**, *27*, 1847–1854. [CrossRef] [PubMed]

25. Valente, M.; Calabrese, F.; Thiene, G.; Angelini, A.; Basso, C.; Nava, A.; Rossi, L. In vivo evidence of apoptosis in arrhythmogenic right ventricular cardiomyopathy. *Am. J. Pathol.* **1998**, *152*, 479–484.
26. Thiene, G.; Corrado, D.; Nava, A.; Rossi, L.; Poletti, A.; Boffa, G.M.; Daliento, L.; Pennelli, N. Right ventricular cardiomyopathy: Is there evidence of an inflammatory aetiology? *Eur. Heart J.* **1991**, *12* (Suppl. D), 22–25. [CrossRef]
27. Chelko, S.P.; Asimaki, A.; Lowenthal, J.; Bueno-Beti, C.; Bedja, D.; Scalco, A.; Amat-Alarcon, N.; Andersen, P.; Judge, D.P.; Tung, L.; et al. Therapeutic Modulation of the Immune Response in Arrhythmogenic Cardiomyopathy. *Circulation* **2019**, *140*, 1491–1505. [CrossRef]
28. D'Amati, G.; Leone, O.; di Gioia, C.R.; Magelli, C.; Arpesella, G.; Grillo, P.; Marino, B.; Fiore, F.; Gallo, P. Arrhythmogenic right ventricular cardiomyopathy: Clinicopathologic correlation based on a revised definition of pathologic patterns. *Hum. Pathol.* **2001**, *32*, 1078–1086. [CrossRef]
29. Sommariva, E.; Brambilla, S.; Carbucicchio, C.; Gambini, E.; Meraviglia, V.; Dello Russo, A.; Farina, F.M.; Casella, M.; Catto, V.; Pontone, G.; et al. Cardiac mesenchymal stromal cells are a source of adipocytes in arrhythmogenic cardiomyopathy. *Eur. Heart J.* **2016**, *37*, 1835–1846. [CrossRef]
30. Thiene, G.; Nava, A.; Corrado, D.; Rossi, L.; Pennelli, N. Right ventricular cardiomyopathy and sudden death in young people. *N. Engl. J. Med.* **1988**, *318*, 129–133. [CrossRef]
31. Nava, A.; Rossi, L.; Thiene, G. *Arrhythmogenic Right Ventricular Cardiomyopathy/Dysplasia*; International Congress Series (Book 1122); Excerpta Medica: Amstelveen, The Netherlands, 1997.
32. Richardson, P.; McKenna, W.; Bristow, M.; Maisch, B.; Mautner, B.; O'Connell, J.; Olsen, E.; Thiene, G.; Goodwin, J.; Gyarfas, I.; et al. Report of the 1995 World Health Organization/International Society and Federation of Cardiology Task Force on the Definition and Classification of cardiomyopathies. *Circulation* **1996**, *93*, 841–842. [PubMed]
33. Basso, C.; Nava, A.; Thiene, G. *Cardiomiopatia Aritmogena*; Arti Grafiche Color Black: Milano, Italy, 2001.
34. Corrado, D.; Basso, C.; Rizzoli, G.; Schiavon, M.; Thiene, G. Does sports activity enhance the risk of sudden death in adolescents and young adults? *J. Am. Coll. Cardiol.* **2003**, *42*, 1959–1963. [CrossRef] [PubMed]
35. Winkel, B.G.; Holst, A.G.; Theilade, J.; Kristensen, I.B.; Thomsen, J.L.; Ottesen, G.L.; Bundgaard, H.; Svendsen, J.H.; Haunsø, S.; Tfelt-Hansen, J. Nationwide study of sudden cardiac death in persons aged 1–35 years. *Eur. Heart J.* **2011**, *32*, 983–990. [CrossRef] [PubMed]
36. Finocchiaro, G.; Papadakis, M.; Robertus, J.L.; Dhutia, H.; Steriotis, A.K.; Tome, M.; Mellor, G.; Merghani, A.; Malhotra, A.; Behr, E.; et al. Etiology of Sudden Death in Sports: Insights From a United Kingdom Regional Registry. *J. Am. Coll. Cardiol.* **2016**, *67*, 2108–2115. [CrossRef]
37. Bagnall, R.D.; Weintraub, R.G.; Ingles, J.; Duflou, J.; Yeates, L.; Lam, L.; Davis, A.M.; Thompson, T.; Connell, V.; Wallace, J.; et al. A Prospective Study of Sudden Cardiac Death among Children and Young Adults. *N. Engl. J. Med.* **2016**, *374*, 2441–2452. [CrossRef] [PubMed]
38. Corrado, D.; Basso, C.; Pavei, A.; Michieli, P.; Schiavon, M.; Thiene, G. Trends in sudden cardiovascular death in young competitive athletes after implementation of a preparticipation screening program. *JAMA* **2006**, *296*, 1593–1601. [CrossRef]
39. Nava, A.; Thiene, G.; Canciani, B.; Scognamiglio, R.; Daliento, L.; Buja, G.; Martini, B.; Stritoni, P.; Fasoli, G. Familial occurrence of right ventricular dysplasia: A study involving nine families. *J. Am. Coll. Cardiol.* **1988**, *12*, 1222–1228. [CrossRef]
40. Nava, A.; Bauce, B.; Basso, C.; Muriago, M.; Rampazzo, A.; Villanova, C.; Daliento, L.; Buja, G.; Corrado, D.; Danieli, G.A.; et al. Clinical profile and long-term follow-up of 37 families with arrhythmogenic right ventricular cardiomyopathy. *J. Am. Coll. Cardiol.* **2000**, *36*, 2226–2233. [CrossRef]
41. Protonotarios, N.; Tsatsopoulou, A.; Patsourakos, P.; Alexopoulos, D.; Gezerlis, P.; Simitsis, S.; Scampardonis, G. Cardiac abnormalities in familial palmoplantar keratosis. *Br. Heart J.* **1986**, *56*, 321–326. [CrossRef]
42. Ruiz, P.; Brinkmann, V.; Ledermann, B.; Behrend, M.; Grund, C.; Thalhammer, C.; Vogel, F.; Birchmeier, C.; Günthert, U.; Franke, W.W.; et al. Targeted mutation of plakoglobin in mice reveals essential functions of desmosomes in the embryonic heart. *J. Cell Biol.* **1996**, *135*, 215–225. [CrossRef]
43. Coonar, A.S.; Protonotarios, N.; Tsatsopoulou, A.; Needham, E.W.; Houlston, R.S.; Cliff, S.; Otter, M.I.; Murday, V.A.; Mattu, R.K.; McKenna, W.J. Gene for arrhythmogenic right ventricular cardiomyopathy with diffuse nonepidermolytic palmoplantar keratoderma and woolly hair (Naxos disease) maps to 17q21. *Circulation* **1998**, *97*, 2049–2058. [CrossRef]
44. McKoy, G.; Protonotarios, N.; Crosby, A.; Tsatsopoulou, A.; Anastasakis, A.; Coonar, A.; Norman, M.; Baboonian, C.; Jeffery, S.; McKenna, W.J. Identification of a deletion in plakoglobin in arrhythmogenic right ventricular cardiomyopathy with palmoplantar keratoderma and woolly hair (Naxos disease). *Lancet* **2000**, *355*, 2119–2124. [CrossRef] [PubMed]
45. Carvajal-Huerta, L. Epidermolytic palmoplantar keratoderma with woolly hair and dilated cardiomyopathy. *J. Am. Acad. Dermatol.* **1998**, *39*, 418–421. [CrossRef]
46. Norgett, E.E.; Hatsell, S.J.; Carvajal-Huerta, L.; Cabezas, J.C.; Common, J.; Purkis, P.E.; Whittock, N.; Leigh, I.M.; Stevens, H.P.; Kelsell, D.P. Recessive mutation in desmoplakin disrupts desmoplakin-intermediate filament interactions and causes dilated cardiomyopathy, woolly hair and keratoderma. *Hum. Mol. Genet.* **2000**, *9*, 2761–2766. [CrossRef] [PubMed]
47. Kaplan, S.R.; Gard, J.J.; Carvajal-Huerta, L.; Ruiz-Cabezas, J.C.; Thiene, G.; Saffitz, J.E. Structural and molecular pathology of the heart in Carvajal syndrome. *Cardiovasc. Pathol.* **2004**, *13*, 26–32. [CrossRef]

48. Rampazzo, A.; Nava, A.; Malacrida, S.; Beffagna, G.; Bauce, B.; Rossi, V.; Zimbello, R.; Simionati, B.; Basso, C.; Thiene, G.; et al. Mutation in human desmoplakin domain binding to plakoglobin causes a dominant form of arrhythmogenic right ventricular cardiomyopathy. *Am. J. Hum. Genet.* **2002**, *71*, 1200–1206. [CrossRef] [PubMed]
49. Bauce, B.; Basso, C.; Rampazzo, A.; Beffagna, G.; Daliento, L.; Frigo, G.; Malacrida, S.; Settimo, L.; Danieli, G.; Thiene, G.; et al. Clinical profile of four families with arrhythmogenic right ventricular cardiomyopathy caused by dominant desmoplakin mutations. *Eur. Heart J.* **2005**, *26*, 1666–1675. [CrossRef]
50. Gerull, B.; Heuser, A.; Wichter, T.; Paul, M.; Basson, C.T.; McDermott, D.A.; Lerman, B.B.; Markowitz, S.M.; Ellinor, P.T.; MacRae, C.A.; et al. Mutations in the desmosomal protein plakophilin-2 are common in arrhythmogenic right ventricular cardiomyopathy. *Nat. Genet.* **2004**, *36*, 1162–1164. [CrossRef] [PubMed]
51. Pilichou, K.; Nava, A.; Basso, C.; Beffagna, G.; Bauce, B.; Lorenzon, A.; Frigo, G.; Vettori, A.; Valente, M.; Towbin, J.; et al. Mutations in desmoglein-2 gene are associated with arrhythmogenic right ventricular cardiomyopathy. *Circulation* **2006**, *113*, 1171–1179. [CrossRef] [PubMed]
52. Syrris, P.; Ward, D.; Evans, A.; Asimaki, A.; Gandjbakhch, E.; Sen-Chowdhry, S.; McKenna, W.J. Arrhythmogenic right ventricular dysplasia/cardiomyopathy associated with mutations in the desmosomal gene desmocollin-2. *Am. J. Hum. Genet.* **2006**, *79*, 978–984. [CrossRef]
53. Beffagna, G.; De Bortoli, M.; Nava, A.; Salamon, M.; Lorenzon, A.; Zaccolo, M.; Mancuso, L.; Sigalotti, L.; Bauce, B.; Occhi, G.; et al. Missense mutations in desmocollin-2 N-terminus, associated with arrhythmogenic right ventricular cardiomyopathy, affect intracellular localization of desmocollin-2 in vitro. *BMC Med. Genet.* **2007**, *8*, 65. [CrossRef] [PubMed]
54. Asimaki, A.; Syrris, P.; Wichter, T.; Matthias, P.; Saffitz, J.E.; McKenna, W.J. A novel dominant mutation in plakoglobin causes arrhythmogenic right ventricular cardiomyopathy. *Am. J. Hum. Genet.* **2007**, *81*, 964–973. [CrossRef] [PubMed]
55. Rigato, I.; Bauce, B.; Rampazzo, A.; Zorzi, A.; Pilichou, K.; Mazzotti, E.; Migliore, F.; Marra, M.P.; Lorenzon, A.; De Bortoli, M.; et al. Compound and digenic heterozygosity predicts lifetime arrhythmic outcome and sudden cardiac death in desmosomal gene-related arrhythmogenic right ventricular cardiomyopathy. *Circ. Cardiovasc. Genet.* **2013**, *6*, 533–542. [CrossRef] [PubMed]
56. Pilichou, K.; Remme, C.A.; Basso, C.; Campian, M.E.; Rizzo, S.; Barnett, P.; Scicluna, B.P.; Bauce, B.; van den Hoff, M.J.; de Bakker, J.M.; et al. Myocyte necrosis underlies progressive myocardial dystrophy in mouse dsg2-related arrhythmogenic right ventricular cardiomyopathy. *J. Exp. Med.* **2009**, *206*, 1787–1802. [CrossRef]
57. Garcia-Gras, E.; Lombardi, R.; Giocondo, M.J.; Willerson, J.T.; Schneider, M.D.; Khoury, D.S.; Marian, A.J. Suppression of canonical Wnt/beta-catenin signaling by nuclear plakoglobin recapitulates phenotype of arrhythmogenic right ventricular cardiomyopathy. *J. Clin. Investig.* **2006**, *116*, 2012–2021. [CrossRef]
58. Giuliodori, A.; Beffagna, G.; Marchetto, G.; Fornetto, C.; Vanzi, F.; Toppo, S.; Facchinello, N.; Santimaria, M.; Vettori, A.; Rizzo, S.; et al. Loss of cardiac Wnt/β-catenin signalling in desmoplakin-deficient AC8 zebrafish models is rescuable by genetic and pharmacological intervention. *Cardiovasc. Res.* **2018**, *114*, 1082–1097. [CrossRef]
59. Asimaki, A.; Kapoor, S.; Plovie, E.; Karin Arndt, A.; Adams, E.; Liu, Z.; James, C.A.; Judge, D.P.; Calkins, H.; Churko, J.; et al. Identification of a new modulator of the intercalated disc in a zebrafish model of arrhythmogenic cardiomyopathy. *Sci. Transl. Med.* **2014**, *6*, 240ra74. [CrossRef]
60. Risato, G.; Celeghin, R.; Brañas Casas, R.; Dinarello, A.; Zuppardo, A.; Vettori, A.; Pilichou, K.; Thiene, G.; Basso, C.; Argenton, F.; et al. Hyperactivation of Wnt/β-catenin and Jak/Stat3 pathways in human and zebrafish foetal growth restriction models: Implications for pharmacological rescue. *Front. Cell Dev. Biol.* **2022**, *10*, 943127. [CrossRef]
61. Rizzo, S.; Lodder, E.M.; Verkerk, A.O.; Wolswinkel, R.; Beekman, L.; Pilichou, K.; Basso, C.; Remme, C.A.; Thiene, G.; Bezzina, C.R. Intercalated disc abnormalities, reduced Na(+) current density, and conduction slowing in desmoglein-2 mutant mice prior to cardiomyopathic changes. *Cardiovasc. Res.* **2012**, *95*, 409–418. [CrossRef]
62. Merner, N.D.; Hodgkinson, K.A.; Haywood, A.F.; Connors, S.; French, V.M.; Drenckhahn, J.D.; Kupprion, C.; Ramadanova, K.; Thierfelder, L.; McKenna, W.; et al. Arrhythmogenic right ventricular cardiomyopathy type 5 is a fully penetrant, lethal arrhythmic disorder caused by a missense mutation in the TMEM43 gene. *Am. J. Hum. Genet.* **2008**, *82*, 809–821. [CrossRef]
63. Christensen, A.H.; Andersen, C.B.; Tybjaerg-Hansen, A.; Haunso, S.; Svendsen, J.H. Mutation analysis and evaluation of the cardiac localization of TMEM43 in arrhythmogenic right ventricular cardiomyopathy. *Clin. Genet.* **2011**, *80*, 256–264. [CrossRef]
64. Haywood, A.F.; Merner, N.D.; Hodgkinson, K.A.; Houston, J.; Syrris, P.; Booth, V.; Connors, S.; Pantazis, A.; Quarta, G.; Elliott, P.; et al. Recurrent missense mutations in TMEM43 (ARVD5) due to founder effects cause arrhythmogenic cardiomyopathies in the UK and Canada. *Eur. Heart J.* **2013**, *34*, 1002–1011. [CrossRef] [PubMed]
65. Erkapic, D.; Neumann, T.; Schmitt, J.; Sperzel, J.; Berkowitsch, A.; Kuniss, M.; Hamm, C.W.; Pitschner, H.F. Electrical storm in a patient with arrhythmogenic right ventricular cardiomyopathy and SCN5A mutation. *Europace* **2008**, *10*, 884–887. [CrossRef] [PubMed]
66. Yu, J.; Hu, J.; Dai, X.; Cao, Q.; Xiong, Q.; Liu, X.; Liu, X.; Shen, Y.; Chen, Q.; Hua, W.; et al. SCN5A mutation in Chinese patients with arrhythmogenic right ventricular dysplasia. *Herz* **2014**, *39*, 271–275. [CrossRef] [PubMed]
67. Te Riele, A.S.; Agullo-Pascual, E.; James, C.A.; Leo-Macias, A.; Cerrone, M.; Zhang, M.; Lin, X.; Lin, B.; Sobreira, N.L.; Amat-Alarcon, N.; et al. Multilevel analyses of SCN5A mutations in arrhythmogenic right ventricular dysplasia/cardiomyopathy suggest non-canonical mechanisms for disease pathogenesis. *Cardiovasc. Res.* **2017**, *113*, 102–111. [CrossRef] [PubMed]

68. van Tintelen, J.P.; Van Gelder, I.C.; Asimaki, A.; Suurmeijer, A.J.; Wiesfeld, A.C.; Jongbloed, J.D.; van den Wijngaard, A.; Kuks, J.B.; van Spaendonck-Zwarts, K.Y.; Notermans, N.; et al. Severe cardiac phenotype with right ventricular predominance in a large cohort of patients with a single missense mutation in the DES gene. *Heart Rhythm.* **2009**, *6*, 1574–1583. [CrossRef]
69. Otten, E.; Asimaki, A.; Maass, A.; van Langen, I.M.; van der Wal, A.; de Jonge, N.; van den Berg, M.P.; Saffitz, J.E.; Wilde, A.A.; Jongbloed, J.D.; et al. Desmin mutations as a cause of right ventricular heart failure affect the intercalated disks. *Heart Rhythm.* **2010**, *7*, 1058–1064. [CrossRef]
70. Klauke, B.; Kossmann, S.; Gaertner, A.; Brand, K.; Stork, I.; Brodehl, A.; Dieding, M.; Walhorn, V.; Anselmetti, D.; Gerdes, D.; et al. De novo desmin-mutation N116S is associated with arrhythmogenic right ventricular cardiomyopathy. *Hum. Mol. Genet.* **2010**, *19*, 4595–4607. [CrossRef]
71. Hedberg, C.; Melberg, A.; Kuhl, A.; Jenne, D.; Oldfors, A. Autosomal dominant myofibrillar myopathy with arrhythmogenic right ventricular cardiomyopathy 7 is caused by a DES mutation. *Eur. J. Hum. Genet.* **2012**, *20*, 984–985. [CrossRef]
72. Lorenzon, A.; Beffagna, G.; Bauce, B.; De Bortoli, M.; Li Mura, I.E.; Calore, M.; Dazzo, E.; Basso, C.; Nava, A.; Thiene, G.; et al. Desmin mutations and arrhythmogenic right ventricular cardiomyopathy. *Am. J. Cardiol.* **2013**, *111*, 400–405. [CrossRef]
73. Brodehl, A.; Dieding, M.; Klauke, B.; Dec, E.; Madaan, S.; Huang, T.; Gargus, J.; Fatima, A.; Saric, T.; Cakar, H.; et al. The novel desmin mutant p.A120D impairs filament formation, prevents intercalated disk localization, and causes sudden cardiac death. *Circ. Cardiovasc. Genet.* **2013**, *6*, 615–623. [CrossRef] [PubMed]
74. Ripoll-Vera, T.; Zorio, E.; Gámez, J.M.; Molina, P.; Govea, N.; Crémer, D. Phenotypic Patterns of Cardiomyopathy Caused by Mutations in the Desmin Gene. A Clinical and Genetic Study in Two Inherited Heart Disease Units. *Rev. Esp. Cardiol.* **2015**, *68*, 1027–1029. [CrossRef]
75. Bermúdez-Jiménez, F.J.; Carriel, V.; Brodehl, A.; Alaminos, M.; Campos, A.; Schirmer, I.; Milting, H.; Abril, B.Á.; Álvarez, M.; López-Fernández, S.; et al. Novel Desmin Mutation p.Glu401Asp Impairs Filament Formation, Disrupts Cell Membrane Integrity, and Causes Severe Arrhythmogenic Left Ventricular Cardiomyopathy/Dysplasia. *Circulation* **2018**, *137*, 1595–1610. [CrossRef] [PubMed]
76. van der Zwaag, P.A.; van Rijsingen, I.A.; Asimaki, A.; Jongbloed, J.D.; van Veldhuisen, D.J.; Wiesfeld, A.C.; Cox, M.G.; van Lochem, L.T.; de Boer, R.A.; Hofstra, R.M.; et al. Phospholamban R14del mutation in patients diagnosed with dilated cardiomyopathy or arrhythmogenic right ventricular cardiomyopathy: Evidence supporting the concept of arrhythmogenic cardiomyopathy. *Eur. J. Heart Fail.* **2012**, *14*, 1199–1207. [CrossRef] [PubMed]
77. van der Zwaag, P.A.; van Rijsingen, I.A.; de Ruiter, R.; Nannenberg, E.A.; Groeneweg, J.A.; Post, J.G.; Hauer, R.N.; van Gelder, I.C.; van den Berg, M.P.; van der Harst, P.; et al. Recurrent and founder mutations in the Netherlands-Phospholamban p.Arg14del mutation causes arrhythmogenic cardiomyopathy. *Neth. Heart J.* **2013**, *21*, 286–293. [CrossRef]
78. van Rijsingen, I.A.; van der Zwaag, P.A.; Groeneweg, J.A.; Nannenberg, E.A.; Jongbloed, J.D.; Zwinderman, A.H.; Pinto, Y.M.; Dit Deprez, R.H.; Post, J.G.; Tan, H.L.; et al. Outcome in phospholamban R14del carriers: Results of a large multicentre cohort study. *Circ. Cardiovasc. Genet.* **2014**, *7*, 455–465. [CrossRef]
79. Gho, J.M.; van Es, R.; Stathonikos, N.; Harakalova, M.; te Rijdt, W.P.; Suurmeijer, A.J.; van der Heijden, J.F.; de Jonge, N.; Chamuleau, S.A.; de Weger, R.A.; et al. High resolution systematic digital histological quantification of cardiac fibrosis and adipose tissue in phospholamban p.Arg14del mutation associated cardiomyopathy. *PLoS ONE* **2014**, *9*, e94820. [CrossRef]
80. Groeneweg, J.A.; van der Zwaag, P.A.; Olde Nordkamp, L.R.; Bikker, H.; Jongbloed, J.D.; Jongbloed, R.; Wiesfeld, A.C.; Cox, M.G.; van der Heijden, J.F.; Atsma, D.E.; et al. Arrhythmogenic right ventricular dysplasia/cardiomyopathy according to revised 2010 task force criteria with inclusion of non-desmosomal phospholamban mutation carriers. *Am. J. Cardiol.* **2013**, *112*, 1197–1206. [CrossRef]
81. Quarta, G.; Syrris, P.; Ashworth, M.; Jenkins, S.; Zuborne Alapi, K.; Morgan, J.; Muir, A.; Pantazis, A.; McKenna, W.J.; Elliott, P.M. Mutations in the Lamin A/C gene mimic arrhythmogenic right ventricular cardiomyopathy. *Eur. Heart J.* **2012**, *33*, 1128–1136. [CrossRef]
82. Valtuille, L.; Paterson, I.; Kim, D.H.; Mullen, J.; Sergi, C.; Oudit, G.Y. A case of lamin A/C mutation cardiomyopathy with overlap features of ARVC: A critical role of genetic testing. *Int. J. Cardiol.* **2013**, *168*, 4325–4327. [CrossRef]
83. Alastalo, T.P.; West, G.; Li, S.P.; Keinänen, A.; Helenius, M.; Tyni, T.; Lapatto, R.; Turanlahti, M.; Heikkilä, P.; Kääriäinen, H.; et al. LMNA Mutation c.917T>G (p.L306R) Leads to Deleterious Hyper-Assembly of Lamin A/C and Associates with Severe Right Ventricular Cardiomyopathy and Premature Aging. *Hum. Mutat.* **2015**, *36*, 694–703. [CrossRef] [PubMed]
84. Kato, K.; Takahashi, N.; Fujii, Y.; Umehara, A.; Nishiuchi, S.; Makiyama, T.; Ohno, S.; Horie, M. LMNA cardiomyopathy detected in Japanese arrhythmogenic right ventricular cardiomyopathy cohort. *J. Cardiol.* **2016**, *68*, 346–351. [CrossRef] [PubMed]
85. Ortiz-Genga, M.F.; Cuenca, S.; Dal Ferro, M.; Zorio, E.; Salgado-Aranda, R.; Climent, V.; Padrón-Barthe, L.; Duro-Aguado, I.; Jiménez-Jáimez, J.; Hidalgo-Olivares, V.M.; et al. Truncating FLNC Mutations Are Associated With High-Risk Dilated and Arrhythmogenic Cardiomyopathies. *J. Am. Coll. Cardiol.* **2016**, *68*, 2440–2451. [CrossRef] [PubMed]
86. Brun, F.; Gigli, M.; Graw, S.L.; Judge, D.P.; Merlo, M.; Murray, B.; Calkins, H.; Sinagra, G.; Taylor, M.R.; Mestroni, L.; et al. FLNC truncations cause arrhythmogenic right ventricular cardiomyopathy. *J. Med. Genet.* **2020**, *57*, 254–257. [CrossRef] [PubMed]
87. Oz, S.; Yonath, H.; Visochyk, L.; Ofek, E.; Landa, N.; Reznik-Wolf, H.; Ortiz-Genga, M.; Monserrat, L.; Ben-Gal, T.; Goitein, O.; et al. Reduction in Filamin C transcript is associated with arrhythmogenic cardiomyopathy in Ashkenazi Jews. *Int. J. Cardiol.* **2020**, *317*, 133–138. [CrossRef] [PubMed]

88. Hall, C.L.; Akhtar, M.M.; Sabater-Molina, M.; Futema, M.; Asimaki, A.; Protonotarios, A.; Dalageorgou, C.; Pittman, A.M.; Suarez, M.P.; Aguilera, B.; et al. Filamin C variants are associated with a distinctive clinical and immunohistochemical arrhythmogenic cardiomyopathy phenotype. *Int. J. Cardiol.* **2020**, *307*, 101–108. [CrossRef]
89. Celeghin, R.; Cipriani, A.; Bariani, R.; Bueno Marinas, M.; Cason, M.; Bevilacqua, M.; De Gaspari, M.; Rizzo, S.; Rigato, I.; Da Pozzo, S.; et al. Filamin-C variant-associated cardiomyopathy: A pooled analysis of individual patient data to evaluate the clinical profile and risk of sudden cardiac death. *Heart Rhythm.* **2022**, *19*, 235–243. [CrossRef]
90. Turkowski, K.L.; Tester, D.J.; Bos, J.M.; Haugaa, K.H.; Ackerman, M.J. Whole exome sequencing with genomic triangulation implicates CDH2-encoded N-cadherin as a novel pathogenic substrate for arrhythmogenic cardiomyopathy. *Congenit. Heart Dis.* **2017**, *12*, 226–235. [CrossRef]
91. Mayosi, B.M.; Fish, M.; Shaboodien, G.; Mastantuono, E.; Kraus, S.; Wieland, T.; Kotta, M.C.; Chin, A.; Laing, N.; Ntusi, N.B.; et al. Identification of Cadherin 2 (CDH2) Mutations in Arrhythmogenic Right Ventricular Cardiomyopathy. *Circ. Cardiovasc. Genet.* **2017**, *10*, e001605. [CrossRef]
92. Ghidoni, A.; Elliott, P.M.; Syrris, P.; Calkins, H.; James, C.A.; Judge, D.P.; Murray, B.; Barc, J.; Probst, V.; Schott, J.J.; et al. Cadherin 2-Related Arrhythmogenic Cardiomyopathy: Prevalence and Clinical Features. *Circ. Genom. Precis. Med.* **2021**, *14*, e003097. [CrossRef]
93. De Bortoli, M.; Postma, A.V.; Poloni, G.; Calore, M.; Minervini, G.; Mazzotti, E.; Rigato, I.; Ebert, M.; Lorenzon, A.; Vazza, G.; et al. Whole-Exome Sequencing Identifies Pathogenic Variants in TJP1 Gene Associated with Arrhythmogenic Cardiomyopathy. *Circ. Genom. Precis. Med.* **2018**, *11*, e002123. [CrossRef] [PubMed]
94. Quang, K.L.; Maguy, A.; Qi, X.Y.; Naud, P.; Xiong, F.; Tadevosyan, A.; Shi, Y.F.; Chartier, D.; Tardif, J.C.; Dobrev, D.; et al. Loss of cardiomyocyte integrin-linked kinase produces an arrhythmogenic cardiomyopathy in mice. *Circ. Arrhythm. Electrophysiol.* **2015**, *8*, 921–932. [CrossRef] [PubMed]
95. Brodehl, A.; Rezazadeh, S.; Williams, T.; Munsie, N.M.; Liedtke, D.; Oh, T.; Ferrier, R.; Shen, Y.; Jones, S.J.M.; Stiegler, A.L.; et al. Mutations in ILK, encoding integrin-linked kinase, are associated with arrhythmogenic cardiomyopathy. *Transl. Res.* **2019**, *208*, 15–29. [CrossRef] [PubMed]
96. Abdelfatah, N.; Chen, R.; Duff, H.J.; Seifer, C.M.; Buffo, I.; Huculak, C.; Clarke, S.; Clegg, R.; Jassal, D.S.; Gordon, P.M.K.; et al. Characterization of a Unique Form of Arrhythmic Cardiomyopathy Caused by Recessive Mutation in LEMD2. *JACC Basic Transl. Sci.* **2019**, *4*, 204–221. [CrossRef] [PubMed]
97. Stevens, T.L.; Wallace, M.J.; Refaey, M.E.; Roberts, J.D.; Koenig, S.N.; Mohler, P.J. Arrhythmogenic Cardiomyopathy: Molecular Insights for Improved Therapeutic Design. *J. Cardiovasc. Dev. Dis.* **2020**, *7*, 21. [CrossRef]
98. Celeghin, R.; Pilichou, K. The complex molecular genetics of arrhythmogenic cardiomyopathy. *Int. J. Cardiol.* **2019**, *284*, 59–60. [CrossRef]
99. James, C.A.; Jongbloed, J.D.H.; Hershberger, R.E.; Morales, A.; Judge, D.P.; Syrris, P.; Pilichou, K.; Domingo, A.M.; Murray, B.; Cadrin-Tourigny, J.; et al. International Evidence Based Reappraisal of Genes Associated with Arrhythmogenic Right Ventricular Cardiomyopathy Using the Clinical Genome Resource Framework. *Circ. Genom. Precis. Med.* **2021**, *14*, e003273. [CrossRef]
100. McKenna, W.J.; Thiene, G.; Nava, A.; Fontaliran, F.; Blomstrom-Lundqvist, C.; Fontaine, G.; Camerini, F. Diagnosis of arrhythmogenic right ventricular dysplasia/cardiomyopathy. Task Force of the Working Group Myocardial and Pericardial Disease of the European Society of Cardiology and of the Scientific Council on Cardiomyopathies of the International Society and Federation of Cardiology. *Br. Heart J.* **1994**, *71*, 215–218.
101. Marcus, F.I.; McKenna, W.J.; Sherrill, D.; Basso, C.; Bauce, B.; Bluemke, D.A.; Calkins, H.; Corrado, D.; Cox, M.G.; Daubert, J.P.; et al. Diagnosis of arrhythmogenic right ventricular cardiomyopathy/dysplasia: Proposed modification of the task force criteria. *Circulation* **2010**, *121*, 1533–1541. [CrossRef]
102. Daliento, L.; Rizzoli, G.; Thiene, G.; Nava, A.; Rinuncini, M.; Chioin, R.; Dalla Volta, S. Diagnostic accuracy of right ventriculography in arrhythmogenic right ventricular cardiomyopathy. *Am. J. Cardiol.* **1990**, *66*, 741–745. [CrossRef]
103. Basso, C.; Ronco, F.; Marcus, F.; Abudureheman, A.; Rizzo, S.; Frigo, A.C.; Bauce, B.; Maddalena, F.; Nava, A.; Corrado, D.; et al. Quantitative assessment of endomyocardial biopsy in arrhythmogenic right ventricular cardiomyopathy/dysplasia: An in vitro validation of diagnostic criteria. *Eur. Heart J.* **2008**, *29*, 2760–2771. [CrossRef]
104. Zorzi, A.; Perazzolo Marra, M.; Rigato, I.; De Lazzari, M.; Susana, A.; Niero, A.; Pilichou, K.; Migliore, F.; Rizzo, S.; Giorgi, B.; et al. Nonischemic Left Ventricular Scar as a Substrate of Life-Threatening Ventricular Arrhythmias and Sudden Cardiac Death in Competitive Athletes. *Circ. Arrhythm. Electrophysiol.* **2016**, *9*, e004229. [CrossRef] [PubMed]
105. Norman, M.; Simpson, M.; Mogensen, J.; Shaw, A.; Hughes, S.; Syrris, P.; Sen-Chowdhry, S.; Rowland, E.; Crosby, A.; McKenna, W.J. Novel mutation in desmoplakin causes arrhythmogenic left ventricular cardiomyopathy. *Circulation* **2005**, *112*, 636–642. [CrossRef] [PubMed]
106. Corrado, D.; Basso, C.; Leoni, L.; Tokajuk, B.; Turrini, P.; Bauce, B.; Migliore, F.; Pavei, A.; Tarantini, G.; Napodano, M.; et al. Three-dimensional electroanatomical voltage mapping and histologic evaluation of myocardial substrate in right ventricular outflow tract tachycardia. *J. Am. Coll. Cardiol.* **2008**, *51*, 731–739. [CrossRef]
107. Migliore, F.; Zorzi, A.; Michieli, P.; Perazzolo Marra, M.; Siciliano, M.; Rigato, I.; Bauce, B.; Basso, C.; Toazza, D.; Schiavon, M.; et al. Prevalence of cardiomyopathy in Italian asymptomatic children with electrocardiographic T-wave inversion at preparticipation screening. *Circulation* **2012**, *125*, 529–538. [CrossRef] [PubMed]

108. Corrado, D.; Leoni, L.; Link, M.S.; Della Bella, P.; Gaita, F.; Curnis, A.; Salerno, J.U.; Igidbashian, D.; Raviele, A.; Disertori, M.; et al. Implantable cardioverter-defibrillator therapy for prevention of sudden death in patients with arrhythmogenic right ventricular cardiomyopathy/dysplasia. *Circulation* **2003**, *108*, 3084–3091. [CrossRef]
109. Corrado, D.; Basso, C.; Pilichou, K.; Thiene, G. Molecular biology and clinical management of arrhythmogenic right ventricular cardiomyopathy/dysplasia. *Heart* **2011**, *97*, 530–539. [CrossRef]
110. Marcus, F.I.; Nava, A.; Thiene, G. *Arrhythmogenic RV Cardiomyopathy/Dysplasia*; Springer: Berlin/Heidelberg, Germany, 2007.

Disclaimer/Publisher's Note: The statements, opinions and data contained in all publications are solely those of the individual author(s) and contributor(s) and not of MDPI and/or the editor(s). MDPI and/or the editor(s) disclaim responsibility for any injury to people or property resulting from any ideas, methods, instructions or products referred to in the content.