

## Review

# Effectiveness of Platelet-Rich Plasma in the Treatment of Androgenic Alopecia Compared to Placebo and Topical Minoxidil: A Systematic Review

Julia Maria Borowiecka <sup>1</sup>, Bartosz Dalewski <sup>2</sup> and Łukasz Pałka <sup>3,\*</sup><sup>1</sup> Gynecology and Obstetrics Student Research Club, Medical University of Warsaw, Żwirki and Wigury 61, 02-091 Warsaw, Poland<sup>2</sup> Department of Dental Prosthetics, Pomeranian Medical University, 70-204 Szczecin, Poland<sup>3</sup> Private Dental Practice, Rzeszowska 2, 68-200 Żary, Poland

\* Correspondence: dr.lpalka@gmail.com

**Abstract:** Platelet-rich plasma (PRP) has become an increasingly popular alternative or additional method in treating androgenic alopecia (AGA). AGA is a multifactorial disease, in which testosterone plays a significant role in influencing hair growth. The aim of this study was to evaluate the effectiveness of PRP treatment in AGA affecting men and women. The research was performed using the following databases: PubMed, Embase, and Cochrane Library. The effects were measured with a TrichoScan by comparing the initial and final hair density. A significant difference was observed between the areas of the scalp where PRP injections were made and those where saline was administered. Compared to conventional minoxidil 5% topical PRP, PRP is more effective in treating alopecia. A beneficial outcome of combined therapy with PRP and minoxidil 5% was observed. Therefore, PRP is not only an excellent alternative for patients in whom the minoxidil 5% topical monotherapy did not bring the expected effects or who experienced unacceptable side effects, but can also be used as a complementary therapy.

**Keywords:** alopecia; androgenic alopecia; platelet-rich plasma; PRP; treatment

**Citation:** Borowiecka, J.M.; Dalewski, B.; Pałka, Ł. Effectiveness of Platelet-Rich Plasma in the Treatment of Androgenic Alopecia Compared to Placebo and Topical Minoxidil: A Systematic Review. *Sci. Pharm.* **2023**, *91*, 4. <https://doi.org/10.3390/scipharm91010004>

Academic Editor: Francisco Javier Otero-Espinar

Received: 22 October 2022

Revised: 20 December 2022

Accepted: 28 December 2022

Published: 31 December 2022



**Copyright:** © 2022 by the authors. Licensee MDPI, Basel, Switzerland. This article is an open access article distributed under the terms and conditions of the Creative Commons Attribution (CC BY) license (<https://creativecommons.org/licenses/by/4.0/>).

## 1. Introduction

Androgenic alopecia (AGA) is a polygenetic condition characterized by progressive non-scarring hair loss due to hair follicle miniaturization. In men, specific locations include temporal and vertex areas, while the occipital region is usually spared. In women, on the other hand, diffuse thinning of hair is usually observed [1] (Figure 1). According to epidemiological data, AGA prevails in the Caucasian population, where it affects approximately 80% of men and 50% of women [1]. Although AGA is a multifactorial condition, androgens play an important role in its pathophysiology. Dihydrotestosterone (DHT) is a metabolite of testosterone produced by 5-alpha-reductase. Type 2 of 5-alpha-reductase is found in the outer root sheath of hair follicles and is instrumental in AGA [2]. Androgen receptors (AR) have two domains—one responsible for binding a ligand (in this case, androgen hormones) and the second for DNA binding. Activation of the AR leads to exposure of androgen-sensitive genes, including gene controlling the hair growth cycle [3].

Female and male androgenetic alopecia present with different clinical patterns. In women, the expression of 5-alpha-reductase is decreased compared to men, which results in less severe hair loss. In men, mainly temporal and parietal areas are affected, while in women, a diffuse pattern of hair loss would be observed [4].

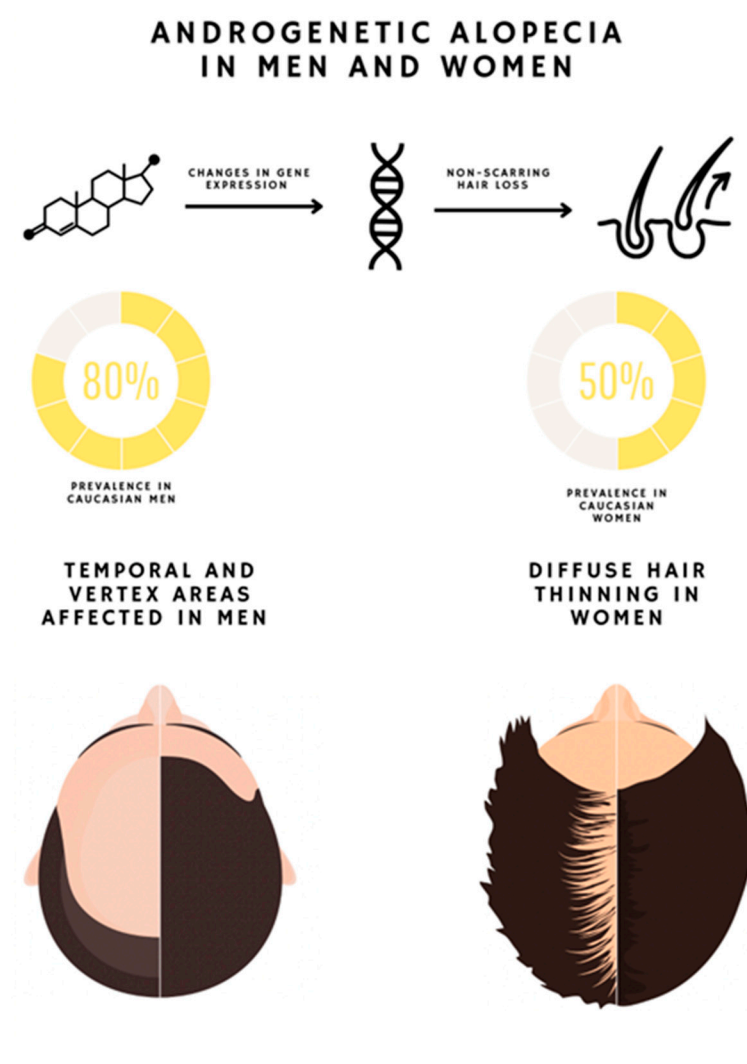
Conventional AGA treatments include therapies approved by the Food and Drug Administration (FDA), i.e., 5% topical minoxidil, 5-alpha-reductase inhibitors

(finasteride), and low-level light therapy (LLLT) [5]. Minoxidil leads to vasodilation secondary to potassium channel opening and smooth muscle relaxation. Higher blood flow increases the level of growth factors in the dermal papilla (DP) [1]. Finasteride is a per os drug that inhibits type II 5- $\alpha$ -reductase, while dutasteride inhibits both I and II types [6]. However, using these drugs carries a specific risk of sexual dysfunction [7]. Low-level light therapy increases hair density, but its exact mechanism is unknown [1].

Other therapeutic alternatives include off-label options such as androgen receptor antagonists, prostaglandin analogs, and ketoconazole.

Androgen receptor antagonists include spironolactone, cyproterone acetate, and flutamide. There are not enough data providing information on the effectiveness of these agents in patients without hyperandrogenism in the treatment of AGA, and they are also highly teratogenic [1].

Prostaglandin F (PGF) analogs are used in eyelash hypotrichosis as they prolong anagen phases. High levels of prostaglandin D (PGD) and its synthetase were discovered in the scalp of men suffering from AGA [8]. These data imply that prostaglandins play an important role in hair growth and a proper balance between PGF and PGD is needed.



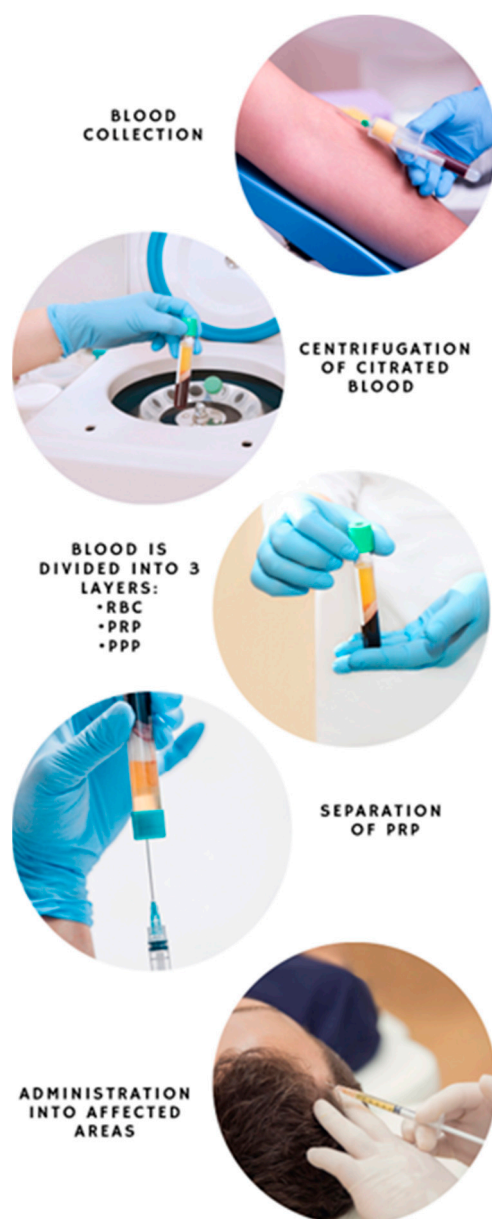
**Figure 1.** Androgenic alopecia in men and women.

Ketoconazole is an antifungal agent that interferes with steroidogenesis affecting androgen levels. It is often used topically in combination with finasteride to produce an additional decrease in DHT in the scalp [1].

Novel therapies include stem cells, scalp micro-needling, Wnt signaling, JAK-STAT signaling, and platelet-rich plasma (PRP) injections [9].

PRP is a blood-derivative previously used in thrombocytopenia treatment [10]. Over time, when the regeneration-stimulating effect of PRP was observed, it began to be used in many other fields of medicine, including orthopedics, gynecology, dermatology, urology, and ophthalmology [11]. Current dermatology applications include hair loss treatment, wound healing improvement, skin rejuvenation and scar appearance improvement [12].

To obtain PRP, citrated whole blood is used in the centrifugation process, which prevents coagulation. The addition of anticoagulant enables treatment providers to obtain liquid PRP [13]. After centrifugation, blood is divided into three layers: red blood cells (RBC) and leukocytes, PRP, and platelet-poor plasma (PPP) [14] (Figure 2).



**Figure 2.** Centrifugation and platelet-rich plasma separation.

A high concentration of autologous platelets is present in a small quantity of plasma after centrifugation of the patient's blood. Alpha granules in the platelets induce stem cell regeneration and promote remodeling of soft tissue. There are many growth factors in

alpha granules of thrombocytes, such as platelet-derived growth factors (PDGF), vascular endothelial growth factor (VEGF), epithelial growth factor (EGF), transforming growth factor-beta (TGF beta), and insulin-like growth factor (IGF) [15]. The mitogenesis and differentiation of monocytes, fibroblasts, stem cells, keratinocytes, and endothelial cells occurs due to growth factors in the PRP alpha granule [12].

## 2. Materials and Methods

### 2.1. PICOS

This systematic review was conducted according to the PICOS criteria and PRISMA protocol (registered in the PROSPERO database for systematic reviews under 353692).

Patient (P): Men and women in all the stages of AGA based on the Norwood scale

Intervention (I): PRP subcutaneous scalp injections

Control (C): Compared with placebo

Outcome of interest (O): Male and female pattern hair loss

Study design (S): randomized clinical trials with placebo control

Focused question: Is PRP more effective in treating AGA than topical 5% minoxidil and placebo?

Search strategy: The reviewer performed computerized, systematic research using the following databases:

PubMed, EMBASE, and Cochrane Library using the following BOOLEAN operators:

“Platelet AND Rich AND Plasma” OR “androgen AND alopecia” OR “androgen AND hair loss” OR “PRP AND treatment” OR “treatment AND androgenic AND alopecia” OR “Platelet AND Rich AND Plasma AND injections” OR “baldness” OR “male AND pattern AND hair AND loss”

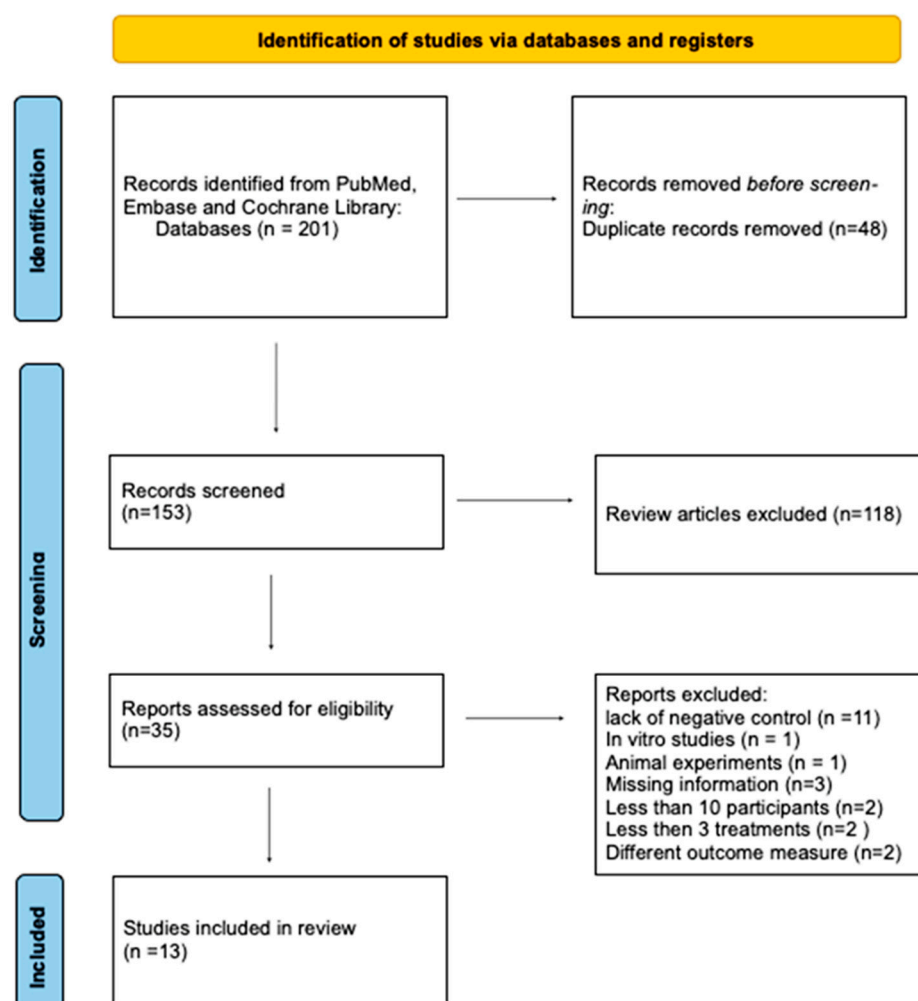
### 2.2. Study Selection

The investigator performed quality control of pre-qualified studies using the inclusion and exclusion criteria. The risk of bias was assessed as low based on a common classification scheme for bias. The research was performed in November 2021 and updated in August 2022.

The study was included if it met the following inclusion criteria: hair loss clinically typical for AGA, randomized clinical trial with placebo control, PRP injections, published in English, at least three treatment sessions, and at least 30-day follow-up, with outcomes measured in hair density.

Exclusion criteria: meta-analysis, systematic reviews, books, case reports, in vitro studies, animal experiments, lack of negative control, hair loss different than AGA, group of participants smaller than 10, studies published prior to 2011.

The search strategy resulted in 153 articles with a full-text review of 35 studies. Twenty-two studies were clinical trials but did not meet other inclusion criteria such as number of interventions, number of participants, and outcome measurement (Figure 3).



**Figure 3.** Identification of studies via databases and registers.

### 3. Results and Discussion

A total of 435 patients were selected for the study. The number of procedures ranged from 3 to 5 (mean = 3; median = 3) and the duration of the studies ranged from 2 months up to 24 months. Age ranged from 18 to 85, and studies included both men and women.

The heterogeneity of the studies was mainly related to the different number of patients, the different duration of the study, the number of procedures performed and the length of the intervals, the different ages of the participants, the severity of the disease, and whether minoxidil was used.

The outcomes of the studies were measured by TrichoScan, which is a digital software-supported epiluminescence technique for measuring hair count (number of hairs/0.65 cm<sup>2</sup>), hair density (number of hairs/cm<sup>2</sup>), hair diameter, vellus hair/terminal hair ratio, and anagen/telogen ratio.

One study included in this article evaluated the impact of dalteparin and protamine on PRP efficacy [16], nine studies compared PRP injections with saline injections as a control group [16–24], and three studies compared PRP treatment with 5% topical minoxidil treatment [25–27] (Table 1).

**Table 1.** Characteristics of the studies.

Author	Number of Patients and Gender	Outcome Measure	Treatment Protocol	Evaluation of the Effect Compared to Control Group	Age Range (years)	TrichoScan Difference in Density (%)
Takikawa et al., 2011 [16]	26 (16 men, 10 women)	Hair density, hair cross section,	5 sessions with 2–3-week intervals	Positive	28–59	1.9% (control) 13.4% (PRP) 15.8% (PRP/DP)
Shapiro et al., 2020 [17]	35 (18 men, 17 women)	Hair density	3 monthly treatment sessions with evaluation after 3 months after the final treatment	No difference between study group and control group Positive effect compared to the baseline	18–58	10.7% (control) 13.3% (PRP)
Gentile et al., 2015 [18]	20 (20 men)	Residual hair count and hair density based on computerized trichogram	3 sessions with 30-day intervals, final evaluation after 2 years	Positive	19–63	2.4% (control) 28.6% (PRP)
Cervelli et al., 2014 [19]	10 (10 men)	Hair density, anagen/telogen ratio	3 sessions with evaluation after 14 weeks, 6 months and 12 months	Positive	22–60	−1.8% (control) 14.8% (PRP)
Alves and Grimalt, 2016 [20]	22 (11 men, 11 women)	Hair density, mean anagen hairs	3 sessions with 30-day intervals	Positive	21–62	1.3% (control) 7.7% (PRP)
Gentile et al., 2018 [21]	23 (18 men, 5 women)	Hair density	3 sessions with 30-day intervals, final evaluation 3 months after the last injection	Positive	21–70	1% (control) 31% (PRP)
Dubin et al., 2020 [22]	30 (30 women)	Hair density	3 sessions, with 1-month intervals, and final evaluation after 6 months	Positive	27–85	−4.5% (control) 12.8% (PRP)

Rodrigues et al., 2019 [23]	26 (26 men)	Hair density	4 sessions, with 15-day intervals and final evaluation 3 months after the last treatment	Positive	18–50	No accurate data available
Siah et al., 2020 [24]	10 (1 man, 9 women)	Hair density	5 sessions, with 2-week intervals and final evaluation 2 months after the last intervention	Positive	20–55	1% (control) 12.8% (PRP)
Tawfik and Osman, 2018 [25]	30 (30 women)	Hair density	4 sessions, with 1-week intervals and final evaluation 6 months after the last treatment	Positive	20–45	24% (control) 104.9% (PRP)
Sultana and Paul, 2020 [26]	54 (54 men)	Hair density	3 sessions with 4 weeks intervals	Positive	18–50	13.2% (minoxidil 5%) 24% (PRP)
Pakhomova and Smirnova, 2020 [27]	69 (69 men)	Hair density	4 procedures with 1 month intervals	Positive	18–53	15.8% (minoxidil 5%) 11.7% (PRP) 32% (PRP + minoxidil 5%)
Singh et al., 2020 [28]	80 (80 men)	Hair density, patient self-assessment, photographs	3 sessions with 1 month intervals and final evaluation after 2 months	Positive	18–60	−1.2% (Control) 54.9% (PRP) 36.7% (Minoxidil 5%) 67.1% (PRP + minoxidil 5%)

PRP injections are becoming an increasingly popular alternative for conventional treatment of AGA in men and women. Its rising popularity stems from an extremely brief recovery period, safety, and good results [28]. Despite many studies, the mechanism of action and its effectiveness remain unclear. It has been proven that PRP promotes DP cell proliferation, but the intensity of proliferation did not correlate with the concentration of thrombocytes [29]. The probable mechanism of action is based on growth factors present in PRP, which induce proliferation of DP cells, activate anti-apoptotic pathways, and promote transition to anagen phase from telogen phase [4].



In this study the reliability and statistical validity of publications that met the inclusion criteria were assessed, to answer the questions related to the effectiveness and safety of PRP as an alternative therapy for AGA in men and women.

The study by Shapiro et al. revealed no significant differences between the two groups, but hair density was significantly increased in both groups at the end of the studies compared to the baseline, which may indicate a significant impact of the injections of the scalp alone. Another possible reason is a diffusion of PRP components to the control area, as the study was split-scalp, and patients acted as their own control [17].

However, other studies showed a significant difference between the study group and the control. In the study by Gentile et al., hair density in the verum group increased significantly (31%) while insignificantly (2%) in the control group. 20 participants acted as their own control and received three treatments, with a follow-up period of 2 years. Four participants showed progressive hair loss after one year and were successfully retreated [18].

The studies by Cervelli et al., Alves and Grimalt, and Gentile et al. even showed a decrease in hair density in the control group, which may be due to bleeding related to administration of the saline solution [19–21].

Ten male participants aged 22–60 were involved in the study by Cervelli et al. and received three treatments in a split-scalp fashion. A positive effect of PRP injections was observed, including an increased number of hair follicles in microscopic evaluation [19].

In the study by Alves and Grimalt, 22 participants received PRP treatment in a split-scalp fashion, with 1-month intervals and 6-month follow-ups. A significant increase in hair density was observed compared to the baseline and the control [20].

Eighteen male and five female participants aged 21–70 were involved in the split-scalp study by Gentile et al. and received three treatment sessions with a 3-month follow-up after the last treatment. The study revealed a significant difference in hair density in PRP-treated areas compared to the study areas and the baseline [21].

Dubin et al. conducted a randomized placebo-controlled study on 30 female participants. Half of them received subcutaneous PRP injections and the other half saline injections in the same fashion. The intervention included three treatment sessions with 1-month intervals and 6-month follow-up. Evaluations after 4, 8, and 24 weeks revealed a significant increase in hair density in the verum group compared to placebo and the baseline [22].

A study by Rodrigues et al. demonstrated a significant positive effect of PRP subcutaneous injections in AGA patients compared to placebo and baseline. 26 male participants were randomly assigned to the verum or placebo group and received four interventions with 15-day intervals and final evaluation three months after the last treatment. However, the positive effect did not correlate with platelet count or growth factors concentration [23].

In a study by Siah, 10 participants (nine female and one male) aged 20–55 received PRP injections in a split-scalp fashion, acting as their own control. Five interventions, with 2-week intervals and 2-month follow-up after the last treatment, resulted in a significant positive effect on hair density compared to the control and the baseline [24].

In a split-scalp study by Tawfik and Osman, 30 female participants received four PRP and saline injection sessions, with 1-week intervals, acting as their own control. The final evaluation took place six months after the last intervention. The study showed a positive result of PRP injections compared with placebo. The effect was maintained during the final evaluation [25].

In the study conducted by Takikawa et al., the impact of dalteparin and protamine microparticles (PRP&D/P) on PRP was evaluated. The study involved 26 participants aged 28–59 (16 men and 10 women). Half the patients received plain PRP injections on one side of the scalp, while saline was administrated on the placebo side, and the other half received PRP&D/P MPs instead of PRP. In PRP and PRP&D/P groups, the increase in hair density and cross-section was significantly higher than on the control side ( $p < 0.01$ ).



Placebo groups did not show any improvement compared to the baseline. The study revealed that PRP&D/P brings better results than PRP alone, but the mechanism remains unknown. Thus, further studies are needed [16].

In a study by Sultana and Paul, PRP injections were compared with topical minoxidil 5% therapy. The trial involved 54 male participants divided into two groups. One group received 3 PRP treatment sessions with 4-week intervals, and the other group was simultaneously treated with topical 5% minoxidil. The evaluation was performed after 8 and 12 weeks. The results indicate PRP therapy is significantly more effective in AGA treatment than topical minoxidil [26]. However, it is unknown to what extent this is due to the high concentration of platelets and the injection procedure itself. Therefore, to unequivocally determine which therapy brings the most beneficial effects, a study should be carried out in which the control group, in addition to minoxidil 5%, also receive saline injections.

Pakhomova and Smirnova took it a step further and, beyond the minoxidil 5% group and the PRP injection group, opened up a combination therapy group consisting of topical minoxidil 5% and PRP. The study involved 69 male participants divided into three groups. Improvement in hair condition was observed in every group. However, data suggest PRP injection therapy is more effective than minoxidil therapy, and combined therapy is more effective than any of those two treatment alternatives in monotherapy [27]. The results of their study are consistent with those achieved by Sultana and Paul [26].

In a study by Singh et al., [28], 80 patients were divided into four groups, three of which were the same as in the study by Pakhomova and Smirnova [28], while the fourth group received only saline injections. In the last group, a decrease in hair density was observed after five months. The other results were consistent with the results achieved by other researchers, as in this case it also turned out that the combination therapy brings the best effect, while the use of PRP alone is more effective than the topical application of minoxidil 5%.

As previously mentioned, the injection method itself can have a significant impact on the final effect, both in the test group and in the placebo, but due to the differences between the groups, it should be assumed that the substances present in PRP have a significant influence on the final effect.

Since some control groups experienced a significant or slight increase in hair density while others showed a decrease in hair density, it may be assumed that the injection method, including the amount of bleeding during the procedure, contributed to the variability of the results.

Most of the studies involved a half-injection of the scalp with PRP, while the other half of the scalp was injected with saline. Therefore, the influence of growth factors present in PRP on the effect observed in control areas cannot be ruled out.

#### 4. Conclusions

PRP in treatment of AGA was previously assessed in systematic reviews, many of which implied that due to heterogeneous results of clinical trials, there is not sufficient evidence on its effectiveness [29]. Due to strict inclusion criteria, the number of studies included in this systematic review was limited. In addition to the assessment of the quality of studies, excluding studies with the number of procedures below 3 and insufficient follow-up period allowed us to evaluate PRP treatment as a therapy consisting of repeated procedures. In our opinion, the inclusion criteria mentioned above are crucial for proper assessment of its effectiveness.

PRP subcutaneous scalp injections are an effective method in the treatment of AGA in men and women. All the studies included in this review revealed a positive impact in the verum group compared to the baseline.

The exact mechanism of action is still unknown and some studies suggest that the platelet count and growth factors concentration are not the crucial factors increasing hair density. Nevertheless, it may be concluded that PRP is a good alternative for patients

whose treatment with topical minoxidil did not bring the desired effect or resulted in unacceptable side effects.

**Author Contributions:** Conceptualization: J.M.B. and L.P.; methodology: J.M.B.; formal analysis: L.P. and B.D.; investigation: J.M.B.; re-sources: J.M.B., L.P.; data curation: J.M.B. and B.D.; writing—original draft preparation: J.M.B., B.D. and L.P.; writing—review and editing: J.M.B., L.P. and B.D.; supervision: L.P.; project administration: B.D.; funding acquisition: B.D. All authors have read and agreed to the published version of the manuscript.

**Funding:** This research received no external funding.

**Institutional Review Board Statement:** Not applicable.

**Informed Consent Statement:** Not applicable.

**Data Availability Statement:** Data available from the corresponding author on request.

**Conflicts of Interest:** The authors declare no conflict of interest.

# References

1. Kelly, Y.; Blanco, A.; Tosti, A. Androgenetic Alopecia: An Update of Treatment Options. *Drugs* **2016**, *76*, 1349–1364. <https://doi.org/10.1007/s40265-016-0629-5>.
2. Ho, C.H.; Sood, T.; Zito, P.M. *Androgenetic Alopecia*; StatPearls Publishing: Tampa, FL, USA, 2021.
3. Miranda, B.H.; Charlesworth, M.R.; Tobin, D.J.; Sharpe, D.T.; Randall, V.A. Androgens trigger different growth responses in genetically identical human hair follicles in organ culture that reflect their epigenetic diversity in life. *FASEB J.* **2018**, *32*, 795–806. <https://doi.org/10.1096/fj.201700260RR>.
4. Mercuri, S.R.; Paolino, G.; Di Nicola, M.R.; Vollono, L. Investigating the Safety and Efficacy of Platelet-Rich Plasma (PRP) Treatment for Female Androgenetic Alopecia: Review of the Literature. *Medicina* **2021**, *57*, 311. <https://doi.org/10.3390/medicina57040311>.
5. Adil, A.; Godwin, M. The effectiveness of treatments for androgenetic alopecia: A systematic review and meta-analysis. *J. Am. Acad. Dermatol.* **2017**, *77*, 136–141.e5. <https://doi.org/10.1016/j.jaad.2017.02.054>.
6. McElwee, K.J.; Shapiro, J.S. Promising Therapies for Treating and/or Preventing Androgenic Alopecia. *Skin Therapy Lett* **2012**, *17*, 1–4.
7. Lee, S.; Lee, Y.B.; Choe, S.J.; Lee, W.-S. Adverse Sexual Effects of Treatment with Finasteride or Dutasteride for Male Androgenetic Alopecia: A Systematic Review and Meta-analysis. *Acta Derm. Venereol.* **2019**, *99*, 12–17. <https://doi.org/10.2340/00015555-3035>.
8. Garza, L.A.; Liu, Y.; Yang, Z.; Alagesan, B.; Lawson, J.A.; Norberg, S.M.; Loy, D.E.; Zhao, T.; Blatt, H.B.; Stanton, D.C.; et al. Prostaglandin D2 inhibits hair growth and is elevated in bald scalp of men with androgenetic alopecia. *Sci. Transl. Med.* **2012**, *4*, 126ra34. <https://doi.org/10.1126/scitranslmed.3003122>.
9. Egger, A.; Tomic-Canic, M.; Tosti, A. Advances in Stem Cell-Based Therapy for Hair Loss. CellR4 Repair Replace Regen Reprogram 2020. p. 8. Available online: <https://www.ncbi.nlm.nih.gov/pubmed/32968692> (accessed on 3 April 2022).
10. Andia, I.; Abate, M. Platelet-rich plasma: Underlying biology and clinical correlates. *Regen Med.* **2013**, *8*, 645–658. <https://doi.org/10.2217/rme.13.59>.
11. Cao, Y.; Zhu, X.; Zhou, R.; He, Y.; Wu, Z.; Chen, Y. A narrative review of the research progress and clinical application of platelet-rich plasma. *Ann. Palliat. Med.* **2021**, *10*, 4823–4829. <https://doi.org/10.21037/apm-20-2223>.
12. Emer, J. Platelet-Rich Plasma (PRP): Current Applications in Dermatology. *Skin Therapy Lett.* **2019**, *24*, 1–6. Available online: <https://www.ncbi.nlm.nih.gov/pubmed/31584784> (accessed on 25 May 2022).
13. Ortega-Mejia, H.; Estrugo-Devesa, A.; Saka-Herrán, C.; Ayuso-Montero, R.; López-López, J.; Velasco-Ortega, E. Platelet-Rich Plasma in Maxillary Sinus Augmentation: Systematic Review. *Materials* **2020**, *13*, 622. <https://doi.org/10.3390/ma13030622>.
14. Paichitrojjana, A.; Paichitrojjana, A. Platelet Rich Plasma and Its Use in Hair Regrowth: A Review. *Drug Des. Devel. Ther.* **2022**, *16*, 635–645. <https://doi.org/10.2147/DDDT.S356858>.
15. Masoudi, E.; Ribas, J.; Kaushik, G.; Leijten, J.; Khademhosseini, A. Platelet-Rich Blood Derivatives for Stem Cell-Based Tissue Engineering and Regeneration. *Curr. Stem. Cell Rep.* **2016**, *2*, 33–42. <https://doi.org/10.1007/s40778-016-0034-8>.
16. Takikawa, M.; Nakamura, S.; Nakamura, S.; Ishirara, M.; Kishimoto, S.; Sasaki, K.; Yanagibayashi, S.; Azuma, R.; Yamamoto, N.; Kiyosawa, T. Enhanced effect of platelet-rich plasma containing a new carrier on hair growth. *Dermatol. Surg* **2011**, *37*, 1721–1729. <https://doi.org/10.1111/j.1524-4725.2011.02123.x>.
17. Shapiro, J.; Ho, A.; Sukhdeo, K.; Yin, L.; Sicco, K.L. Evaluation of platelet-rich plasma as a treatment for androgenetic alopecia: A randomized controlled trial. *J. Am. Acad. Dermatol.* **2020**, *83*, 1298–1303. <https://doi.org/10.1016/j.jaad.2020.07.006>.
18. Gentile, P.; Garcovich, S.; Bielli, A.; Scioli, M.G.; Orlandi, A.; Cervelli, V. The Effect of Platelet-Rich Plasma in Hair Regrowth: A Randomized Placebo-Controlled Trial. *Stem. Cells Transl. Med.* **2015**, *4*, 1317–1323. <https://doi.org/10.5966/sctm.2015-0107>.

19. Cervelli, V.; Garcovich, S.; Bielli, A.; Cervelli, G.; Curcio, B.C.; Scioli, M.G.; Orlandi, A.; Gentile, P. The effect of autologous activated platelet rich plasma (AA-PRP) injection on pattern hair loss: Clinical and histomorphometric evaluation. *Biomed. Res. Int.* **2014**, *2014*, 760709. <https://doi.org/10.1155/2014/760709>.
20. Alves, R.; Grimalt, R. Randomized Placebo-Controlled, Double-Blind, Half-Head Study to Assess the Efficacy of Platelet-Rich Plasma on the Treatment of Androgenetic Alopecia. *Dermatol. Surg.* **2016**, *42*, 491–497. <https://doi.org/10.1097/DSS.0000000000000665>.
21. Gentile, P.; Garcovich, S.; Scioli, M.G.; Bielli, A.; Orlandi, A.; Cervelli, V. Mechanical and Controlled PRP Injections in Patients Affected by Androgenetic Alopecia. *J. Vis. Exp.* **2018**, e56406. <https://doi.org/10.3791/56406>.
22. Dubin, D.P.; Lin, M.J.; Leight, H.M.; Farberg, A.S.; Torbeck, R.L.; Burton, W.B.; Khorasani, H. The effect of platelet-rich plasma on female androgenetic alopecia: A randomized controlled trial. *J. Am. Acad. Dermatol.* **2020**, *83*, 1294–1297. <https://doi.org/10.1016/j.jaad.2020.06.1021>.
23. Rodrigues, B.L.; Montalvão, S.A.; Cancela, R.B.; Silva, F.A.; Urban, A.; Huber, S.C.; Júnior, J.L.R.; Lana, J.F.S.; Annichinno-Bizzacchi, J.M. Treatment of male pattern alopecia with platelet-rich plasma: A double-blind controlled study with analysis of platelet number and growth factor levels. *J. Am. Acad. Dermatol.* **2019**, *80*, 694–700. <https://doi.org/10.1016/j.jaad.2018.09.033>.
24. Siah, T.W.; Guo, H.; Chu, T.; Santos, L.; Nakamura, H.; Leung, G.; Shapiro, J.; McElwee, K.J. Growth factor concentrations in platelet-rich plasma for androgenetic alopecia: An intra-subject, randomized, blinded, placebo-controlled, pilot study. *Exp. Dermatol.* **2020**, *29*, 334–340. <https://doi.org/10.1111/exd.14074>.
25. Tawfik, A.A.; Osman, M.A.R. The effect of autologous activated platelet-rich plasma injection on female pattern hair loss: A randomized placebo-controlled study. *J. Cosmet. Dermatol.* **2018**, *17*, 47–53. <https://doi.org/10.1111/jocd.12357>.
26. Sultana, B.; Paul, H. Efficacy and safety of platelet rich plasma therapy in male androgenetic alopecia. *J. Pak. Assoc. Dermatol.* **2020**, *3*, 375–381.
27. Pakhomova, E.E.; Smirnova, I.O. Comparative Evaluation of the Clinical Efficacy of PRP-Therapy, Minoxidil, and Their Combination with Immunohistochemical Study of the Dynamics of Cell Proliferation in the Treatment of Men with Androgenetic Alopecia. *Int. J. Mol. Sci.* **2020**, *21*, 6516. <https://doi.org/10.3390/ijms21186516>.
28. Singh, S.K.; Kumar, V.; Rai, T. Comparison of efficacy of platelet-rich plasma therapy with or without topical 5% minoxidil in male-type baldness: A randomized, double-blind placebo control trial. *Indian J. Dermatol. Venereol. Leprol.* **2020**, *86*, 150–157. [https://doi.org/10.4103/ijdv.IJDVL\\_589\\_18](https://doi.org/10.4103/ijdv.IJDVL_589_18).
29. Cruciani, M.; Masiello, F.; Pati, I.; Marano, G.; Pupella, S.; De Angelis, V. Platelet-rich plasma for the treatment of alopecia: A systematic review and meta-analysis. *Blood Transfus.* **2021**, *ahead of print*. <https://doi.org/10.2450/2021.0216-21>.

**Disclaimer/Publisher’s Note:** The statements, opinions and data contained in all publications are solely those of the individual author(s) and contributor(s) and not of MDPI and/or the editor(s). MDPI and/or the editor(s) disclaim responsibility for any injury to people or property resulting from any ideas, methods, instructions or products referred to in the content.