diseases

MDPI

Article

Pancreaticoduodenectomy for Solid Pseudopapillary Neoplasm of the Pancreatic Head in Children: A Case Series with Long-Term Follow-Up

Nhan Vu Truong [1] and Tuyen Tran [2,3,*]

[1] Faculty of Medicine, Nam Can Tho University, 168 Nguyen Van Cu Street, An Binh Ward, Can Tho City 94000, Vietnam
[2] Department of Pediatrics, Vinmec Central Park, Vinmec International Hospital, 208 Nguyen Huu Canh, Thanh My Tay Ward, Ho Chi Minh City 700000, Vietnam
[3] College of Health Sciences, VinUniversity, Hanoi 100000, Vietnam
* Correspondence: tuyentranmd.work@gmail.com; Tel.: +84-888-224-909

Abstract

Background/Objectives: Solid pseudopapillary neoplasm (SPN) of the pancreas is rare in children, and complete resection is the principal treatment. Tumors of the pancreatic head may require pancreaticoduodenectomy (PD), but pediatric PD series usually combine several histologies. We report the outcomes of PD for pancreatic-head SPN in children. **Methods:** We retrospectively reviewed five children who underwent PD for pancreatic-head SPN between 2017 and 2023 at a public tertiary pediatric hospital in Vietnam, a lower-middle-income country during the study period. Operative indication, pathology, complications (Clavien–Madadi classification), and follow-up were summarized descriptively. Seventeen children whose pancreatic-head SPN was enucleated at the same center are described to show the context of operative selection, without comparison of outcomes. **Results:** All five children were girls (median age, 12.8 years; median tumor diameter, 68 mm). All five tumors abutted the main pancreatic duct; four compressed the portal or superior mesenteric vein, and in the fifth venous compression could not be determined. PD was planned on preoperative imaging in four children and decided at operation in one, whose tumor could not be separated from the duodenum. Median operative time was 440 min and median blood loss 150 mL; one portal-vein injury occurred. All margins were microscopically negative (R0). Four children had postoperative complications: a grade B pancreatic fistula in one, delayed gastric emptying in two, and a collection requiring percutaneous drainage (Clavien–Madadi grade III) in one. There was no perioperative death, and no recurrence, metastasis, disease-related death, or small-bowel obstruction was recorded during a median follow-up of 46 months (range, 36–100). Among the 17 enucleations, the main pancreatic duct was injured in four. No PD was performed from 2024 onward (0 of 7 operations; 95% confidence interval, 0–41%). **Conclusions:** PD achieved R0 resection in all five children, with no recurrence recorded during follow-up, but four had postoperative complications. The five tumors treated by PD all abutted the main pancreatic duct, and four compressed a major vein. Most pancreatic-head tumors at our center, including very large ones, were enucleated.

Keywords: solid pseudopapillary neoplasm; pancreaticoduodenectomy; enucleation; pediatric surgery; case series; postoperative complications

Check for updates

Academic Editor: Nikos Viazis

Received: 22 October 2026
Revised: 15 November 2026
Accepted: 21 November 2026
Published: 24 November 2026

Copyright: © 2026 by the authors. Licensee MDPI, Basel, Switzerland. This article is an open access article distributed under the terms and conditions of the Creative Commons Attribution (CC BY) license.

1. Introduction

Solid pseudopapillary neoplasm (SPN) is an uncommon pancreatic tumor of low malignant potential, predominantly diagnosed in adolescent girls [1–6]. Complete resection is associated with a favorable prognosis. A meta-analysis of 701 children reported recurrence in 40 (5.7%), with a median interval to recurrence of 41 months; positive margins and larger tumors were associated with recurrence [7]. Surgery therefore aims for complete excision while limiting long-term loss of pancreatic function [8].

Enucleation and other parenchyma-preserving operations are considered when a tumor can be removed intact without compromising the main pancreatic duct or adjacent structures [8–12]. Pancreaticoduodenectomy (PD) may be needed when a limited resection cannot achieve adequate tumor clearance, but requires major reconstruction and may lead to postoperative morbidity and long-term pancreatic insufficiency [8,13–16].

Much of the pediatric evidence combines different histologies or different pancreatic operations [17,18]. A multicenter series included 65 pediatric PDs, with SPN the most common histology [13]. A recent single-center series reported 31 pancreatic resections, including seven PDs, two of them for SPN [19]. A five-case series of tailored resections for SPN, mostly in adults, included two PDs [20], and a five-patient pediatric series enucleated both pancreatic-head tumors [21]. Pediatric PD for SPN is therefore reported mainly as a few cases within broader series. We describe five children who underwent PD for pancreatic-head SPN, with their operative findings, pathology, postoperative course, and long-term follow-up. Children whose pancreatic-head tumors were enucleated at the same center are described to show how the operation was selected; their outcomes are not compared with those after PD.

2. Materials and Methods

2.1. Study Design and Participants

We conducted a retrospective single-center case series at Children's Hospital 2, a public tertiary pediatric hospital in Ho Chi Minh City that receives referrals from the southern provinces of Vietnam. We included children who underwent PD for histologically confirmed SPN of the pancreatic head or uncinate process; tumors of the pancreatic neck, body, or tail were not included. All children who underwent surgery for SPN between 2017 and May 2026 were identified from the institutional surgical database. To show the context in which PD was chosen, we also included every child in this period whose pancreatic-head SPN was enucleated. Children were grouped by the operation performed, so a child in whom PD was decided during the operation was counted in the PD group. The enucleation group is described in Section 3.5 and Appendix A; the study was not designed to compare outcomes between the two operations.

Every variable was abstracted from the source records (CT reports, operative notes, anesthesia charts, pathology reports, inpatient charts, and outpatient records) by one author and checked by the second. A finding that was looked for and absent was coded as absent; a finding that could not be assessed was coded as not assessed. Records were reviewed up to October 2026.

The operation was chosen by the operating surgeon and the surgical team after the case had been presented at the weekly departmental preoperative conference, on the basis of preoperative imaging, the appearance of the tumor at operation, and whether it could be dissected safely; tumor size alone was not a criterion. Before 2024 there was no multidisciplinary tumor board and no written criterion for choosing between PD and enucleation. From January 2024, children with pancreatic tumors were also discussed at a hepatobiliary–pancreatic team conference attended by a radiologist, and the department, having accumulated experience with enucleation, agreed to attempt enucleation first un-

der intraoperative ultrasound (IOUS) guidance, reserving PD for tumors that could not be removed completely or for ductal or duodenal injury that could not be reconstructed. The reason for each PD was taken from the conference record and the operative note and confirmed with the operating surgeon.

2.2. Variables and Definitions

For all children we collected presenting symptoms and imaging characteristics. Preoperative imaging comprised contrast-enhanced computed tomography (CT) and abdominal ultrasound; magnetic resonance imaging and magnetic resonance cholangiopancreatography were not part of the routine work-up at our center during the study period. For the five children who underwent PD, one radiologist re-read the archived CT images for tumor size and morphology, compression of the portal or superior mesenteric vein, compression of the common bile duct, main pancreatic duct (MPD) caliber, and the shortest distance between the tumor and the MPD. Each finding was recorded as present or absent as judged by the radiologist, without a predefined quantitative threshold, or as indeterminate when it could not be judged; a tumor–MPD distance of 0 mm meant that no parenchyma separated the tumor from the duct. For the enucleation group, the hospital's image-archiving software could not retrieve the stored studies reliably, and the only images available were photographs of printed films kept by the families, which were not of sufficient quality for re-reading. Imaging findings for this group were therefore taken from the original CT reports, which had been written in routine practice without uniform criteria, and a finding not mentioned in a report was coded as not reported. The relation of the tumor to the MPD in this group was taken from the operative note. Compression on imaging was not equated with tumor invasion. Operative data comprised operative time, blood loss, intraoperative events, lymph-node dissection, and final pathological margin status (R0, microscopically negative; R1, microscopically positive; Rx, not assessable).

Postoperative data included time to oral intake, drain removal, hospital stay, and complications within 90 days of surgery, graded retrospectively from the inpatient charts. Pancreatic fistula was defined and graded by the 2016 International Study Group on Pancreatic Surgery (ISGPS) definition [22,23]; a biochemical leak was not counted as a fistula. Delayed gastric emptying was graded by the ISGPS definition [24]. Overall complication severity was reported as the highest grade per patient on the pediatric Clavien–Madadi classification [25,26]. Intraoperative adverse events were graded separately with ClassIntra [27]. Events occurring later than 90 days were reported separately as late events. All patients were monitored in intensive care after PD as routine care, and this admission was not considered a complication.

R0 status was confirmed on final pathology review. Follow-up was not protocolized. Recurrence, death, and late events were taken from the outpatient records, including the results of any imaging performed during follow-up, and, when the last contact was by telephone, from the family's report. For the PD group, follow-up was recorded from surgery to the last clinical contact in whole months. For the enucleation group, follow-up was calculated from the dates of surgery and of last contact where both were recorded, and a child who could not be reached after at least two attempts was classified as lost to follow-up. Follow-up visits focused on disease status and complications: height and weight were not recorded at uniform time points, and endocrine and exocrine pancreatic function were not assessed by a uniform protocol, so growth and pancreatic function are not reported. Because travel affects follow-up in our setting, we also recorded each family's region of residence and the road distance to the hospital. No survival analysis was attempted.

2.3. Surgical Technique

PD was performed through an upper transverse laparotomy, either as a classic resection with antrectomy or as pylorus-preserving PD (PPPD), according to the relation of the tumor to the duodenum found at operation. Reconstruction used a single jejunal loop with end-to-side pancreaticojejunostomy, hepaticojejunostomy, and gastrojejunostomy or duodenojejunostomy, with two closed-suction drains.

Enucleation was performed through the same incision. After a wide Kocher maneuver and exposure of the superior mesenteric vein at the inferior border of the pancreatic neck, the parenchyma was opened where it was thinnest over the tumor, and the tumor was dissected along its pseudocapsule with bipolar or ultrasonic energy; small vessels and ductules were ligated or clipped. Before 2024, no specific measure was used to identify or protect the MPD beyond keeping the dissection on the capsule. From 2024, IOUS was used to locate the MPD and the common bile duct before dissection and to re-examine the cavity afterwards. Preoperative pancreatic duct stenting was not used. After the tumor was removed, the floor of the cavity was inspected for leakage of pancreatic juice. A small tear was sutured and drained. A larger injury, or an MPD lying exposed in the floor of the cavity, was managed by anastomosing a Roux-en-Y jejunal loop to the cavity. A closed-suction drain was left in all patients, and drain amylase was measured from postoperative day 3. Frozen section was obtained when the diagnosis was uncertain.

2.4. Analysis

Data were summarized using counts, medians, and ranges. Proportions are given with their denominators and, where shown, exact (Clopper–Pearson) 95% confidence intervals (CI); for a proportion of zero, the upper limit indicates the rate that cannot be excluded [28]. No hypothesis test was performed, and outcomes after PD and enucleation were not compared, because the operation was chosen on the basis of the anatomical findings and the groups are not comparable. Analyses were performed in R version 4.5.2 (R Foundation for Statistical Computing, Vienna, Austria). This case series is reported with reference to the PROCESS 2023 guidelines [29].

3. Results

3.1. Presentation and Imaging

Five girls underwent PD for pancreatic-head SPN (Table 1). Median age was 12.8 years (range, 8.2–14.4), and median tumor diameter was 68 mm (range, 36–90). All presented with abdominal pain; one also had jaundice and one a palpable mass. All had contrast-enhanced CT and ultrasound, and none had magnetic resonance imaging. All five tumors were mixed solid–cystic. On re-reading, the tumor compressed the superior mesenteric or portal vein without thrombosis in cases 2–5; in case 1, compression by the 90 mm tumor could not be determined (Figure 1). Biliary compression was present in two patients and absent in three. The MPD measured 2–6 mm, and all five tumors abutted it with no intervening parenchyma on CT.

Table 1. Presentation and imaging features in children undergoing PD for pancreatic-head SPN.

Case	Age (y)	Symptoms	Tumor (mm)	Morphology	Vascular/Biliary Compression	Main Duct
1	14.3	Pain	90	Mixed solid–cystic	Indeterminate/No	5 mm
2	11.9	Pain; jaundice	53	Mixed solid–cystic	Yes/Yes	4 mm

Table 1. *Cont.*

Case	Age (y)	Symptoms	Tumor (mm)	Morphology	Vascular/Biliary Compression	Main Duct
3	8.2	Pain	36	Mixed solid–cystic	Yes/No	2 mm
4	14.4	Pain; mass	75	Mixed solid–cystic	Yes/No	3 mm
5	12.8	Pain	68	Mixed solid–cystic	Yes/Yes	6 mm

Findings are from the re-reading of archived CT images; "No" means assessed and absent; "Indeterminate" means that compression could not be determined. All five tumors abutted the main pancreatic duct (tumor–duct distance, 0 mm). CT, computed tomography; PD, pancreaticoduodenectomy; SPN, solid pseudopapillary neoplasm.

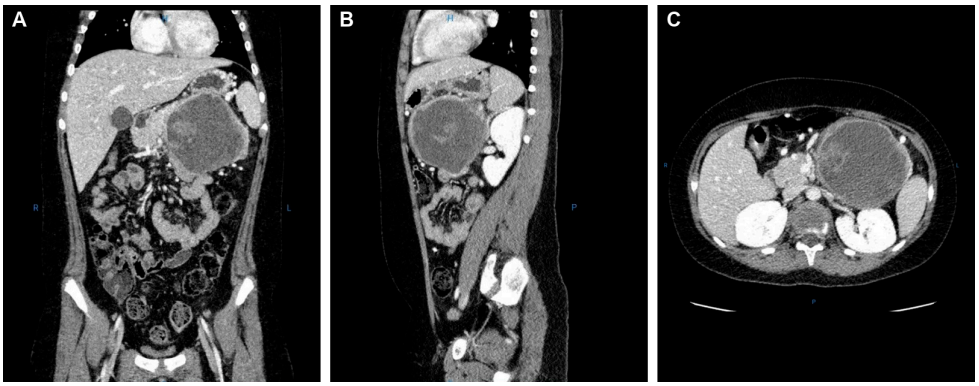

Figure 1. Case 1. Contrast-enhanced computed tomography of the 90 mm mixed solid–cystic pancreatic-head tumor. (**A**) Coronal, (**B**) sagittal, and (**C**) axial views.

3.2. Operation and Margins

All five children underwent PD: classic PD with antrectomy in four and pylorus-preserving PD (PPPD) in one (Table 2). PD was planned on preoperative imaging in four children. In case 2, the tumor caused obstructive jaundice with an 11 mm common bile duct, surrounded the intrapancreatic bile duct, and compressed the superior mesenteric vein. In case 3, the 36 mm tumor lay at the junction of the bile duct and the MPD, reached the duodenal wall, and compressed the superior mesenteric vein despite its small size. In case 4, the 75 mm tumor compressed the superior mesenteric vein. In case 5, the 68 mm tumor compressed both the superior mesenteric–portal vein and the common bile duct. In case 1 (2017), the decision was made at operation: the 90 mm tumor was densely adherent to the duodenum and could not be separated from it, and PD was performed. The type of PD followed the relation of the tumor to the duodenum at operation: the pylorus was preserved in case 1, in which it and the first part of the duodenum were free of tumor, and classic PD with antrectomy was performed in the other four, in whom the tumor was adherent to the duodenum. Case 5 had been labeled "Whipple (DPPD)" in the operative register; the operative note describes a classic PD with antrectomy, and it is classified as such. The operations were performed largely by one fixed surgical team. Median operative time was 440 min (range, 180–780) and median blood loss was 150 mL (range, 40–800). One portal-vein injury (ClassIntra grade III) occurred in the patient with the greatest blood loss (800 mL; case 1; Figure 2) and was repaired by suture. Lymph-node dissection was recorded in four cases, and no tumor rupture was documented. All five resections had microscopically negative (R0) margins. Histology of case 1 is shown in Figure 3.

Table 2. Operative characteristics and pathological margins.

Case	Procedure	Time (min)	Blood Loss (mL)	Lymph-Node Dissection	Intraoperative Event	Margin
1	PPPD	540	800	Yes	Portal vein injury	R0
2	Whipple	355	40	Yes	None documented	R0
3	Whipple	180	50	Yes	None documented	R0
4	Whipple	440	150	Yes	None documented	R0
5	Whipple	780	200	No	None documented	R0

PD, pancreaticoduodenectomy; PPPD, pylorus-preserving PD. Median operative time 440 min (range 180–780); median blood loss 150 mL (range 40–800). Whipple, classic PD with antrectomy. Procedures were verified against the operative notes.

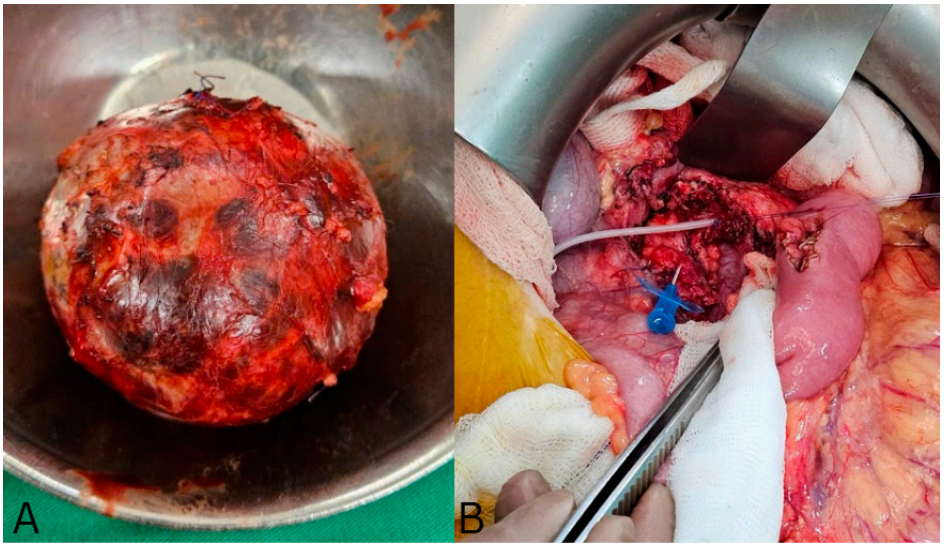

Figure 2. Case 1, pylorus-preserving pancreaticoduodenectomy. (**A**) Resected tumor. (**B**) Operative field after tumor resection.

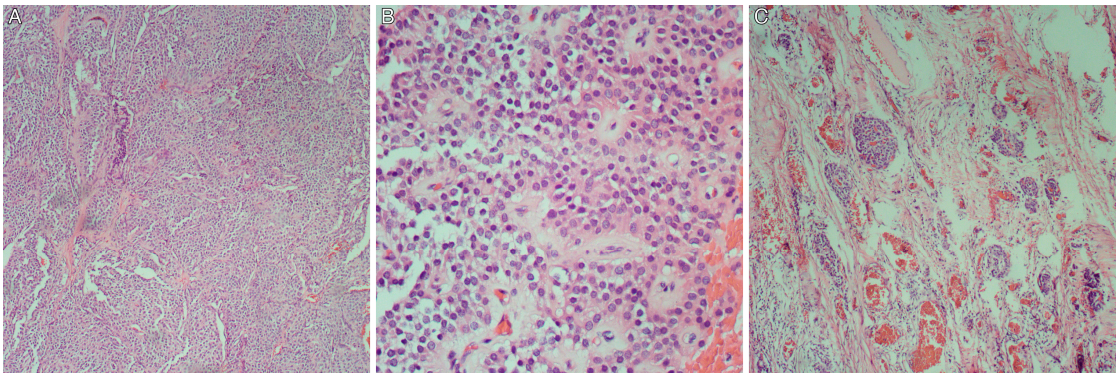

Figure 3. Case 1, histopathology (hematoxylin and eosin). (**A**) Solid sheets of uniform tumor cells separated by delicate fibrovascular septa (×10). (**B**) Uniform tumor cells at higher magnification (×40). (**C**) Tumor cell nests infiltrating peritumoral fibrovascular tissue (×10).

3.3. Postoperative Course

Median time to oral intake was 7 days (range, 4–10), and median postoperative stay was 14 days (range, 12–28). Drain removal dates were available for four children (median, 14.5 days; range, 6–18). Four children had at least one recorded postoperative complication (Table 3). Case 2 had a pancreatic fistula, with drain amylase more than three times the upper limit of normal from day 3 and an infected intra-abdominal collection treated with antibiotics (ISGPS grade B), together with grade A delayed gastric emptying, a chyle leak, and pneumonia (Clavien–Madadi grade II). Case 5 developed pancreatitis, an intra-abdominal collection, surgical-site infection, and pneumonia, and required percutaneous catheter drainage of the collection (grade III); the drain fluid met only the criteria for a biochemical leak, the records did not establish that the collection was of pancreatic origin, and it was not graded as a pancreatic fistula. Case 4 had a surgical-site infection (grade II), and case 1 had grade A delayed gastric emptying (Clavien–Madadi grade I); in the two children with delayed gastric emptying, oral intake resumed on days 7 and 10. No perioperative death was recorded.

Table 3. Patient-level postoperative morbidity and follow-up.

Case	Oral/Drain/Stay (Days)	Recorded Postoperative Events (Clavien–Madadi Grade)	Follow-Up (Months)
1	10/15/20	Delayed gastric emptying, ISGPS grade A (I)	100; no recurrence
2	7/18/28	Pancreatic fistula (ISGPS grade B) with infected intra-abdominal collection; delayed gastric emptying (grade A); chyle leak; pneumonia (II)	51; no recurrence
3	4/6/12	No complication recorded	36; no recurrence
4	4/NR/14	Surgical-site infection (II)	46; no recurrence
5	7/14/14	Postoperative pancreatitis; intra-abdominal collection; surgical-site infection; fever; pneumonia; percutaneous catheter drainage (III)	43; no recurrence

ISGPS, International Study Group on Pancreatic Surgery; NR, not recorded. The grade in parentheses is the highest Clavien–Madadi grade for the child. Intensive care monitoring was routine and was not counted as a complication. Follow-up was rounded to whole months.

3.4. Follow-Up

Median follow-up was 46 months (range, 36–100; Table 3). No recurrence, metastasis, or disease-related death was documented in the available records. No small-bowel obstruction was recorded. Case 5 was admitted once for cholangitis 20 months after surgery and was treated conservatively. Three of the five families lived outside Ho Chi Minh City, up to 350 km away.

3.5. Pancreatic-Head SPN Treated by Enucleation

Between 2017 and May 2026, 34 children, all younger than 15 years at operation, underwent surgery for SPN, 22 of them for tumors of the pancreatic head or uncinate process. Of these 22, five underwent PD and 17 enucleation (Table 4; patient-level data in Appendix A, Table A1). The 17 children (15 girls) had a median age of 12.2 years (range, 7.4–14.1). Fourteen presented with abdominal pain, six with nausea or vomiting, and one with jaundice; in three the tumor was an incidental finding. Tumor morphology was recorded for 16 children: solid in six, cystic in two, and mixed solid–cystic in eight. Tumor size overlapped between the groups: median 68 mm (range, 36–90) for PD and 56 mm (range, 30–151) for enucleation. Eight enucleated tumors measured 68 mm or more, and four were larger than any tumor treated by PD. All 17 had contrast-enhanced CT, 16 also had

ultrasound, and none had magnetic resonance imaging. In the original CT reports, venous compression was described in one of the 11 children whose venous status was reported (110 mm tumor), biliary compression in one of 11, and MPD dilatation in four of 13; these findings were not reported for the remaining children. The operative note described the tumor as abutting or adherent to the MPD in nine and did not describe this relation in eight. All PDs were performed between 2017 and 2023, when five of 15 operations for pancreatic-head SPN were PDs (33%; 95% CI, 12–62). From 2024 onward, all seven children underwent enucleation (PD, 0 of 7; 95% CI, 0–41), including the child with reported venous compression (110 mm tumor) and five whose tumor was described as abutting the MPD. This period followed the departmental agreement described in Section 2.1, reached after the team had accumulated experience with enucleation, and coincided with the introduction of IOUS.

IOUS was used in all seven enucleations from 2024 and in none before. The MPD was injured in four of 17 enucleations (24%; 95% CI, 7–50): in two of 10 before 2024 and in two of seven with IOUS. All four injuries occurred among the nine tumors that the operative note described as abutting the MPD; none occurred among the eight for which no such relation was described. Three injuries were managed by Roux-en-Y drainage of the cavity and one 1 mm tear by suture and drainage; in these four children, oral intake resumed on days 2–5 and drains were removed on days 6–10, and one had a postoperative infection. Two further children had a Roux-en-Y loop anastomosed to the cavity because the intact MPD lay exposed in its floor. Other intraoperative events were duodenal injury in two children (sutured), common bile duct injury in one (repaired over a T-tube), and tumor rupture in one. In all, seven children had an intraoperative adverse event (ClassIntra grade II in three and grade III in four). Median operative time was 185 min (range, 70–305; recorded in 16) and median blood loss 50 mL (range, 10–400; recorded in 15). Margins were R0 in 13, R1 in three, and not assessable after tumor rupture in one.

After enucleation, median time to oral intake was 3 days (range, 1–17), drains were removed after a median of 6.5 days (range, 5–21; recorded in 16), and median postoperative stay was 11 days (range, 4–38). Within 90 days, the events recorded among the 17 children, two of whom were lost to follow-up before day 90, were an ISGPS grade B pancreatic fistula in one (6%), postoperative pancreatitis in three (18%), and a postoperative infection in one (6%). A bile leak followed the bile duct injury, and one child required hepaticojejunostomy for a biliary stricture on day 41 (Clavien–Madadi grade III). There was no death.

Twelve of the 17 children lived outside Ho Chi Minh City (median road distance to the hospital, 75 km; range, 9–520). Two children, living 230 and 520 km away, were lost to follow-up within three months of surgery, before the end of the 90-day window. The other 15 remained under follow-up; their last contact was a clinic visit in ten and a telephone call with the family in five. The date of last contact was recorded for 11 children, including the two lost to follow-up, and median follow-up in these 11 was 24.1 months (range, 2.0–102.0). Among the 15, one late event was recorded, a pancreatic pseudocyst treated by cystojejunostomy four months after surgery, and no recurrence or small-bowel obstruction was recorded. Of the three children with R1 margins, two had been followed for 24 and 4 months, and the date of last contact was not recorded for the third. These data are descriptive, and the two groups were not compared.

Table 4. Characteristics, operative findings, and outcomes of children with pancreatic-head SPN treated by PD or enucleation.

Characteristic	PD (n = 5)	Enucleation (n = 17)
Age at surgery, years	12.8 (8.2–14.4)	12.2 (7.4–14.1)
Girls	5/5	15/17
Tumor diameter, mm	68 (36–90)	56 (30–151)
Venous compression (PD: CT re-read; enucleation: CT report)	4/5 (1 indeterminate)	1/11 (not reported in 6)
Biliary compression (as above)	2/5	1/11 (not reported in 6)
Tumor documented as abutting the MPD (PD: CT re-read; enucleation: operative note)	5/5	9/17 (not described in 8)
Intraoperative ultrasound	0/5	7/17
Operative time, minutes	440 (180–780)	185 (70–305), n = 16
Blood loss, mL	150 (40–800)	50 (10–400), n = 15
MPD injury	Not applicable	4/17
Any intraoperative adverse event (ClassIntra ≥ I)	1/5	7/17
R0 margin	5/5	13/17 (R1 in 3, Rx in 1)
Clavien–Madadi grade ≥ III	1/5	1/17
Pancreatic fistula, ISGPS grade B or C	1/5	1/17
Postoperative pancreatitis	1/5	3/17
Time to oral intake, days	7 (4–10)	3 (1–17)
Drain removal, days	14.5 (6–18), n = 4	6.5 (5–21), n = 16
Postoperative stay, days	14 (12–28)	11 (4–38)
Residence outside Ho Chi Minh City	3/5	12/17
Road distance to hospital, km	50 (8–350)	75 (9–520)
Follow-up, months	46 (36–100)	24.1 (2.0–102.0), n = 11
Last contact by telephone	0/5	5/17
Lost to follow-up	0/5	2/17
Late event (after 90 days)	1/5 (cholangitis)	1/15 (pseudocyst, cystojejunostomy)
Recurrence recorded	0/5	0/15 (2 lost to follow-up)
Small-bowel obstruction recorded	0/5	0/15

Values are median (range) or number/denominator. For the enucleation group, imaging denominators are the children whose CT report stated the finding; events within 90 days are those recorded among all 17 children, two of whom were lost to follow-up before day 90; late outcomes refer to the other 15, who remained under follow-up; and n is given for continuous values not recorded in every child. Follow-up after PD was recorded in whole months; after enucleation it is given for the 11 children with a dated last contact. CT, computed tomography; MPD, main pancreatic duct; ISGPS, International Study Group on Pancreatic Surgery; Rx, margin not assessable. Archived CT images could not be retrieved for the enucleation group; findings not mentioned in a report are shown as not reported. The groups are shown side by side for description only; they differ in selection, period of surgery, and follow-up, and no statistical comparison was made. IOUS, intraoperative ultrasound; PD, pancreaticoduodenectomy; SPN, solid pseudopapillary neoplasm.

4. Discussion

PD achieved R0 resection in all five children with pancreatic-head SPN, and no recurrence was recorded during 36–100 months of follow-up. Four children had postoperative complications, one requiring an invasive intervention. PD was uncommon at our center: most pancreatic-head tumors, including very large ones, were enucleated.

4.1. Oncological and Functional Outcomes

The reported median time to recurrence in pediatric SPN is 41 months [7]. Four of our patients were followed beyond this point, but follow-up ranged from 36 to 100 months, later recurrences remain possible, and the absence of recurrence in five children is compatible with a recurrence proportion as high as 52% (upper 95% confidence limit for 0 of 5). Long-term pancreatic insufficiency is a further concern after PD: it was reported in 32% of a multicenter PD cohort that included other histologies [13], and functional impairment after childhood PD has been described [14–16]. Our data do not address these outcomes (Section 4.5). No small-bowel obstruction was recorded, and the only late event recorded was one episode of cholangitis, treated conservatively.

4.2. Perioperative Morbidity

In three of the four children with complications, the most severe event was Clavien–Madadi grade I or II. The multicenter pediatric PD study reported pancreatic leak in 14%, delayed gastric emptying in 9%, and one death within 30 days [13]. In a five-case series of tailored SPN resections, mostly in adults, no grade B or C pancreatic fistula or complication of Clavien–Dindo grade III or higher occurred [20]. Our series is too small for a meaningful comparison, and complication definitions and tumor histologies differ between studies. Intraoperative events were graded separately from postoperative complications [27]; the single portal-vein injury occurred in the earliest PD, for the largest tumor.

4.3. PD Within the Management of Pancreatic-Head SPN

Pediatric expert recommendations favor parenchyma-preserving surgery when the tumor can be removed intact with negative margins while preserving critical anatomy [8]. A recent five-patient pediatric series treated both pancreatic-head tumors by enucleation [21]. In a single-center Vietnamese series of 32 children with SPN, however, enucleation of pancreatic-head tumors raised fistula and margin concerns, and one local recurrence after R1 enucleation was treated with PD [30]. In our five children the reason for PD was anatomical and was identified in every case. In four, PD was chosen on imaging because the tumor compressed a major vein, with biliary compression in two of them and a periampullary position in one; in the fifth, the tumor was found at operation to be inseparable from the duodenum. Tumor diameter did not separate the two operations: many enucleated tumors were as large as or larger than those treated by PD, and the smallest PD tumor measured 36 mm.

Proximity to the MPD did not clearly separate the operations either, although it was assessed differently in the two groups: all five PD tumors abutted the duct on CT, whereas the operative notes described nine enucleated tumors as abutting it and gave no description for the other eight. In adults, a tumor within 2 mm of the MPD has been associated with pancreatic fistula after enucleation [31], and a shorter tumor–duct distance predicted fistula in a recent series [32], although a larger series found no such association [33]. In our enucleation group, all four MPD injuries occurred in tumors that the operative note described as abutting the duct, both before and after the introduction of IOUS; with 17 patients and a relation recorded by the surgeon, this observation is hypothesis-generating only. A multicenter adult cohort of benign and low-grade pancreatic-head tumors found

more clinically relevant fistulas but fewer major complications and less new-onset diabetes after enucleation than after PD [34]. We are not aware of comparable pediatric data, and our study was not designed to provide them.

No PD has been performed at our center from 2024 onward. The operation was still chosen case by case, and the change coincided with a departmental agreement to attempt enucleation first, reached as the team accumulated experience, and with the introduction of IOUS. The period, however, includes only seven operations: a true PD rate as high as 41% is compatible with observing none, and venous compression, which had led to PD earlier, was reported in only one of these seven children and was not reported in three. No single factor therefore explains the change, and we do not interpret it as evidence that PD is no longer needed.

4.4. Resource Context

Vietnam was classified by the World Bank as a lower-middle-income country throughout the period in which these children were operated on and was reclassified as upper-middle-income in July 2026 [35]. Outcomes of pancreatic surgery in low- and middle-income countries are reported infrequently: a meta-analysis of surgery for pancreatic cancer in these countries, a population different from children with SPN, identified 114 studies, of which 51 were of good quality, with pooled rates of pancreatic fistula of 16.6% and postoperative mortality of 4.4% [36]. Pediatric data from such settings are scarcer still.

Several features of our setting shaped both the care and the data. Magnetic resonance cholangiopancreatography, which shows the relation between tumor and duct better than CT, was not part of the routine work-up; IOUS became available only in 2024; and there was no multidisciplinary tumor board until that year. The image archive could not retrieve the studies of the enucleation group reliably, and the printed films kept by families were not adequate for re-reading, so imaging of this group could not be re-examined. Most families lived outside Ho Chi Minh City, some more than 300 km away. In pediatric oncology in low- and middle-income countries, distance and travel are recognized risk factors for abandonment of treatment [37]. In our series, the two children lost to follow-up lived 230 and 520 km from the hospital, and the last contact with five others was by telephone.

These conditions bear on the choice between PD and enucleation. Where follow-up, enzyme supply, and diabetes care depend on the family's resources, loss of pancreatic parenchyma may carry a greater long-term cost than in high-income settings, although we did not measure this in our cohort. Enucleation of a tumor close to the duct, on the other hand, carries a risk of duct injury and reconstruction, as our enucleation series shows. Our data cannot settle this balance. They do suggest that reports from similar settings should record access to imaging, follow-up, and enzyme replacement alongside surgical outcomes.

4.5. Limitations

This series is small, retrospective, and descriptive, and confidence intervals are wide throughout. The reasons for PD were reconstructed from conference records and operative notes and confirmed by the operating surgeons, which may be subject to hindsight; and no written selection criteria existed before 2024. Imaging was limited to ultrasound and CT. Archived images were re-read by a single radiologist, without predefined quantitative thresholds, for the PD group only, and venous compression could not be determined in one child. For the enucleation group, findings come from routine CT reports written without uniform criteria, venous and biliary status was not reported in six of 17 children, and the tumor–duct relation was taken from operative notes, recorded by the surgeon and possibly

influenced by the course of the operation. Compression on imaging does not establish invasion. Complications were graded retrospectively from the records, so some grades, particularly of delayed gastric emptying, may be imprecise, and the origin of the collection drained in PD case 5 could not be established. Follow-up was not protocolized. Recurrence and late events were taken from outpatient records and, for the five enucleation patients last contacted by telephone, from the family's report; follow-up after PD was recorded in whole months; and the date of last contact was available for 11 of the 17 enucleation patients, so their median follow-up rests on these 11. Two enucleation patients were lost to follow-up before day 90, so complications after their discharge may have gone unrecorded, and follow-up of the three children with R1 margins was short or undated. Pancreatic function, growth, and quality of life were not assessed systematically. Some values were missing: one drain-removal date after PD and, after enucleation, operative time, blood loss, or drain removal in one or two children. The two groups differ in selection, period of surgery, and follow-up, so outcomes after the two operations cannot be compared. Larger multicenter series should record prospectively why PD is chosen over enucleation and report long-term pancreatic function and growth.

5. Conclusions

Pancreaticoduodenectomy achieved R0 resection in all five children with pancreatic-head SPN, with no recurrence recorded during 36–100 months of follow-up, although four experienced postoperative complications. At our center, most pancreatic-head tumors, including some larger than those treated by PD, were enucleated.

Author Contributions: N.V.T.: Conceptualization; clinical data collection; data validation; interpretation of clinical findings; critical manuscript revision. T.T.: Conceptualization; study methodology; formal analysis; original manuscript drafting; critical manuscript revision. All authors have read and agreed to the published version of the manuscript.

Funding: This research received no external funding.

Institutional Review Board Statement: The study was conducted in accordance with the Declaration of Helsinki and approved by the Ethics Committee of Children's Hospital 2, Ho Chi Minh City, Vietnam (approval no. 64/GCN-BVNĐ2, 19 May 2026).

Informed Consent Statement: Written informed consent for participation and for publication of the clinical details was obtained from the parents or legal guardians of the five children who underwent PD. For the children who underwent enucleation, only de-identified data are reported, and the ethics committee waived individual consent for this retrospective review of records.

Data Availability Statement: Patient-level data for the five PD cases are contained in the article tables, and de-identified patient-level data for the enucleation group are given in Appendix A. The underlying clinical records are not publicly available because of patient confidentiality; requests for additional de-identified data may be considered by the corresponding author subject to institutional and ethics approval.

Acknowledgments: We thank the Department of General Surgery, the Department of Diagnostic Imaging, and the Department of Pathology of Children's Hospital 2 for their contribution to the care and diagnosis of these patients. During the preparation of this manuscript, the authors used Claude Sonnet 5.5 (Anthropic) for language editing. The authors have reviewed and edited the output and take full responsibility for the content of this publication.

Conflicts of Interest: The authors declare no conflicts of interest.

Abbreviations

The following abbreviations are used in this manuscript:

CI	confidence interval
CT	computed tomography
IOUS	intraoperative ultrasound
ISGPS	International Study Group on Pancreatic Surgery
MPD	main pancreatic duct
PD	pancreaticoduodenectomy
PPPD	pylorus-preserving pancreaticoduodenectomy
SPN	solid pseudopapillary neoplasm

Appendix A

Table A1. Patient-level data for the 17 children with pancreatic-head SPN treated by enucleation.

Case	Year	Age (y)/Sex	Tumor (mm)	Venous/Biliary Compression (CT Report)	Abutting MPD (Operative Note)	IOUS	Procedure	Intraoperative Event (ClassIntra)	Margin
E1	2017	10.5/F	30	No/No	Not described	No	EN	None	R0
E2	2020	12.6/F	40	No/No	Not described	No	EN	None	R0
E3	2022	11.8/F	85	NR/NR	Yes	No	EN	Duodenal injury; tumor rupture (II)	Rx
E4	2022	7.4/F	83	No/No	Not described	No	EN	Duodenal injury (II)	R0
E5	2023	13.5/F	50	NR/NR	Yes	No	EN + RY	MPD injury (III)	R0
E6	2023	13.9/F	151	NR/NR	Yes	No	EN + RY	MPD injury (III)	R1
E7	2023	9.8/M	56	No/No	Not described	No	EN	None	R0
E8	2023	9.1/F	43	No/No	Not described	No	EN	None	R0
E9	2023	7.9/F	37	No/No	Not described	No	EN	None	R0
E10	2023	12.9/F	94	No/No	Yes	No	EN	Bile duct injury (III)	R0
E11	2024	12.2/F	36	NR/NR	Yes	Yes	EN + RY	MPD injury (III)	R1
E12	2024	11.5/F	35	NR/NR	Yes	Yes	EN	MPD tear 1 mm, sutured (II)	R0
E13	2025	14.1/F	94	No/No	Yes	Yes	EN + RY (prophylactic)	None	R0
E14	2025	10.6/M	33	No/No	Not described	Yes	EN	None	R0
E15	2025	12.4/F	90	NR/NR	Not described	Yes	EN	None	R0
E16	2026	13.0/F	110	Yes/No	Yes	Yes	EN	None	R1
E17	2026	12.7/F	83	No/Yes	Yes	Yes	EN + RY (prophylactic)	None	R0

EN, enucleation; RY, Roux-en-Y jejunal loop anastomosed to the enucleation cavity (prophylactic: main pancreatic duct exposed but intact); MPD, main pancreatic duct; IOUS, intraoperative ultrasound; Rx, margin not assessable; NR, not reported in the original CT report (archived images could not be retrieved). All children had contrast-enhanced CT; all but E15 also had ultrasound. The ClassIntra grade in parentheses is the highest for the child. Postoperative complications and follow-up are summarized for the group in Section 3.5 and Table 4.

References

1. Mylonas, K.S.; Doulamis, I.P.; Tsilimigras, D.I.; Nasioudis, D.; Schizas, D.; Masiakos, P.T.; Kelleher, C.M. Solid pseudopapillary and malignant pancreatic tumors in childhood: A systematic review and evidence quality assessment. *Pediatr. Blood Cancer* **2018**, *65*, e27114. [CrossRef]
2. Bender, A.M.; Thompson, E.D.; Hackam, D.J.; Cameron, J.L.; Rhee, D.S. Solid Pseudopapillary Neoplasm of the Pancreas in a Young Pediatric Patient: A Case Report and Systematic Review of the Literature. *Pancreas* **2018**, *47*, 1364–1368. [CrossRef]
3. Choi, S.H.; Kim, S.M.; Oh, J.T.; Park, J.Y.; Seo, J.M.; Lee, S.K. Solid pseudopapillary tumor of the pancreas: A multicenter study of 23 pediatric cases. *J. Pediatr. Surg.* **2006**, *41*, 1992–1995. [CrossRef]
4. Speer, A.L.; Barthel, E.R.; Patel, M.M.; Grikscheit, T.C. Solid pseudopapillary tumor of the pancreas: A single-institution 20-year series of pediatric patients. *J. Pediatr. Surg.* **2012**, *47*, 1217–1222. [CrossRef]
5. Leraas, H.J.; Kim, J.; Sun, Z.; Ezekian, B.; Gulack, B.C.; Reed, C.R.; Tracy, E.T. Solid Pseudopapillary Neoplasm of the Pancreas in Children and Adults: A National Study of 369 Patients. *J. Pediatr. Hematol. Oncol.* **2018**, *40*, e233–e236. [CrossRef]
6. Jentzsch, C.; Fuchs, J.; Agaimy, A.; Vokuhl, C.; Escherich, G.; Blattmann, C.; Warmann, S.W.; Schmidt, A.; Schäfer, J.; Brecht, I.B.; et al. Solid pseudopapillary neoplasms of the pancreas in childhood and adolescence—An analysis of the German Registry for Rare Pediatric Tumors (STEP). *Eur. J. Pediatr.* **2023**, *182*, 5341–5352. [CrossRef]
7. Balfour, J.; Braungart, S. Outcomes in Paediatric Solid Pseudopapillary Neoplasms of the Pancreas: A Systematic Review and Meta-analysis. *Ann. Surg.* **2025**, *Online ahead of print*. [CrossRef]
8. Irtan, S.; Abele, M.; Virgone, C.; Kuhlen, M.; Lopez-Almarez, R.; Ben-Ami, T.; Bien, E.; Cesen, M.; Krawczyk, M.A.; Ferrari, A.; et al. Solid Pseudopapillary Neoplasm of the Pancreas in Children and Adolescents: Expert Recommendations. *Pediatr. Blood Cancer* **2026**, *73*, e70546. [CrossRef]
9. Cho, Y.J.; Namgoong, J.-M.; Kim, D.Y.; Kim, S.C.; Kwon, H.H. Suggested Indications for Enucleation of Solid Pseudopapillary Neoplasms in Pediatric Patients. *Front. Pediatr.* **2019**, *7*, 125. [CrossRef]
10. Wang, X.; Chen, Y.-H.; Tan, C.-L.; Zhang, H.; Xiong, J.-J.; Chen, H.-Y.; Ke, N.-W.; Liu, X.-B. Enucleation of pancreatic solid pseudopapillary neoplasm: Short-term and long-term outcomes from a 7-year large single-center experience. *Eur. J. Surg. Oncol.* **2018**, *44*, 644–650. [CrossRef]
11. Li, Y.-Q.; Pan, S.-B.; Yan, S.-S.; Jin, Z.-D.; Huang, H.-J.; Sun, L.-Q. Impact of parenchyma-preserving surgical methods on treating patients with solid pseudopapillary neoplasms: A retrospective study with a large sample size. *World J. Gastrointest. Surg.* **2022**, *14*, 174–184. [CrossRef]
12. Kawakubo, N.; Takemoto, J.; Irie, K.; Souzaki, R.; Maniwa, J.; Obata, S.; Yoshimaru, K.; Nagata, K.; Miyata, J.; Matsuura, T.; et al. Surgical outcome and prognosis of pediatric solid-pseudopapillary neoplasm. *Pediatr. Int.* **2023**, *65*, e15666. [CrossRef]
13. Vasudevan, S.A.; Ha, T.-A.N.; Zhu, H.; Heaton, T.E.; LaQuaglia, M.P.; Murphy, J.T.; Barry, W.E.; Goodhue, C.; Kim, E.S.; Aldrink, J.H.; et al. Pancreaticoduodenectomy for the treatment of pancreatic neoplasms in children: A Pediatric Surgical Oncology Research Collaborative study. *Pediatr. Blood Cancer* **2020**, *67*, e28425. [CrossRef]
14. Lindholm, E.B.; Alkattan, A.K.; Abramson, S.J.; Price, A.P.; Heaton, T.E.; Balachandran, V.P.; La Quaglia, M.P. Pancreaticoduodenectomy for pediatric and adolescent pancreatic malignancy: A single-center retrospective analysis. *J. Pediatr. Surg.* **2017**, *52*, 299–303. [CrossRef]
15. Park, H.-H.; Kim, H.-Y.; Jung, S.-E.; Lee, S.-C.; Park, K.-W. Long-term functional outcomes of PPPD in children—Nutritional status, pancreatic function, GI function and QOL. *J. Pediatr. Surg.* **2016**, *51*, 398–402. [CrossRef]
16. Mizuno, S.; Okuda, Y.; Gyoten, K.; Koide, T.; Suzaki, M. Long-term functional outcomes after pylorus preserving pancreaticoduodenectomy from childhood through middle age: 30-year follow-up of nutritional status, pancreatic function, and morphological changes of the pancreatic remnant. *J. Pediatr. Surg.* **2018**, *53*, 1263–1264. [CrossRef]
17. Kakos, C.D.; Ziogas, I.A.; Kokkinakis, S.; Khomiak, A.; Moris, D.; Marantos, A.; Dionysis, T.T.; Schulick, R.D.; Del Chiaro, M.; Roach, J.P. Systematic Review and Pooled Analysis of 1021 Children with Pancreatic Tumors. *J. Surg. Res.* **2026**, *325*, 363–374. [CrossRef]
18. Cheng, H.; Yang, S.; Ren, Q.; Yang, W.; Han, W.; Chang, X.; Zhu, Z.; Qin, H.; Wang, H. Pancreatectomies for pediatric pancreatic tumors: A single institute experience from 2007 to 2018. *J. Pediatr. Surg.* **2020**, *55*, 1722–1726. [CrossRef]
19. Rozhkova, V.; Burlaka, A.; Kvasivka, O.; Lisnyy, I.; Beznosenko, A.; Kopchak, K.; Cheverdiuk, D.; Lukashenko, A. Pediatric pancreatectomy for neoplasms: Indications, outcomes, and implementation of minimally invasive surgery in a Ukrainian tertiary center. *BMC Pediatr.* **2025**, *25*, 441. [CrossRef]
20. Pontrelli, A.; Di Meo, G.; Prete, F.P.; Panzera, P.; De Luca, G.M.; Calomino, N.; Mita, M.T.; De Simone, B.; Bisceglie, M.; Miccoli, M.M.; et al. Tailored Surgical Treatment and Outcomes in Solid Pseudopapillary Neoplasms of the Pancreas: A Case Series of Five Consecutive Paradigmatic Cases. *Diseases* **2026**, *14*, 180. [CrossRef]
21. Zhao, Z.; Xi, H.-W. Solid pseudopapillary neoplasm of the pancreas in children. *World J. Surg. Oncol.* **2026**. [CrossRef]

22. Bassi, C.; Marchegiani, G.; Dervenis, C.; Sarr, M.; Hilal, M.A.; Adham, M.; Allen, P.; Andersson, R.; Asbun, H.J.; Besselink, M.G.; et al. The 2016 update of the International Study Group (ISGPS) definition and grading of postoperative pancreatic fistula: 11 Years After. *Surgery* **2017**, *161*, 584–591. [CrossRef]
23. Bassi, C.; Marchegiani, G.; Dervenis, C.; Sarr, M.; Abu Hilal, M.; Adham, M.; Allen, P.; Andersson, R.; Asbun, H.J.; Besselink, M.G.; et al. Corrigendum to "The 2016 update of the International Study Group (ISGPF) definition and grading of postoperative pancreatic fistula: Eleven years after". *Surgery* **2024**, *176*, 988–989. [CrossRef]
24. Wente, M.N.; Bassi, C.; Dervenis, C.; Fingerhut, A.; Gouma, D.J.; Izbicki, J.R.; Neoptolemos, J.P.; Padbury, R.T.; Sarr, M.G.; Traverso, L.W.; et al. Delayed gastric emptying (DGE) after pancreatic surgery: A suggested definition by the International Study Group of Pancreatic Surgery (ISGPS). *Surgery* **2007**, *142*, 761–768. [CrossRef]
25. Madadi-Sanjani, O.; Kuebler, J.F.; Brendel, J.; Wiesner, S.; Mutanen, A.; Eaton, S.; Domenghino, A.; Clavien, P.-A.; Ure, B.M. Implementation and validation of a novel instrument for the grading of unexpected events in paediatric surgery: Clavien–Madadi classification. *Br. J. Surg.* **2023**, *110*, 576–583. [CrossRef]
26. Dindo, D.; Demartines, N.; Clavien, P.-A. Classification of Surgical Complications: A new proposal with evaluation in a cohort of 6336 patients and results of a survey. *Ann. Surg.* **2004**, *240*, 205–213. [CrossRef]
27. Dell-Kuster, S.; Gomes, N.V.; Gawria, L.; Aghlmandi, S.; Aduse-Poku, M.; Bissett, I.; Blanc, C.; Brandt, C.; ten Broek, R.B.; Bruppacher, H.R.; et al. Prospective validation of classification of intraoperative adverse events (ClassIntra): International, multicentre cohort study. *BMJ* **2020**, *370*, m2917. [CrossRef]
28. Hanley, J.A.; Lippman-Hand, A. If nothing goes wrong, is everything all right? Interpreting zero numerators. *JAMA* **1983**, *249*, 1743–1745. [CrossRef]
29. Mathew, G.; Sohrabi, C.; Franchi, T.; Nicola, M.; Kerwan, A.; Agha, R.; PROCESS Group. Preferred Reporting of Case Series in Surgery (PROCESS) 2023 guidelines. *Int. J. Surg.* **2023**, *109*, 3760–3769. [CrossRef]
30. Vu, H.M.; Pham, H.D.; Nguyen, S.C.; Bui, N.Y.; Nguyen, H.V.; Nguyen, N.L.K.; Nguyen, Q.T. Surgical and functional outcomes of pediatric pancreatic solid pseudopapillary neoplasm: A retrospective study. *PLoS ONE* **2026**, *21*, e0357019. [CrossRef]
31. Brient, C.; Regenet, N.; Sulpice, L.; Brunaud, L.; Mucci-Hennekine, S.; Carrère, N.; Milin, J.; Ayav, A.; Pradere, B.; Hamy, A.; et al. Risk factors for postoperative pancreatic fistulization subsequent to enucleation. *J. Gastrointest. Surg.* **2012**, *16*, 1883–1887. [CrossRef]
32. Madeka, I.; Yi, S.; Evans, J.; Baek, D.; Naringrekar, H.V.; Lavu, H.; Yeo, C.J.; Nevler, A.; Bowne, W.B. Clinicopathologic risk factors for post-operative complications after enucleation of pancreatic neoplasms. *World J. Surg. Oncol.* **2025**, *23*, 293. [CrossRef]
33. Strobel, O.; Cherrez, A.; Hinz, U.; Mayer, P.; Kaiser, J.; Fritz, S.; Schneider, L.; Klauss, M.; Büchler, M.W.; Hackert, T. Risk of pancreatic fistula after enucleation of pancreatic tumours. *Br. J. Surg.* **2015**, *102*, 1258–1266. [CrossRef]
34. Yao, Z.; Gao, Y.; Wang, W.; Lin, C.; Ma, K.; Jia, W.; Xiao, C.; Yin, Y.; Zhao, Z.; Liu, Q.; et al. Enucleation vs Pancreatoduodenectomy for Benign and Low-Grade Pancreatic Head Tumors. *JAMA Surg.* **2026**, *161*, 1210–1218. [CrossRef]
35. Metreau, E.; Young, K.E.; Eapen, S.G. Who Moves up and Why? A Closer Look at the 2026–2027 Release of the World Bank Group Country Income Classifications. *World Bank Data Blog*, 1 July 2026. Available online: https://blogs.worldbank.org/en/opendata/who-moves-up-and-why–a-closer-look-at-the-new-world-bank-group- (accessed on 12 November 2026).
36. Khan, M.A.; Sherwani, M.; Ahmed, K.S.; Ali, M.; Kumar, P.A.; Tariq, J.; Christensen, L.; Bogale, N.; Schwartz, P.B.; Zafar, S.N. Morbidity and Mortality Following Surgery for Pancreatic Cancer in Low- and Middle-Income Countries: A Systematic Review and Meta-Analysis. *J. Surg. Oncol.* **2025**, *131*, 435–442. [CrossRef]
37. Palagyi, A.; Balane, C.; Shanthosh, J.; Jun, M.; Bhoo-Pathy, N.; Gadsden, T.; Canfell, K.; Jan, S. Treatment abandonment in children with cancer: Does a sex difference exist? A systematic review and meta-analysis of evidence from low- and middle-income countries. *Int. J. Cancer* **2021**, *148*, 895–904. [CrossRef]

Disclaimer/Publisher's Note: The statements, opinions and data contained in all publications are solely those of the individual author(s) and contributor(s) and not of MDPI and/or the editor(s). MDPI and/or the editor(s) disclaim responsibility for any injury to people or property resulting from any ideas, methods, instructions or products referred to in the content.