diseases

MDPI

Review

Carbon Dioxide Gas Embolism in Minimally Invasive Liver Surgery: A Scoping Review of Incidence, Mechanisms, and Risk Determinants

Salvatore Spiezia [1,2,*], Paolo Bianco [1,2], Giovanni Andrea Garella [3], Gennaro Quarto [4], Agostino Fernicola [4], Francesco Stanzione [5], Germano Guerra [1], Graziano Ceccarelli [6,7], Aldo Rocca [1,2,†] and Pasquale Avella [1,2,4,*,†]

[1] Department of Medicine and Health Science "V. Tiberio", University of Molise, 86100 Campobasso, Italy
[2] Hepatobiliary and Pancreatic Surgery Unit, Pineta Grande Hospital, 81030 Castel Volturno, Italy
[3] Department of Periodontics, Case Western Reserve University, Cleveland, OH 44106, USA
[4] Department of Clinical Medicine and Surgery, University of Naples "Federico II", 80131 Naples, Italy
[5] General Surgery Unit, Pineta Grande Hospital, 81030 Castel Volturno, Italy
[6] Division of General and Minimally Invasive Surgery, Department of Surgery, San Giovanni Battista Hospital, 06034 Foligno, Italy
[7] Minimally Invasive and Robotic Surgery Unit, San Matteo Hospital, 06049 Spoleto, Italy
* Correspondence: salvatorespiezia00@gmail.com (S.S.); avella.p@libero.it (P.A.)
† These authors contributed equally to this work.

Abstract

Purpose: Minimally invasive liver surgery combines carbon dioxide pneumoperitoneum with deliberately lowered central venous pressure, a combination that drives gas into veins opened during transection. We aimed to map the incidence, mechanisms, and determinants of gas embolism during laparoscopic and robotic hepatectomy and to propose a flow-chart of immediate actions for its management. **Methods:** This PRISMA-ScR-compliant scoping review, registered on the Open Science Framework, searched PubMed/MEDLINE, Scopus, and the Cochrane Library for English-language studies published up to July 2026 (search completed on 5 September 2026); the methodological quality of included studies was appraised according to study design. **Results:** Twenty-one studies were included (822 patients, 228 of whom experienced at least one embolic event). Because detection depended on study design and monitoring, frequencies were not pooled. Under systematic transoesophageal echocardiography (two randomised trials, 190 patients), embolism was detected in 180 patients (94.7%) and was severe in 108 (56.8%), but it was rarely clinically significant. Among studies employing clinical surveillance only (three retrospective series, 615 patients in total), clinically apparent embolism was reported in 31 patients, corresponding to an incidence of 5.0%. An exposed hepatic vein was the proposed source in about 80% of studies. In an exploratory, descriptive comparison, morbidity occurred in 60% of patients with documented paradoxical systemic passage, including 3 cerebral infarctions, and in 0.5% in which no gas passage was documented. No embolism-related death occurred. **Conclusions:** Gas embolism is frequently detected when actively sought, whereas clinically significant events are uncommon. Its determinants appear predominantly intraoperative and potentially modifiable; reduced pneumoperitoneum pressure is the only preventive measure tested in a dedicated randomised trial. Although laparoscopic and robotic hepatectomy have been compared extensively, no comparative study has specifically assessed the risk of gas embolism between the two approaches.

Academic Editor: Veysel Tahan

Received: 3 October 2026
Revised: 13 November 2026
Accepted: 18 November 2026
Published: 23 November 2026

Copyright: © 2026 by the authors. Licensee MDPI, Basel, Switzerland. This article is an open access article distributed under the terms and conditions of the Creative Commons Attribution (CC BY) license.

Keywords: minimally invasive liver surgery; carbon dioxide embolism; gas embolism; paradoxical embolism; laparoscopic liver resection; robotic liver resection; hepatectomy

1. Introduction

The use of Minimally Invasive Liver Surgery (MILS) has expanded substantially over the last decades [1–3]. Laparoscopic Liver Resection (LLR) improves short-term outcomes compared with open surgery [4], while Robotic Liver Resection (RLR) has rapidly disseminated across specialised centres since its introduction [5]. This growth has been supported by consensus meetings and evidence-based guidelines aimed at ensuring safe implementation: Louisville in 2008 [6], Morioka in 2015 [7], the first European LLR guidelines in Southampton in 2017 [8], and, more recently, the internationally validated Brescia guidelines [2] and the Paris consensus on robotic hepato-pancreato-biliary (HPB) surgery [9]. Although the two approaches share broadly similar indications, differences in instrumentation, techniques, and training justify platform-specific recommendations [10]. Both minimally invasive approaches are now used for major hepatectomies and for deep, central, or posteriorly located lesions [11–15].

Parenchymal transection routinely approaches the major hepatic veins, the hepatocaval junction, and the retrohepatic inferior vena cava—territory in which a single division can open the lumen of a high-flow vein draining directly into the caval system [16]. If venous pressure falls below that of the carbon dioxide (CO_2) pneumoperitoneum, gas enters the open vein and passes into the circulation, causing anything from silent microbubbles to cardiovascular collapse and paradoxical systemic embolism [17,18]. The clinical consequence of paradoxical embolism is most severe when it manifests as ischaemic stroke: a right-to-left shunt, such as a patent foramen ovale, provides a direct route for venous emboli to reach the cerebral circulation [19], and the early recognition of acute ischaemic stroke remains challenging, particularly in anaesthetised patients, prompting the search for novel diagnostic markers [20].

In general laparoscopy, gas embolism is rare, with an incidence below 0.5% [21–24] although mortality approaches 30% once events become clinically significant [25]. In LLR, symptomatic embolism affects approximately 5% of patients [26], and Trans-Esophageal Echocardiography (TEE) detects severe events in 40% to 65% [27]. This increased risk reflects the combination of hepatic venous exposure, positive intra-abdominal pressure, and deliberately reduced central venous pressure (CVP), which limits blood loss but widens the pressure gradient favouring gas entry [18].

We performed a scoping review on gas embolism during LLR and RLR, evaluating its incidence, clinical spectrum, and pathophysiology; the patient-, anesthesia-, and procedure-related determinants of risk; and the strategies available for prevention, early recognition, and management.

2. Materials and Methods

2.1. Study Design and Search Strategy

This literature review includes articles published up to July 2026 and was conducted and reported in accordance with the Preferred Reporting Items for Systematic Reviews and Meta-Analyses extension for Scoping Reviews (PRISMA-ScR) guidelines [28]. The protocol for this scoping review was registered with the Open Science Framework [29] (DOI: 10.17605/OSF.IO/6Y2TC, registered on 13 August 2026); the completed checklist is provided in Supplementary Materials Table S1. The literature search was completed on 5

September 2026; the protocol was therefore registered before completion of the search and before study selection and data extraction.

A comprehensive search of PubMed/MEDLINE, Scopus, and the Cochrane Library was conducted to identify original English-language papers reporting gas or CO_2 embolism during LLR and RLR. Studies were retrieved in PubMed using the following medical subject headings (MeSH) and free-text terms: ("Embolism, Air" OR "gas embolism" OR "carbon dioxide embolism") AND ("Hepatectomy" OR hepatectomy OR "liver resection" OR "minimally invasive liver surgery") AND ("Laparoscopy" OR "Robotic Surgical Procedures" OR laparoscop* OR robot*).

The strategy was adapted to the requirements of Scopus, where the equivalent query was TITLE-ABS-KEY (("gas embolism" OR "CO2 embolism" OR "carbon dioxide embolism") AND (hepatectomy OR "liver resection") AND (laparoscop* OR robot*)).

In the Cochrane Library (Cochrane Central Register of Controlled Trials and Cochrane Database of Systematic Reviews), the following strategy was used: (gas NEXT embolism OR CO2 NEXT embolism OR carbon NEXT dioxide NEXT embolism OR air NEXT embolism) AND (hepatectomy OR liver NEXT resection OR hepatic NEXT resection OR liver NEXT surgery) AND (laparoscop* OR robot* OR minimally NEXT invasive). The three complementary sources were selected to combine the biomedical coverage of MEDLINE, the broader multidisciplinary and conference-indexed coverage of Scopus, and the trial-focused content of the Cochrane Library.

The search was further expanded by systematically screening the reference lists of all retrieved texts. The search strategy was discussed and approved by all authors.

Titles and abstracts were screened independently by two authors (S.S. and P.A.) using Rayyan (Rayyan Systems Inc., Cambridge, MA, USA; web-based version, accessed July–September 2026) [30], after removal of duplicates. The agreement between the two reviewers at the title and abstract stage was 95%; disagreements were first discussed between them and, when consensus was not reached, were resolved by a third author (A.R.). All records were exported to EndNote (EndNote™ 21, Clarivate, Philadelphia, PA, USA), and duplicates were managed according to the method of Bramer et al. [31]. The final review of the articles was carried out in September 2026.

2.2. Inclusion Criteria

The main study objectives were formulated according to the Patients, Intervention, Comparison, Outcomes and Study Design (PICOS) method [32] (Table 1). English-language, human, full-text studies were included only if gas or CO_2 embolism occurring during LLR or RLR was explicitly described in sufficient clinical, haemodynamic, or echocardiographic detail to characterise the event.

Table 1. Patients, intervention, comparison, outcomes, and study design method used to screen experiences in the literature. Abbreviations: CO_2, carbon dioxide; RCT, Randomized Clinical Trials.

Population	Intervention	Comparator	Outcomes	Study Design
Adult patients who underwent laparoscopic or robotic liver surgery of any extent, for benign or malignant disease, including living liver donors	Minimally invasive hepatectomy performed under CO_2 pneumoperitoneum	Different pneumoperitoneum pressures, insufflation systems, anaesthetic techniques, or surgical platforms (laparoscopic, robotic, or open); a comparator was not required for inclusion	Occurrence, detection method, severity, mechanism, management, and clinical consequences of gas or CO_2 embolism	RCT, controlled cohort studies, case series, and case reports which met inclusion criteria

Comparative studies, case series, and case reports meeting these criteria were included. All resection extents were eligible, and both benign and malignant indications were collected (hepatocellular carcinoma, intrahepatic cholangiocarcinoma, colorectal and other liver metastases, haemangioma, focal nodular hyperplasia, hepatic cysts, hydatid disease, hepatolithiasis, and living-donor hepatectomy).

2.3. Exclusion Criteria

Studies involving animal experiments, articles published in languages other than English, conference abstracts, editorials, expert opinions, and review papers were excluded. Reports were also excluded if the full text was unobtainable, if gas embolism was not a reported outcome or was mentioned without extractable detail, if they concerned non-hepatic surgery, or if they reported open hepatectomy only; studies including open procedures were retained when they permitted comparison with a minimally invasive cohort.

Patients◎sample size, age, pneumoperitoneum pressure, and resection extent do not represent exclusion criteria.

2.4. Definitions and Classification Frameworks

Resection extent was classified according to the Brisbane 2000 terminology (minor resection <3 Couinaud segments, major ≥3 segments) [33]. Because this dichotomy does not capture technical difficulty, a third category was added, and a hierarchical rule was applied so that each resection was assigned to a single category:

(1) resections of three or more segments were classified as major, irrespective of their location;
(2) resections of fewer than three segments were classified as complex when they involved segment 1, 4a, 7, or 8;
(3) all remaining resections of fewer than three segments were classified as minor.

Accordingly, a right anterior sectionectomy (segments 5 and 8) was classified as complex, whereas a right hepatectomy (segments 5, 6, 7, and 8) was classified as major.

Furthermore, we also evaluated dissection immediately adjacent to the major hepatic veins or inferior vena cava, corresponding to the advanced and expert grades according to IWATE criteria [34] or grade III according to Kawaguchi classification [35], and to the expert-level indications of the Southampton Consensus [8]. Where authors did not report segmental anatomy in sufficient detail, extent and complexity were recorded as not classifiable rather than inferred.

Severity of embolism, where graded, was classified according to TEE microbubble scale [17,27,36]. In order to homogenize gas embolism severity, we stratified data according to Schmandra et al. [17]as reported in Table 2.

Table 2. Transoesophageal echocardiographic grading of venous gas embolism according to the Schmandra classification [17], as operationalised in the two randomised controlled trials included in this review (Luo et al. [27]and Hong et al. [36]). Abbreviations: RA, right atrium; RV, right ventricle; RVOT, right ventricular outflow tract.

Transoesophageal Echocardiographic Appearance in RA, RV, or RVOT	Stage According to Schmandra et al. [17]	Grade According to Luo et al. [27]	Grade According to Hong et al. [36]
No bubbles observed	Stage 0	Grade 0	Grade 1
A single gas bubble	Stage I	Grade 1	Grade 2
Gas bubbles filling <50% of chamber diameter	Stage II	Grade 2	Grade 3
Gas bubbles filling >50% of chamber diameter (severe)	Stage III	Grade 3	Grade 4
Gas bubbles filling the entire chamber diameter (severe)	Stage IV	Grade 4	Grade 5

Where the original authors did not report a formal grade, two reviewers (P.A. and S.S.) assigned the stage post hoc from the echocardiographic findings described in the report, by consensus; where such findings were not described, severity was recorded as not classifiable and characterised descriptively.

Paradoxical gas embolism is the passage of gas from the venous to the systemic arterial circulation through a right-to-left shunt, such as an atrial septal defect, ventricular septal defect, or patent foramen ovale; cerebral involvement is rare but may be fatal [37].

2.5. Data Extraction and Endpoints

Reports were divided into three distinct groups, namely irrelevant, relevant, and unsure. Studies determined to be irrelevant by both reviewers were excluded, while papers judged relevant or unsure by at least one reviewer were analysed through full-text evaluation using the Rayyan platform [30]. Disagreements on article selection were resolved by discussion and consensus among the authors. A PRISMA flow chart documents the entire search and selection process (Figure 1).

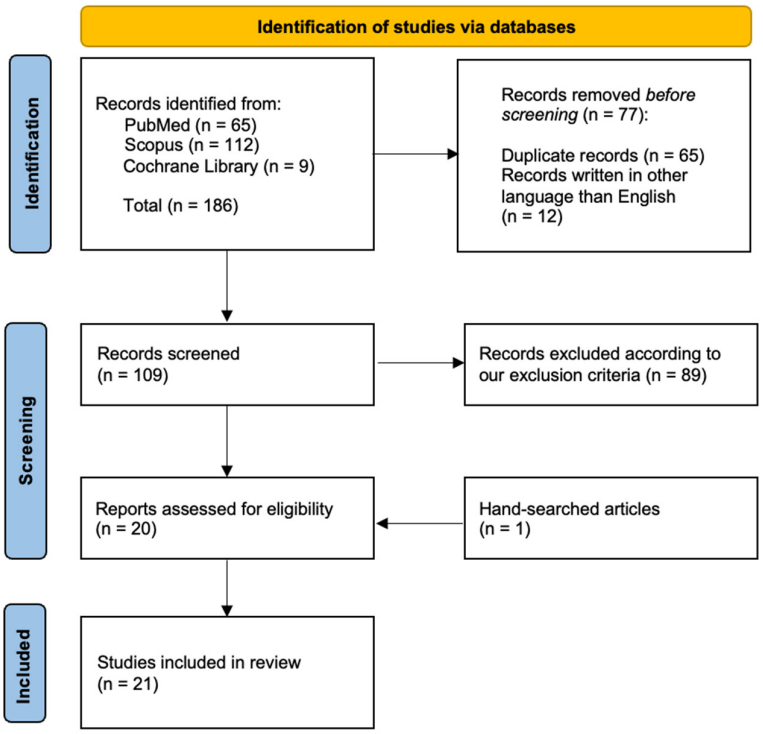

Figure 1. PRISMA Flowchart of our literature analysis.

Data were extracted independently by two reviewers (S.S. and P.A.) using a standardised data extraction form, which had been piloted on a subset of included studies and refined before full extraction. Discrepancies were resolved by consensus, with arbitration by a third author (A.R.) when required. The following items were recorded for each of the 21 studies forming the evidentiary core (Table 3): the first author, year of publication, study design, country, total number of patients, number of patients with gas embolism, type of surgery (laparoscopic, robotic, or open), insufflation pressure and insufflation system where reported, liver disease, resection extent and technical complexity, the severity of gas embolism, the embolic route, method of detection, clinical and radiological findings, management of the embolic event, proposed mechanism of gas entry, and morbidity and mortality.

Embolism was classified as clinically significant when it caused haemodynamic, respiratory, or neurological compromise prompting intervention, or embolism-related sequelae. These criteria were operationalised as follows: haemodynamic compromise (H), hypotension, arrhythmia or electrocardiographic changes, or cardiovascular collapse prompting vasopressor or inotropic support, fluid loading, cardiopulmonary resuscitation, interruption of the pneumoperitoneum, or conversion; respiratory compromise (R), desaturation, hypercapnia with acidosis, or an abrupt capnographic change prompting an increase in the inspired oxygen fraction, positive end-expiratory pressure, ventilatory adjustment, or interruption of the pneumoperitoneum; and embolism-related sequelae (S), any neurological, respiratory, or cardiovascular sequela persisting beyond the intraoperative event. Because neurological compromise cannot be reliably assessed in anaesthetised patients, it was captured as postoperative neurological sequelae. Echocardiographic or capnographic findings alone, without such compromise or sequelae, were not considered sufficient. The two reviewers (S.S. and P.A.) applied these criteria by consensus to the intraoperative findings and management described in each report (Supplementary Materials Table S2), and the criteria fulfilled are reported for each study in a dedicated column of Table 4. Because all included studies reported embolism per patient, each patient was counted once regardless of the number of embolic episodes. Discrepancies in the extracted data were resolved by consensus among the authors.

Pneumoperitoneum pressure was recorded as the working pressure in use immediately before the embolic event, rather than the pressure adopted after the event as part of the resuscitative response or the institutional protocol subsequently introduced. Where a study reported both, the pre-event value was extracted and the change recorded separately under management. In the case of missing information, aggregate figures were recomputed from the individual studies.

The primary endpoint was to characterise the incidence and clinical spectrum of gas embolism during MILS.

Secondary endpoints addressed the pathophysiological mechanisms and diagnostic approaches reported, together with the patient-, procedure-, and anaesthesia-related determinants of risk and their distribution across the perioperative timeline. A further endpoint was to establish whether the available evidence permits a comparison of embolic risk between the laparoscopic and robotic approaches.

2.6. Methodological Quality Assessment

The methodological quality of the included studies was appraised independently by two reviewers (S.S. and P.A.), using the tool appropriate to each study design. Randomised controlled trials and cohort studies were assessed with the corresponding methodology checklists of the Scottish Intercollegiate Guidelines Network (SIGN-50) [38], rated as high quality (++), acceptable (+), low quality (−), or unacceptable (0), and assigned a level of evidence from 1++ to 2−. Case reports and case series were assessed with the Joanna Briggs Institute (JBI) Critical Appraisal Checklists for Case Reports (8 items) [39]and for Case Series (10 items) [40], respectively; each item was answered as yes, no, unclear, or not applicable, and, according to SIGN-50, these non-analytic studies correspond to level 3 evidence. For descriptive purposes, case reports fulfilling at least seven of the eight items were considered of high reporting quality, those fulfilling five–six items of moderate quality, and those fulfilling four or fewer of low quality. Disagreements were resolved by consensus. Since critical appraisal is optional in scoping reviews, the appraisal was used to qualify the strength of the evidence underlying each finding and not as a criterion for exclusion; the results are reported in Supplementary Materials Table S3 (SIGN-50) and Table S4 (JBI).

2.7. Statistical Analysis

No meta-analytic pooling was undertaken, and no pooled incidence was estimated. Data are reported descriptively as counts and percentages, with the patient experiencing at least one embolic event as the unit of analysis, and are presented separately according to study design and monitoring technique. Outcomes of patients with and without documented paradoxical systemic passage are described descriptively. No inferential testing was performed, because the unit of analysis is the published case rather than a probability sample of patients. Descriptive analyses were performed with Stata (version 19; StataCorp LLC, College Station, TX, USA).

2.8. Ethical Considerations

Ethical approval and informed consent were not required, as this review is based solely on previously published studies and involves no direct contact with individual subjects.

3. Results

3.1. Literature Review

A total of 186 articles were initially obtained, 65 from PubMed, 112 from Scopus and 9 from Cochrane library, (Figure 1). Twenty-one articles were finally selected [26,27,36,37,41–57]: 16 case reports, 3 retrospective studies (one single-centre, one multicentre, and one comparative cohort), and 2 Randomized Clinical Trials (RCTs). The cumulative study population encompassed 822 patients (Table 3), 228 of whom experienced at least 1 embolic event of any severity; this crude descriptive proportion (27.7%) combines heterogeneous designs and detection methods and should not be interpreted as an estimate of incidence. Whether embolism was clinically significant is reported separately for each study in Table 4.

According to SIGN-50, the randomised trial of Luo et al. [27]was rated as acceptable quality (level 1+) and that of Hong et al. [36]as level 1−, whereas the retrospective cohorts of Hadji et al. [26]and Sambommatsu et al. [56]were both rated 2−. The case series of Qu et al. [51]was of low quality (JBI 3/10), mainly because gas embolism was identified on clinical grounds without predefined criteria or echocardiographic monitoring. Of the 16 case reports, 14 fulfilled at least seven of the eight JBI items and two fulfilled six items [44,47]; however, gas embolism was documented by echocardiography in only eight of them [37,41,45,46,48–50,57], was directly visualised or aspirated in two [44,52], and was diagnosed on clinical, capnographic, or blood-gas grounds alone in the remaining six [42,43,47,53–55] (Supplementary Materials Tables S3 and S4). Accordingly, most findings of this review rest on non-analytic evidence (SIGN level 3).

The underlying pathologies are listed in Table 3.

Table 3. Characteristics of the included studies. Abbreviations: Sg, Segment; HCC, Hepatocellular Carcinoma; RCT, Randomized Clinical Trial; FNH, Focal Nodular Hyperplasia; iCCA, Intrahepatic Cholangiocarcinoma; CRLM, ColoRectal Liver Metastases; GE, gas embolism; NC, not classifiable; n, number.

Author	Year	Design	Country	N. of Patients	N. of Patients with GE	Indication	Surgical Approach	Resected Segments (Major, Minor, Complex)
Min et al. [41]	2007	Case report	South Korea	1	1	Hepatolithiasis	Laparoscopic	Sg2 and 3 (Minor)
Kawahara et al. [37]	2017	Case report	Japan	1	1	HCC	Laparoscopic	Sg7 (Complex)

Hong et al. [36]	2017	RCT	China	49	49	Hepatolithiasis, Haemangioma, Carcinoma, FNH	Laparoscopic	Major resection (n = 22) *; Minor resection (n = 27) *
De Cassai et al. [42]	2019	Case report	Italy	1	1	HCC	Laparoscopic	Sg8 (Complex)
Kobayashi et al. [43]	2019	Case report	Japan	1	1	HCC	Laparoscopic	Partial hepatectomy *
Takechi et al. [44]	2020	Case report	Japan	1	1	iCCA	Laparoscopic	Sg5-6-7-8 (Major)
Zhang et al. [45]	2020	Case report	China	1	1	Carcinoma	Laparoscopic	Sg5 and 8 (Complex)
Hou et al. [46]	2020	Case report	China	1	1	CRLM	Laparoscopic	Sg2 and 3 (Minor)
Yang et al. [47]	2022	Case report	China	1	1	HCC	Laparoscopic	NC
Kim et al. [48]	2022	Case report	South Korea	1	1	HCC	Laparoscopic	Sg6 and 7 (Complex)
Jeon et al. [49]	2022	Case report	South Korea	1	1	HCC	Laparoscopic	Sg2-3-4 (Major)
Kennedy et al. [50]	2023	Case report	Canada	1	1	iCCA	Laparoscopic	NC
Qu et al. [51]	2023	Retrospective study	China	60	4	HCC (n= 31); Hepatolithiasis (n = 21); FNH (n = 3); Liver metastatic carcinoma (n = 3); Hepatoblastoma (n = 1); Inflammatory pseudotumor of the liver (n = 1)	Laparoscopic	Minor (n = 15); Major (n = 30); Complex (n = 15)
Wu et al. [52]	2023	Case report	China	1	1	Liver hydatid cyst	Laparoscopic	Sg5-6-7-8 (Major)
Shimizu et al. [53]	2023	Case report	Japan	1	1	CRLM	Laparoscopic	Partial Sg7 (Complex)
Luo et al. [27]	2024	RCT	China	141	131	HCC (n = 75); Haemangioma (n = 23); Liver metastases (n = 19); FNH (n = 15); iCCA (n = 6); Hepatic cysts (n = 3)	Laparoscopic	Minor (n = 132) *; Major (n = 9) *;
Li et al. [54]	2024	Case report	China	1	1	Primary liver carcinoma	Laparoscopic	NC
Nakaji et al. [55]	2024	Case report	Japan	1	1	HCC	Laparoscopic	Partial Sg8 (Complex)
Sambommatsu et al. [56]	2025	Retrospective cohort	USA	37	1	Healthy living liver donors	Robotic	Sg5-6-7-8 (Major)
Hadji et al. [26]	2025	Multicentre retrospective study	France	518	26	Benign tumours (n = 53); iCCA (n = 34); HCC (n = 140); Liver metastases (n = 181); Others (n = 110)	Laparoscopic	Major (n = 142) *
Saito et al. [57]	2025	Case reports	Japan	2	2	HCC	Laparoscopic	Partial Sg8 and Sg7 (Complex)

* Segmental anatomy was not reported for individual patients; cohort-level extent as reported by the original authors and not attributable to the embolic events.

The robotic experience was reported only by Sambommatsu et al. [56].

3.2. Proposed Mechanisms of Gas Embolism

In 17 of 21 (81.0%) studies the proposed source was an exposed or injured hepatic vein, venous branch, or sinusoid, usually during deep parenchymal transection [26,27,36,37,41–47,51–54,56,57]. Three studies (14.3%) reported another source: portal vein rupture [48], an inferior vena cava tear [49], and injury to an abdominal wall collateral at port insertion [50]; the site was unspecified in one (4.8%) [55].

Gas entry was uniformly attributed to the pressure gradient between the CO_2 pneumoperitoneum and the venous system, widened by low CVP (Supplementary Materials Table S2). Contributing factors were the Pringle manoeuvre [27,44], higher insufflation pressure [27,45,49,51,52], previous abdominal surgery [36,52], and cirrhosis [36,43]. One study implicated argon-beam coagulation, which delivers a poorly soluble gas mixture [41].

Insufflation pressure was reported in 19 of 21 (90.5%) studies (Table 4) and was most commonly set at 12 mmHg. Only one randomised trial directly compared insufflation pressures: in this double-blind trial comparing 10 with 15 mmHg, low-pressure pneumoperitoneum significantly reduced the incidence and duration of severe embolism [27]. The second randomised trial compared sevoflurane with propofol anaesthesia at a fixed pressure and therefore informs anaesthetic management rather than pressure-related prevention [36]. Nevertheless, clinically significant and catastrophic events occurred also at ≤12 mmHg.

Three (14.3%) studies attributed the occurrence of gas embolism to the use of a valveless high-flow insufflation device (AirSeal) as the probable underlying mechanism [26,53,57].

Systemic passage was proposed to occur by two routes: an interatrial communication, either a patent foramen ovale [48,53] or an iatrogenic septal defect after catheter ablation [55,57], or transpulmonary passage where no shunt was demonstrated [37,41,43,45,46,49]. Where gas remained in the right heart, compromise was attributed to outflow-tract obstruction [36,50].

3.3. Gas Embolism Detection

The reported frequency of gas embolism varied widely across the included studies, largely in relation to the method of intraoperative detection employed. Under systematic TEE, gas was near-ubiquitous: Hong et al. [36]detected it in all 49 patients, almost all clinically silent, with a single haemodynamically significant event (2.0%), while Luo et al. [27] reported severe embolism (grade ≥3) in 76 of 141 (53.9%) patients.

Where detection rested on clinical and haemodynamic recognition, incidence was far lower: 26 of 518 (5.0%) in the multicentre series of Hadji et al. [26] and four of 60 (6.7%) in the Qu et al. study [51]. Subclinical venous CO_2 embolism is therefore a near-constant accompaniment of parenchymal transection under pneumoperitoneum, whereas clinically relevant events converge around 5%.

When the evidence is stratified by study design and monitoring technique, three distinct strata emerge. In the two RCTs employing systematic TEE (190 patients), embolism was detected in 180 patients (94.7%), and was severe (Schmandra stage ≥III) in 108 (56.8%) of all patients [27,36]; nevertheless, clinically significant events were uncommon. Hong et al. reported a single patient with haemodynamic instability [36], whereas Luo et al. reported haemodynamic and respiratory changes only at group level, together with one postoperative cerebral infarction, so that the number of patients with clinically significant embolism in this trial could not be determined [27]. In the three retrospective studies relying on clinical recognition (615 patients), clinically recognised

embolism occurred in 31 patients (5.0%) [26,51,56]. The 16 case reports and case series contributed 17 patients, all with clinically significant events, reflecting the selection inherent in this design. These strata answer different questions and were therefore not combined (Table 4).

The classical semiology was variable: a rapid end-tidal CO_2 fall was present in only about 50% of the cases, whereas a paradoxical rise or an unchanged capnographic trace accounted for the remainder. A widened arterial-to-end-tidal CO_2 gradient on blood-gas analysis was the most consistent bedside adjunct (Supplementary Materials Table S2). The mill-wheel murmur was audible in only three (1.3%) cases [45,49,52].

Echocardiography was diagnostic when used. Furthermore, in one case [46] echocardiography detected intracardiac gas before any vital-sign change, and in another it identified a patent foramen ovale opened under a right-sided gas load [48].

Individual resection data were available for 18 of the 228 (7.9%) patients with gas embolism, namely the 17 patients described in case reports and the single robotic case [56]. Complex resections accounted for eight of these 18 (44.4%) events [37,42,45,48,53,55,57], major resections for four (22.2%) [44,49,52,56], and minor resections for two (11.1%) [41,46]; in the remaining four (22.2%) the segmental anatomy was not reported in sufficient detail to permit classification [43,47,50,54] (Table 3). Among the 14 classifiable patients, complex, major, and minor resections therefore accounted for eight (57.1%), four (28.6%), and two (14.3%) events, respectively. Because the number of resections of each category performed without embolism was not available, these figures describe the distribution of reported events and cannot be used to estimate category-specific risk.

3.4. Management and Outcomes

The detailed adopted management strategies are reported in Supplementary Materials Table S2.

The most frequent strategy was represented by immediate cessation of insufflation (frequently sufficient in itself), an inspired oxygen fraction of 100% with positive end-expiratory pressure, haemodynamic and postural support, and definitive control of the venous breach. Catheter aspiration of gas was attempted with inconstant yield [42,46,52,55], and hyperbaric oxygen was reserved for selected patients with established systemic gas [26].

Conversion to open surgery attributable to the embolic event (including conversions performed to shorten the operation in response to the embolism) was reported in eight of the 228 patients with gas embolism (3.5%). Three conversions reported by Luo et al. [27] were performed for bleeding.

Embolism confined to the right heart followed an essentially benign course [26,36,42,44,47,50–52,54,56], although one (0.5%) patient without documented paradoxical passage suffered permanent neurological injury [27] (Figure 2A,B).

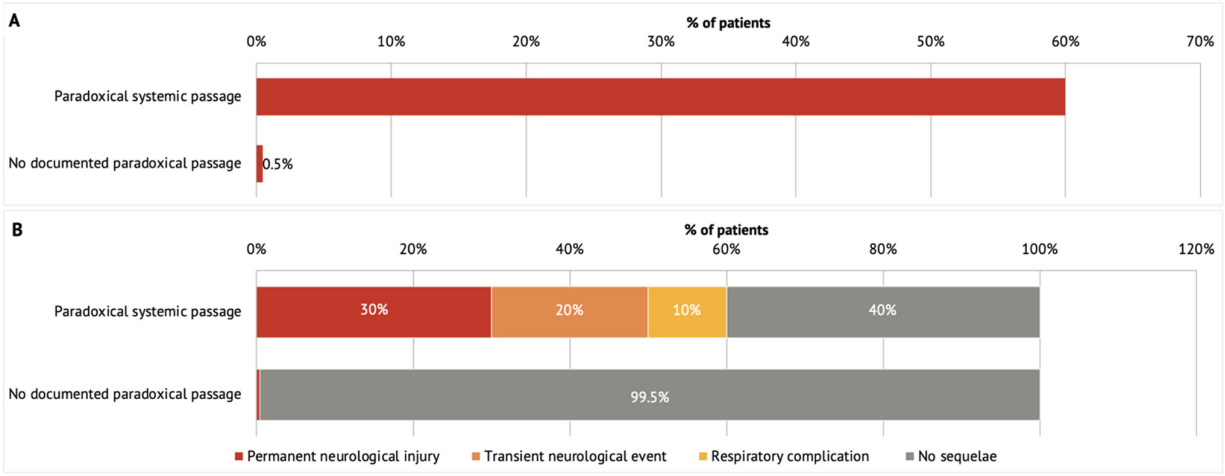

Figure 2. Outcomes of gas embolism according to embolic route. (**A**) Morbidity occurred in 6 of 10 patients (60%) with documented paradoxical systemic passage and in 1 of 218 patients (0.5%) without documented paradoxical passage. (**B**) Distribution of outcome categories within each group, expressed as a percentage of the group. Among patients with documented paradoxical systemic passage (10 cases), 3 (30%) had permanent neurological injury, 2 (20%) had a transient neurological event, 1 (10%) had respiratory complications only, and 4 (40%) had no sequelae. Among patients without documented paradoxical passage (218 cases), 1 (0.5%) had permanent neurological injury, while 217 (99.5%) had no sequelae. Morbidity was defined as any embolism-related neurological, respiratory, or cardiovascular sequela persisting beyond the intraoperative event. Data are presented descriptively; no inferential testing was performed.

On the other hand, embolism-related morbidity (any neurological, respiratory, or cardiovascular sequela persisting beyond the intraoperative event) occurred in six of 10 patients (60%) with documented paradoxical passage, as depicted in Figure 2 [37,41,43,45,46,53]. This contrast should be regarded as an exploratory, descriptive observation. Intracardiac and transpulmonary passage was not systematically investigated across studies, so that patients classified as having no documented paradoxical passage may simply have undergone less intensive diagnostic assessment; the comparison is therefore exposed to substantial ascertainment and reporting bias and does not establish an independent prognostic relationship.

Three (30%) patients affected by paradoxical embolism experienced cerebral infarctions [37,43,53], while two (20%) transient neurological events [45,46] and one (10%) patient reported pulmonary oedema [41].

No embolism-related death occurred across the 822 patients: the single fatality in the series of Hadji et al. [26], on postoperative day 14, was due to pulmonary infection and unrelated to the embolic event.

Table 4. Pneumoperitoneum pressure, severity, clinical significance, and outcomes of gas embolism in the included studies. Abbreviations: GE, gas embolism; NA, not available; NR, not reported; PP, pneumoperitoneum pressure.

Author	Pneumoperitoneum Pressure	GE Severity Grade °	Clinically Significant GE †	Paradoxical GE (Yes/No)	Outcomes	Mortality (Yes/No)
Min et al. [41]	12 mmHg	II-III	Yes (H, R, S)	Yes	Pulmonary oedema	No
Kawahara et al. [37]	10 mmHg	II-III	Yes (H, S)	Yes	- Cerebral infarction - Quadriplegia	No
Hong et al. [36]	15 mmHg	≥III: 32	1/49 (H)	No	No sequelae	No

De Cassai et al. [42]	12 mmHg	NA	Yes (H, R)	No	No sequelae	No
Kobayashi et al. [43]	7.4 mmHg #	NA	Yes (H, S)	Yes	Cerebral infarction	No
Takechi et al. [44]	12 mmHg	NA	Yes (H, R)	No	No sequelae	No
Zhang et al. [45]	15 mmHg	II-III	Yes (H, R, S)	Yes	- Tremor of left upper limb, - Reduced muscular power - Bilateral pleural effusion	No
Hou et al. [46]	12 mmHg	NA	Yes (R, S)	Yes	Transient right-hand numbness	No
Yang et al. [47]	12 mmHg	NA	Yes (H, R)	No	No sequelae	No
Kim et al. [48]	12 mmHg	II-III	Yes (H, R)	Yes	No sequelae	No
Jeon et al. [49]	17 mmHg	II-III	Yes (H, R)	Yes	No sequelae	No
Kennedy et al. [50]	NA	IV	Yes (H, R)	No	No sequelae	No
Qu et al. [51]	12 mmHg	NA	4/4 (H, R)	No	No sequelae	No
Wu et al. [52]	15 mmHg; Reduced to 13 mmHg after first desaturation	NA	Yes (H, R)	No	No sequelae	No
Shimizu et al. [53]	8–10 mmHg	NA	Yes (S)	Yes	- Cerebral infarction - Aphasia - Right-sided weakness	No
Luo et al. [27]	Low PP: 10 mmHg; Standard PP: 15 mmHg	≥III: 76 (29 at 10 mmHg vs. 47 at 15 mmHg)	NR ‡	No	1 cerebral infarction	No
Li et al. [54]	12 mmHg	NA	Yes (H, R)	No	No sequelae	No
Nakaji et al. [55]	12 mmHg	NA	Yes (H, R)	Yes	No sequelae	No
Sambommatsu et al. [56]	Exact pressure during the embolic event not reported; after this case, the upper limit was set at 12 mmHg	NA	1/1 (H, R)	No	No sequelae	No
Hadji et al. [26]	≤12 mmHg in 93% of cases	NA	26/26 (H and/or R) §	No	No sequelae	No
Saito et al. [57]	10–12 mmHg	II-III	2/2 (R)	Yes (1 case)	No sequelae	No

° GE severity was graded according to Schmandra et al. † Clinically significant: haemodynamic, respiratory, or neurological compromise prompting intervention, or embolism-related sequelae; for randomised trials and retrospective studies, number of patients with clinically significant GE/number of patients with GE. The criteria fulfilled are given in parentheses (H, haemodynamic compromise; R, respiratory compromise; S, embolism-related sequelae), as operationalised in the Methods; events classified as clinically significant without sequelae fulfilled at least one intraoperative criterion (H and/or R). # Original data reported 10 cmH_2O; the conversion to mmHg was performed by the reviewers. ‡ Clinically significant embolism was not reported per patient: severe embolism (Schmandra stage ≥III) was detected in 76 patients, haemodynamic and respiratory changes were reported only at group level, and one patient developed a postoperative cerebral infarction. § Symptomatic embolism was defined by the original authors on haemodynamic and/or respiratory grounds, which were not reported per patient.

4. Discussion

This review synthesised 21 studies reporting gas or CO_2 embolism during MILS, comprising 822 patients, 228 of whom experienced gas embolism of any severity.

Hepatic resection, with or without biliary and vascular reconstruction, remains challenging because of the numerous intra- and postoperative complications that may arise, such as post-hepatectomy haemorrhage (PHH) [58], bile leak [59], post-hepatectomy liver failure (PHLF) [60]and sepsis [61]. Among these adverse events, gas embolism is common but predominantly subclinical.

Resection extent, expressed as the number of resected segments, was not used to stratify incidence in any included study; its predictive value for embolic risk therefore remains undetermined. By contrast, reduction of pneumoperitoneum pressure was the

only preventive measure tested in a dedicated randomised trial, attenuating but not abolishing the risk [27].

4.1. Gas Embolism Pathway and Its Severity

During MILS, gas entry begins at the transection surface, where division of the parenchyma opens a hepatic vein or one of its branches. Because the pneumoperitoneum exceeds venous pressure, particularly under deliberately lowered CVP, this breach becomes a portal of entry rather than a source of bleeding, and CO_2 is drawn into the lumen [18]. The gas then follows the venous return through the hepatic veins into the inferior vena cava and reaches the right atrium and right ventricle [18]. From there it is carried into the pulmonary arteries, where a sufficient volume of intravascular bubbles may obstruct the right ventricular outflow tract and produce the gas-lock physiology that underlies acute haemodynamic collapse [18]. No event confined to the venous pathway was fatal. A minority of emboli instead reach the systemic arterial circulation, either through a right-to-left interatrial communication (a patent foramen ovale, an atrial septal defect, or a defect persisting after a transseptal procedure), or, when no shunt is demonstrable, by transpulmonary passage once the filtering capacity of the pulmonary microcirculation is exceeded [18]. This route appeared to be associated with the clinical severity of the event, although this observation is exploratory and subject to ascertainment bias.

4.2. Resection Extent and Surgical Approaches

Liver resection carries a substantial risk of resection surface-related complications (RSRC), chiefly bile leakage, bleeding, and abscess formation [62–66]. Gas embolism belongs to the same family of events, since it likewise originates at the transection plane; unlike the others, however, it arises from a vessel that is opened rather than one that bleeds. This distinction matters for how risk is stratified. Resection extent, as dichotomised by the Brisbane system into minor and major hepatectomy [33], captures the volume of parenchyma removed but not the anatomical circumstances that permit gas entry: the calibre and pressure of the veins exposed, their proximity to the hepatic venous confluence and inferior vena cava, and the duration for which the transection surface remains open.

Complex resections may plausibly favour gas embolism through several converging features, although this remains a hypothesis rather than an established association. Dissection proceeds adjacent to the major hepatic veins and inferior vena cava [67]; the operative field may be restricted, especially in posterosuperior resections, making visualization and vascular control more challenging [68], impeding haemostasis [51,69]; the transection plane is deep [70] prolonging the interval during which venous branches remain open; and the exposed veins are large-calibre and low-pressure, and therefore fully subject to the pneumoperitoneum-to-venous pressure gradient that drives gas entrainment [18,71–73]. These resections correspond to the advanced and expert grades of the IWATE criteria [34] and Tampa difficulty score [74], grade III of the Kawaguchi classification [35], and the expert-level indications of the Southampton Consensus [8]. However, the proximity of the target lesion to major vessels is itself a well-recognised marker of technical difficulty, given the intra- and postoperative complications it entails; yet only the IWATE score incorporates this factor into its stratification of complexity. These considerations should be regarded as a hypothesis requiring prospective validation: resection characteristics were documented for only 18 of the 228 patients, only 14 of whom could be classified, and denominators for the individual complexity categories were unavailable, so that no category-specific risk can be estimated from the present data. Accordingly, the present evidence neither supports nor excludes resection

extent or complexity as predictors of embolic risk, and their predictive value remains undetermined.

Although perioperative outcomes of RLR and LLR have been compared extensively, no comparative study or meta-analysis has specifically examined the risk of gas embolism between the two approaches [4,11,75,76]. Nevertheless, robotic surgery combines stable low-pressure valveless insufflation with magnified 3D vision that may aid earlier recognition of venous injury but lacks haptic feedback near major veins [3,77–80]. On the other hand, RLR may require prolonged parenchymal transection times [56] and places the primary surgeon at a remote console, potentially reducing direct patient observation and immediate communication with the anaesthetic team when haemodynamic instability occurs [81,82].

4.3. Prevention, Recognition, and Management

Although the adoption of minimally invasive approaches is steadily increasing [2,9,83,84], the determinants of gas embolism converge on a limited set of variables, distributed across the perioperative pathway (Table 5).

Preoperative determinants, a right-to-left shunt [48,53,55,57], cirrhosis with intrapulmonary shunting or portal-hypertensive collaterals [43,50], lesion location [37,54], and previous abdominal surgery [36,52] are largely non-modifiable and were the least well evidenced since no included study was designed to identify them.

Intraoperative determinants account for most of the risk and are largely modifiable: pneumoperitoneum pressure [27,49,51,52], the insufflation system [26,53,57], the depth of CVP reduction [26,27,42,51], the use and duration of the Pringle manoeuvre [27,44], the energy device (argon-beam coagulation having produced a mixed CO_2–argon embolism with impaired resorption [41]), and the trajectory of transection [27,51,54]. These converge on deep transection adjacent to an exposed hepatic vein under low CVP, the phase in which monitoring should be concentrated [18,27].

Table 5. Determinants of gas embolism risk during minimally invasive hepatectomy, by perioperative phase.

Phase	Determinant	Mechanism	Modifiable
Preoperative	Patent foramen ovale or other right-to-left shunt	Direct route for paradoxical systemic embolism	No (identifiable)
	Iatrogenic atrial septal defect after transseptal cardiac ablation	Persistent interatrial communication permitting transient right-to-left shunting	No (identifiable)
	Cirrhosis/portal hypertension	Intrapulmonary right-to-left shunting; collateral circulation providing additional portals of entry	No
	Lesion in postero-superior segments or adjacent to hepatic venous confluence	Determines dissection trajectory	Partly (approach, monitoring)
	Previous abdominal surgery	Adhesions and neovascularisation	No
Intraoperative	Pneumoperitoneum pressure	Magnitude of the pneumoperitoneum-to-venous gradient	Yes
	Valveless high-flow insufflation system	Pressure stability at high flow; possible room-air entrainment during suction	Yes
	Depth of CVP reduction	Widens the gradient at the moment of venous exposure	Yes
	Pringle manoeuvre	Reduces inflow and thereby intrahepatic venous pressure	Yes (duration, timing)

	Hepatic vein exposure, dissection, or injury	Creates the venous-to-peritoneal interface	Partly
	Energy device (e.g., argon-beam coagulation)	Delivery of poorly soluble gas into an open vein	Yes
Postoperative	None identified	Driving gradient abolished on desufflation; what persists is consequence (neurological sequelae), not risk	—

The benefit of a lower insufflation pressure must nonetheless be weighed against the need to maintain adequate exposure and haemostasis. Pneumoperitoneum exerts a tamponade effect on back-bleeding from hepatic venous branches, and an excessive reduction in pressure may impair the working space, prolong transection, and increase blood loss; the optimal pressure is therefore likely to be phase-specific and tailored to the resection, a question currently addressed by ongoing randomised trials (e.g., NCT06770803 [85]). Similarly, the optimal CVP strategy remains uncertain, as a low CVP limits bleeding but widens the pressure gradient favouring gas entry, and no included study defined a target that balances these competing risks.

Postoperative determinants were not identified; once the pneumoperitoneum is evacuated the driving gradient is removed, and postoperative care is supportive rather than preventive.

Because most determinants are therefore concentrated in the intraoperative phase, recognition and management at the operating table become decisive. We therefore propose a flow-chart of early recognition and management (Figure 3). This algorithm is an expert-informed synthesis derived largely from heterogeneous observational evidence and is not a validated management protocol; its individual steps should be adapted to the clinical circumstances, the available resources, and the strength of the supporting evidence.

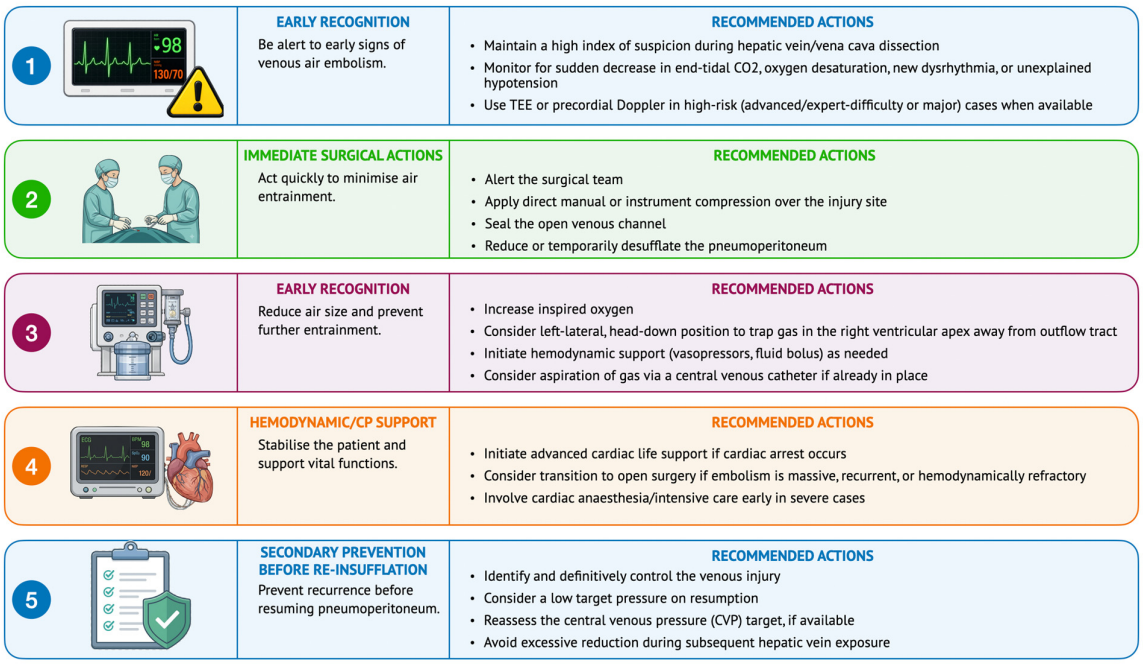

Figure 3. Stepwise intraoperative recognition and management of suspected gas embolism. The algorithm represents an expert-informed synthesis of the predominantly observational evidence identified in this review and has not been validated prospectively.

Because an abrupt fall in end-tidal CO_2 was absent or paradoxically reversed in approximately 50% of cases, and the mill-wheel murmur was audible in 1.3% [45,49,52], any unexplained haemodynamic or respiratory deterioration during vein-adjacent transection should prompt consideration of embolism. Capnography, arterial blood-gas analysis, and echocardiography should be used as confirmatory tests.

If confirmed, desufflation alone frequently arrested the event, and control of the venous breach was decisive, whereas catheter aspiration of gas gave inconsistent results [42,46,52,55].

Conversion should be reserved for instability refractory to desufflation and supportive measures, or for a source not controllable minimally invasively.

4.4. Limitations

This is a scoping review rather than a meta-analysis: quantitative pooling was precluded both by heterogeneity in embolism definitions, detection modalities and outcome reporting, and by the structure of the evidence itself. Most included reports contributed a single patient, yielding no denominator and no within-study variance, so that inverse-variance weighting and heterogeneity metrics could not be computed. We therefore summarised the published cases descriptively, with the patient experiencing at least one embolic event as the unit of analysis; because individual-level information was not consistently available from the included cohort studies, this should not be regarded as an individual-patient-data analysis, and the proportions presented describe the published cases rather than the disease population. No inferential testing was performed, because the unit of analysis is the published case and not a probability sample. The scoping design was chosen deliberately: the heterogeneity of definitions, detection methods, and study designs made a systematic review and/or meta-analysis aimed at estimating incidence inappropriate at this stage, whereas mapping the extent and nature of the available evidence was feasible. The search was documented, conducted in three databases, and screened through Rayyan [30]; nevertheless, the restriction to English-language publications and to three databases may have introduced selection bias, and relevant studies published in other languages or indexed elsewhere may have been missed.

The evidence base is dominated by single-patient case reports (16 of 21 studies), which are subject to reporting and publication bias and cannot support precise incidence estimation. Only two randomised trials and three retrospective studies were identified; none of the latter was designed with embolism as a prospectively defined primary outcome. Geographical concentration is pronounced, with 81% of reports originating from three East Asian countries.

Resection difficulty was seldom reported in a manner permitting quantitative attribution, and in several cases complexity was assigned by the reviewers from segmental anatomy rather than by the original authors; individual resection data were available for 18 patients, only 14 of whom could be classified. Similarly, the classification of clinical significance relied on the intraoperative findings and management described in the original reports, which varied in detail. The three-tier framework is conceptual and unvalidated, and conclusions on surgical complexity should be regarded as hypotheses requiring prospective validation. Finally, publication bias probably operates in two directions, since dramatic or fatal events are preferentially reported whereas routine, TEE-detected subclinical embolism is rarely published; it could be neither quantified nor corrected, so the true incidence and severity distribution may be misestimated.

5. Conclusions

Gas embolism during LLR and RLR ranges from subclinical microbubble showers to rare cardiovascular and neurological events. The predictive value of resection extent and complexity for embolic risk remains undetermined. The determinants of risk appear predominantly intraoperative and potentially modifiable, and reduction of pneumoperitoneum pressure is the only preventive measure tested in a dedicated randomised trial, attenuating rather than abolishing risk. Although laparoscopic and robotic liver resection have been compared extensively, no comparative study has specifically assessed embolic risk between the two approaches, which is the principal and most clinically relevant evidence gap identified here. Priorities for future research are: prospective multicentre studies using standardised TEE-based grading as a predefined outcome, stratified by resection difficulty grade and insufflation system; randomised evaluation of dynamic, phase-specific CVP targets; registry-based pooling of events across HPB centres.

Supplementary Materials: The following supporting information can be downloaded at: https://www.mdpi.com/article/10.3390/diseases14120440/s1. **Table S1:** Preferred Reporting Items for Systematic reviews and Meta-Analyses extension for Scoping Reviews (PRISMA-ScR) Checklist [28]; **Table S2:** Clinical course of the embolic events: findings, management, proposed mechanism, and outcome; **Table S3:** Methodological quality of the randomised controlled trials, cohort studies, and case series, appraised with the SIGN-50 methodology checklists [38] or, for the case series, with the JBI Critical Appraisal Checklist for Case Series [40]; **Table S4:** Methodological quality of the case reports, appraised with the JBI Critical Appraisal Checklist for Case Reports [39]. According to SIGN-50, all case reports correspond to level 3 evidence [38]. Case reports fulfilling at least 7 of the 8 items were considered of high reporting quality, those fulfilling 5–6 items of moderate quality, and those fulfilling 4 or fewer of low quality. Q1, patient demographics clearly described; Q2, patient history clearly described and presented as a timeline; Q3, clinical condition at presentation clearly described; Q4, diagnostic tests or assessment methods and results clearly described; Q5, intervention or treatment clearly described; Q6, post-intervention clinical condition clearly described; Q7, adverse or unanticipated events identified and described; Q8, take-away lessons provided.

Author Contributions: S.S. and P.A.: study conception and design, literature search, data acquisition, interpretation, and analysis; drafting and critically revising the article for important intellectual content; final approval of the version to be published. P.B. and G.A.G.: literature search, data acquisition, final approval of the version to be published. S.S., P.B., G.A.G., G.Q., A.F., F.S., G.G., G.C., A.R. and P.A.: interpretation and analysis; G.G., G.C., A.R. and P.A.: supervision, drafted and critically revised the article for important intellectual content; final approval of the version to be published. All authors have read and agreed to the published version of the manuscript.

Funding: This research received no funding.

Institutional Review Board Statement: Not applicable. This study is a review of previously published literature and did not involve human participants or animals.

Informed Consent Statement: Not applicable.

Data Availability Statement: The raw data supporting the conclusions of this article will be made available by the authors, without undue reservation.

Conflicts of Interest: The authors declare no conflicts of interest.

References

1. Rocca, A.; Avella, P.; Scacchi, A.; Brunese, M.C.; Cappuccio, M.; De Rosa, M.; Bartoli, A.; Guerra, G.; Calise, F.; Ceccarelli, G. Robotic versus open resection for colorectal liver metastases in a "referral centre Hub&Spoke learning program". A multicenter propensity score matching analysis of perioperative outcomes. *Heliyon* **2024**, *10*, e24800. https://doi.org/10.1016/j.heliyon.2024.e24800.
2. Abu Hilal, M.; Hoogteijling, T.J.; Edwin, B.; Dagher, I.; D'Hondt, M.; Marques, H.P.; Swijnenburg, R.J.; Boggi, U.; Sucandy, I.; Ferrero, A.; et al. The Brescia internationally validated European guidelines on minimally invasive liver surgery. *Br. J. Surg.* **2025**, *112*, znaf113. https://doi.org/10.1093/bjs/znaf113.
3. Ceccarelli, G.; Avella, P.; Ballelli, L.; Mariani, L.; Bianco, P.; Scarponi, R.; Guerra, G.; Spiezia, S.; Rocca, A. Robotic hepatectomy for benign liver disease: Single-centre consecutive series and meta-analysis comparing minimally invasive and open approaches. *J. Robot. Surg.* **2026**, *20*, 738. https://doi.org/10.1007/s11701-026-03692-z.
4. Kamarajah, S.K.; Bundred, J.; Manas, D.; Jiao, L.; Hilal, M.A.; White, S.A. Robotic versus conventional laparoscopic liver resections: A systematic review and meta-analysis. *Scand. J. Surg.* **2021**, *110*, 290–300. https://doi.org/10.1177/1457496920925637.
5. Landry, J.; Jain, A.J.; Tzeng, C.W.; Newhook, T.E.; Ikoma, N.; Chun, Y.S.; Vauthey, J.N.; Cheah, Y.L.; Hawksworth, J.S.; Tran Cao, H.S. Robotic Hepatic Parenchymal Transection Techniques: A Choice Between Imperfect Tools. *Ann. Surg. Oncol.* **2024**, *32*, 438–439. https://doi.org/10.1245/s10434-024-16350-1.
6. Buell, J.F.; Cherqui, D.; Geller, D.A.; O'Rourke, N.; Iannitti, D.; Dagher, I.; Koffron, A.J.; Thomas, M.; Gayet, B.; Han, H.S.; et al. The international position on laparoscopic liver surgery: The Louisville Statement, 2008. *Ann. Surg.* **2009**, *250*, 825–830. https://doi.org/10.1097/sla.0b013e3181b3b2d8.
7. Wakabayashi, G.; Cherqui, D.; Geller, D.A.; Buell, J.F.; Kaneko, H.; Han, H.S.; Asbun, H.; O'Rourke, N.; Tanabe, M.; Koffron, A.J.; et al. Recommendations for laparoscopic liver resection: A report from the second international consensus conference held in Morioka. *Ann. Surg.* **2015**, *261*, 619–629.
8. Abu Hilal, M.; Aldrighetti, L.; Dagher, I.; Edwin, B.; Troisi, R.I.; Alikhanov, R.; Aroori, S.; Belli, G.; Besselink, M.; Briceno, J.; et al. The Southampton Consensus Guidelines for Laparoscopic Liver Surgery: From Indication to Implementation. *Ann. Surg.* **2018**, *268*, 11–18. https://doi.org/10.1097/sla.0000000000002524.
9. Hobeika, C.; Pfister, M.; Geller, D.; Tsung, A.; Chan, A.C.; Troisi, R.I.; Rela, M.; Di Benedetto, F.; Sucandy, I.; Nagakawa, Y.; et al. Recommendations on Robotic Hepato-Pancreato-Biliary Surgery. The Paris Jury-Based Consensus Conference. *Ann. Surg.* **2025**, *281*, 136–153. https://doi.org/10.1097/sla.0000000000006365.
10. Ceccarelli, G.; Avella, P.; Muttillo, E.M.; Conticchio, M.; Tebala, G.D.; Piccolo, G.; Romano, L.; Memeo, R.; Rocca, A. Devices for minimally invasive liver parenchyma transection: The SICE (Italian Society of Endoscopic Surgery) Italian and International survey. *Surg. Endosc.* **2025**, *39*, 4822–4838. https://doi.org/10.1007/s00464-025-11769-3.
11. Aboudou, T.; Li, M.; Zhang, Z.; Wang, Z.; Li, Y.; Feng, L.; Chu, X.; Chen, N.; Zhou, W.; Yang, K. Laparoscopic versus Robotic Hepatectomy: A Systematic Review and Meta-Analysis. *J. Clin. Med.* **2022**, *11*, 5831. https://doi.org/10.3390/jcm11195831.
12. Conticchio, M.; Maggialetti, N.; Rescigno, M.; Brunese, M.C.; Vaschetti, R.; Inchingolo, R.; Calbi, R.; Ferraro, V.; Tedeschi, M.; Fantozzi, M.R.; et al. Hepatocellular Carcinoma with Bile Duct Tumor Thrombus: A Case Report and Literature Review of 890 Patients Affected by Uncommon Primary Liver Tumor Presentation. *J. Clin. Med.* **2023**, *12*, 423. https://doi.org/10.3390/jcm12020423.
13. Cheung, T.T.; Liu, R.; Cipriani, F.; Wang, X.; Efanov, M.; Fuks, D.; Choi, G.H.; Syn, N.L.; Chong, C.C.N.; Di Benedetto, F.; et al. Robotic versus laparoscopic liver resection for huge (≥10 cm) liver tumors: An international multicenter propensity-score matched cohort study of 799 cases. *Hepatobiliary Surg. Nutr.* **2023**, *12*, 205–215. https://doi.org/10.21037/hbsn-22-283.
14. Traina, G.; Marino, R.; Ferrero, A.; Giuliante, F.; Ruzzenente, A.; Ercolani, G.; Cillo, U.; Mazzaferro, V.; Ettorre, G.M.; Belli, A.; et al. Laparoscopic versus robotic surgery in the setting of combined resection of colorectal cancer and liver metastases: An experience from the I Go MILS registry. *Updates Surg.* **2026**, *78*, 2029–2038. https://doi.org/10.1007/s13304-026-02684-w.
15. Procopio, F.; Risi, L.; Costa, G.; Torzilli, G. Robotic parenchyma-sparing resection with a multiplanar-driven approach: The mini-rollercoaster hepatectomy. *Updat. Surg.* 2026. *Epub ahead of print*. https://doi.org/10.1007/s13304-026-02790-9.
16. Likalamu, P.W.; Yu, W.; Xia, N.; Zhang, Y.; Sun, L.; Li, X.; Chen, X.; Han, S.; Wang, Z.; Pu, L. Anatomy of the right portal vein and right hepatic vein for anatomical minimally invasive liver resection. *iLIVER* **2026**, *5*, 100226. https://doi.org/10.1016/j.iliver.2026.100226.
17. Schmandra, T.C.; Mierdl, S.; Bauer, H.; Gutt, C.; Hanisch, E. Transoesophageal echocardiography shows high risk of gas embolism during laparoscopic hepatic resection under carbon dioxide pneumoperitoneum. *Br. J. Surg.* **2002**, *89*, 870–876. https://doi.org/10.1046/j.1365-2168.2002.02123.x.

18. Xie, Z.; Li, W.; Dong, B.; Huang, Z.; Jin, C.; Yu, H.; Yu, X. Research progress on carbon dioxide embolism during laparoscopic liver resection. *Laparosc. Endosc. Robot. Surg.* **2025**, *8*, 171–177. https://doi.org/10.1016/j.lers.2025.10.002.
19. Lucas, T.O.; Schaustz, E.B.; Dos Reis, I.J.R.; Lopes, C.G.; Mendoça, V.S.; Salluh, J.I.F.; Zukowski, C.N.; Serafim, R.B. Risk of ischemic stroke in patients with pulmonary embolism and patent foramen ovale: A systematic review and meta-analysis. *J. Stroke Cerebrovasc. Dis.* **2025**, *34*, 108157. https://doi.org/10.1016/j.jstrokecerebrovasdis.2024.108157.
20. Wu, D.; Zhang, M.; Tao, Y.; Li, Y.; Yu, H.; Zhang, S.; Luo, Y.; Chu, T.; Chen, X.; Ying, W. Characteristic 'Pattern of Autofluorescence◉of the Fingernails and Certain Skin◉ Positions is a Novel Diagnostic Biomarker for Acute Ischemic Stroke: A Preliminary Study. *Phenomics* **2025**, *5*, 681–696. https://doi.org/10.1007/s43657-024-00209-2.
21. Neudecker, J.; Sauerland, S.; Neugebauer, E.; Bergamaschi, R.; Bonjer, H.J.; Cuschieri, A.; Fuchs, K.H.; Jacobi, C.; Jansen, F.W.; Koivusalo, A.M.; et al. The European Association for Endoscopic Surgery clinical practice guideline on the pneumoperitoneum for laparoscopic surgery. *Surg. Endosc.* **2002**, *16*, 1121–1143. https://doi.org/10.1007/s00464-001-9166-7.
22. Shulman, D.; Aronson, H.B. Capnography in the early diagnosis of carbon dioxide embolism during laparoscopy. *Can. Anaesth. Soc. J.* **1984**, *31*, 455–459. https://doi.org/10.1007/bf03015425.
23. Otsuka, Y.; Katagiri, T.; Ishii, J.; Maeda, T.; Kubota, Y.; Tamura, A.; Tsuchiya, M.; Kaneko, H. Gas embolism in laparoscopic hepatectomy: What is the optimal pneumoperitoneal pressure for laparoscopic major hepatectomy? *J. Hepato-Biliary-Pancreat. Sci.* **2013**, *20*, 137–140. https://doi.org/10.1007/s00534-012-0556-0.
24. Atkinson, T.M.; Giraud, G.D.; Togioka, B.M.; Jones, D.B.; Cigarroa, J.E. Cardiovascular and Ventilatory Consequences of Laparoscopic Surgery. *Circulation* **2017**, *135*, 700–710. https://doi.org/10.1161/circulationaha.116.023262.
25. Park, E.Y.; Kwon, J.Y.; Kim, K.J. Carbon dioxide embolism during laparoscopic surgery. *Yonsei Med. J.* **2012**, *53*, 459–466. https://doi.org/10.3349/ymj.2012.53.3.459.
26. Hadji, W.; Beghdadi, N.; Salloum, C.; Goumard, C.; Dokmak, S.; Lim, C.; Roullet, S.; Bounab, R.; Annane, D.; Lesurtel, M.; et al. Incidence and Risk Factors of Symptomatic Venous Gas Embolism During Laparoscopic Liver Resection. *J. Hepato-Biliary-Pancreat. Sci.* **2025**, *32*, 865–870. https://doi.org/10.1002/jhbp.70013.
27. Luo, W.; Jin, D.; Huang, J.; Zhang, J.; Xu, Y.; Gu, J.; Sun, C.; Yu, J.; Xu, P.; Liu, L.; et al. Low Pneumoperitoneum Pressure Reduces Gas Embolism During Laparoscopic Liver Resection: A Randomized Controlled Trial. *Ann. Surg.* **2024**, *279*, 588–597. https://doi.org/10.1097/sla.0000000000006130.
28. Tricco, A.C.; Lillie, E.; Zarin, W.; O◉Brien, K.K.; Colquhoun, H.; Levac, D.; Moher, D.; Peters, M.D.J.; Horsley, T.; Weeks, L.; et al. PRISMA Extension for Scoping Reviews (PRISMA-ScR): Checklist and Explanation. *Ann. Intern. Med.* **2018**, *169*, 467–473. https://doi.org/10.7326/m18-0850.
29. van den Akker, O.R.; Peters, G.Y.; Bakker, C.J.; Carlsson, R.; Coles, N.A.; Corker, K.S.; Feldman, G.; Moreau, D.; Nordström, T.; Pickering, J.S.; et al. Increasing the transparency of systematic reviews: Presenting a generalized registration form. *Syst. Rev.* **2023**, *12*, 170.
30. Ouzzani, M.; Hammady, H.; Fedorowicz, Z.; Elmagarmid, A. Rayyan—A web and mobile app for systematic reviews. *Syst. Rev.* **2016**, *5*, 210. https://doi.org/10.1186/s13643-016-0384-4.
31. Bramer, W.M.; Giustini, D.; de Jonge, G.B.; Holland, L.; Bekhuis, T. De-duplication of database search results for systematic reviews in EndNote. *J. Med. Libr. Assoc. JMLA* **2016**, *104*, 240–243. https://doi.org/10.3163/1536-5050.104.3.014.
32. Eldawlatly, A.; Alshehri, H.; Alqahtani, A.; Ahmad, A.; Al-Dammas, F.; Marzouk, A. Appearance of Population, Intervention, Comparison, and Outcome as research question in the title of articles of three different anesthesia journals: A pilot study. *Saudi J. Anaesth.* **2018**, *12*, 283–286. https://doi.org/10.4103/sja.SJA_767_17.
33. Strasberg, S.M.; Belghiti, J.; Clavien, P.A.; Gadzijev, E.; Garden, J.O.; Lau, W.Y.; Makuuchi, M.; Strong, R.W. The Brisbane 2000 Terminology of Liver Anatomy and Resections. *HPB* **2000**, *2*, 333–339. https://doi.org/10.1016/S1365-182X(17)30755-4.
34. Ban, D.; Tanabe, M.; Ito, H.; Otsuka, Y.; Nitta, H.; Abe, Y.; Hasegawa, Y.; Katagiri, T.; Takagi, C.; Itano, O.; et al. A novel difficulty scoring system for laparoscopic liver resection. *J. Hepato-Biliary-Pancreat. Sci.* **2014**, *21*, 745–753. https://doi.org/10.1002/jhbp.166.
35. Kawaguchi, Y.; Fuks, D.; Kokudo, N.; Gayet, B. Difficulty of Laparoscopic Liver Resection: Proposal for a New Classification. *Ann. Surg.* **2018**, *267*, 13–17. https://doi.org/10.1097/sla.0000000000002176.
36. Hong, Y.; Xin, Y.; Yue, F.; Qi, H.; Jun, C. Randomized clinical trial comparing the effects of sevoflurane and propofol on carbon dioxide embolism during pneumoperitoneum in laparoscopic hepatectomy. *Oncotarget* **2017**, *8*, 27502–27509. https://doi.org/10.18632/oncotarget.15492.
37. Kawahara, T.; Hagiwara, M.; Takahashi, H.; Tanaka, M.; Imai, K.; Sawada, J.; Kunisawa, T.; Furukawa, H. Cerebral Infarction by Paradoxical Gas Embolism During Laparoscopic Liver Resection with Injury of the Hepatic Vessels in a Patient without a Right-to-Left Systemic Shunt. *Am. J. Case Rep.* **2017**, *18*, 687–691. https://doi.org/10.12659/ajcr.903777.

38. Scottish Intercollegiate Guidelines Network (SIGN). *SIGN 50: A Guideline Developer's Handbook*; SIGN: Edinburgh, UK, 2011. Available online: https://www.sign.ac.uk/assets/sign50_2011.pdf (accessed on 16 November 2026).
39. Aromataris, E.; Lockwood, C.; Porritt, K.; Pilla, B.; Jordan, Z. (Eds.) *JBI Manual for Evidence Synthesis*; JBI: Long Beach, CA, USA, 2024.
40. Munn, Z.; Barker, T.H.; Moola, S.; Tufanaru, C.; Stern, C.; McArthur, A.; Stephenson, M.; Aromataris, E. Methodological quality of case series studies: An introduction to the JBI critical appraisal tool. *JBI Evid. Synth.* **2020**, *18*, 2127–2133. https://doi.org/10.11124/jbisrir-d-19-00099.
41. Min, S.K.; Kim, J.H.; Lee, S.Y. Carbon dioxide and argon gas embolism during laparoscopic hepatic resection. *Acta Anaesthesiol. Scand.* **2007**, *51*, 949–953. https://doi.org/10.1111/j.1399-6576.2007.01361.x.
42. De Cassai, A.; Boetto, R.; Gabellini, G.; Cillo, U. Massive Carbon Dioxide Embolism During Laparoscopic Liver Resection: A Case Report. *Cureus* **2019**, *11*, e5075. https://doi.org/10.7759/cureus.5075.
43. Kobayashi, A.; Shirozu, K.; Karashima, Y.; Matsushita, K.; Yamaura, K. Cerebral infarction detected after laparoscopic partial hepatectomy: Case report. *JA Clin. Rep.* **2019**, *5*, 82. https://doi.org/10.1186/s40981-019-0301-7.
44. Takechi, K.; Ito, M.; Peng, Y.; Daizen, W.; Shimizu, I. Laparoscopic image of carbon dioxide embolism during laparoscopic hepatectomy: A case report. *JA Clin. Rep.* **2020**, *6*, 39. https://doi.org/10.1186/s40981-020-00345-4.
45. Zhang, J.; Zhao, J.; Fei, Y.; Liu, T.; Liu, M. Successful outcome of massive carbon dioxide embolism during laparoscopic hepatectomy. *Laparosc. Endosc. Robot. Surg.* **2020**, *3*, 52–55. https://doi.org/10.1016/j.lers.2020.04.001.
46. Hou, W.; Zhong, J.; Pan, B.; Huang, J.; Wang, B.; Sun, Z.; Miao, C. Paradoxical carbon dioxide embolism during laparoscopic surgery without intracardiac right-to-left shunt: Two case reports and a brief review of the literature. *J. Int. Med. Res.* **2020**, *48*, 300060520933816. https://doi.org/10.1177/0300060520933816.
47. Yang, M. Hypercarbia During Laparoscopic Hepatectomy. *Indian J. Surg.* **2022**, *84*, 431–433. https://doi.org/10.1007/s12262-022-03390-8.
48. Kim, H.; Lee, J.; Lee, S.G.; Shim, K.S. Detection of paradoxical carbon dioxide gas embolism with opening of patent foramen ovale by perioperative transesophageal echocardiography during laparoscopic hepatectomy—A case report. *Anesth. Pain Med.* **2022**, *17*, 397–403. https://doi.org/10.17085/apm.22170.
49. Jeon, S.; Hong, J.M.; Lee, H.J.; Kim, Y.; Kang, H.; Hwang, B.Y.; Lee, D.; Jung, Y.H. Paradoxical carbon dioxide embolism during laparoscopic hepatectomy without intracardiac shunt: A case report. *World J. Clin. Cases* **2022**, *10*, 2908–2915. https://doi.org/10.12998/wjcc.v10.i9.2908.
50. Kennedy, L.; Zamper, R.P.C. When Insufflation Goes Awry: Massive Gas Embolism During Laparoscopic Surgery. *CASE* **2023**, *7*, 185–188. https://doi.org/10.1016/j.case.2022.12.001.
51. Qu, Z.; Wu, K.J.; Feng, J.W.; Shi, D.S.; Chen, Y.X.; Sun, D.L.; Duan, Y.F.; Chen, J.; He, X.Z. Treatment of hepatic venous system hemorrhage and carbon dioxide gas embolization during laparoscopic hepatectomy via hepatic vein approach. *Front. Oncol.* **2022**, *12*, 1060823. https://doi.org/10.3389/fonc.2022.1060823.
52. Wu, D. Carbon Dioxide Embolism During Laparoscopic Right Hepatectomy: A Case Report. *Asploro J. Biomed. Clin. Case Rep.* **2023**, *6*, 195–200. https://doi.org/10.36502/2023/ASJBCCR.6315.
53. Shimizu, K.; Usuda, M.; Kakizaki, Y.; Narita, T.; Suzuki, O.; Fukuoka, K. Cerebral infarction by paradoxical gas embolism detected after laparoscopic partial hepatectomy with an insufflation management system: A case report. *Surg. Case Rep.* **2023**, *9*, 34. https://doi.org/10.1186/s40792-023-01611-0.
54. Li, M.; Yan, B.; Wang, M.; Zhu, S.; Kang, X. A portent of catastrophic carbon dioxide embolism in laparoscopic hepatectomy: A case report. *Medicine* **2024**, *103*, e38468. https://doi.org/10.1097/md.0000000000038468.
55. Nakaji, Y.; Sakai, Y.; Yonezawa, H.; Kakuta, N.; Tanaka, K. Carbon dioxide embolism during laparoscopic hepatectomy in a patient with an iatrogenic atrial septal defect:A case report. *J. Med. Investig.* **2024**, *71*, 320–322. https://doi.org/10.2152/jmi.71.320.
56. Sambommatsu, Y.; Kumaran, V.; Imai, D.; Savsani, K.; Khan, A.A.; Sharma, A.; Saeed, M.; Cotterell, A.H.; Levy, M.F.; Lee, S.D.; et al. Early outcomes of robotic vs open living donor right hepatectomy in a US Center. *Surg. Endosc.* **2025**, *39*, 1643–1652. https://doi.org/10.1007/s00464-024-11469-4.
57. Saito, Y.; Morine, Y.; Yamada, S.; Teraoku, H.; Ikemoto, T.; Shimada, M. Paradoxical carbon dioxide embolism through an iatrogenic atrial septal defect after catheter ablation for atrial fibrillation during laparoscopic hepatectomy: Two case reports and a brief review of the literature (with video). *Clin. J. Gastroenterol.* **2025**, *18*, 1000–1006. https://doi.org/10.1007/s12328-025-02196-x.

58. Rahbari, N.N.; Garden, O.J.; Padbury, R.; Maddern, G.; Koch, M.; Hugh, T.J.; Fan, S.T.; Nimura, Y.; Figueras, J.; Vauthey, J.N.; et al. Post-hepatectomy haemorrhage: A definition and grading by the International Study Group of Liver Surgery (ISGLS). *HPB* **2011**, *13*, 528–535. https://doi.org/10.1111/j.1477-2574.2011.00319.x.
59. Koch, M.; Garden, O.J.; Padbury, R.; Rahbari, N.N.; Adam, R.; Capussotti, L.; Fan, S.T.; Yokoyama, Y.; Crawford, M.; Makuuchi, M.; et al. Bile leakage after hepatobiliary and pancreatic surgery: A definition and grading of severity by the International Study Group of Liver Surgery. *Surgery* **2011**, *149*, 680–688. https://doi.org/10.1016/j.surg.2010.12.002.
60. Rahbari, N.N.; Garden, O.J.; Padbury, R.; Brooke-Smith, M.; Crawford, M.; Adam, R.; Koch, M.; Makuuchi, M.; Dematteo, R.P.; Christophi, C.; et al. Posthepatectomy liver failure: A definition and grading by the International Study Group of Liver Surgery (ISGLS). *Surgery* **2011**, *149*, 713–724. https://doi.org/10.1016/j.surg.2010.10.001.
61. Capussotti, L.; Viganò, L.; Giuliante, F.; Ferrero, A.; Giovannini, I.; Nuzzo, G. Liver dysfunction and sepsis determine operative mortality after liver resection. *Br. J. Surg.* **2009**, *96*, 88–94. https://doi.org/10.1002/bjs.6429.
62. Une, N.; Kobayashi, S.; Kudo, M.; Sugimoto, M.; Kitaguchi, D.; Hasegawa, H.; Ando, K.; Ikeda, K.; Nishizawa, Y.; Tsukada, Y.; et al. Predictive risk factors for resection surface-related complications after laparoscopic simultaneous resection of primary colorectal tumor and synchronous liver metastases: A single-center retrospective study. *Surg. Endosc.* **2024**, *38*, 5006–5016. https://doi.org/10.1007/s00464-024-10964-y.
63. Avella, P.; Spiezia, S.; Rotondo, M.; Cappuccio, M.; Scacchi, A.; Inglese, G.; Guerra, G.; Brunese, M.C.; Bianco, P.; Tedesco, G.A.; et al. Real-Time Navigation in Liver Surgery Through Indocyanine Green Fluorescence: An Updated Analysis of Worldwide Protocols and Applications. *Cancers* **2025**, *17*, 872. https://doi.org/10.3390/cancers17050872.
64. Sena, G.; Picciariello, A.; Marino, F.; Goglia, M.; Rocca, A.; Meniconi, R.L.; Gallo, G. One-Stage Total Laparoscopic Treatment for Colorectal Cancer With Synchronous Metastasis. Is It Safe and Feasible? *Front. Surg.* **2021**, *8*, 752135. https://doi.org/10.3389/fsurg.2021.752135.
65. Ratti, F.; Serenari, M.; Corallino, D.; Aldrighetti, L. Augmented reality improving intraoperative navigation in minimally invasive liver surgery: An interplay between 3D reconstruction and indocyanine green. *Updates Surg.* **2024**, *76*, 2701–2708. https://doi.org/10.1007/s13304-024-01857-9.
66. Avella, P.; Brunese, M.C.; Spiezia, S.; Inglese, G.; Bianco, P.; Stanzione, F.; Varriano, G.; Cappabianca, S.; Calise, F.; Rocca, A.; et al. Imaging-based 3D-printed anatomical models for preoperative planning in hepatopancreatobiliary surgery: A single-center pilot study, cost analysis, and systematic review. *Radiol. Med.* **2026**, *131*, 1100–1120. https://doi.org/10.1007/s11547-026-02210-3.
67. Grat, M.; Grzegorczyk, K.; Lewandowski, Z.; Sujecki, D.; Szwedowski, D.; Boltuc, A.; Smoter, P.; Kornasiewicz, O.; Krawczyk, M. Intraoperative injuries during liver resection: Analysis of 1,005 procedures. *Hepatol. Int.* **2012**, *6*, 498–504. https://doi.org/10.1007/s12072-011-9281-z.
68. Xie, Q.; Zhang, B.; Tan, Y.C.; Koh, B.; Wu, H.; Zhang, C.; Cai, Y.; Gao, F.; Wu, H.; Xie, K. Application of selective outflow control technique-assisted laparoscopic hepatectomy for hepatocellular carcinoma in the right posterior superior area: A case series study (with video). *Surg. Endosc.* **2026**, *40*, 7213–7222.
69. Kawaguchi, Y.; Nomi, T.; Fuks, D.; Mal, F.; Kokudo, N.; Gayet, B. Hemorrhage control for laparoscopic hepatectomy: Technical details and predictive factors for intraoperative blood loss. *Surg. Endosc.* **2016**, *30*, 2543–2551. https://doi.org/10.1007/s00464-015-4520-3.
70. Fuji, T.; Takagi, K.; Yasui, K.; Ito, A.; Nishiyama, T.; Nagai, Y.; Yokoyama, S.; Fujiwara, T. The impact of liver transection depth on surgical difficulty in robotic versus laparoscopic limited liver resection (TAKUMI-5). *Langenbeck's Arch. Surg.* **2025**, *411*, 22. https://doi.org/10.1007/s00423-025-03916-0.
71. Mascherini, J.; Guidetti, C.; Al Harakeh, H.; Odorizzi, R.; Magistri, P.; Guerrini, G.P.; Sucandy, I.; Di Benedetto, F. Advanced robotic liver surgery. *Surg. Endosc.* **2026**, *40*, 6437–6448. https://doi.org/10.1007/s00464-026-13093-w.
72. Mirski, M.A.; Lele, A.V.; Fitzsimmons, L.; Toung, T.J. Diagnosis and treatment of vascular air embolism. *Anesthesiology* **2007**, *106*, 164–177. https://doi.org/10.1097/00000542-200701000-00026.
73. Zheng, B.; Zhao, R.; Li, X.; Li, B. Comparison of laparoscopic liver resection for lesions located in anterolateral and posterosuperior segments: A meta-analysis. *Surg. Endosc.* **2017**, *31*, 4641–4648. https://doi.org/10.1007/s00464-017-5527-8.
74. Sucandy, I.; Dugan, M.M.; Ross, S.B.; Syblis, C.; Crespo, K.; Kenary, P.Y.; Rosemurgy, A. Tampa Difficulty Score: A novel scoring system for difficulty of robotic hepatectomy. *J. Gastrointest. Surg.* **2024**, *28*, 685–693. https://doi.org/10.1016/j.gassur.2024.02.022.
75. Bansal, B.; Pattilachan, T.M.; Ross, S.; Christodoulou, M.; Sucandy, I. Implications of robotic platforms for repeat hepatectomies: A propensity score matched study of clinical outcomes. *Updates Surg.* **2025**, *77*, 447–454. https://doi.org/10.1007/s13304-025-02117-0.

76. Di Sandro, S.; Centonze, L.; Ratti, F.; Russolillo, N.; Conci, S.; Gringeri, E.; Ardito, F.; Colasanti, M.; Sposito, C.; De Carlis, R.; et al. Robotic vs laparoscopic resection for hepatocellular carcinoma: Multicentric propensity-score matched analysis of surgical and oncologic outcomes in 647 patients. *Updates Surg.* **2025**, *77*, 1451–1462. https://doi.org/10.1007/s13304-025-02293-z.
77. Ducas, A.; Cassiani, J.; Mendoza Medina, D.F.; Valle, V.; Giulianotti, P.C. Robotic Liver Resections: Current State-of-the-Art and Future Perspectives. *Curr. Surg. Rep.* **2025**, *13*, 36. https://doi.org/10.1007/s40137-025-00469-5.
78. Selim, M.; Dresscher, D.; Abayazid, M. A comprehensive review of haptic feedback in minimally invasive robotic liver surgery: Advancements and challenges. *Int. J. Med. Robot. Comput. Assist. Surg.* **2023**, *20*, e2605. https://doi.org/10.1002/rcs.2605.
79. Milivojev Covilo, K.; Pagano, S.J.; Ross, S.B.; Bilik, A.; Vanterpool, G.; Sucandy, I. Transforming robotic hepatectomy outcomes: A comparative analysis before and after ERAS protocol implementation. *Updates Surg.* **2025**, *77*, 2499–2504. https://doi.org/10.1007/s13304-025-02399-4.
80. Ceccarelli, G.; Catena, F.; Avella, P.; Tian, B.W.; Rondelli, F.; Guerra, G.; De Rosa, M.; Rocca, A. Emergency robotic surgery: The experience of a single center and review of the literature. *World J. Emerg. Surg.* **2024**, *19*, 28. https://doi.org/10.1186/s13017-024-00555-6.
81. Pauli, H.; Eladawy, M.; Park, J. Anesthesia for robotic thoracic surgery. *Ann. Cardiothorac. Surg.* **2019**, *8*, 263–268. https://doi.org/10.21037/acs.2018.12.06.
82. Rocca, A.; Porfidia, C.; Russo, R.; Tamburrino, A.; Avella, P.; Vaschetti, R.; Bianco, P.; Calise, F. Neuraxial anesthesia in hepato-pancreatic-bilio surgery: A first western pilot study of 46 patients. *Updates Surg.* **2023**, *75*, 481–491. https://doi.org/10.1007/s13304-022-01437-9.
83. Marte, G.; Scuderi, V.; Rocca, A.; Surfaro, G.; Migliaccio, C.; Ceriello, A. Laparoscopic splenectomy: A single center experience. Unusual cases and expanded inclusion criteria for laparoscopic approach. *Updates Surg.* **2013**, *65*, 115–119. https://doi.org/10.1007/s13304-013-0197-0.
84. St John, A.; Caturegli, I.; Kubicki, N.S.; Kavic, S.M. The Rise of Minimally Invasive Surgery: 16 Year Analysis of the Progressive Replacement of Open Surgery with Laparoscopy. *JSLS J. Soc. Laparosc. Robot. Surg.* **2020**, *24*, e2020.00076. https://doi.org/10.4293/jsls.2020.00076.
85. Giehl-Brown, E.; Khajeh, E.; Dehne, S.; Czigany, Z.; Gutzeit, O.; Neuhaus, C.; Riediger, C.; Birgin, E.; Rahbari, N.; D©Hondt, M.; et al. High versus low pneumoperitoneum PressUre for parenchymal transection in minimally invasive major liver surgery (PPULS)-a non-inferiority, multicenter, randomized, controlled trial. *Trials* **2025**, *26*, 556. https://doi.org/10.1186/s13063-025-09269-9.

Disclaimer/Publisher's Note: The statements, opinions and data contained in all publications are solely those of the individual author(s) and contributor(s) and not of MDPI and/or the editor(s). MDPI and/or the editor(s) disclaim responsibility for any injury to people or property resulting from any ideas, methods, instructions or products referred to in the content.