cosmetics

MDPI

Hypothesis

N-ANCHOR: An Anatomy-Guided Hypothesis for Lateral Structural Support and Periligamentous Tissue Remodeling

Francesco Marchetti [1,*] and Giuseppe Colombo [2]

[1] Casa di Cura "Villa Mafalda", Via Monte Delle Gioie 5, 00199 Rome, Italy
[2] Private Practice Clinic, Sant'Anna, 6924 Lugano, Switzerland; chirurgia.colombo@gmail.com
* Correspondence: drfrancescomarchetti@gmail.com

Abstract

Injectable facial rejuvenation has often been framed primarily as the replacement of lost volume. This article proposes N-ANCHOR, an anatomy-guided framework that interprets facial aging as a redistribution of structural support across the facial skeleton, retaining ligaments, superficial musculoaponeurotic system, fat compartments, and skin. Based on published anatomical, biomechanical, and mechanobiological evidence combined with clinical reasoning, the framework introduces four proposed operational support zones (Zygomatic Bioline, Masseteric Frame, Temple Bioanchor, and Preauricular Lock) and proposes the periligamentous connective-tissue environment, rather than the ligament fiber itself, as the injectable target. A lateral-before-medial sequence that avoids primary central overfilling is organized into three severity-based tiers (Prevent, Rebalance, and Rebuild), combining a superficial hyaluronic acid (HA)-based component, a crosslinked HA/calcium hydroxyapatite formulation placed in defined subcutaneous and temporal planes, and, in advanced cases, supraperiosteal crosslinked HA. Proposed injection planes, instruments, and principal neurovascular safety considerations are outlined for the core treatment zones. The central propositions, that lateral-first treatment reduces subsequent medial volume requirements, alters lateral soft-tissue position, and induces measurable periligamentous tissue remodeling, are presented as testable hypotheses requiring prospective validation with standardized imaging, validated outcome measures, and systematic adverse-event reporting.

Keywords: facial rejuvenation; retaining ligaments; hyaluronic acid; calcium hydroxyapatite; extracellular matrix; facial aging; biostimulation

Check for updates

Academic Editor: Enzo Berardesca

Received: 6 October 2026
Revised: 24 November 2026
Accepted: 24 November 2026
Published: 26 November 2026

Copyright: © 2026 by the authors. Licensee MDPI, Basel, Switzerland. This article is an open access article distributed under the terms and conditions of the Creative Commons Attribution (CC BY) license.

1. Introduction: Structural Support Before Central Volume

Injectable rejuvenation has frequently been approached as a problem of deflation, in which lost volume is replaced. Several established approaches, however, already integrate facial anatomy, structural support, and treatment sequencing, including layer-by-layer treatment of anatomical aging changes [1], ligament-oriented lateral-before-medial injection [2], and systematized anatomy-based injection methods such as the MD Codes [3]. N-ANCHOR builds on these approaches from a structural premise. The face can be understood as a layered soft-tissue envelope whose position is organized by interactions among the facial skeleton, retaining structures, fat compartments, superficial musculoaponeurotic system (SMAS), retinacula cutis, and skin. Within this model, jowling, nasolabial deepening, mid-cheek furrowing, and temporal hollowing are not read as isolated volume deficits, but as visible surface expressions of a deeper redistribution of support across these interconnected layers.

This redistribution is often described clinically as the "inversion of the triangle of youth": a youthful face has its widest and most projected point high at the cheekbones, whereas an aged face becomes relatively wider in the lower third. Retaining structures contribute importantly to maintaining spatial relationships between mobile soft-tissue compartments and their deeper attachments [1,4–6]. As skeletal anchorage, fat distribution, and the surrounding connective-tissue network change with age, the mechanical balance across these interfaces is altered and soft-tissue descent becomes clinically apparent. In this sense, the visible face can be read as a structural map of where fixed and mobile tissues are no longer interacting in the same way they did earlier in life.

N-ANCHOR therefore does not start centrally. It follows a "no central overfilling" principle: address lateral, ligament-defined support zones first and treat the central midface only if a clinically relevant volume deficit remains. This sequence is supported by preliminary clinical evidence. In a split-face study, treating lateral injection points first significantly reduced the filler volume subsequently required at medial sites and reduced total injected volume while achieving comparable aesthetic outcomes [2]. This evidence should be interpreted with caution: the study included 12 patients, the lateral-first sequence was applied to the same facial side in every patient rather than allocated at random, and the aesthetic rating scores did not differ between sides, so that the observed benefit concerns injected volume rather than aesthetic outcome. Moreover, the study addresses injection sequencing only. It does not validate the specific products, the tier structure, or the regenerative mechanism proposed here. N-ANCHOR adopts this lateral-before-medial sequencing as a working principle but does not claim it as novel. Its proposed contribution lies elsewhere: (i) the operational definition of the periligamentous connective-tissue environment adjacent to ligament-defined regions as a candidate treatment target, without asserting that this environment can be separated from adjacent fat and septal tissue in vivo, (ii) an operational nomenclature for four lateral support zones, and (iii) a severity-based tier structure linking these zones to specific products and injection planes. Each of these elements is a proposal for prospective evaluation rather than an established clinical standard.

The framework can be summarized in four steps:

- Treat the lateral support system first.
- Target the periligamentous environment at key structural support zones.
- Reassess central volume only after lateral support has been addressed.
- Correct residual central deficits conservatively, avoiding primary overfilling of the central cheek, tear trough, or nasolabial fold.

2. A Conceptual Layered Model of Structural Support

Facial aging is not a single-layer event. It reflects interacting changes from bone to skin [1]. N-ANCHOR uses the retaining-ligament system as an organizational framework because it forms a mechanical interface between deeper structures and the superficial soft-tissue envelope. The concept is not that one layer ages in isolation, but that changes in one layer alter the relationships among the others (Table 1). The model is conceptual rather than strictly stratigraphic: its components do not form five discrete sequential planes. Retaining ligaments traverse several layers on their course from bone or deep fascia to the dermis, and fat occupies both superficial and deep compartments separated by the SMAS. Table 1 therefore lists interacting structural components, not five separate surgical or injection planes. The therapeutic implications of this, including why the periligamentous connective-tissue environment rather than the ligament core is the proposed injectable target, are developed in Section 4.

Table 1. Conceptual model of interacting structural components in facial aging, adapted from Kapoor et al. [1] and Distefano et al. [6]. The listed components overlap and should not be interpreted as sequential anatomical or injection planes.

Model Component	Structure	Dominant Aging Change
Facial skeleton	Facial skeleton (orbital rim, maxilla, pyriform aperture, pre-jowl mandible)	Site-dependent skeletal remodeling can modify the geometry of adjacent soft-tissue attachments; temporal causality for ligament displacement has not been established
Retaining connective-tissue network	Retaining ligament system (osteocutaneous + fasciocutaneous)	Relatively limited intrinsic fiber change described in anatomical literature; functional compromise may occur secondary to skeletal and soft-tissue remodeling
SMAS and muscle	SMAS/mimetic and masticatory muscle layer	Laxity, altered vector transmission with repetitive movement
Fat compartments (superficial and deep)	Deep and superficial fat compartments	Regional changes in superficial and deep fat compartments, which are not a single sequential layer
Skin and retinacula cutis	Skin/dermis/retinacula cutis	Skin aging and possible age-related change in the retinacular network; direct longitudinal evidence of fiber stretching is limited

SMAS, superficial musculoaponeurotic system.

A clinically relevant implication of this model concerns sequencing. Bone resorption at specific sites (the superomedial and inferolateral orbital rim, the maxilla, the pyriform aperture, and the pre-jowl mandible) has been proposed to contribute to the repositioning of the ligaments that originate from that bone [1,6], although direct longitudinal evidence that skeletal change precedes and causes ligament repositioning in humans is lacking. Skeletal change itself, however, is measurable. Facial bone remodeling has been reported in both sexes from as early as the third decade of life and continues throughout adulthood, with considerable regional and individual variability in onset and magnitude. It tends to follow a site-specific pattern: a reduction in the glabellar angle, a reduction in the maxillary angle, an enlargement of the pyriform aperture, and a retrusion of the pre-jowl mandible and bony chin, alongside blunting of the mandibular angle [1]. Imaging-based work has further characterized this as a net "clockwise rotation" of the facial skeleton in profile, with the upper face rotating posteriorly relative to the lower face, which reframes skeletal aging as a directional, vectorial process rather than uniform shrinkage [7].

Within this framework, intrinsic ligament-fiber failure is not assumed to be the initiating event. Selective remodeling of the maxilla and mandible can alter the osseous origin and effective course of the zygomatic and mandibular retaining structures [1,6]. Even when the principal ligament fibers remain relatively preserved, changes in skeletal anchorage and the surrounding soft-tissue environment may reduce the efficiency of force transmission. The resulting clinical picture can therefore be understood as functional loss of support without requiring primary material failure of the ligament fiber.

Reduced efficiency of ligament-defined support is accompanied by compartment-specific deflation and displacement of superficial and deep fat. These changes are neither uniform nor simultaneous. Lateral and middle cheek changes may become clinically evident earlier than more advanced malar deflation [1]. This variability supports severity-based rather than age-defined treatment selection.

Visible landmarks of facial aging often correspond to transitions between relatively fixed ligamentous insertions and more mobile surrounding tissue. The mid-cheek furrow at the zygomatic cutaneous ligament is a representative example, while adjacent less-anchored

regions may display greater displacement and fold formation, including the nasolabial fold, malar mound, and pre-jowl sulcus [6]. These surface changes can therefore be interpreted as a topographic expression, a structural map of aging, in which regional differences in retaining architecture become visible at the skin surface rather than appearing as a uniformly distributed process.

3. The Retaining Ligament System in Detail

3.1. True Ligaments vs. Septa and Adhesions

The nomenclature and classification of facial retaining structures remain inconsistent: descriptions, classifications, and terminology vary across anatomical studies [6,8]. Some authors classify a broader set of fibrous structures as retaining ligaments, whereas others distinguish true osteocutaneous or fasciocutaneous ligaments from septa and adhesion zones [6]. N-ANCHOR therefore adopts an operational classification, described below, which should not be read as universally accepted anatomical terminology. Under this classification, not every fibrous structure in the face is treated as a true retaining ligament. The distinction rests on a specific anatomical criterion. Each true ligament is rooted in a tree-like, cylindrical arrangement of fibrous tissue that divides as it approaches the SMAS and inserts directly into the dermis. This branching terminal network is the retinacula cutis [6]. Within N-ANCHOR, the distinction is used to guide where a biostimulatory protocol is proposed to be targeted:

- True retaining ligaments: strong, tree-like condensations of fibrous tissue that originate from periosteum (osteocutaneous ligaments) or deep fascia (fasciocutaneous ligaments) and insert directly into the dermis. Zygomatic and mandibular ligaments are the clearest examples [5,6].
- Septa and adhesions, including much of the temporal and periorbital fibrous network, do not meet this criterion: they act on the SMAS directly and on the dermis only indirectly, through the retinacula cutis. They are not classified as true ligaments, though they behave similarly at a clinical level [6].

N-ANCHOR adopts the stricter dermal-insertion-based definition for its primary midface landmarks because this creates a more direct anatomical rationale for targeting the surrounding connective-tissue environment. Septa and adhesion zones remain clinically relevant, but they are not assumed to provide the same type of direct dermal linkage.

3.2. The Zygomatic–Masseteric Complex: The Primary N-ANCHOR Target

The zygomatic cutaneous ligament originates from the periosteum of the maxilla and zygoma, above the origin of levator labii superioris, and runs infero-laterally along the curvature of the inferior zygomatic margin. Its fibers envelop the origin of zygomaticus minor and continue laterally to the origin of zygomaticus major, tracking the entire length of the zygomatic arch as the zygomatic retaining ligament, referred to here by the proposed operational name Zygomatic Bioline [5].

Detailed cadaveric mapping has shown that this is not a single uniform band but a complex that can be divided into four continuous segments: a medial portion near the origin of levator labii superioris, a segment extending caudally toward the inferior maxillary margin, a segment enveloping the origins of zygomaticus minor and major, and, laterally, the zygomatic retaining ligament proper along the arch [5]. In the measurement series of that study (18 hemifaces from Han Chinese donors; 36 hemifaces were dissected in total), the mean ± SD vertical distances from the Frankfort horizontal line to the ligament along five predefined reference lines (L1–L5) were 9.1 ± 2.5 mm (range 5–12), 19.5 ± 2.3 mm (15–24), 22.1 ± 1.9 mm (20–26), 21.7 ± 3.4 mm (16–28), and 18.7 ± 2.6 mm (15–24), respectively [5].

Individual values thus differed by up to 12 mm along a single reference line, and the original authors identified the small, single-ethnicity sample as a limitation. These values describe a cadaveric sample. They are not patient-specific coordinates or evidence of a safe injection trajectory, and individual anatomy must therefore be assessed independently.

This anatomical relationship is clinically important because the zygomatic branch of the facial nerve and the transverse facial artery course in close relation to the zygomatic ligamentous complex before continuing toward the anteromedial midface [5]. The same complex also contributes to compartment boundaries between the prezygomatic, premaxillary, and deep lateral cheek regions [5]. The zygomatic ligament-defined zone is therefore simultaneously a structural, compartmental, and neurovascular landmark, making explicit plane and depth control essential.

The masseteric cutaneous ligaments, termed the Masseteric Frame within N-ANCHOR, arise as condensations of the deep fascia over the masseter. Their exact origin is debated, but anatomical studies consistently describe a T-shaped relationship with the zygomatic ligamentous complex. A particularly dense and mechanically relevant junction near the origin of zygomaticus major, approximately 40 mm medial to the tragus (reported without variability in the cadaveric series [5]), corresponds to the region classically described as McGregor's patch [5,6].

McGregor's patch is also a recognized surgical landmark in contemporary midface dissection [5]. Within N-ANCHOR, the patch and adjacent lateral zygomatic arch are therefore used as reproducible structural landmarks in the Rebuild tier. Their selection reflects the convergence of the zygomatic and masseteric retaining systems rather than the assumption that a single point controls global midface support.

Primary biomechanical testing of osteocutaneous retaining ligaments in 10 cadaveric hemifaces found that the zygomatic ligament had the greatest stiffness and resistance to failure among the tested structures, while the buccomaxillary ligament exhibited the lowest percentage elongation [9]. Although these observations are compatible with the possibility of regionally different mechanical behavior, the relationship between ex vivo ligament properties and the chronology of visible facial descent has not been demonstrated prospectively. The zygomatic ligament's contribution to malar tissue suspension also depends on the extent and configuration of its dermal attachments [6]. Variation in these relationships supports individualized anatomical assessment, but does not itself validate a specific injection target or treatment tier.

3.3. How Ligament-Defined Support Changes with Age

Within N-ANCHOR, age-related support change is not assumed to arise from ligament-fiber failure alone. Relevant changes include:

- As described above, selective skeletal remodeling can shift the origin and anchoring environment of retaining structures [1,6].
- Changes may also involve the fine retinacula cutis fibers that branch from the ligament through the subcutaneous layer to the dermis. These thinner fibers are likely to be mechanically weaker and more exposed to repetitive movement. Imaging–histology work has associated a sparser retinacula cutis network with lower subcutaneous elasticity and more pronounced facial sagging [10], although direct longitudinal evidence of age-related stretching of these fibers in humans is limited.
- Ligaments in more mobile zones (for example, the masseteric ligaments below the oral commissure) have been described as showing more pronounced age-related change than those in more stable zones (the upper masseteric ligaments, which show minimal change) [1]. Differences in mechanical loading have been proposed as a contributing factor, although intrinsic regional differences in ligament tissue have not been excluded.

These observations support assessment of the connective-tissue environment around ligament-defined support zones. The therapeutic rationale is developed in Section 4 and remains hypothesis-generating rather than clinically demonstrated.

An alternative view is supported by an experimental animal study reporting age-related thickening of the zygomatic ligament and an increased collagen type I/III ratio, suggesting greater stiffness and reduced elasticity [11]. Because this evidence derives from a rat model, its relevance to human facial retaining ligaments remains uncertain. N-ANCHOR therefore treats intrinsic ligament aging as an open question rather than as an established primary mechanism.

3.4. Clinical Translation of Regional Landmarks

The zygomatic–masseteric line provides a practical anatomical reference for the lateral-before-medial sequence described in Section 1 [2]. The Temple Bioanchor is used as a regional support landmark rather than as a true retaining ligament. Product-specific temporal injection planes are defined in Section Product Rationale and Injection Planes and addressed from a safety perspective in Section 6 [12].

3.5. The Preauricular Lock: Extending the System Posteriorly

In the Prevent tier, the anatomical targets comprise McGregor's patch, located at the junction of the Zygomatic Bioline and Masseteric Frame, and the posterior Preauricular Lock. Furnas described the platysma-auricular ligament as arising from parotid fascia and anchoring the posterior platysma to preauricular skin [4], whereas later authors have used broader descriptions including parotid cutaneous ligament and platysma-auricular fascial adhesion [6]. N-ANCHOR therefore treats this region as a distributed posterior support zone rather than as a single high-load support zone equivalent to McGregor's patch.

3.6. Proposed N-ANCHOR Support-Zone Nomenclature

The four anatomical regions described above are assigned proposed operational names, which are used consistently throughout the protocol (Table 2). These names are working terms introduced by the authors and are not part of standard anatomical terminology. Because each target represents a distributed anatomical region rather than a discrete point, the term 'zone' is used for treatment targets, 'line' refers to the linear course of a ligament (as in the Zygomatic Bioline), and 'point' is reserved for individual injection sites. Elements such as 'Bioline', 'Frame', 'Bioanchor', and 'Lock' are parts of these proposed names only. 'Anchor' is not used as a separate technical term.

Table 2. Proposed N-ANCHOR support-zone nomenclature (operational terms) and the underlying anatomical basis.

N-ANCHOR Name	Anatomical Basis
Zygomatic Bioline	Zygomatic cutaneous ligament and zygomatic retaining ligament, along the inferior zygomatic margin and the full length of the arch
Masseteric Frame	Masseteric cutaneous ligaments; T-junction with the Zygomatic Bioline at McGregor's patch
Temple Bioanchor	Temporal support region; superficial temporal fat compartment for Stimulate, with a separate supraperiosteal point when Intense is used in Rebuild
Preauricular Lock	Platysma-auricular ligament/fascia; parotid cutaneous attachment

4. The Periligamentous Environment as the Proposed Therapeutic Target

N-ANCHOR does not claim to mechanically tension or strengthen the ligament fibers themselves and does not advocate direct intraligamentous injection. Its proposed target

is the connective-tissue environment surrounding ligament-defined support zones, the periligamentous extracellular matrix (ECM), where a filler with proposed biostimulatory properties might influence hydration, matrix organization, and fibroblast–matrix interaction. This proposed target should not be interpreted as a separately delineated anatomical compartment or as a proven site of functional regeneration.

For the purposes of this hypothesis, the periligamentous environment is defined operationally as the connective tissue immediately surrounding a true retaining ligament along its course from its osseous or fascial origin toward the dermis, including the proximal branching of the retinacula cutis within the superficial fat and the adjacent fibrous septa that bound neighboring fat compartments. It excludes the ligament core, which is not injected, and the dermis. Within the proposed protocol, this environment is approached from the deep subcutaneous plane adjacent to the ligament. Its spatial extent has not been defined histologically and is likely to vary between regions and individuals. Correspondingly, 'periligamentous bio-regeneration' is used here as a hypothesis-level term for a sustained, organized remodeling of this environment (structurally organized collagen deposition with preserved tissue architecture and improved local mechanical properties) that persists beyond the expected residence time of the injected material. Increased hydration, greater tissue thickness, or collagen deposition alone would not be sufficient to demonstrate regeneration or restored mechanical function. Demonstrating the proposed effect would require concordant evidence of tissue organization (e.g., histology in preclinical models), mechanical change (e.g., elastography), and durable soft-tissue position change after the injected material has degraded. Throughout this manuscript, 'bio-regeneration', 'periligamentous remodeling', and 'biostimulation' denote proposed biological mechanisms, and 'structural support', when used to describe a treatment objective, denotes an intended goal. None of these terms describes a clinically demonstrated effect of the protocol. When used in an anatomical sense, 'structural support' refers to the established role of the facial skeleton and retaining structures.

The rationale draws on dermal mechanobiology, that is, on studies of human skin and dermal fibroblasts rather than of periligamentous tissue. Aging fragments the collagen network and reduces the mechanical force fibroblasts can transmit against it. Reduced fibroblast spreading and mechanical force activate c-Jun/activator protein-1 (AP-1) signaling and increase matrix metalloproteinase-1 (MMP-1) expression, promoting collagen fibril fragmentation, while reduced fibroblast size and force down-regulate transforming growth factor-β (TGF-β) type II receptor expression and TGF-β-driven collagen synthesis. Together, these processes contribute to a self-reinforcing cycle of matrix decline [13–15]. Whether the same mechanisms operate in the periligamentous connective tissue has not been examined.

Evidence from dermal fibroblast mechanobiology and calcium hydroxyapatite (CaHA) studies provides a biologically plausible, but indirect, rationale for local ECM remodeling [13–16]. The CaHA experiments of Nowag et al. involved Radiesse (Merz) and should not be treated as direct evidence for Neauvia Stimulate [16]. In a separate in vitro study, Zerbinati et al. tested Neauvia Stimulate (poly(ethylene glycol) diglycidyl ether (PEGDE)-crosslinked hyaluronic acid (HA), 26 mg/mL, containing 1% CaHA, as reported for the tested product lot) and observed increased soluble collagen production in cultured human fibroblasts [17]. This is a cell-culture endpoint, not evidence of tissue-level regeneration. Separately, a bench study compared 24 commercial HA fillers at 37 °C [18]. It included four PEGDE-crosslinked Neauvia fillers, among them Stimulate and Intense. These fillers retained solid-like behavior (storage modulus above loss modulus) up to strains of about 1000–1300%, among the highest in the series. Like most fillers tested, they recovered more than 85% of their initial storage modulus after a 500% step strain. These measurements describe the material outside tissue. Within the proposed "dual-core" framework, the HA

network is proposed to provide hydration and scaffold support, whereas CaHA microspheres are proposed to provide a complementary particulate stimulus, based on fibroblast activation and collagen-related activity observed in vitro [16,19]. Together, these observations are consistent with a mechanistic rationale for ECM remodeling [20]. However, they derive from cell culture, laboratory rheology, and a mixture of formulation-specific and non-matched material or tissue models, and they do not demonstrate an effect in human facial periligamentous tissue. Accordingly, their extension to the periligamentous environment within N-ANCHOR remains a hypothesis requiring prospective validation.

To make the evidential basis explicit, the proposed mechanism can be divided into sequential steps with different levels of support: (i) age-related loss of mechanical tension and collagen fragmentation in the ECM demonstrated in human skin and dermal fibroblast models [14,15], not studied in periligamentous tissue; (ii) fibroblast stimulation and increased collagen production in response to CaHA microspheres (Radiesse) [16] or PEGDE-HA/CaHA (Neauvia Stimulate) [17] demonstrated in fibroblast cultures, with collagen changes reported in human skin after subdermal injection of this formulation [20,21], but not studied in human facial periligamentous tissue; (iii) mechanical behavior of PEGDE-crosslinked HA fillers, including Stimulate and Intense, under laboratory deformation, shown by bench rheology of the material outside tissue [18], with in vivo persistence at N-ANCHOR sites not measured; (iv) translation of these responses into organized, functionally relevant remodeling of the periligamentous environment hypothetical; and (v) a resulting clinically meaningful and durable improvement in lateral soft-tissue support, hypothetical. Steps (iv) and (v) constitute the core propositions of N-ANCHOR and require direct validation. In particular, nonspecific collagen deposition, such as that associated with a foreign-body or fibrotic response, should not be equated with organized functional remodeling.

The potential durability of the HA scaffold contribution depends on the network's ability to maintain continuity under repeated deformation. Comparative bench rheology of 24 commercial HA fillers, including the Stimulate and Intense formulations used here, has characterized their deformation and recovery behavior [18]. These properties are conceptually relevant to a tissue environment exposed to repeated facial movement and mechanical loading, although they have not been measured directly at N-ANCHOR injection sites. Laboratory rheology characterizes the material outside the tissue and does not by itself predict in vivo persistence, tissue integration, or therapeutic benefit. Nor can rheological data be assumed to transfer between HA/CaHA formulations that differ in HA concentration, crosslinking, particle content, or manufacturing process.

Two distinct effects should also be distinguished. The crosslinked HA component exerts an immediate, predominantly mechanical and volumetric effect (space filling, tissue displacement, and hydration), whereas any contribution of CaHA to neocollagenesis would be expected to emerge later. Its time course has not been established at the sites proposed here. Two human studies provide tissue-level data for the PEGDE-HA/CaHA formulation. The first is an uncontrolled prospective study reported within a narrative review [20]. In it, 14 volunteers received a single subdermal injection of a PEGDE-crosslinked HA filler containing CaHA, glycine, and L-proline. Type I collagen immunostaining was unchanged at 1 month and stronger at 4 and 9 months. Dermal thickness on high-frequency ultrasound increased progressively over 9 months. Collagen types III, IV, and VII did not change. In the second study, five women received 1 mL of Neauvia Stimulate subdermally in abdominal skin before abdominoplasty [21]. A higher proportion of thin, newly formed collagen fibers was found at a single time point, 2 months after injection. Data also exist for a different CaHA-based filler (Radiesse). Newly formed collagen was reported in abdominal skin 2 months after subdermal injection [22]. After supraperiosteal injection in the postauricular

region, collagen type III expression was higher at 4 months and collagen type I expression at 9 months than with an HA filler [23]. All these studies were small and examined skin, not facial periligamentous tissue. Only [23] included a control (an HA filler). Within these limits, collagen changes appear to become detectable over months rather than weeks. A delay of months before any CaHA-related contribution at N-ANCHOR sites is therefore an extrapolation from these models and is treated here as a hypothesis. In the proposed protocol both mechanisms may contribute to the clinical outcome, and without objective assessment it is not possible to determine whether an observed improvement in tissue support results from volumization, from altered distribution of the injected material, or from ECM remodeling. Any claim of a biological effect would therefore require assessment at time points at which the volumetric contribution of the injected material can be accounted for.

Clinical outcomes of a different HA/CaHA hybrid formulation have been assessed longitudinally with two- and three-dimensional (2D/3D) photography, ultrasound, and elastography [24], supporting the feasibility of objective imaging in this setting. Each method, however, has specific capabilities and limitations. Standardized 2D/3D photography can quantify surface contour, volume, and soft-tissue position but provides no information on tissue composition. High-frequency ultrasound can show the injected material, its plane and distribution, and changes in dermal and subcutaneous thickness and echogenicity [25,26], but it is operator-dependent and cannot reliably distinguish residual filler from newly formed connective tissue. Elastography can estimate tissue stiffness, and high intra-rater reproducibility has been reported for shear-wave elastography of facial skin [27], but measurements are influenced by probe pressure, depth, and the presence of injected material, and changes in stiffness are not specific to collagen remodeling. These methods can therefore document volume, position, or mechanical change, but none can independently demonstrate regeneration or establish the proposed mechanism. Distinguishing persistent filler from biological remodeling requires repeated measurements beyond the expected degradation period of the product, ideally complemented by histological evidence from preclinical models.

For the purposes of validation, residual injected material would be assessed at every follow-up visit by high-frequency ultrasound of each treated site, using a standardized protocol (fixed transducer frequency and settings, minimal probe pressure, predefined anatomical landmarks, and side-by-side comparison with the baseline and immediate post-injection images of the same site) and, where feasible, a reader blinded to the time point. HA deposits typically appear as anechoic or hypoechoic pseudocystic structures, whereas CaHA appears as hyperechoic deposits that may show posterior acoustic shadowing [25]. How the low CaHA content of the formulations proposed here affects their sonographic appearance over time has not been characterized. Each site would be classified as residual material present, residual material not detected, or indeterminate. Non-detection is not proof of clearance, because small, dispersed, or tissue-integrated deposits may fall below the resolution of the method or become indistinguishable from the surrounding tissue. Inconclusive imaging therefore limits interpretation: where residual material is present or the examination is indeterminate, sustained tissue displacement or a change in stiffness at that site cannot be attributed to tissue remodeling. Such findings would be reported as ‘effect observed with residual material present’ when filler is detected at the site and as ‘mechanism indeterminate’ when imaging is inconclusive. Neither label implies that residual material causes the persistent displacement or altered stiffness. Each indicates only that a contribution of the material cannot be excluded. Only sites without detectable material on repeated examinations would be regarded as compatible with a tissue-level effect and, in the absence of histological confirmation, even these would be supportive rather than conclusive.

5. N-ANCHOR Protocol Architecture

The protocol is organized in three tiers that escalate primarily with the severity and distribution of structural support loss rather than chronological age. The tiers are intended to represent a progression from preservation of existing architecture, through rebalancing of clinically evident support change, to selective reconstruction of deeper structural deficits. Age ranges are illustrative clinical context, not prescriptive treatment thresholds. At present, tiers are assigned by clinical assessment of the profiles summarized in Table 3. No validated scale cutoffs define them (Section 7). The classification criteria, product volumes, and injection strategies of all three tiers are preliminary proposals of the authors and should not be interpreted as validated clinical recommendations. When a patient's findings correspond to different tiers, the higher tier applies. The tiers are cumulative: each higher tier includes the components of the lower tiers, although any component may be omitted when the corresponding region does not require treatment. The protocol combines a superficial HA-based component used intradermally (Neauvia Hydro Deluxe, Matex Lab S.p.A., Brindisi, Italy), PEGDE-HA/CaHA-based periligamentous treatment (Neauvia Stimulate, Matex Lab S.p.A., Brindisi, Italy), and, in the most advanced tier, selected deep structural volumization with PEGDE-crosslinked HA (Neauvia Intense, Matex Lab S.p.A., Brindisi, Italy). The proposed three-tier treatment sequence is summarized in Table 3 and Figure 1. The tissue planes targeted by each product, relative to a true retaining ligament and the proposed periligamentous target zone, are shown schematically in Figure 2. Other HA/CaHA hybrid formulations, or CaHA and other biostimulatory fillers used alone or combined with HA, could in principle be considered for the same targets. The framework has been developed with the formulations listed above, and whether its rationale extends to other products with comparable properties remains to be tested.

Table 3. N-ANCHOR severity-based three-tier protocol, anatomical targets, products, and injection planes.

Tier	Clinical Profile	Product/Volume	Anatomical Target	Technique
PREVENT Proposed objective: early support preservation	Preserved global architecture; mild lateral support change; good skin quality. Illustrative age range: 30–45 years.	Neauvia Stimulate × 1 syringe (1 mL; 0.5 mL per side)	Periligamentous environment at McGregor's patch, with the Preauricular Lock as a posterior support zone.	Deep subcutaneous plane adjacent to the defined support zones. A 22-G cannula; ≈0.1 mL per line along five lines per side, 0.5 mL per side in total (McGregor's patch and Preauricular Lock; Figure 1A). [a,c] Same protocol bilaterally.
REBALANCE Proposed objective: rebalancing of lateral support	Clinically evident midface descent, early mandibular instability, and moderate loss of lateral structural support. Illustrative age range: 40–55 years.	Neauvia Stimulate × 2 syringes (1 mL each; usually 1.0 mL per side); Neauvia Hydro Deluxe × 1 syringe (2.5 mL; 1.25 mL per side; intradermal)	Prevent targets plus the zygomatic periligamentous environment and the Temple Bioanchor regional support zone.	Midface and lower face, including the Prevent targets: 0.5–0.7 mL per side of Stimulate, 22-G cannula-based linear threading with fanning along the Zygomatic Bioline. [a,c] Temple: 0.3–0.5 mL per side of Stimulate using three to four retrograde threads in the superficial temporal fat compartment above the superficial temporal fascia. [a,c] Hydro Deluxe: intradermal, 30-G needle, over the areas treated with Stimulate. [a,c,d]

Table 3. *Cont.*

Tier	Clinical Profile	Product/Volume	Anatomical Target	Technique
REBUILD Proposed objective: reinforcement of deep structural support	Advanced multi-compartment descent with marked structural support loss. Illustrative age range: ≥50 years.	Neauvia Stimulate × 2 syringes (1 mL each; usually 1.0 mL per side, allocated as in Rebalance); Neauvia Hydro Deluxe × 1 syringe (2.5 mL; 1.25 mL per side); Neauvia Intense × 1 syringe (1 mL; 0.5 mL per side), or 2 syringes when the deep pyriform space is treated	Rebalance targets plus core structural landmarks: zygomatic–masseteric junction (McGregor's patch/Masseteric Frame), adjacent zygomatic arch, and Temple Bioanchor. An adjunct supraperiosteal point in the deep pyriform space may be added when clinically indicated.	Neauvia Intense is proposed for delivery with a 27-G needle (the IFU recommends a 22-G cannula) as supraperiosteal boluses of ≈0.2 mL at the anterior temple (Temple Bioanchor) and ≈0.3 mL at the zygomatic arch per side, divided between two points (≈0.15 mL each), with 0.2–0.4 mL per side in the deep pyriform space only when clinically indicated. [b,c,d] Neauvia Stimulate remains cannula-based (22 G) in the specified subcutaneous and temporal planes [a,c]; Hydro Deluxe remains a superficial intradermal component (30-G needle). [a,c,d]

Note: The proposed age ranges, tier thresholds, treatment volumes, and injection parameters are derived from the authors' clinical experience and anatomical rationale and should be regarded as proposed clinical parameters for prospective evaluation rather than validated treatment cutoffs. Tier names and objectives denote intended treatment goals, not demonstrated outcomes. The tiers are cumulative: Rebalance includes the Prevent targets and Rebuild includes the Rebalance targets. Any component may be omitted when the corresponding region does not require treatment. Per-line volumes are kept to small aliquots (≈0.1 mL), in line with the small-aliquot principle described in Section 6. In Rebalance and Rebuild, the Stimulate allocations for the midface and lower face and for the temple vary jointly. Together they usually total 1.0 mL per side (e.g., 0.7 + 0.3 mL or 0.5 + 0.5 mL). This total already includes the retained Prevent targets, which are treated within the midface and lower-face allocation. All volumes are indicative and adjusted to the individual patient. When clinically required, more than 1.0 mL of Stimulate per side may be given, with an additional syringe if needed. The total remains within the maximum daily dose stated in the manufacturer's instructions for use (4 mL for a 60-kg patient). Clinical-profile terms are defined as follows: early mandibular instability, early loss of jawline definition with incipient jowling, the jawline still continuous at rest; moderate loss of lateral structural support, visible descent and hollowing of the lateral cheek, with a mid-cheek furrow and deepening nasolabial fold, and malar projection still preserved with initial leveling; advanced multi-compartment descent, established jowls with an interrupted jawline, deep nasolabial and mid-cheek folds, malar flattening, and temporal hollowing. Relationship to the manufacturers' instructions for use (IFUs) [28–30]. Superscript letters in the Technique column assign each product–site–plane entry to one or more of the following categories. For every entry, the general indication (temporary correction of soft-tissue atrophy of the face) and the injection plane are those specified in the respective IFU. Categories (b)–(d) identify what the authors have chosen beyond the IFU. (a) General indication, plane, and instrument as specified in the IFU: Hydro Deluxe by intradermal injection with a 30-G needle in the face [28] and Stimulate by subdermal injection with a 22-G cannula in the face [29]. (b) General indication and plane as specified in the IFU, but instrument and technique chosen by the authors and differing from the IFU: supraperiosteal Intense delivered as a bolus with a 27-G needle, whereas the IFU recommends a 22-G cannula and retrograde injection [30]. (c) Choices of the authors not specified in the IFUs, which indicate treatment of the face without naming individual sites: the selection of the sites (McGregor's patch, Preauricular Lock, Zygomatic Bioline, Temple Bioanchor, zygomatic arch, and deep pyriform space), periligamentous targeting, the number, direction, and fan arrangement of cannula threads, the distribution of volume per site and per tier, the lateral-before-medial sequence, and tier assignment. (d) Outside the IFUs when 'area' is read as anatomical region: the use of more than one product in the same region in one session, each in a different tissue plane (Hydro Deluxe over areas treated with Stimulate, and Stimulate with Intense in the temporal and zygomatic-arch regions). Each IFU lists among its contraindications 'Do not inject in patients already treated with temporary or permanent fillers in the same area', and none addresses combined use. Section Product Rationale and Injection Planes gives the authors' interpretation of this contraindication for same-session use. The volume of each product per session is within the maximum suggested in its IFU.

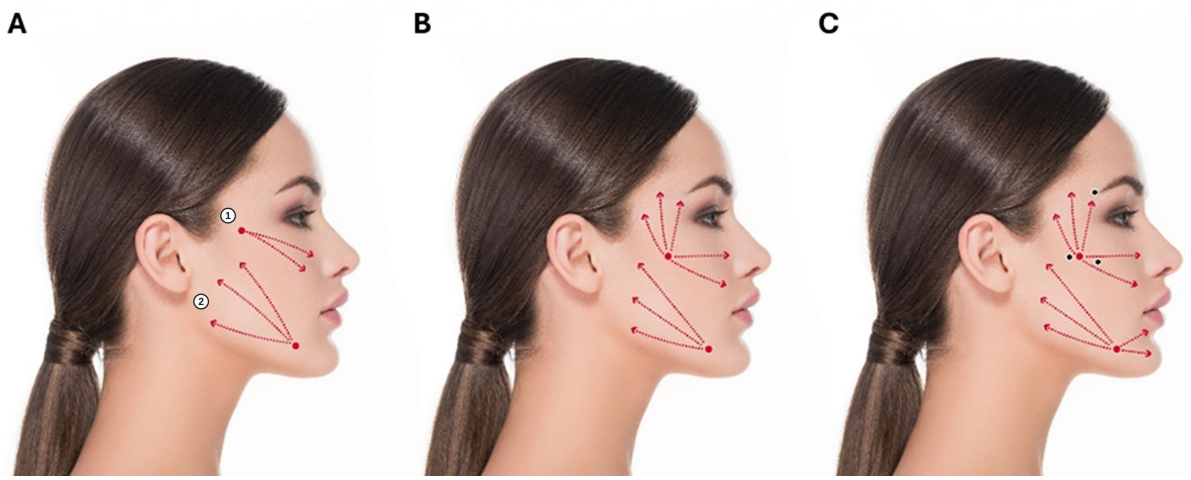

Figure 1. Conceptual surface illustration of the N-ANCHOR three-tier protocol. (**A**) Prevent: deep subcutaneous cannula-based treatment with Neauvia Stimulate at McGregor's patch (1; junction of the Zygomatic Bioline and Masseteric Frame) and the Preauricular Lock (2). (**B**) Rebalance: Neauvia Stimulate along the Zygomatic Bioline with additional treatment of the Temple Bioanchor in the superficial temporal fat compartment. (**C**) Rebuild: Neauvia Stimulate is combined with selected supraperiosteal boluses of Neauvia Intense. Black dots indicate Intense injection sites. The tiers are cumulative: the fan from the mandibular entry point shown in panels (**B**,**C**) corresponds to the Prevent treatment of the Preauricular Lock, which is retained in the higher tiers. Red dots and dotted arrows indicate cannula entry points and treatment vectors. The base photograph is a licensed stock image (LIGHTFIELD STUDIOS/stock.adobe.com, asset no. 199117285). The treatment markings were added on the authors' instructions to illustrate the proposed injection strategy. Entry points and vectors are shown as surface projections only. They do not depict tissue depth, fascial relationships, or neurovascular structures, and they do not define patient-specific injection sites, which must be determined by individual anatomical assessment. The figure cannot be used to establish safe injection locations. Tissue planes are shown in cross-section in Figure 2B.

Product Rationale and Injection Planes

Copies of the manufacturers' instructions for use (IFUs) of the three products [28–30] are available from the corresponding author on request. The IFU section supporting each statement below is given in parentheses. According to its IFU, Neauvia Hydro Deluxe is a non-crosslinked HA hydrogel containing sodium hyaluronate 18 mg/mL, glycine, L-proline, and CaHA (Description, Composition). It is supplied in prefilled 1.0-mL or 2.5-mL syringes (Description). The stated intended use is 'the temporary correction of the sign of primary soft tissue senile atrophy of the face and neck with intradermal injection' (Intended Use), and the recommended instrument is a 30-G needle (Preparing for Treatment). The IFU also refers to injection 'into the dermis and epidermis' (Indications). It states that pre-clinical and clinical studies, which it does not identify, showed a mean degradation time of two weeks (Indications) [28]. This is a manufacturer-reported value, not an independently measured in vivo persistence. Within N-ANCHOR, it is used intradermally as a superficial adjunct intended to address skin quality.

The IFU describes Neauvia Stimulate as a crosslinked HA hydrogel containing sodium hyaluronate 26 mg/mL, glycine, L-proline, and CaHA, provided in a 1.0-mL prefilled syringe (Description, Composition). Its intended use is 'the temporary correction of the sign of primary soft tissue senile atrophy of the face' (Intended Use). It specifies injection 'into the subdermis and/or over the periosteum' (Indications). It reports a mean degradation time of six months, attributed to pre-clinical and clinical studies that it does not identify (Indications). It recommends a 22-G cannula (Preparing for Treatment) and the retrograde sliding injection technique (Treatment Procedure) [29]. Within N-ANCHOR,

it is placed subdermally adjacent to ligament-defined support zones and, separately, in the superficial temporal fat compartment. An in vitro study reported 1% CaHA for the Stimulate formulation tested in that experiment [17]. The IFU does not state a CaHA percentage (Composition).

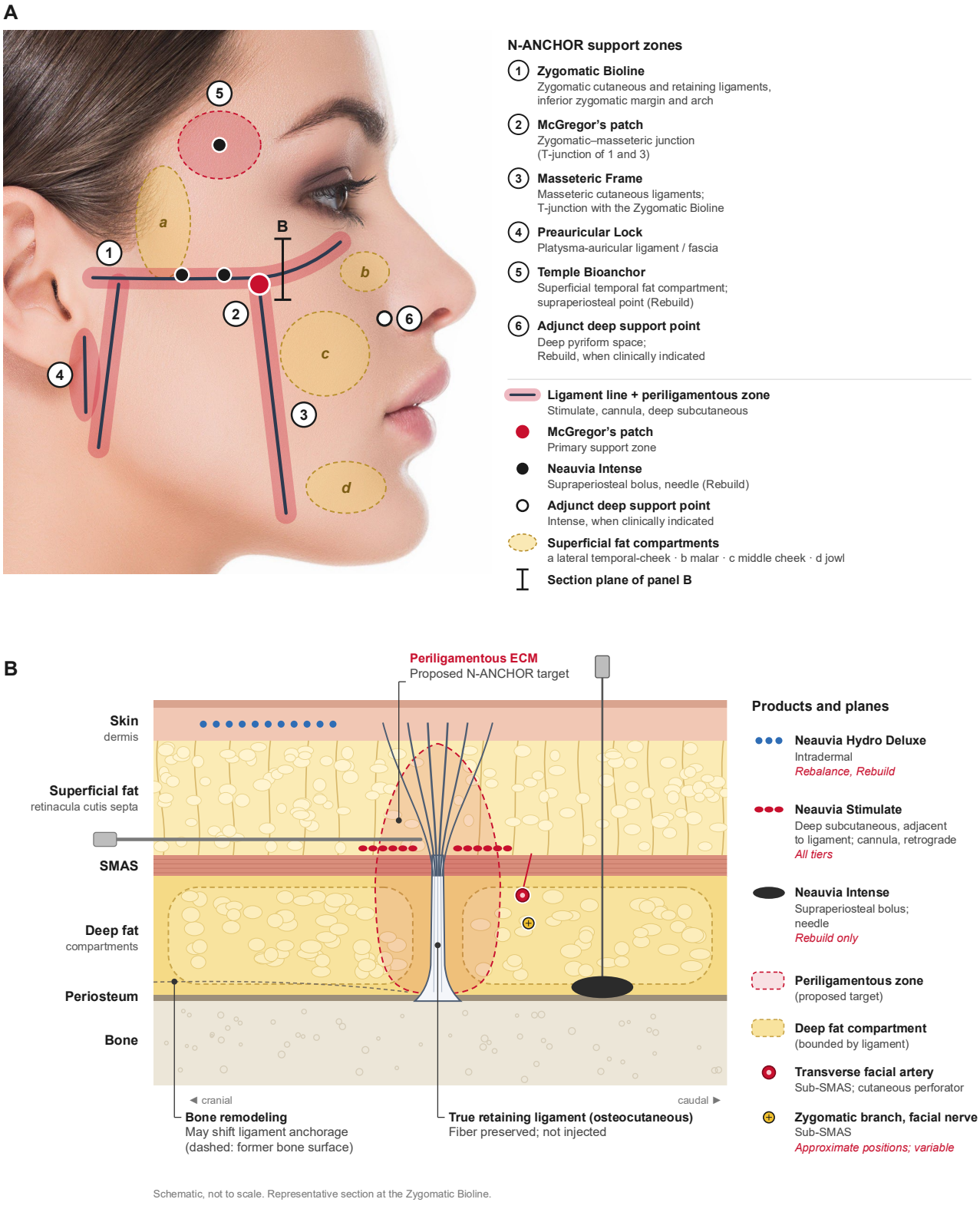

Figure 2. Conceptual representation of the proposed N-ANCHOR support zones and injection-related tissue planes. (**A**) Surface projection of the four operational support zones (1, Zygomatic Bioline;

3, Masseteric Frame; 4, Preauricular Lock; 5, Temple Bioanchor), the zygomatic–masseteric junction (2, McGregor's patch), and the optional adjunct supraperiosteal point in the deep pyriform space (6). Filled black circles indicate the proposed supraperiosteal Intense sites of the Rebuild tier and the open circle indicates the optional deep pyriform point. Colored outlines denote illustrative superficial fat compartments (a–d), red lines indicate schematic ligament-associated regions rather than validated injection trajectories, and the vertical bar marks the section plane of panel (**B**). (**B**) Schematic cross-section at the Zygomatic Bioline showing the osteocutaneous retaining ligament, retinacula cutis, superficial and deep fat compartments, SMAS, and the hypothesized periligamentous connective-tissue region (red dashed outline). The blue, red, and black markers illustrate conceptual relative locations for Hydro Deluxe, Stimulate, and Intense, respectively, not validated injection planes or safe depths. The Hydro Deluxe marker denotes intradermal administration as specified in the IFU [28]. The approximate sub-SMAS positions of the transverse facial artery, with a cutaneous perforator, and of a zygomatic branch of the facial nerve are shown for orientation only [5]. Their course varies between individuals. The dashed bone contour is an illustrative model of skeletal change, not a measured reconstruction. The illustration is not to scale and cannot be used to identify safe injection locations.

The IFU describes Neauvia Intense as a crosslinked HA hydrogel containing sodium hyaluronate 28 mg/mL, glycine, and L-proline, supplied in a 1.0-mL prefilled syringe (Description, Composition). It has the same intended use as Stimulate (Intended Use) and specifies injection 'into the subcutis and/or over the periosteum' (Indications). It reports a mean degradation time of six months, attributed to pre-clinical and clinical studies that it does not identify (Indications). It recommends a 22-G cannula (Preparing for Treatment) and the retrograde sliding injection technique (Treatment Procedure) [30]. The supraperiosteal bolus technique proposed for the Rebuild tier (Table 3) uses a 27-G needle and therefore differs from the instrument recommended in the IFU. The authors prefer a needle for bolus placement because, in their experience, it allows more precise positioning on the periosteum and more controlled delivery of a small volume. This preference has not been compared with cannula delivery, and the associated vascular risk is discussed in Section 6. In the Rebuild tier, an optional supraperiosteal point in the deep pyriform space, a deep compartment adjacent to the pyriform aperture [31], may be added when clinically indicated. Although medial in location, it is included on the same structural rationale as the temporal and zygomatic-arch points: age-related enlargement of the pyriform aperture reduces deep skeletal support of the overlying soft tissue [1], and the intended aim is to supplement deep support rather than to add central soft-tissue volume. Its contribution within N-ANCHOR has not been evaluated, and site-specific safety considerations are given in Section 6.

The three formulations thus differ in HA concentration (18, 26, and 28 mg/mL), crosslinking (non-crosslinked vs. PEGDE-crosslinked), and the presence of CaHA, properties that may influence their rheological behavior, tissue integration, and residence time but do not alone predict clinical performance. Within the proposed mechanism, HA concentration and crosslinking are assumed to govern the scaffold and volumetric contribution, whereas CaHA particles are assumed to provide the cellular stimulus. The CaHA content of each formulation is therefore relevant to the expected magnitude of any biostimulatory effect.

All three products are CE-marked medical devices in the European Union, the jurisdiction to which the cited IFUs apply [28–30]. Regulatory status and indications may differ elsewhere. These IFUs specify temporary soft-tissue volume correction. The proposed regional strategy does not establish a new indication, periligamentous ECM regeneration, or validated efficacy of the N-ANCHOR tier structure. Manufacturer-stated mean degradation times are not independent measurements of in vivo persistence and should not be equated with complete material clearance, duration of correction, or duration of any biological

response. In summary, the IFUs indicate treatment of the face (and, for Hydro Deluxe, the neck) without naming individual sites. They exclude the periorbital and glabellar regions (Stimulate and Intense) or the eyelids (Hydro Deluxe) (Contraindications), none of which is an N-ANCHOR target. The injection planes used for the three products correspond to those specified in the respective IFUs, as do delivery of Hydro Deluxe with a 30-G needle and of Stimulate with a 22-G cannula, and the volume of each product per session is within the maximum suggested in its IFU (Dosage and Instructions for Use). These maxima are 22.5 mL per session for Hydro Deluxe and a daily dose of 4 mL for a 60-kg patient for Stimulate and for Intense. The needle-based bolus proposed for supraperiosteal Intense differs from the cannula and retrograde technique recommended in the IFU. The selection of specific anatomical sites, periligamentous targeting, the distribution of volume per site and per tier, treatment sequencing, and tier assignment are proposals of the authors that are not specified in the IFUs. The IFUs describe each product for use on its own and do not address same-session use with other fillers. Each IFU states 'Do not mix the product with other substances' (Warnings). Within N-ANCHOR, the products are neither mixed nor placed in the same tissue plane: Hydro Deluxe is injected intradermally, Stimulate subdermally, and Intense supraperiosteally, each in small volumes, so that no two products are deposited in the same layer at a given site. The products are, however, placed within the same anatomical region in one session (Hydro Deluxe over areas treated with Stimulate, and Stimulate and Intense in the temporal and zygomatic-arch regions), and the Contraindications section of each IFU contains the identical statement 'Do not inject in patients already treated with temporary or permanent fillers in the same area' [28–30]. The IFUs do not define 'area'. They do not say whether it means an anatomical region or a tissue plane, or whether the contraindication applies within one session. The authors interpret it conservatively. A product placed earlier in a session is regarded as prior filler treatment for any product placed later in the same anatomical region. On this interpretation, the combined use in the Rebalance and Rebuild tiers is outside the IFUs (Table 3, category d). This applies even though the products are always injected into different tissue planes and never into the same layer. The combined use reflects the authors' clinical practice. Placement in distinct planes is the authors' rationale. It does not establish that combined use is as safe as single-product use. Consistent with these distinctions, findings obtained with other CaHA or HA/CaHA products [16,22–24] are cited in this article as indirect support only and are not extrapolated to the formulations used here.

6. Safety Considerations

N-ANCHOR does not involve direct intraligamentous injection. Because the zygomatic–masseteric complex and temporal region contain clinically relevant neurovascular structures, injection plane, depth, product selection, and instrument choice must be explicitly defined for each anatomical target rather than generalized across the protocol.

Instrument selection is correspondingly site-specific. Linear threading or fanning with a 22-G cannula is used for Neauvia Stimulate within the defined subcutaneous/periligamentous and temporal planes, whereas delivery with a 27-G needle is proposed for selected supraperiosteal Neauvia Intense boluses at the Rebuild tier, although the Intense IFU recommends a 22-G cannula [30] (Section Product Rationale and Injection Planes). These techniques and planes are procedurally distinct and should not be treated as interchangeable.

At the zygomatic–masseteric complex, the close anatomical relationship between the zygomatic branch of the facial nerve, the transverse facial vessels, and the retaining structures makes precise depth control essential [5]. As Rebuild-tier treatment combines multiple anatomical sites within a single session, it is intended for experienced injectors with detailed knowledge of regional vascular and neural anatomy.

The temporal region carries comparable demands, given the coexistence of deep and superficial temporal vascular systems. The superficial temporal fat-compartment approach used for Neauvia Stimulate and the supraperiosteal bolus technique used for Neauvia Intense represent distinct procedures with different risk profiles, and should be performed only by injectors familiar with temporal anatomy and its recognized danger zones [12].

These principles have important limitations. Neurovascular anatomy varies considerably between individuals in vessel course, depth, and branching, so that published danger zones and mean cadaveric distances (Section 3.2) indicate regions of risk rather than reliably safe injection locations and do not replace individual anatomical assessment.

Intravascular injection or external vascular compression by filler can cause acute skin ischemia and necrosis, and retrograde embolization into the ophthalmic arterial system can result in visual loss, ophthalmoplegia, or central nervous system complications. The glabella, nasal region, nasolabial fold, and forehead are among the sites most frequently implicated [32]. Cannulas have been associated with substantially lower, but not zero, rates of vascular occlusion than needles in a large retrospective study [33]. They can still penetrate vessels, particularly small-gauge cannulas or when excessive force is applied, and their use does not remove the need for slow, low-pressure, small-aliquot injection. These considerations are particularly relevant to the needle-based supraperiosteal boluses of the Rebuild tier and, above all, to the optional deep pyriform space point. In a Doppler ultrasound study of 166 volunteers, the angular artery lay within 3 mm of the bone in 38.6% of the 332 pyriform spaces examined and followed a highly variable course. The authors advised against supraperiosteal bolus injection where the artery lies close to the bone and recommended ultrasound assessment of its course before treatment [34]. Within N-ANCHOR, this point should therefore be considered only after assessment of the angular artery course, preferably by ultrasound. Because CaHA is not dissolved by hyaluronidase, CaHA-containing formulations are only partly reversible, and vascular compromise after CaHA injection requires a dedicated management approach [35]. This should be considered in high-risk sites.

Other acute and delayed complications should also be anticipated and monitored, including edema, bruising, and hypersensitivity reactions; infection, including biofilm-associated infection; delayed-onset inflammatory nodules and granulomatous reactions, which may present weeks to months after treatment; and non-inflammatory nodules related to superficial placement or product aggregation [36]. Sensory or motor nerve disturbance through compression or direct injury is uncommon but possible where nerve branches lie close to the injection plane, such as the zygomatic branch of the facial nerve near the zygomatic ligamentous complex [5].

Product-specific clinical evidence is confined to single-product, single-site studies. For Stimulate, a prospective, open-label, observational, single-center study of 60 patients treated in the zygomatic area, by deep subcutaneous bolus with a 27-G needle or more superficial subcutaneous injection with a 22-G cannula, reported no major side effects over 24 weeks, without further itemization of adverse events [37]. A prospective study of 15 women with Hashimoto's thyroiditis treated subcutaneously in the buccal area with a 22-G cannula reported edema for up to 2 days in one patient, tenderness for up to 3 days in two, and transient palpability of the product in three, with no redness or nodules and no further events through day 150 [38]. In the five patients who underwent serial retroauricular biopsies in that study, the inflammatory infiltrate decreased from baseline. For Intense, a prospective, open-label, single-center study of 60 patients treated in the nasolabial folds, by bolus or linear retrograde injection with a 27-G needle or a 22-G or 25-G cannula in the subcutaneous or supraperiosteal plane, reported no product-related adverse effects over six months [39]. These studies were uncontrolled, had follow-up of about six months or

less, and are too small to exclude rare events such as vascular occlusion. None evaluated the temple, the preauricular region, or the deep pyriform space, Intense at the zygomatic arch, or the use of the three products in a single session. The site-specific considerations above therefore rest on anatomical and imaging studies and on the general literature on facial fillers [5,12,32–34,36] rather than on clinical data for these formulations.

Finally, the safety profile of the combined multi-site protocol described here, including same-session use of several products in different tissue planes of one region, which is outside the IFUs, has not been evaluated directly. It cannot be inferred from studies of other biomaterials or other HA/CaHA products and should be established prospectively through systematic, standardized reporting of acute and delayed adverse events (Section 7).

7. Limitations and Future Validation

N-ANCHOR is currently a conceptual and anatomy-guided treatment framework rather than a clinically validated classification system. The proposed support zones and treatment tiers are derived from published anatomical, biomechanical, and mechanobiological evidence combined with clinical reasoning, and the protocol itself has not yet been evaluated in a prospective controlled study. Accordingly, the illustrative age ranges, tier thresholds, and product volumes should be regarded as proposed parameters for prospective evaluation rather than validated cutoffs. Its central propositions remain testable hypotheses: treatment initiated at lateral ligament-defined support zones may reduce subsequent medial volumization requirements, produce measurable changes in lateral soft-tissue position, and induce detectable remodeling of the periligamentous tissue environment. These hypotheses should be evaluated prospectively using standardized photography, three-dimensional imaging, ultrasound where appropriate, validated aesthetic outcome measures, patient-reported outcomes, treatment-volume documentation, and systematic adverse-event reporting. More speculative mechanotransduction pathways described in experimental models [40] should not be interpreted as evidence of a clinically demonstrated mechanism. Tier assignment currently relies on clinical assessment of the profiles in Table 3, and no validated scale cutoffs define the tiers. The illustrative age ranges are not assignment criteria. For prospective evaluation, tier assignment could be documented with validated photonumeric scales for upper and lower cheek fullness [41], temple hollowing (Allergan Temple Hollowing Scale) [42], and the jawline [43]. Score thresholds for each tier would require dedicated validation studies. Untested cutoffs are therefore not proposed here.

These three propositions are distinct and require different tests. A reduction in medial filler requirement is a procedural outcome that can be tested by comparing the volume needed to reach a predefined aesthetic endpoint after lateral-first versus conventional treatment. Sustained tissue displacement is a positional outcome that requires standardized 3D surface imaging at baseline and at prespecified follow-up time points, with imaging used to document residual injected material rather than assuming that it has disappeared at the manufacturer-stated mean degradation time. Residual material would be classified at each visit as described in Section 4. Where it is detected, persistent displacement or altered stiffness would be reported as 'effect observed with residual material present', and where imaging is inconclusive, as 'mechanism indeterminate'. Neither finding would be interpreted as evidence of remodeling, and neither implies that the residual material causes the observed change. Biological remodeling is a tissue-level outcome that cannot be inferred from either of the former and would require a multimodal approach combining morphology (e.g., high-frequency ultrasound of tissue thickness and architecture), mechanical assessment (e.g., elastography), and, where ethically and practically feasible, molecular or histological markers. Evidence from wound-healing models should be interpreted with particular caution: wound repair is a response to tissue injury involving inflammation, gran-

ulation tissue, and scar formation, whereas the proposed effect concerns gradual remodeling of intact, aging connective tissue, and the two processes are not interchangeable. Wound-model endpoints, such as wound closure, re-epithelialization, and the tensile strength of a healing scar, describe repair after injury and cannot be transferred to intact periligamentous tissue. Wound-model studies are therefore not used here as methodological support.

A staged validation strategy is therefore proposed. Stage 1 would comprise preclinical studies characterizing the tissue response to the selected formulations in a connective-tissue environment, with histological assessment of collagen content and organization, vascularization, and inflammatory response, in order to distinguish organized remodeling from nonspecific collagen deposition. Formulation characterization should be kept separate from demonstrated biological efficacy. Stage 2 would be a prospective pilot study with standardized protocol documentation to establish feasibility, safety, and the reproducibility of tier assignment, including interobserver agreement between independent assessors (e.g., weighted kappa or intraclass correlation coefficient). Stage 3 would be a randomized controlled study, as specified below.

The Stage 1 assessments rely on established histological methods that have been applied to human skin after filler injection: picrosirius red staining under polarized light for collagen organization, which reflects fiber thickness, packing, and orientation rather than collagen type [21,22,44]; immunohistochemical quantification of collagen types I and III and elastin [20,23]; and semiquantitative grading of the inflammatory infiltrate with immunohistochemistry for CD4, CD8, CD20, and CD68, as reported for Stimulate [38]. These sources support the feasibility of the methods, not the proposed effect: they examined skin rather than periligamentous tissue, and two concern a different CaHA product [22,23]. The findings would be interpreted together. Organized remodeling would require, concurrently, collagen fibers whose thickness, orientation, and bundle architecture resemble adjacent untreated tissue; an absent or minimal, non-progressive inflammatory infiltrate without giant cells, granulomas, or encapsulation of residual particles; and mechanical values within a prespecified reference range for untreated tissue, defined as follows.

The untreated reference and its mechanical range would be specified before data collection. In preclinical models, the reference would be untreated tissue at the homologous contralateral site of the same animal, together with vehicle- or sham-injected sites. These would be sampled at the same time points, and excised tissue would be tested by the same mechanical protocol (e.g., tensile or indentation testing). In clinical studies, the reference would be the baseline value of each treated site and an untreated reference site measured at every visit with the same elastography protocol. The reference site could be an adjacent untreated region at the same depth or the corresponding site in control-arm patients. The reference range would be derived from repeated measurements of untreated tissue (e.g., a 95% reference interval). It would take into account the measurement error of the method, estimated from test–retest data [27]. Changes smaller than this error would not be interpreted. Values within the reference range would provide no mechanical evidence of pathological stiffening but would not, by themselves, demonstrate functional improvement or exclude other pathological tissue changes. They would not by themselves demonstrate benefit. An improvement in local support would require a change from baseline that exceeds the measurement error and differs from the control condition. It would also require a corresponding positional change on 3D imaging, because tissue stiffness alone is not a measure of support.

Findings would be classified in a prespecified order. First, a persistent macrophage-rich infiltrate with giant cells or granulomas around residual material would be classified as a foreign-body response, irrespective of collagen content or mechanical values [45]. Second, in the absence of such a response, dense, disorganized collagen or stiffening above the reference

range would be classified as nonspecific deposition or fibrosis. Third, organized remodeling would be recorded only when collagen architecture, inflammatory status, and mechanical measures all meet the criteria above. Organized collagen without a mechanical change beyond measurement error would be recorded as structural change without demonstrated mechanical effect. A mechanical change without corresponding histological organization would be recorded as mechanical change of undetermined origin. Any other combination, or incomplete data, would be classified as indeterminate. In clinical studies without histology, findings could at most be classified as compatible with remodeling, and the residual-material categories defined in Section 4 would apply.

Stage 3 would be a randomized, evaluator-blinded, parallel-group study of the full N-ANCHOR framework. It would therefore estimate the effect of the overall strategy and could not attribute a difference to any single component. Patients with one clinical profile (e.g., Rebalance) would be randomized to N-ANCHOR or to conventional medial-first, volume-based treatment with a crosslinked HA filler without CaHA, treated to the same predefined aesthetic endpoint. The primary endpoint would be a clinical efficacy endpoint for the overall strategy. It would be the proportion of patients with an improvement of at least one grade on a validated photonumeric jawline scale [43] at 12 months. Blinded independent evaluators would rate standardized images. The hypothesis is that N-ANCHOR is superior. This endpoint measures the clinical result of the strategy irrespective of mechanism. The 12-month time point is not assumed to coincide with clearance of the injected material. The primary endpoint would therefore not be interpreted as evidence of filler-independent durability or biological remodeling. Injected volumes, 3D-measured soft-tissue position, and residual material on ultrasound would be secondary endpoints, with follow-up to 18–24 months. In the secondary analyses of durability and remodeling, residual material would be classified at each treated site and visit as described in Section 4. Positional or mechanical changes at sites with detected material would be reported as 'effect observed with residual material present', and those at sites with inconclusive imaging as 'mechanism indeterminate'. Only sites without detectable material on repeated examinations would contribute to the analysis of a possible tissue-level effect. Results would be reported separately for each category. A sensitivity analysis would be restricted to patients in whom no treated site shows detected or indeterminate material at the time point analyzed. Isolating the effect of lateral-first sequencing would require a separate design in which products, sites, planes, instruments, maximum volumes, and the aesthetic endpoint are held constant and only the order of lateral and medial treatment differs.

Adverse events would be recorded prospectively at every visit, by solicited and spontaneous reporting, as acute (onset within 4 weeks) or delayed, with their location, severity, management, and outcome. Because several products and sites are treated in one session, a per-site injection record (product, lot, volume, plane, and instrument) would be kept and each event mapped to it. This mapping identifies exposure, that is, the site, product, plane, and instrument where an event occurs. It would be kept separate from causal attribution. An event localized to a site that received a single product would be mapped to that product and site. Events at sites where products overlap in different planes, and diffuse or systemic events, would be mapped to the session as a whole. Localization alone cannot show whether the formulation, the injection procedure, or another factor caused an event. Procedural factors include needle or cannula trauma, plane, volume, and technique. Other factors include a concomitant treatment, intercurrent infection, or a pre-existing condition. Causality would therefore be assessed separately for each product and for the injection procedure. The investigator would make the assessment, and an independent safety assessor would review it. The assessment would use the four causality categories of European guidance on safety reporting in clinical investigations of medical devices: not

related, possible, probable, and causal relationship [46]. It would consider the temporal relationship, biological plausibility, known response patterns of the product, the course after treatment, and alternative explanations. Ultrasound and, where indicated, biopsy would be used to identify the material involved in nodular or inflammatory lesions. These findings can inform causality but do not establish it on their own. Events whose causal relationship to a product or to the procedure remains uncertain would be recorded as 'attribution uncertain'. All candidate products and procedural factors would be listed. These events would be reported separately and not assigned to a single product in the analysis.

8. Conclusions

N-ANCHOR proposes an anatomy-guided framework that shifts the emphasis of injectable facial rejuvenation from visible volume loss toward the structural interfaces that organize facial soft tissue, building on existing ligament-oriented and lateral-first approaches. Key retaining-ligament zones are used as anatomical landmarks within a broader system in which skeletal remodeling, fat-compartment change, retinacula cutis changes, and altered force transmission are thought to interact to produce the visible phenotype of aging.

Its proposed contribution is threefold: the periligamentous connective-tissue environment, rather than the ligament fiber itself, as a candidate injectable target; an operational nomenclature for four lateral support zones; and a severity-based tier structure linking these zones to specific products and injection planes. Periligamentous bio-regeneration and improved structural support remain proposed mechanisms rather than demonstrated effects. The tier criteria, product volumes, and injection strategies are likewise preliminary and are not validated clinical recommendations, and the supporting evidence, where it concerns HA/CaHA fillers, is formulation-specific and should not be extrapolated between products. Several questions remain unresolved: whether lateral-first treatment within this framework reduces medial volume requirements, whether any change in soft-tissue position persists beyond product degradation, whether organized periligamentous remodeling occurs at all, and how the safety profile of the multi-site protocol compares with that of established approaches. These questions should be addressed in prospective controlled studies before the framework is adopted in routine practice.

Author Contributions: Conceptualization, F.M. and G.C.; methodology, F.M. and G.C.; writing—original draft preparation, F.M. and G.C.; writing—review and editing, F.M. and G.C. All authors have read and agreed to the published version of the manuscript.

Funding: This research received no external funding.

Institutional Review Board Statement: Not applicable. This article does not report original research involving human participants or animals.

Informed Consent Statement: Not applicable.

Data Availability Statement: The original contributions presented in this study are included in the article. Copies of the manufacturers' instructions for use of the three products are available from the corresponding author on request. Further inquiries can be directed to the corresponding author.

Acknowledgments: Editorial support, preparation of the figures based on the authors' instructions, and assistance with manuscript submission were provided by Matex Lab S.p.A. (Neauvia). Claude (Claude Opus 5.5, Anthropic) was used to prepare Figure 2 from a licensed stock photograph and to assist with drafting and language editing of the revised text. The authors reviewed and edited all AI-generated output and take full responsibility for the scientific accuracy and content of this publication.

Conflicts of Interest: F.M. and G.C. serve as Key Opinion Leaders (KOLs) for Neauvia and are involved in educational and training activities related to Neauvia products. Matex Lab S.p.A. (Neauvia)

funded the APC and provided editorial support, figure preparation, and assistance with manuscript submission. The authors selected the literature, wrote the manuscript, and made all final decisions on its content. These professional relationships and the manufacturer's involvement are disclosed as potential conflicts of interest.

Abbreviations

The following abbreviations are used in this manuscript:

2D/3D	Two-dimensional/three-dimensional
AP-1	Activator protein-1
CaHA	Calcium hydroxyapatite
ECM	Extracellular matrix
HA	Hyaluronic acid
IFU	Instructions for use
KOL	Key Opinion Leader
MMP-1	Matrix metalloproteinase-1
PEGDE	Poly(ethylene glycol) diglycidyl ether
SMAS	Superficial musculoaponeurotic system
TGF-β	Transforming growth factor-β

References

1. Kapoor, K.M.; Saputra, D.I.; Porter, C.E.; Colucci, L.; Stone, C.; Brenninkmeijer, E.E.A.; Sloane, J.; Sayed, K.; Winaya, K.K.; Bertossi, D. Treating Aging Changes of Facial Anatomical Layers with Hyaluronic Acid Fillers. *Clin. Cosmet. Investig. Dermatol.* **2021**, *14*, 1105–1118. [CrossRef] [PubMed]
2. Casabona, G.; Frank, K.; Koban, K.C.; Freytag, D.L.; Schenck, T.L.; Lachman, N.; Green, J.B.; Toni, S.; Rudolph, C.; Cotofana, S. Lifting vs volumizing—The difference in facial minimally invasive procedures when respecting the line of ligaments. *J. Cosmet. Dermatol.* **2019**, *18*, 1237–1243. [CrossRef] [PubMed]
3. de Maio, M. MD Codes™: A Methodological Approach to Facial Aesthetic Treatment with Injectable Hyaluronic Acid Fillers. *Aesthetic Plast. Surg.* **2021**, *45*, 690–709. [CrossRef] [PubMed]
4. Furnas, D.W. The retaining ligaments of the cheek. *Plast. Reconstr. Surg.* **1989**, *83*, 11–16. [CrossRef] [PubMed]
5. Duan, J.; Cong, L.Y.; Luo, C.E.; Luo, S.K. Clarifying the Anatomy of the Zygomatic Cutaneous Ligament: Its Application in Midface Rejuvenation. *Plast. Reconstr. Surg.* **2022**, *149*, 198e–208e. [CrossRef] [PubMed]
6. Distefano, A.; Dotto, A.; Garlaschi, A.; Colombo, G. Instrumental Analysis of Retaining Ligaments and Literature Review. What Can We Deduce? *J. Craniofac. Surg. Open* **2024**, *2*, e0018. [CrossRef]
7. Cotofana, S.; Gotkin, R.H.; Morozov, S.P.; Kim, S.Y.; Gombolevskiy, V.A.; Laipan, A.S.; Pyatnitskiy, I.A.; Movsisyan, T.V.; Frank, K. The Relationship between Bone Remodeling and the Clockwise Rotation of the Facial Skeleton: A Computed Tomographic Imaging-Based Evaluation. *Plast. Reconstr. Surg.* **2018**, *142*, 1447–1454. [CrossRef] [PubMed]
8. Alghoul, M.; Codner, M.A. Retaining Ligaments of the Face: Review of Anatomy and Clinical Applications. *Aesthet. Surg. J.* **2013**, *33*, 769–782. [CrossRef] [PubMed]
9. Brandt, M.G.; Hassa, A.; Roth, K.; Wehrli, B.; Moore, C.C. Biomechanical properties of the facial retaining ligaments. *Arch. Facial Plast. Surg.* **2012**, *14*, 289–294. [CrossRef] [PubMed]
10. Sakata, A.; Abe, K.; Mizukoshi, K.; Gomi, T.; Okuda, I. Relationship between the Retinacula Cutis and Sagging Facial Skin. *Skin Res. Technol.* **2018**, *24*, 93–98. [CrossRef] [PubMed]
11. Zhang, Y.L.; Hong, W.J.; Chen, Y.; Zhou, Y.F.; Chen, Y.Q.; Li, Z.H.; Li, X.R.; Yu, H.; Cotofana, S.; Luo, S.K. Age-Related Changes of the Zygomatic Ligament: An Experimental Animal Study. *Aesthet. Surg. J.* **2023**, *43*, NP979–NP986. [CrossRef] [PubMed]
12. Cotofana, S.; Gaete, A.; Hernandez, C.A.; Casabona, G.; Bay, S.; Pavicic, T.; Coimbra, D.; Suwanchinda, A.; Swift, A.; Green, J.B.; et al. The six different injection techniques for the temple relevant for soft tissue filler augmentation procedures—Clinical anatomy and danger zones. *J. Cosmet. Dermatol.* **2020**, *19*, 1570–1579. [CrossRef] [PubMed]
13. Marchetti, F.; Fahmy Habib, M.M.; Basso, M. From ECM Aging to Mechanobiological Restoration: Injectable Fillers and Dermal Fibroblast Mechanotransduction—A Narrative Review. *Gels* **2026**, *12*, 609. [CrossRef] [PubMed]
14. Qin, Z.; Voorhees, J.J.; Fisher, G.J.; Quan, T. Age-associated reduction of cellular spreading/mechanical force up-regulates matrix metalloproteinase-1 expression and collagen fibril fragmentation via c-Jun/AP-1 in human dermal fibroblasts. *Aging Cell* **2014**, *13*, 1028–1037. [CrossRef] [PubMed]
15. Fisher, G.J.; Shao, Y.; He, T.; Qin, Z.; Perry, D.; Voorhees, J.J.; Quan, T. Reduction of fibroblast size/mechanical force down-regulates TGF-β type II receptor: Implications for human skin aging. *Aging Cell* **2016**, *15*, 67–76. [CrossRef] [PubMed]

16. Nowag, B.; Casabona, G.; Kippenberger, S.; Zöller, N.; Hengl, T. Calcium hydroxylapatite microspheres activate fibroblasts through direct contact to stimulate neocollagenesis. *J. Cosmet. Dermatol.* **2023**, *22*, 426–432. [CrossRef] [PubMed]
17. Zerbinati, N.; Rauso, R.; Gonzalez, P.; Cherubino, M.; D'Este, E.; Calligaro, A.; Sommatis, S.; Maccario, C.; Mocchi, R. In vitro evaluation of collagen production on human fibroblasts treated with hyaluronic acid PEG cross-linked with micromolecules of calcium hydroxyapatite in low concentration. *J. Biol. Regul. Homeost. Agents* **2017**, *31*, 87–90. [PubMed]
18. Zhu, W.; da Silva, M.; Murray, G.; Dreiss, C.A. Integrated mechanical and structural characterisation of 24 commercial hyaluronic acid fillers: A multi-parametric framework for comparative analysis. *J. Colloid Interface Sci.* **2026**, *713*, 140085. [CrossRef] [PubMed]
19. Basso, M.; Di Lella, E.; Marchetti, F. Dual Core: A Mechanical, Biological, and Metabolic Model for Physiological Bio-regeneration with PEG-Crosslinked Hyaluronic Acid Fillers. *J. Appl. Cosmetol.* **2025**, *43*, 3–10. [CrossRef]
20. Cavallini, M.; Fernández de Castro Isalguez, R.; Marchetti, F.; Ramazanova Kurbankadieva, I.; Sandoval Vásquez, R.A.; Forjaz, D.P.; Zimbres, S.; Panithaporn, D. Physiological Bio-Regeneration in Aesthetic Medicine: A Conceptual Framework and Narrative Review of PEGDE-HA and CaHA-Based Formulations. *Cosmetics* **2026**, *13*, 67. [CrossRef]
21. Zerbinati, N.; Rauso, R.; Protasoni, M.; D'Este, E.; Esposito, C.; Lotti, T.; Tirant, M.; Van Thuong, N.; Mocchi, R.; Zerbinati, U.; et al. PEGylated hyaluronic acid filler enriched with calcium hydroxyapatite treatment of human skin: Collagen renewal demonstrated through morphometric computerized analysis. *J. Biol. Regul. Homeost. Agents* **2019**, *33*, 1967–1971. [CrossRef] [PubMed]
22. Zerbinati, N.; Calligaro, A. Calcium hydroxylapatite treatment of human skin: Evidence of collagen turnover through picrosirius red staining and circularly polarized microscopy. *Clin. Cosmet. Investig. Dermatol.* **2018**, *11*, 29–35. [CrossRef] [PubMed]
23. Yutskovskaya, Y.; Kogan, E.; Leshunov, E. A randomized, split-face, histomorphologic study comparing a volumetric calcium hydroxylapatite and a hyaluronic acid-based dermal filler. *J. Drugs Dermatol.* **2014**, *13*, 1047–1052. [PubMed]
24. Urdiales-Gálvez, F.; Braz, A.; Cavallini, M. Facial rejuvenation with the new hybrid filler HArmonyCa: Clinical and aesthetic outcomes assessed by 2D and 3D photographs, ultrasound, and elastography. *J. Cosmet. Dermatol.* **2023**, *22*, 2186–2197. [CrossRef] [PubMed]
25. Wortsman, X. Identification and Complications of Cosmetic Fillers: Sonography First. *J. Ultrasound Med.* **2015**, *34*, 1163–1172. [CrossRef] [PubMed]
26. Schelke, L.W.; Decates, T.S.; Velthuis, P.J. Ultrasound to improve the safety of hyaluronic acid filler treatments. *J. Cosmet. Dermatol.* **2018**, *17*, 1019–1024. [CrossRef] [PubMed]
27. Paluch, Ł.; Pietruski, P.; Noszczyk, B.; Kwiek, B.; Ambroziak, M. Intra-rater reproducibility of shear wave elastography in the evaluation of facial skin. *Adv. Dermatol. Allergol.* **2020**, *37*, 371–376. [CrossRef] [PubMed]
28. Matex Lab. *NEAUVIA Hydro Deluxe: Instructions for Use*; Document 10770_BRINDISI_HYDRO_DELUXE_LFT03, Rev. 04, Last Revised July 2023; Matex Lab S.p.A.: Brindisi, Italy, 2023.
29. Matex Lab. *NEAUVIA Stimulate: Instructions for Use*; Document 10770_BRINDISI_STIMULATE_LFT01, Rev. 04, Last Revised July 2023; Matex Lab S.p.A.: Brindisi, Italy, 2023.
30. Matex Lab. *NEAUVIA Intense: Instructions for Use*; Document 10770_BRINDISI_INTENSE_LFT06, Rev. 04, Last Revised July 2023; Matex Lab S.p.A.: Brindisi, Italy, 2023.
31. Surek, C.K.; Vargo, J.; Lamb, J. Deep Pyriform Space: Anatomical Clarifications and Clinical Implications. *Plast. Reconstr. Surg.* **2016**, *138*, 59–64. [CrossRef] [PubMed]
32. Beleznay, K.; Carruthers, J.D.A.; Humphrey, S.; Jones, D. Avoiding and Treating Blindness from Fillers: A Review of the World Literature. *Dermatol. Surg.* **2015**, *41*, 1097–1117. [CrossRef] [PubMed]
33. Alam, M.; Kakar, R.; Dover, J.S.; Harikumar, V.; Kang, B.Y.; Wan, H.T.; Poon, E.; Jones, D.H. Rates of Vascular Occlusion Associated with Using Needles vs Cannulas for Filler Injection. *JAMA Dermatol.* **2021**, *157*, 174–180. [CrossRef] [PubMed]
34. Franceschelli, A.; Cazzulani, M.; Urso, S.U.; Molinari, P.; Piludu, M.; Zuccaro, M.; Bastiani, L.; Mosti, G. In Vivo Ultrasound Study of the Angular Artery Anatomy: Practical Indications for the Treatment of the Deep Pyriform Space. *Aesthet. Surg. J. Open Forum* **2024**, *6*, ojae113. [CrossRef] [PubMed]
35. van Loghem, J.; Funt, D.; Pavicic, T.; Goldie, K.; Yutskovskaya, Y.; Fabi, S.; Siebenga, P.; Thuis, J.; Hkeik, J.; Kadouch, J.; et al. Managing intravascular complications following treatment with calcium hydroxylapatite: An expert consensus. *J. Cosmet. Dermatol.* **2020**, *19*, 2845–2858. [CrossRef] [PubMed]
36. Funt, D.; Pavicic, T. Dermal Fillers in Aesthetics: An Overview of Adverse Events and Treatment Approaches. *Clin. Cosmet. Investig. Dermatol.* **2013**, *6*, 295–316. [CrossRef] [PubMed]
37. Zerbinati, N.; D'Este, E.; De Silvestri, A.; Zullino, M.; Rabbiosi, G.; Guida, S.; Kubik, P.; Stabile, G.; Mocchi, R.; Barlusconi, C.; et al. Efficacy of Pegylated Hyaluronic Acid Filler Enriched with Calcium Hydroxyapatite: A 24-Week Post-Market, Observational, Prospective, Open-Label, Single-Center Study. *J. Funct. Biomater.* **2023**, *14*, 345. [CrossRef] [PubMed]

38. Kubik, P.; Gallo, D.; Tanda, M.L.; Jankau, J.; Rauso, R.; Gruszczyński, W.; Pawłowska, A.; Chrapczyński, P.; Malinowski, M.; Grzanka, D.; et al. Evaluation of the Safety of Neauvia Stimulate Injectable Product in Patients with Autoimmune Thyroid Diseases Based on Histopathological Examinations and Retrospective Analysis of Medical Records. *Gels* **2023**, *9*, 440. [CrossRef] [PubMed]
39. Zerbinati, N.; Płatkowska, A.; Guida, S.; Stabile, G.; Mocchi, R.; Barlusconi, C.; Sommatis, S.; Garutti, L.; Rauso, R.; Cipolla, G.; et al. Efficacy and Safety of Neauvia Intense in Correcting Moderate-to-Severe Nasolabial Folds: A Post-Market, Prospective, Open-Label, Single-Centre Study. *Clin. Cosmet. Investig. Dermatol.* **2024**, *17*, 1351–1363. [CrossRef] [PubMed]
40. Sladitschek-Martens, H.L.; Guarnieri, A.; Brumana, G.; Zanconato, F.; Battilana, G.; Xiccato, R.L.; Panciera, T.; Forcato, M.; Bicciato, S.; Guzzardo, V.; et al. YAP/TAZ activity in stromal cells prevents ageing by controlling cGAS-STING. *Nature* **2022**, *607*, 790–798. [CrossRef] [PubMed]
41. Carruthers, J.; Flynn, T.C.; Geister, T.L.; Görtelmeyer, R.; Hardas, B.; Himmrich, S.; Jones, D.; Kerscher, M.; de Maio, M.; Mohrmann, C.; et al. Validated Assessment Scales for the Mid Face. *Dermatol. Surg.* **2012**, *38*, 320–332. [CrossRef] [PubMed]
42. Carruthers, J.; Jones, D.; Hardas, B.; Murphy, D.K.; Donofrio, L.; Sykes, J.M.; Carruthers, A.; Creutz, L.; Marx, A.; Dill, S. Development and Validation of a Photonumeric Scale for Evaluation of Volume Deficit of the Temple. *Dermatol. Surg.* **2016**, *42*, S203–S210. [CrossRef] [PubMed]
43. Narins, R.S.; Carruthers, J.; Flynn, T.C.; Geister, T.L.; Görtelmeyer, R.; Hardas, B.; Himmrich, S.; Jones, D.; Kerscher, M.; de Maio, M.; et al. Validated Assessment Scales for the Lower Face. *Dermatol. Surg.* **2012**, *38*, 333–342. [CrossRef] [PubMed]
44. Lattouf, R.; Younes, R.; Lutomski, D.; Naaman, N.; Godeau, G.; Senni, K.; Changotade, S. Picrosirius Red Staining: A Useful Tool to Appraise Collagen Networks in Normal and Pathological Tissues. *J. Histochem. Cytochem.* **2014**, *62*, 751–758. [CrossRef] [PubMed]
45. Lemperle, G.; Gauthier-Hazan, N.; Wolters, M.; Eisemann-Klein, M.; Zimmermann, U.; Duffy, D.M. Foreign body granulomas after all injectable dermal fillers: Part 1. Possible causes. *Plast. Reconstr. Surg.* **2009**, *123*, 1842–1863. [CrossRef] [PubMed]
46. Medical Device Coordination Group. *MDCG 2020-10/1 Rev. 1: Safety Reporting in Clinical Investigations of Medical Devices Under the Regulation (EU) 2017/745*; European Commission: Brussels, Belgium, 2022.

Disclaimer/Publisher's Note: The statements, opinions and data contained in all publications are solely those of the individual author(s) and contributor(s) and not of MDPI and/or the editor(s). MDPI and/or the editor(s) disclaim responsibility for any injury to people or property resulting from any ideas, methods, instructions or products referred to in the content.