

Figure S1. Nail of a healthy person. NP: nail plate; NB: nail bed; NM: nail matrix.

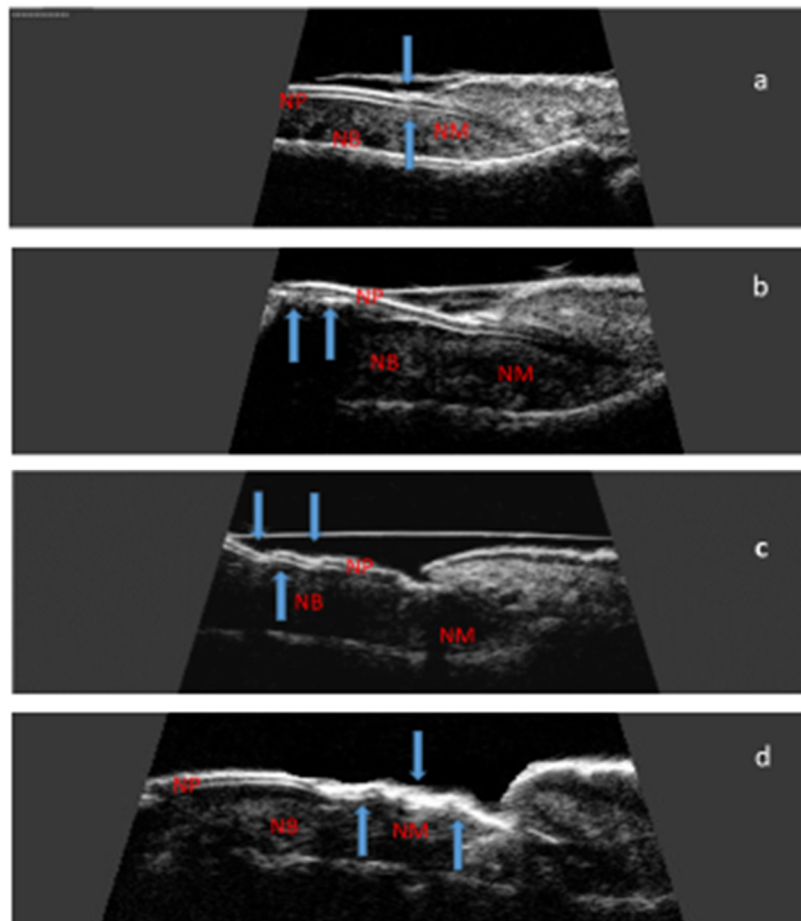


Figure S2. Longitudinal scan of psoriatic nail. (a) Focal hyperechoic involvement of the ventral plate, (b) Loosening of the borders of the ventral plate, (c) Wavy plates. d Loss of definition of both plates. NP: nail plate; NB: nail bed; NM: nail matrix.

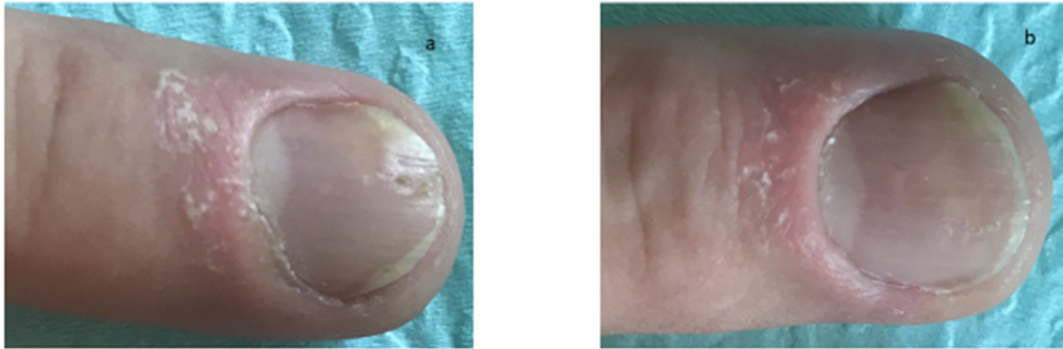


Figure S3. The effect of six months of methotrexate treatment on the clinical improvement of nail psoriasis. (a) before treatment, (b) after 6 months of treatment with methotrexate.