

**Supplementary Table S1. Nasolabial Folds Assessment according to
Wrinkle Severity Rating Scale before Midface Augmentation**

Grade	Description	N	%
1 (absent)	No visible fold; continuous skin line.	1	1.2
2 (mild)	Shallow but visible fold with a slight indentation; minor facial feature.	39	45.9
3 (moderate)	Moderately deep folds; clear facial features visible at normal appearance but not when stretched.	41	48.2
4 (severe)	Very long and deep folds, prominent facial features; Less than 2 mm visible fold when stretched.	4	4.7
5 (extreme)	Extremely deep and long folds, detrimental to facial appearance; 2–4 mm visible V-shaped fold when stretched.	0	0

Supplementary Table S2. Results of Patient Self-Evaluation at Week 24

		N	%
Overall satisfied	Yes	64	75.3
	No	21	24.7
Feel more attractive	Yes	67	78.8
	No	18	21.2
Willingness to recommend to	Yes	67	78.8

others

No

18

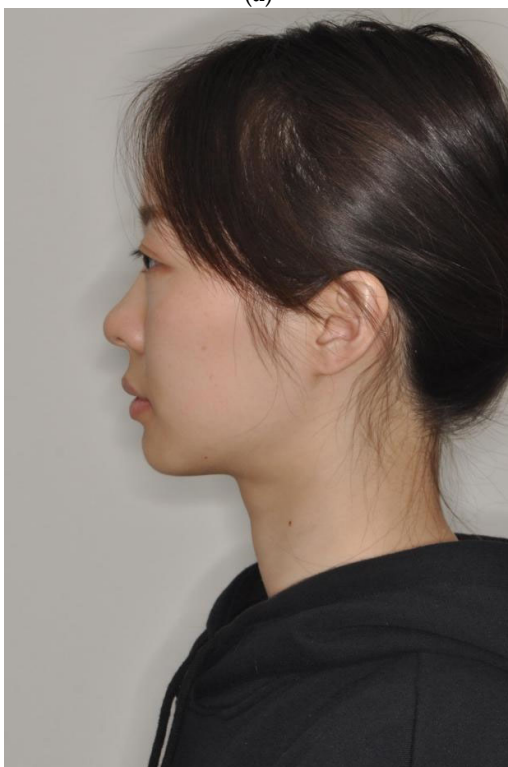21.2




(a)



(b)



(c)



(d)

Figure S1. (a) Preoperative oblique view of patient 1; (b) 24 weeks postoperative oblique view of patient 1; (c) preoperative lateral view of patient 1; (d) 24 weeks postoperative lateral view of patient 1.

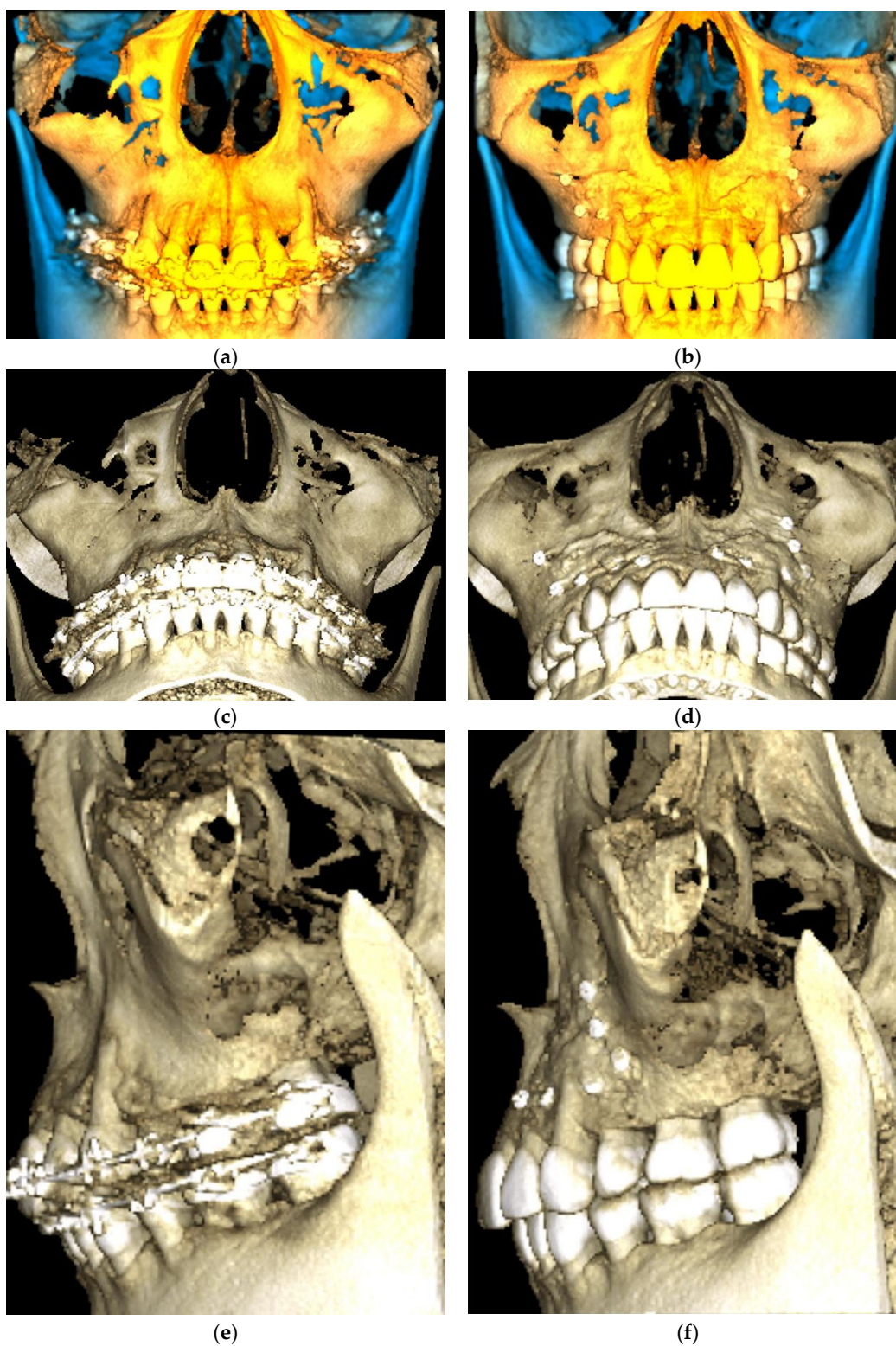


Figure S2. (a) Front view of preoperative three-dimensional reconstructed CT image of patient 1; (b) front view of 24 weeks

postoperative three-dimensional reconstructed CT image of patient 1; (c) bottom view of preoperative three-dimensional reconstructed CT image of patient 1; (d) bottom view of 24 weeks postoperative three-dimensional reconstructed CT image of patient 1; (e) lateral view of preoperative three-dimensional reconstructed CT image of patient 1; (f) lateral view of 24 weeks postoperative three-dimensional reconstructed CT image of patient 1.

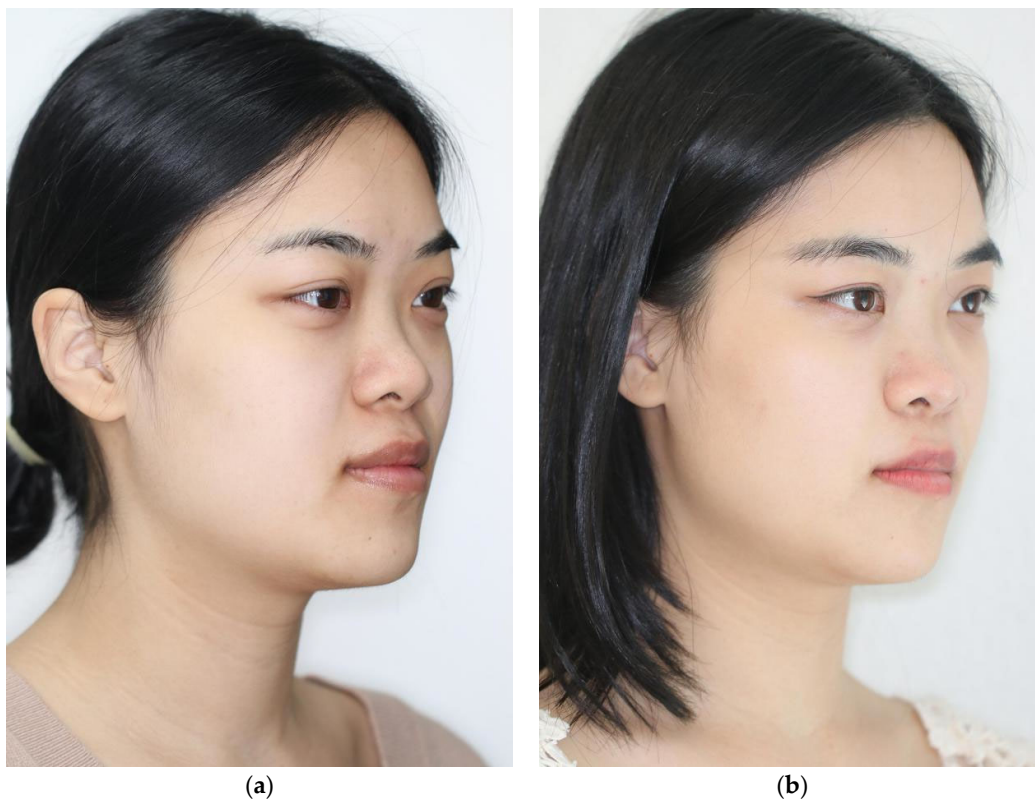

Figure S3. (a) Preoperative oblique view of patient 2; (b) 24 weeks postoperative oblique view of patient 2.