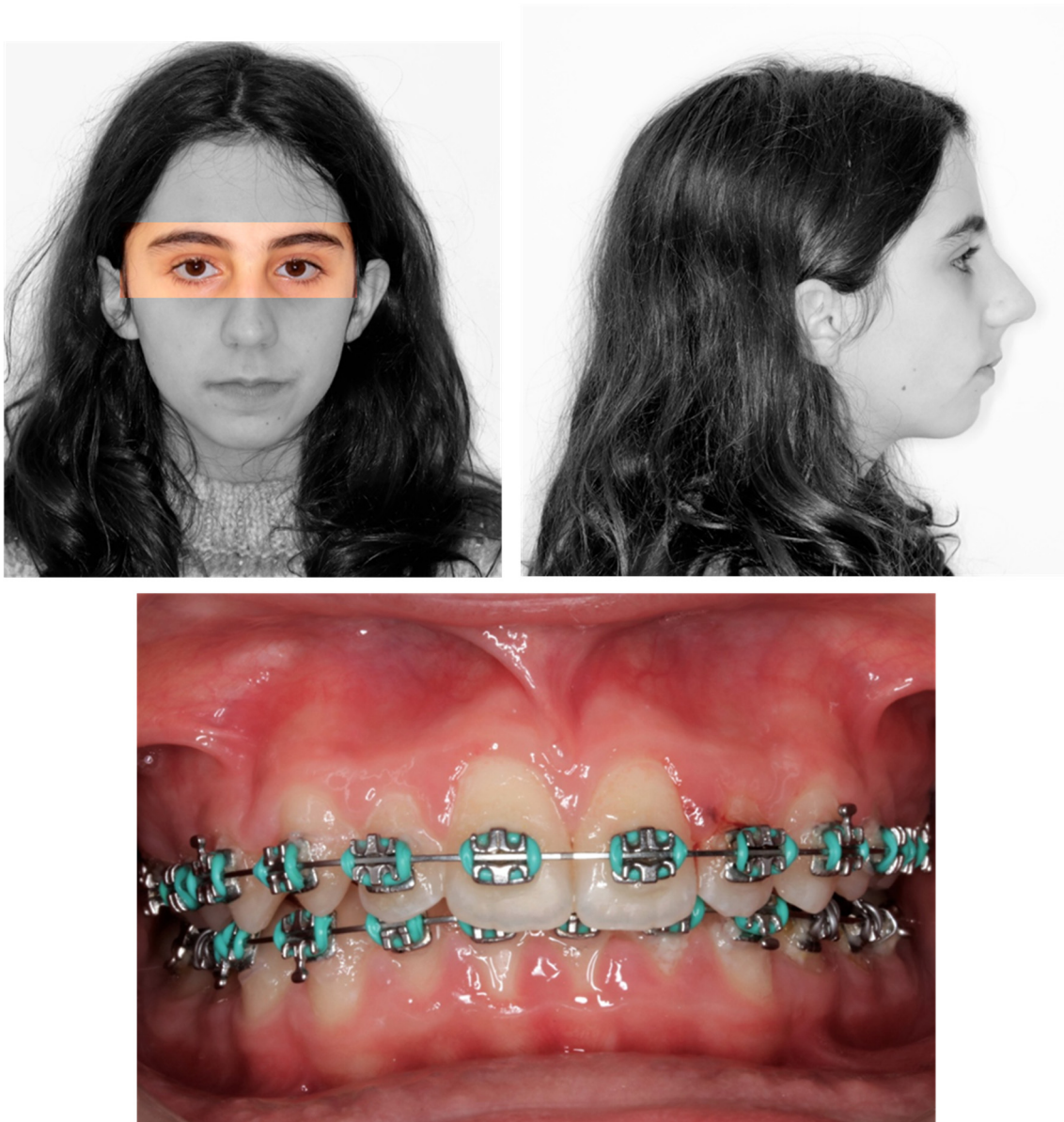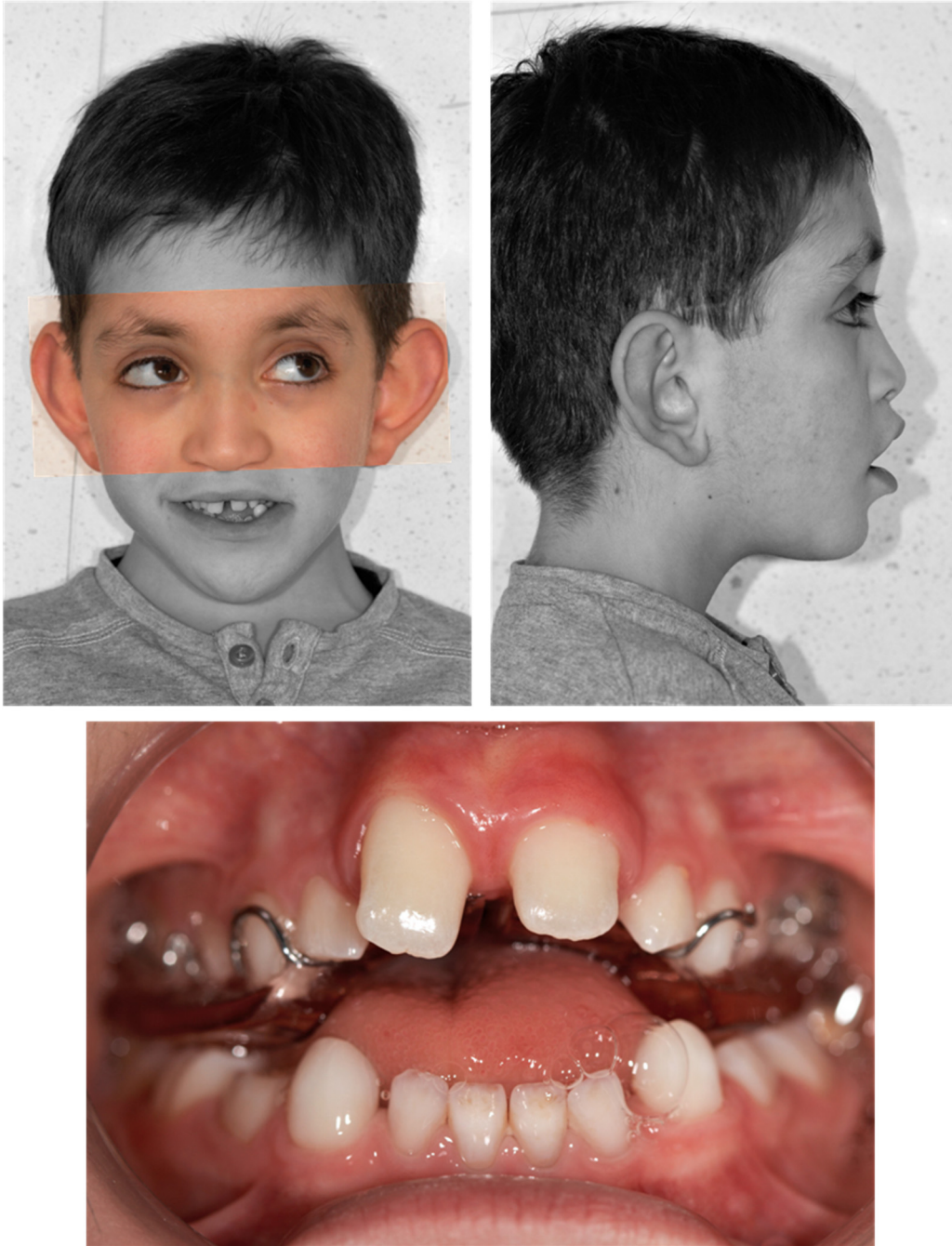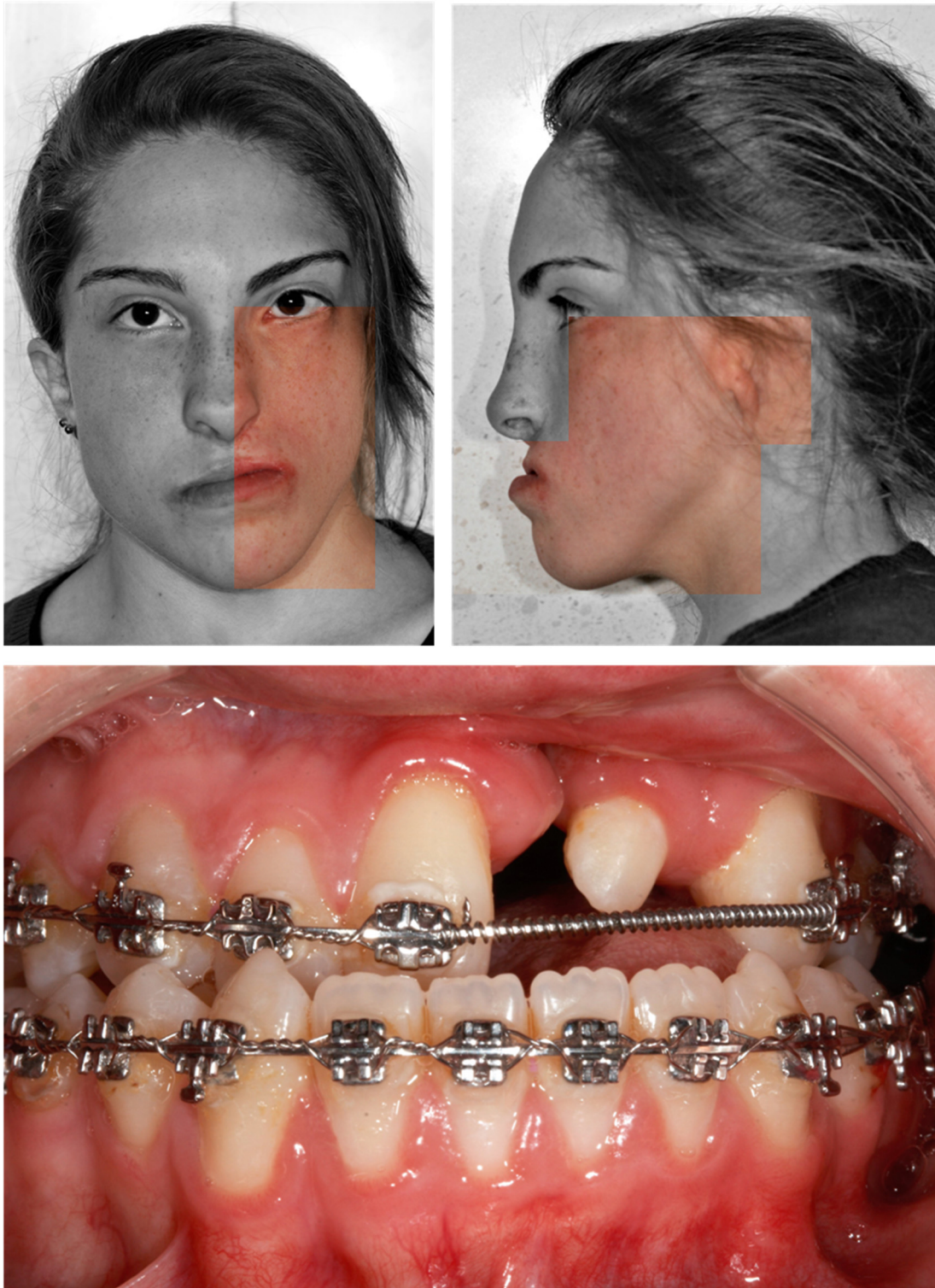


**Figure S1.** Osteogenesis imperfecta.

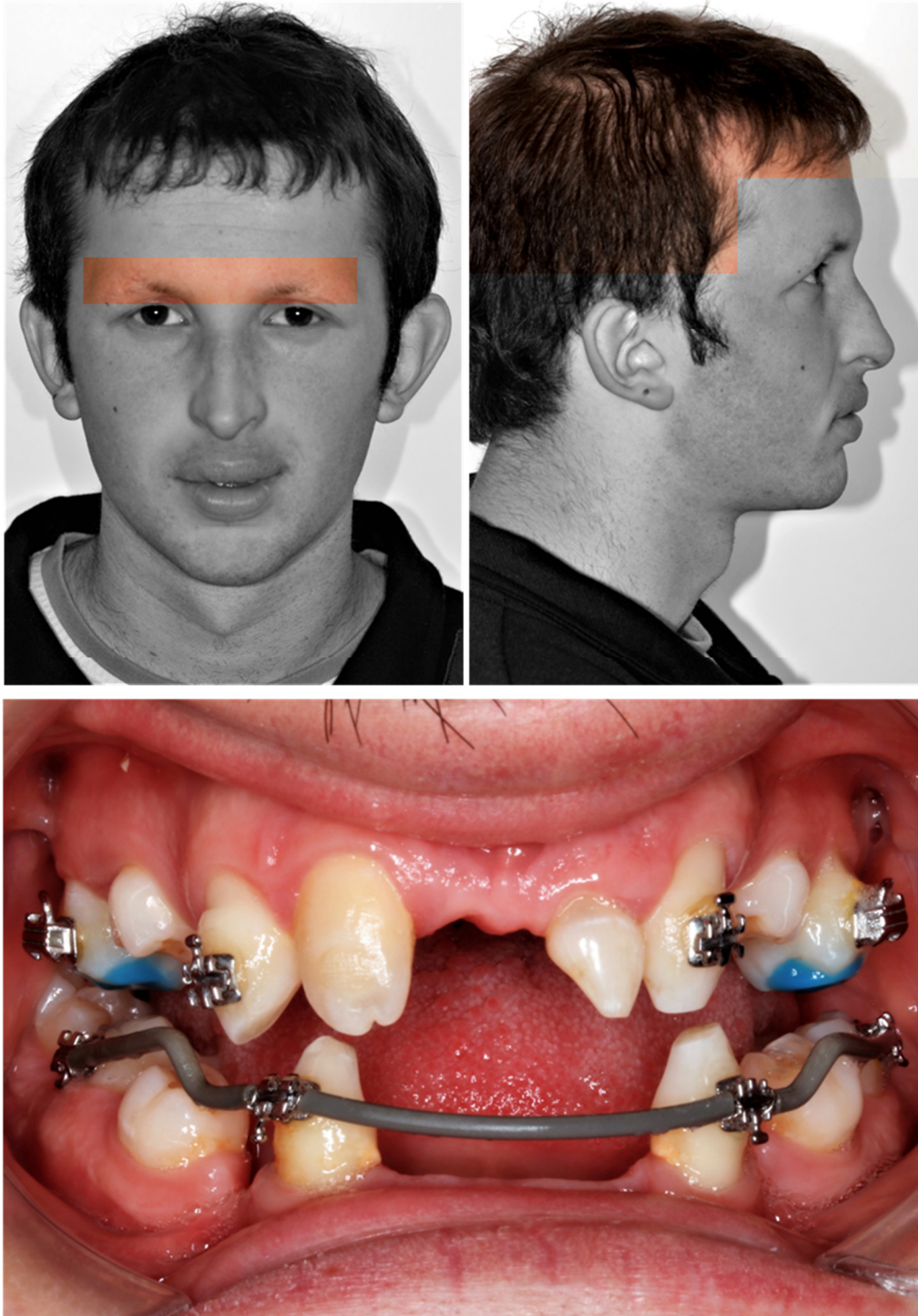


**Figure S2.** Kabuki syndrome.



**Figure S3.** Goldenhar syndrome.





**Figure S4.** Ectodermal dysplasia.