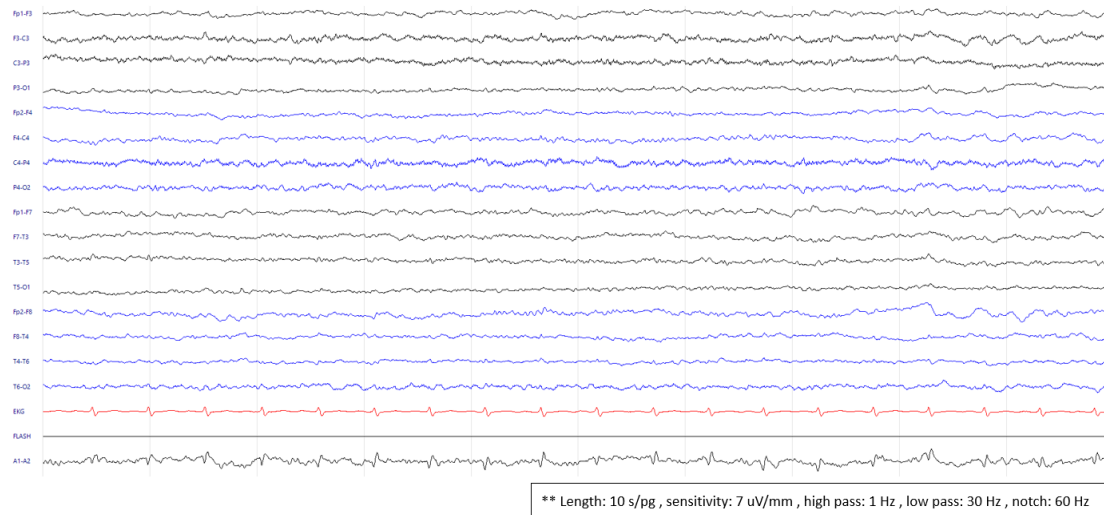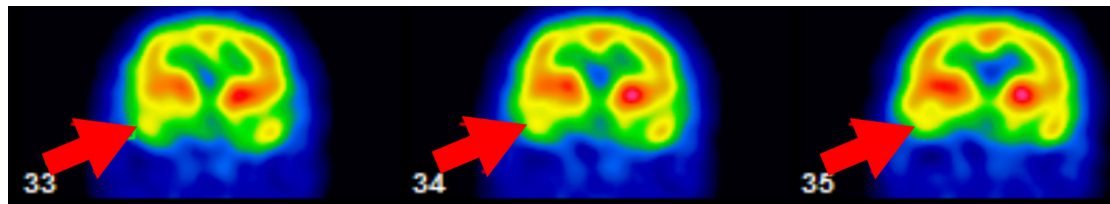


Supplementary Figure S1. Electroencephalogram demonstrated a continuous diffuse slowing in the theta and delta ranges (Case 2).



Supplementary Figure S2. The cerebral perfusion scan with single-photon emission computed tomography (SPECT) that indicated hypoperfusion in the right temporal region (Case 2).