applied sciences

MDPI

Case Report

Fully Digital Guided Single-Stage Maxillectomy and Zygomatic Implant Rehabilitation After Recurrent Oral Squamous Cell Carcinoma: A Case Report

Giada Anna Beltramini [1,2], Francesco Zingari [3], Francesco Montan [2], Margherita Tumedei [1,2,*], Massimo Del Fabbro [1,2] and Alessandro Remigio Bolzoni [1]

[1] Maxillo-Facial Surgery and Dental Unit, Fondazione IRCCS Ca' Granda Ospedale Maggiore Policlinico, 20122 Milano, Italy; giada.beltramini@unimi.it (G.A.B.); massimo.delfabbro@unimi.it (M.D.F.); alessandro.bolzoni@policlinico.mi.it (A.R.B.)
[2] Department of Biomedical, Surgical and Dental Sciences, University of Milan, Via della Commenda 10, 20122 Milan, Italy; francesco.montan@unimi.it
[3] Department of Maxillofacial Surgery, Galeazzi Hospital, 20157 Milan, Italy; francescozingari@gmail.com
* Correspondence: margherita.tumedei@unimi.it

Abstract

Background: The rehabilitation of patients who have undergone extensive maxillectomy for neoplastic lesions is a significant clinical challenge. The resulting anatomical and functional defects severely impact quality of life, and traditional removable prostheses often lack stability. Zygomatic implants offer a viable solution by providing stable anchorage in the zygomatic bone, bypassing the need for bone reconstruction. **Methods:** This case report details the rehabilitation of a 62-year-old female patient with a history of recurrent oral squamous cell carcinoma. A fully digital workflow, including CBCT and CAD/CAM technology, was used for meticulous surgical and prosthetic planning. The surgical procedure involved a guided maxillectomy, a free forearm flap reconstruction, and the simultaneous placement of two zygomatic implants and one conventional implant. The procedure was done with EZGOMA guided surgery, which, starting from the EZPLAN software design of zygomatic and traditional implants, allowed us to determine the implant's position in the three-dimensional axes and also the position of the internal hexagon. This allowed us to design the implant beneath the diagnostic wax-up in the three axes, and also to calculate the degrees of inclination of the multi-unit abutment. **Results:** All implants achieved primary stability with a torque exceeding 45 Ncm. The patient received an immediate provisional prosthesis, which allowed for the rapid restoration of phonetic and esthetic function. The post-operative course was uneventful, with no complications. Follow-up imaging confirmed the successful integration of the implants and the absence of any prosthetic or surgical issues at 24-month successful follow-up. **Conclusions:** This case suggests that implant-supported rehabilitation with zygomatic implants can be a highly effective treatment for patients with severe maxillary defects following cancer surgery. By using an integrated surgical and prosthetic strategy, along with advanced digital technology, we can achieve fast, safe, and predictable results. This approach successfully restores both function and esthetics, even in challenging anatomical situations. The auxilium of guided plates is a helpful aid for both implant placement and managing bone resection during cancer surgery.

Keywords: oral cancer; reconstructive surgery; dental implant; zygomatic implant

Check for updates

Academic Editors: Mario Taba, Jr., Erick Ricardo Silva and Ester Alves Ferreira Bordini

Received: 11 March 2026
Revised: 15 June 2026
Accepted: 23 June 2026
Published: 30 June 2026

Copyright: © 2026 by the authors. Licensee MDPI, Basel, Switzerland. This article is an open access article distributed under the terms and conditions of the Creative Commons Attribution (CC BY) license.

1. Introduction

The management of patients who have undergone ablative surgery for facial skeleton neoplasms represents a significantly complex clinical challenge [1–4]. The resection of large portions of the maxilla, while necessary for treating the disease, often results in severe anatomical and functional defects [3,5]. These defects not only compromise facial esthetics but also deeply impact the patient's quality of life, affecting chewing, speech, swallowing, and consequently, nutrition and socialization [6]. The rehabilitation of these patients requires a multidisciplinary approach involving surgeons, oncologists, prosthodontists, and psychologists [7]. Traditionally, prosthetic options were based on removable dentures or conventional obturators [1]. However, the instability of these solutions, due to the reduced support surface and post-surgical anatomical changes, significantly limits their effectiveness [8]. These prostheses can often cause complications like contact mucositis and are not able to fully restore oral functions and aesthetics. In this context, zygomatic implantology has emerged as a revolutionary technique for the rehabilitation of patients with extensive maxillary defects [9]. Initially developed by Brånemark for patients with severe maxillary atrophy, zygomatic implants offer stable anchorage in the robust zygomatic bone, which is often not involved or is less affected by ablative surgery [10]. This approach makes it possible to overcome the lack of bone in the maxillary region and to avoid complex bone grafting procedures [11].

Previous or post-operative oncological treatment may substantially influence implant-based rehabilitation after maxillary resection [12]. Radiotherapy can reduce bone vascularity, impair remodeling and wound healing, and negatively affect osseointegration; therefore, radiation dose, field distribution, timing of implant placement, residual bone quality and expected adjuvant treatment should be considered during surgical-prosthetic planning [3,5]. In patients requiring maxillectomy, zygomatic implants may provide remote anchorage in bone that is often outside the main resection field, but their use remains technically demanding and should be planned within a multidisciplinary pathway that includes oncological, reconstructive and prosthetic objectives [10,11]. While zygomatic implants have been described for delayed rehabilitation of post-oncological maxillary defects, fewer reports have focused on an integrated single-stage approach combining guided oncological resection, guided zygomatic implant placement, free-flap reconstruction and early/immediate prosthetic provisionalization [11]. The present case was therefore reported to illustrate how digital planning may coordinate resection margins, implant trajectories, abutment angulation and provisional prosthetic emergence in a recurrent oral cancer patient with complex maxillary anatomy.

Rehabilitation with zygomatic implants in cancer patients can be planned in two main phases. The first is the pre-prosthetic phase. This phase includes surgical planning, which often uses digital technologies (CAD/CAM) for creating surgical guides and virtual simulation of the procedure [13,14]. The primary stability of the implants is a crucial factor for the success of the rehabilitation [15–17]. The implants can be inserted at the same time as the ablative surgery or at a later stage, depending on the clinical protocol and the patient's condition [18]. This solution, unlike removable dentures, offers superior stability and functionality, drastically improving chewing ability, speech, and esthetics [19]. Numerous studies have shown that the use of prostheses supported by zygomatic implants leads to a significant improvement in quality-of-life scores and chewing function, and a reduction in psychological stress and anxiety related to post-operative disfigurement. Although zygomatic implantology represents an effective solution, the surgical procedure is complex and requires a deep knowledge of facial anatomy [20–24]. Complications, while rare, can include infections, sinus issues, and, in the long term, mechanical failures [24,25]. Therefore, patient selection and meticulous planning are essential to ensure the success of the

treatment [24,25]. The aim of the present investigation was to describe a clinical case report of patient rehabilitation through zygomatic implants after ablative neoplastic treatment.

2. Case Report

A 62-year-old woman previously treated for a well-differentiated squamous cell carcinoma of the maxillary alveolar crest relapsed at the tumor site. The first operation consisted of maxillectomy with dental alveolar resection of sites 2.2 to 1.2 and simultaneous reconstruction using a microvascular free flap from the medial femoral condyle. Histopathology showed pT4a squamous cell cancer (SCC) with bone infiltration, no perineural or vascular invasion, and clear margins. The patient refused adjuvant radiotherapy. During follow-up, 5 years after first diagnosis, a persistent proliferative verrucous hyperplasia-like lesion associated with chronic lichenoid inflammation was identified.

2.1. Surgery Resection

It is important to note that the patient had previously undergone surgery, also under general anesthesia, for the removal of an SCC of the oral cavity in the maxillary alveolar crest region. This prior procedure involved a maxillectomy and the avulsion of dental elements 22 to 12, with simultaneous reconstruction using a microvascular free flap from the medial femoral condyle. The final diagnosis had indicated a well-differentiated squamous cell carcinoma (G1), infiltrating the underlying bone component, with no perineural infiltration, no vascular invasion, and clear resection margins (pT4a). Following the persistent presence of a proliferative verrucous hyperplasia-like lesion associated with chronic lichenoid inflammation during follow-ups, an incisional biopsy was performed, which yielded a diagnosis of carcinoma in situ.

2.2. Second-Stage Surgery

Incisional biopsy demonstrated carcinoma in situ. Total-body CT staging showed perilesional bone infiltration and suggested a clinical TMN (tumor-node-metastasis system) stage of cT4a N0 M0. This was achieved through a maxillectomy and the avulsion of dental elements 13 to 15, followed by reconstruction with a free forearm flap and implant-supported prosthetic rehabilitation using both zygomatic and conventional implants.

After guided resection and intraoperative confirmation of negative margins, two zygomatic implants were placed in the right zygoma and one conventional implant was placed in the residual maxilla at site 2.3.

2.3. Implant Positioning

Implants were inserted before final flap inset to maintain direct surgical access to the zygomatic bone, preserve the prosthetically guided trajectory, verify abutment emergence and minimize the risk that flap bulk or post-operative edema would obscure the prosthetic components. Dedicated angled multi-unit abutments (MUAs) were selected according to the preoperative prosthetic plan. The radial forearm free flap was then inset and anastomosed to reconstruct the soft-tissue defect.

A healing guide/bar was used during the early post-operative phase to support the flap and maintain access to the MUA healing components. A provisional prosthesis from sites 1.6 to 2.2 was delivered after 7 days. Clinical and radiographic follow-up was performed after 7 days and then at 6-month oncological follow-up imaging (a total-body CT). At the last follow-up of 24 months, implant survival was 100%, the prosthesis was functional, and oncological status was negative.

2.4. Prosthetic Management

Prior to the surgical intervention, a case study was conducted by collecting various files to create a surgical plan based on a prosthetic design (Figure 1). A custom-made CAD-designed plate was created for the guided resection of the maxilla involved with the neoplastic lesion.

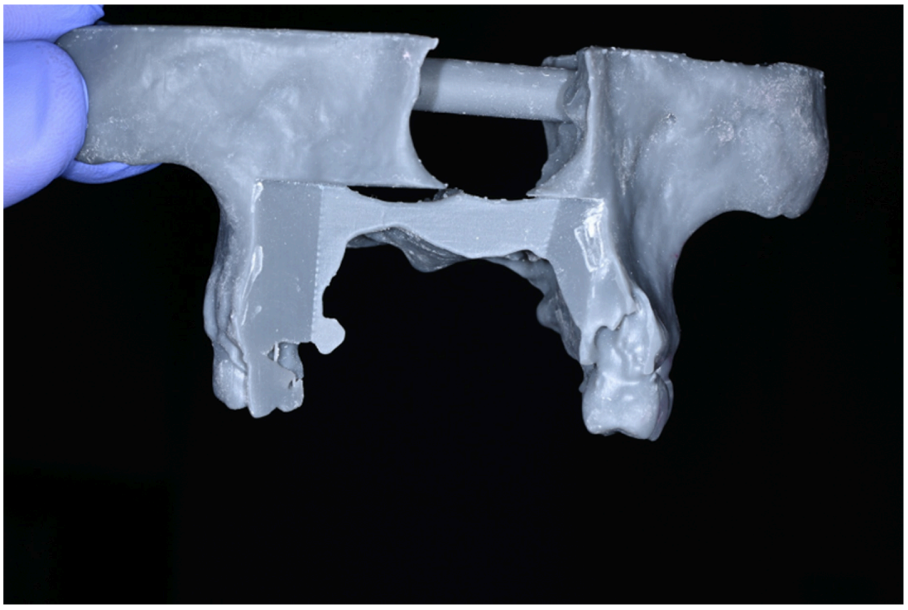

Figure 1. Detail of the stereolithographic template with the resection planning.

To design it, the following was carried out: a CBCT scan with a custom-made stent, mucosal defect compensation with polyether material, segmentation of the maxilla involved with the lesion, STL impressions with intraoral scanners for the upper and lower jaws, a check bite, and a digital max-up of the area to be resected (Figure 2). The overlapping of the files was managed using multiple software programs: EzPlan for the zygomatic surgical plan, ProPlan Materialise for designing the oncological resection guide, Exocad for the healing guide, and EZgoma for the guided surgery.

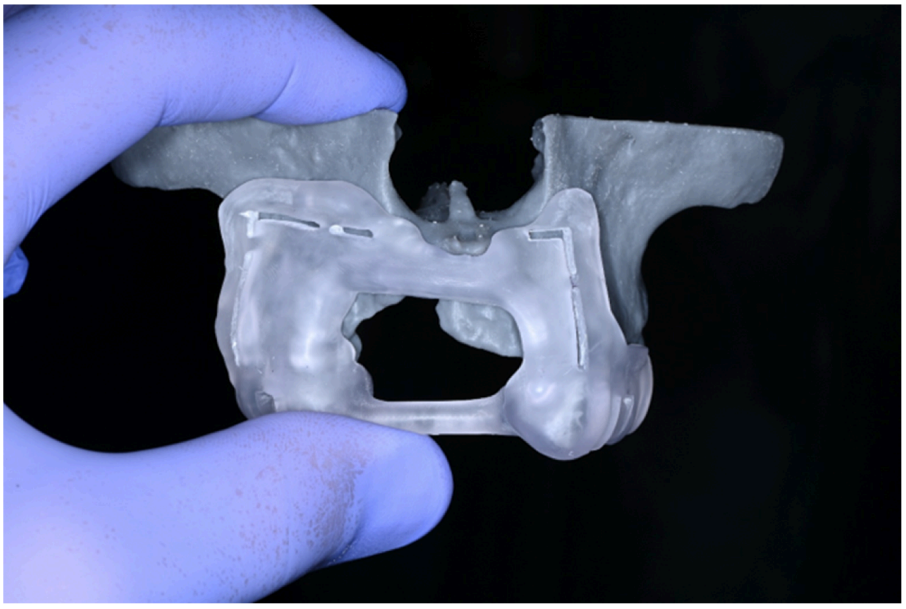

Figure 2. Detail of the stereolithographic template with the surgical guide for resection.

The surgery, following a pre-drawn area, led to the guided removal of the resected maxillary segment (Figure 3). Subsequently, after completing the resection and ensuring negative margins, two zygomatic implants were placed in the right zygoma, and one conventional implant was placed at the level of element 2.3 (Figures 4–7).

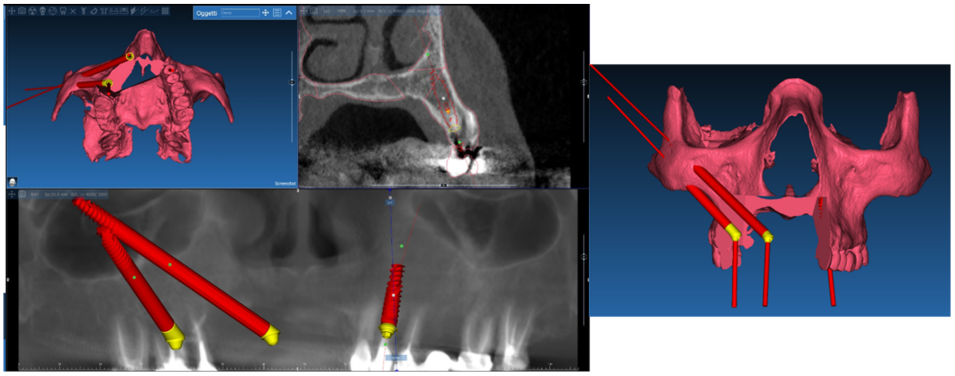

Figure 3. Panorex CBCT projection illustrating the plan for the zygomatic implant positioning.

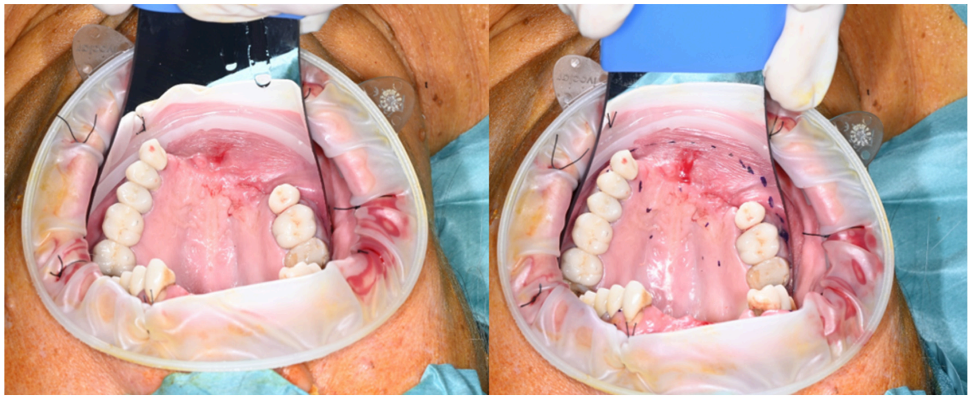

Figure 4. Pre-operative occlusal view of the clinical case with resection marks visible in the right panel.

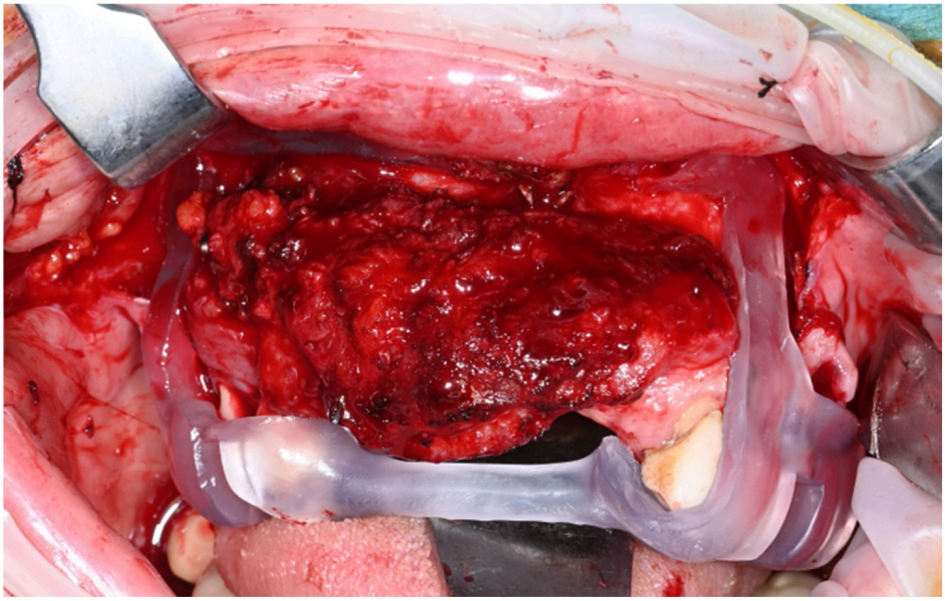

Figure 5. Intraoperative view of the flap during tumor resection using the surgical template.

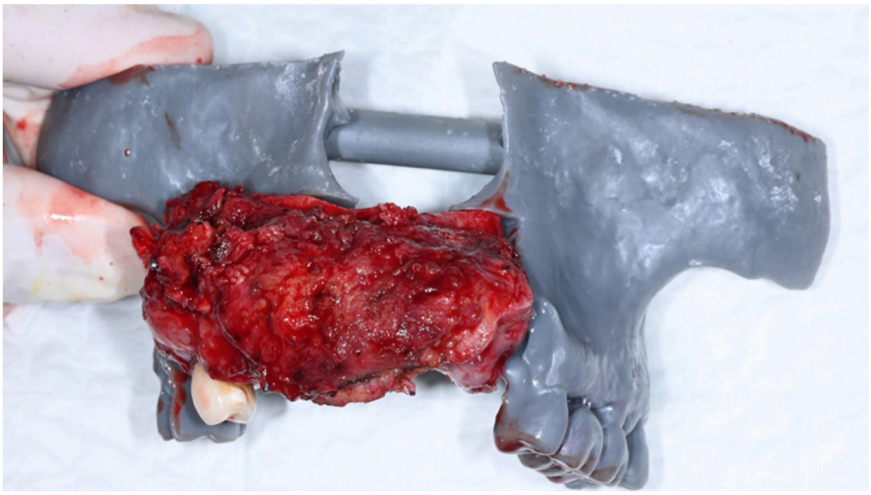

Figure 6. Matching of the surgical resection in the stereolithography template.

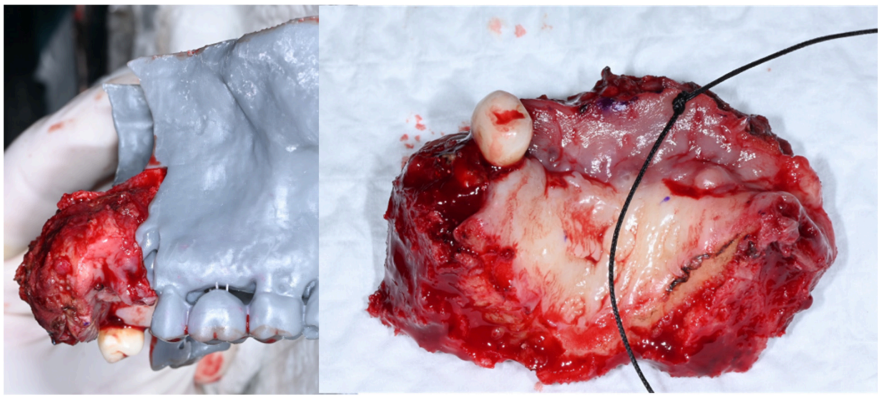

Figure 7. Detail of the tumor orientation in latero-lateral view.

The three implants were inserted with a torque exceeding 45 Ncm, and dedicated angled multi-unit abutments (MUAs) were placed to ensure the correct prosthetic axis. After positioning the healing abutments for the MUAs, the free forearm flap was positioned and anastomosed (Figures 8–10).

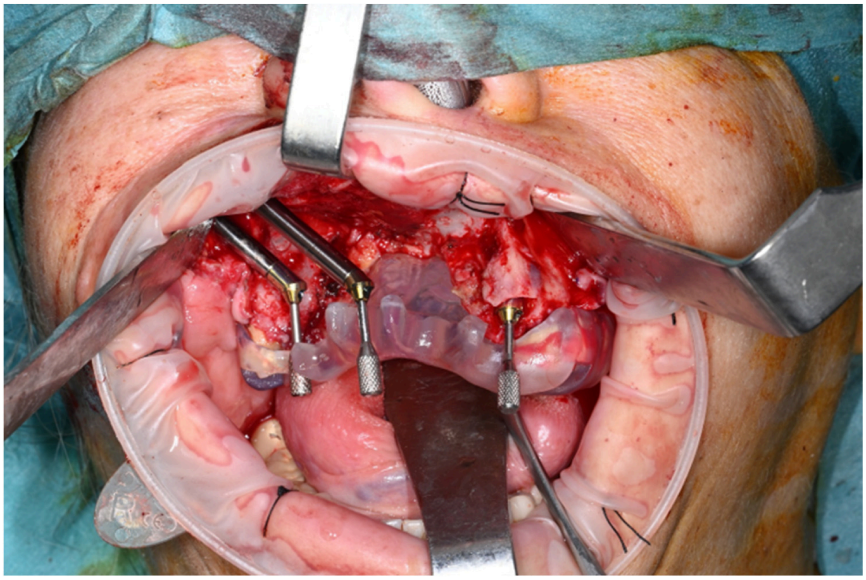

Figure 8. Direct mounting of MUA abutment and parallelism management.

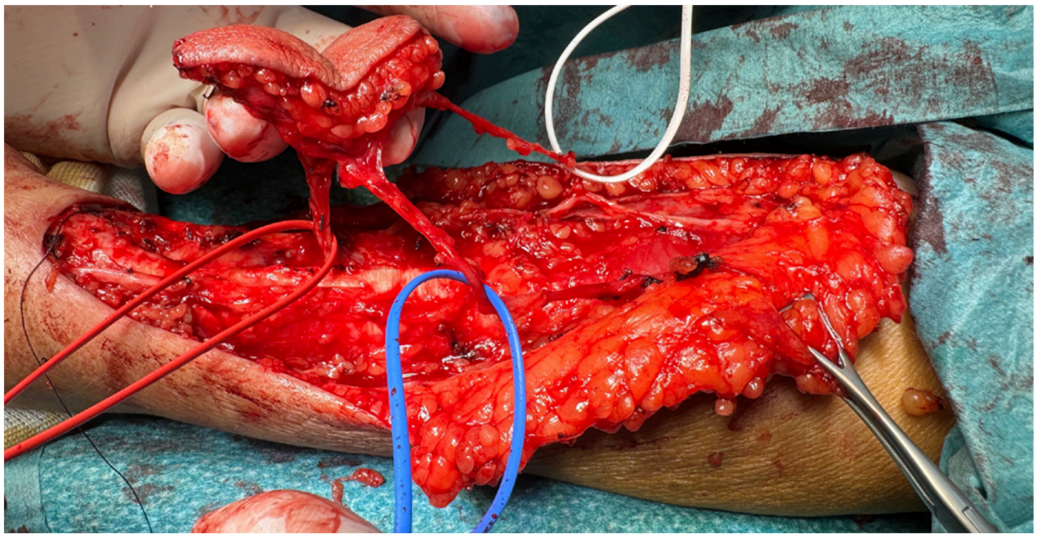

Figure 9. Detail of forearm flap access.

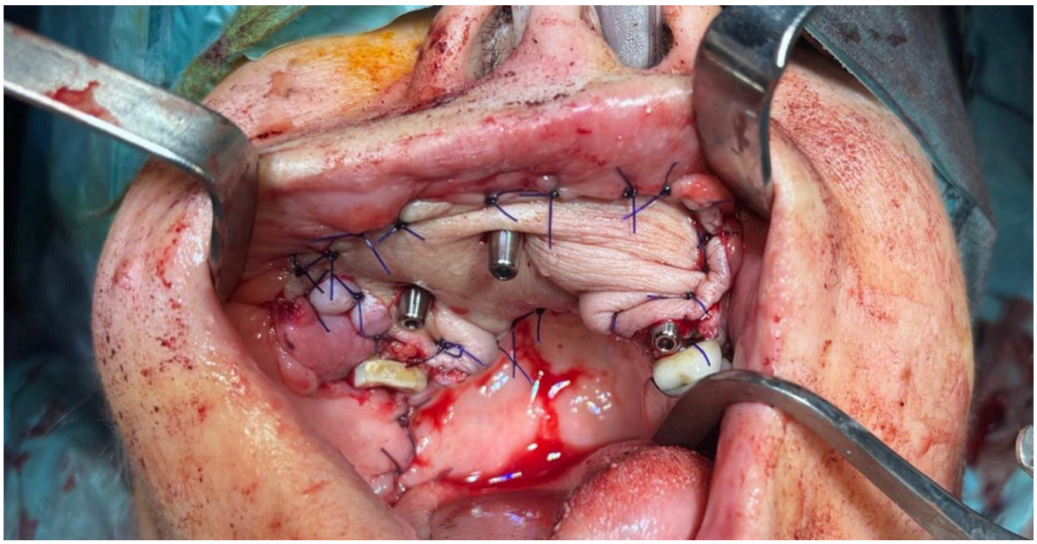

Figure 10. Intraoral view of the upper arch after suture positioning.

During the first two days of post-operative healing, a healing guide (mentioned previously, made with Exocad) was applied to support the forearm flap and prevent its collapse, which could lead to invagination of the healing abutments (Figures 11–14). After another five days of post-operative recovery, a provisional prosthesis from elements 1.6 to 2.2 was placed on the three MUAs, following the removal of the healing guide. This provisional prosthesis's purpose was to functionalize the patient's lip and the forearm flap to avoid possible lip incompetence and immediately restore esthetics to the patient's appearance. The use of a healing bar allowed us to produce a temporary, immediate-load prosthesis within 48 h. The purpose was to prevent the post-surgical swelling of the gum tissue from covering the prosthetic components. This guided the healing process and allowed the temporary prosthesis to be inserted at 48 h without needing to perform any additional surgery to locate the implants under the swollen mucosa.

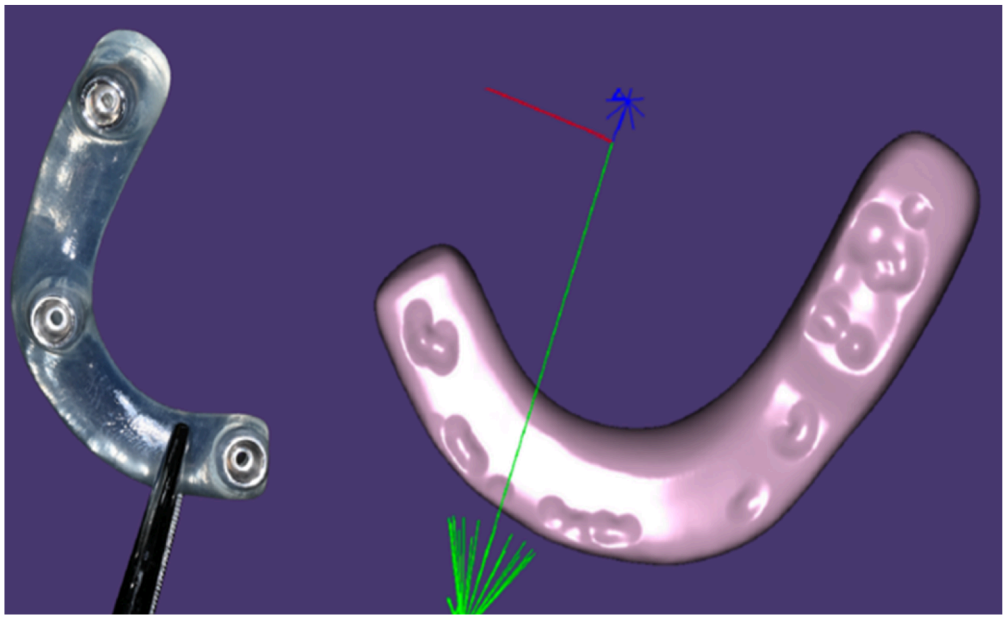

Figure 11. CAD-CAM planning and production of the prosthetic super-structure.



Figure 12. Clinical picture 11 days after the treatment.



Figure 13. Detail of the prosthetic space 11 days after the treatment.

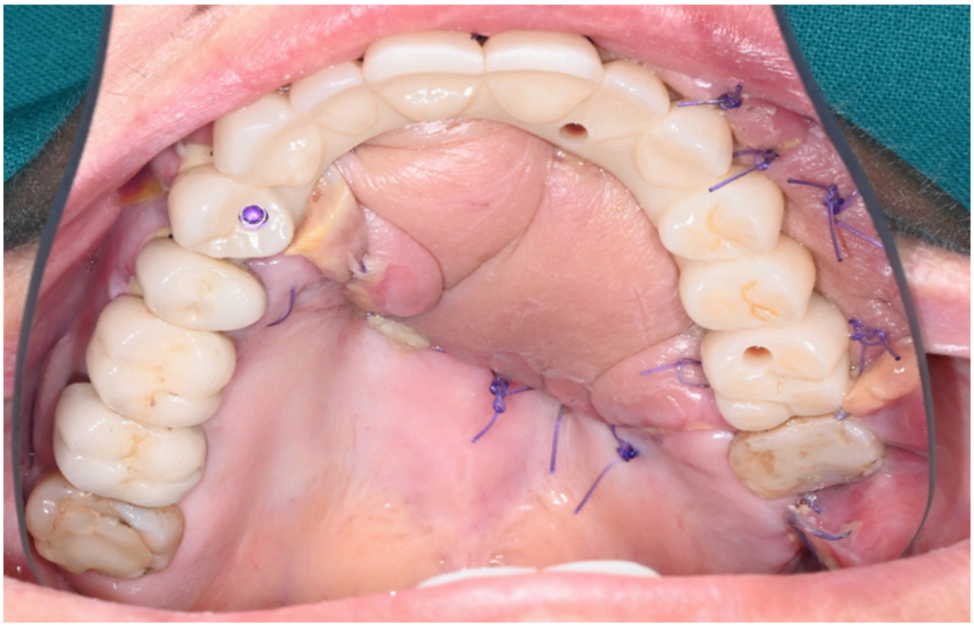

Figure 14. Occlusal view 11 days after the treatment.

The post-operative course was uneventful, with no surgical complications. Immediate loading, as mentioned earlier, allowed for quick restoration of phonetic and esthetic function (Figures 11–15). The follow-up imaging showed no prosthetic or surgical issues.



Figure 15. Lateral view 11 days after the treatment.

3. Discussion

The scientific literature on the use of zygomatic implants for post-oncological maxillary reconstruction is a growing field of research [11,26,27]. Numerous studies highlight their effectiveness and benefits, as well as the challenges and potential complications [11,26,27]. The main goal of this technique in an oncological setting is to provide stable anchorage for fixed prosthetic rehabilitation in patients who have experienced severe maxillary bone loss due to extensive surgical resections for facial skeleton tumors [11,28]. A crucial point that has emerged from the literature is that zygomatic implants offer remote anchorage in the robust zygomatic bone, thus bypassing the need for complex bone grafting procedures [11]. Many studies and systematic reviews report high survival rates for zygomatic implants, with percentages ranging from 77% to 100%. A more in-depth analysis has shown a 12-year cumulative survival rate of 96.7% for patients with severe maxillary atrophy and a range between 78.6% and 91.7% for cancer patients [27]. This difference can be attributed to factors such as the general unhealthy condition of the oncologic patients, and radiotherapy, which can negatively influence bone healing. However, even in irradiated patients, zygomatic implants have proven to be successful, albeit with a slightly higher risk of failure [27]. Furthermore, many studies, including case reports and prospective studies, have shown a significant improvement in patients' quality of life after rehabilitation with zygomatic implants. This improvement is measured through specific questionnaires and is seen in better chewing, speech, and esthetic function, as well as a reduction in psychological stress and anxiety associated with post-surgical disfigurement [29].

The main contribution of this case is the integration of oncological, reconstructive and prosthetic objectives within a single digitally planned workflow. In contrast with delayed rehabilitation pathways, which may require multiple surgical stages and prolonged use of removable obturators, the present approach was designed to preserve prosthetic emergence and provide early fixed provisional restoration while simultaneously reconstructing the soft-tissue defect. The choice of a radial forearm free flap was based on the need for a thin, pliable, reliable soft-tissue flap with a long pedicle in a premaxillary defect requiring mucosal lining and prosthetic compatibility. Compared with osseous flaps such as fibula, scapula or iliac crest flaps, the radial forearm flap does not restore bony support for conventional implants. This limitation was addressed by using zygomatic anchorage, which allowed implant support to be obtained remotely from the resected maxillary bone. The guided workflow was clinically useful because it allowed simultaneous visualization of the planned resection, residual anatomy, implant trajectory, prosthetic wax-up and MUA angulation. Nevertheless, the present report cannot prove superior accuracy of guided surgery unless post-operative deviation analysis is performed. This limitation has been stated explicitly.

This case should also be interpreted cautiously in light of its oncological context. Radiotherapy, when present, may increase the risk of implant failure and soft-tissue complications. Therefore, the patient's adjuvant treatment history, as well as the field and dose of radiation applied to the zygomatic bone, are important variables for interpreting the outcome and for comparing this case with published oncological cohorts.

This report has several limitations. It describes a single selected patient and therefore cannot establish generalizable effectiveness or safety. Follow-up is limited to24 months, and long-term implant survival, peri-implant tissue stability and oncological outcomes require continued observation. No post-operative superimposition analysis was performed to quantify guided surgery accuracy. These limitations should be addressed in future studies.

This approach ensures superior stability and functionality compared to removable prostheses such as conventional obturators, which, while an alternative, often suffer from

poor retention and stability [6]. Zygomatic implants can also be used in combination with microvascular free flaps to provide prosthetic anchorage in complex reconstructions [6].

Although zygomatic implantology is considered a reliable technique, the literature also reports potential complications, although their incidence is generally low. The most frequently reported biological complications include sinusitis, oro-antral fistulas, and peri-implantitis. Sinusitis, in particular, is a common complication due to the implants' proximity to the maxillary sinus [25]. Radiotherapy is a known risk factor for implant failure, although recent studies show that zygomatic implants can be used successfully even in irradiated patients [3]. The location and size of the tumor, which influence the dose of radiation applied to the zygomatic bone, are critical factors to consider. The surgical procedure is complex and requires a deep understanding of the anatomy of the maxilla and zygoma. For patients who have undergone ablative surgery of the upper jaw due to a neoplastic lesion, the therapeutic alternatives for reconstruction are numerous and should be evaluated based on factors like the extent of the defect, age, systemic condition, oncological prognosis, and the patient's functional and esthetic expectations [5,22,30]. Vosselman et al. reported that the survival rate of ZIs placed in non-irradiated patients was 100%, and 85% in irradiated subjects [30]. Similar results were obtained from a study of 42 zygomatic implants positioned after maxillectomy [23].

A microvascular free flap, such as those from the fibula, scapula, or iliac bone, or an anterolateral thigh or forearm flap (for soft-tissue reconstructions only) can provide three-dimensional restoration of the defect with possible secondary implant-prosthetic rehabilitation, even with traditional, pterygoid, or nasal fixtures [1]. The ideal therapeutic choice must balance several key points, such as the extent and location of the defect, the patient's age and comorbidities, functional goals including chewing and speech, and the availability of an experienced and multidisciplinary surgical team. Zygomatic implantology often proves to be one of the most effective and least invasive solutions for achieving immediate and fixed rehabilitation in patients who are not candidates for major reconstructions. In summary, the scientific literature supports the use of zygomatic implants as a predictable and effective treatment modality for the prosthetic rehabilitation of patients with post-oncological maxillary defects. They offer a valid and often superior alternative to traditional methods, contributing to a significant improvement in patients' quality of life and oral functions, although complication management and surgical planning remain crucial aspects of clinical success.

4. Conclusions

In this selected patient with a recurrent/maxillary oncological defect, a fully digital guided workflow enabled coordination of maxillary resection, zygomatic/conventional implant placement, radial forearm free-flap reconstruction and early fixed provisional rehabilitation. This approach may help shorten the functional rehabilitation pathway in carefully selected patients, particularly when conventional maxillary implant placement is not feasible. However, conclusions must remain cautious because this is a single case report; longer follow-up and larger series with quantitative implant, prosthetic, oncological and patient-reported outcomes are needed.

Author Contributions: Conceptualization, G.A.B. and A.R.B.; methodology, M.T., M.D.F. and G.A.B.; software, F.Z. and F.M.; validation, M.D.F., M.T., G.A.B. and A.R.B.; formal analysis, M.D.F. and G.A.B.; investigation, F.Z., A.R.B. and F.M.; resources, A.R.B.; data curation, M.D.F., G.A.B., M.T. and F.Z.; writing—original draft preparation, M.D.F., M.T. and G.A.B.; writing—review and editing, M.D.F., M.T. and G.A.B.; visualization, F.Z., F.M. and A.R.B.; supervision, G.A.B. and M.D.F.; project administration, F.Z. All authors have read and agreed to the published version of the manuscript.

Funding: This research received no external funding.

Institutional Review Board Statement: According to European Regulation (EU) no. 536/2014 on Clinical Trials and a National decree (No. 52/2019), to which Italian Ethical Committees adhere, ethical committee approval was not necessary for a single case report in the Institution where the authors work. The authors adhered to the principles embedded in the WMA Helsinki Declaration of 2013 regarding patient care.

Informed Consent Statement: Informed consent was obtained from the subject for their involvement in the study and for the use of their clinical and radiographical images.

Data Availability Statement: The data are available upon request from the corresponding author.

Conflicts of Interest: The authors declare no conflicts of interest.

References

1. Yenisey, M.; Külünk, Ş.; Kaleli, N. An Alternative Prosthetic Approach for Rehabilitation of Two Edentulous Maxillectomy Patients: Clinical Report. *J. Prosthodont.* **2017**, *26*, 483–488. [CrossRef] [PubMed]
2. Gaur, V.; Perumal, S.M.; Rahmaan, F.; Pałka, Ł. A Practical Approach to Orofacial Rehabilitation in a Patient after Inferior Maxillectomy and Rhinectomy with Mono Framework Construction Supported on a Zygomatic Implant Placed in the Glabella: A Case Report. *Maxillofac. Plast. Reconstr. Surg.* **2021**, *43*, 25. [CrossRef] [PubMed]
3. Salvatori, P.; Mincione, A.; Rizzi, L.; Costantini, F.; Bianchi, A.; Grecchi, E.; Garagiola, U.; Grecchi, F. Maxillary Resection for Cancer, Zygomatic Implants Insertion, and Palatal Repair as Single-Stage Procedure: Report of Three Cases. *Maxillofac. Plast. Reconstr. Surg.* **2017**, *39*, 13. [CrossRef] [PubMed]
4. Edher, F.; Nguyen, C.T. Short Dental Implants: A Scoping Review of the Literature for Patients with Head and Neck Cancer. *J. Prosthet. Dent.* **2018**, *119*, 736–742. [CrossRef] [PubMed]
5. Boyes-Varley, J.G.; Howes, D.G.; Davidge-Pitts, K.D.; Brånemark, P.-I.; McAlpine, J.A. A Protocol for Maxillary Reconstruction Following Oncology Resection Using Zygomatic Implants. *Int. J. Prosthodont.* **2007**, *20*, 521–531. [PubMed]
6. Ozaki, H.; Ishikawa, S.; Kitabatake, K.; Yusa, K.; Sakurai, H.; Iino, M. Functional and Aesthetic Rehabilitation with Maxillary Prosthesis Supported by Two Zygomatic Implants for Maxillary Defect Resulting from Cancer Ablative Surgery: A Case Report/Technique Article. *Odontology* **2016**, *104*, 233–238. [PubMed]
7. Bidra, A.S.; May, G.W.; Tharp, G.E.; Chambers, M.S. Pterygoid Implants for Maxillofacial Rehabilitation of a Patient with a Bilateral Maxillectomy Defect. *J. Oral Implantol.* **2013**, *39*, 91–97. [CrossRef] [PubMed]
8. Sun, J.; Shen, Y.; Li, J.; Zhang, Z.-Y. Reconstruction of High Maxillectomy Defects with the Fibula Osteomyocutaneous Flap in Combination with Titanium Mesh or a Zygomatic Implant. *Plast. Reconstr. Surg.* **2011**, *127*, 150–160. [CrossRef] [PubMed]
9. Lacroix, T.; Jaby, P.; Nokovitch, L.; Chaux-Bodard, A.G. Prosthetic Rehabilitation with Zygomatic Implants after Maxillectomy: A Systematic Review. *J. Dent. Oral Disord.* **2020**, *6*, 1132.
10. Aparicio, C.; Ouazzani, W.; Hatano, N. The Use of Zygomatic Implants for Prosthetic Rehabilitation of the Severely Resorbed Maxilla. *Periodontology* **2000**, *2008*, 47.
11. Lorusso, F.; Conte, R.; Inchingolo, F.; Festa, F.; Scarano, A. Survival Rate of Zygomatic Implants for Fixed Oral Maxillary Rehabilitations: A Systematic Review and Meta-Analysis Comparing Outcomes between Zygomatic and Regular Implants. *Dent. J.* **2021**, *9*, 38. [CrossRef] [PubMed]
12. Moreno Soriano, C.; Castañeda Vega, P.; Estrugo Devesa, A.; Jané Salas, E.; López López, J. Frequency and Type of Digital Procedures Used for the Intraoral Prosthetic Rehabilitation of Patients with Head and Neck Cancer: A Systematic Review. *J. Prosthet. Dent.* **2022**, *127*, 811–815. [CrossRef] [PubMed]
13. Alqutaibi, A.Y. CAD-CAM Surgically-Guided Oral Implant Site Expansion and Implant Placement in Severely Atrophic Maxilla. *J. Taibah Univ. Med. Sci.* **2020**, *15*, 153–159. [CrossRef] [PubMed]
14. Grecchi, E.; Stefanelli, L.V.; Grecchi, F.; Grivetto, F.; Franchina, A.; Pranno, N. A Novel Guided Zygomatic Implant Surgery System Compared to Free Hand: A Human Cadaver Study on Accuracy. *J. Dent.* **2022**, *119*, 103942. [CrossRef] [PubMed]
15. Antonelli, A.; Bennardo, F.; Brancaccio, Y.; Barone, S.; Femiano, F.; Nucci, L.; Minervini, G.; Fortunato, L.; Attanasio, F.; Giudice, A. Can Bone Compaction Improve Primary Implant Stability? An In Vitro Comparative Study with Osseodensification Technique. *Appl. Sci.* **2020**, *10*, 8623. [CrossRef]
16. Al-Jamal, M.F.J.; Al-Jumaily, H.A. Can the Bone Density Estimated by CBCT Predict the Primary Stability of Dental Implants? A New Measurement Protocol. *J. Craniofac. Surg.* **2021**, *32*, e171–e174. [CrossRef] [PubMed]
17. Cavallaro, J.; Greenstein, B.; Greenstein, G. Clinical Methodologies for Achieving Primary Dental Implant Stability: The Effects of Alveolar Bone Density. *J. Am. Dent. Assoc.* **2009**, *140*, 1366–1372. [CrossRef] [PubMed]

18. Weyh, A.; Quimby, A.; Salman, S. Zygomatic Implants in Avulsive and Ablative Defects. *Atlas Oral Maxillofac. Surg. Clin.* **2021**, *29*, 271–276. [CrossRef]
19. Aparicio, C.; Manresa, C.; Francisco, K.; Ouazzani, W.; Claros, P.; Potau, J.M.; Aparicio, A. The Long-Term Use of Zygomatic Implants: A 10-Year Clinical and Radiographic Report. *Clin. Implant. Dent. Relat. Res.* **2014**, *16*, 447–459. [CrossRef] [PubMed]
20. Schiegnitz, E.; Reinicke, K.; Sagheb, K.; König, J.; Al-Nawas, B.; Grötz, K.A. Dental Implants in Patients with Head and Neck Cancer-A Systematic Review and Meta-Analysis of the Influence of Radiotherapy on Implant Survival. *Clin. Oral Implants Res.* **2022**, *33*, 967–999. [CrossRef] [PubMed]
21. Shokouhi, B.; Cerajewska, T. Radiotherapy and the Survival of Dental Implants: A Systematic Review. *Br. J. Oral Maxillofac. Surg.* **2022**, *60*, 422–429. [CrossRef] [PubMed]
22. Al-Nawas, B.; Aghaloo, T.; Aparicio, C.; Bedrossian, E.; Brecht, L.; Brennand-Roper, M.; Chow, J.; Davó, R.; Fan, S.; Jung, R.; et al. ITI Consensus Report on Zygomatic Implants: Indications, Evaluation of Surgical Techniques and Long-Term Treatment Outcomes. *Int. J. Implant. Dent.* **2023**, *9*, 28. [CrossRef] [PubMed]
23. Mathevosyan, D.; Hovhannisyan, S.; Mashinyan, K.; Khachatryan, L.; Badalyan, A.; Hakobyan, G. Prosthetic Rehabilitation of Patients with Maxillary Oncology Defects Using Zygomatic Implants. *Int. J. Implant. Dent.* **2024**, *10*, 31. [CrossRef] [PubMed]
24. Mavriqi, L.; Lorusso, F.; Conte, R.; Rapone, B.; Scarano, A. Zygomatic Implant Penetration to the Central Portion of Orbit: A Case Report. *BMC Ophthalmol.* **2021**, *21*, 121. [CrossRef] [PubMed]
25. Chrcanovic, B.R.; Abreu, M.H.N.G. Survival and Complications of Zygomatic Implants: A Systematic Review. *Oral Maxillofac. Surg.* **2013**, *17*, 81–93. [CrossRef] [PubMed]
26. Gómez-Pedraza, A.; González-Cardín, V.; Díez-Suárez, L.; Herrera-Villalva, M. Maxillofacial Rehabilitation with Zygomatic Implants in an Oncologic Patient: A Case Report. *J. Oral Maxillofac. Surg.* **2020**, *78*, 547–556. [CrossRef] [PubMed]
27. Hackett, S.; El-Wazani, B.; Butterworth, C. Zygomatic Implant-Based Rehabilitation for Patients with Maxillary and Mid-Facial Oncology Defects: A Review. *Oral Dis.* **2020**, *27*, 27–41. [CrossRef] [PubMed]
28. Troncoso-Pazos, J.; Matamala, P.; Jusari, M.F.; Risco, K.; Aguilera, F.-R.; Aravena, P.C. Position of Digitally Guided Implants in Completely Edentulous Maxillae by Using a Modified Double-Scan and Overlap of Three Digital Surface Protocol. *J. Prosthet. Dent.* **2023**, *133*, 780–789. [CrossRef] [PubMed]
29. Scarano, A.; Conte, R.; Murmura, G.; Lorusso, F.; Harrath, A.H. Satisfaction Grade Assessment of Patients Treated with Zygomatic Implants with Self-Tapping Apex and Machined Body. *J. Biol. Regul. Homeost. Agents* **2019**, *33*, 1651–1656. [CrossRef] [PubMed]
30. Vosselman, N.; Kraeima, J.; Siang, K.N.W.; Raghoebar, G.M.; Witjes, M.J.H.; de Visscher, S. Guided Placement of Zygomatic Implants in Head and Neck Cancer Patients: Implant Survival and Patient Outcomes at 1–3 Years of Follow-Up. *Int. J. Oral Maxillofac. Surg.* **2024**, *53*, 600–606. [CrossRef] [PubMed]

Disclaimer/Publisher's Note: The statements, opinions and data contained in all publications are solely those of the individual author(s) and contributor(s) and not of MDPI and/or the editor(s). MDPI and/or the editor(s) disclaim responsibility for any injury to people or property resulting from any ideas, methods, instructions or products referred to in the content.