applied sciences

MDPI

Review

Radicular Aberrations of Mandibular Third Molars: Relevance for Oral Surgery—A Comprehensive Narrative Review

Fabrizio Zaccheo [1], Giulia Petroni [2,*] and Andrea Cicconetti [1]

[1] Department of Oral and Maxillofacial Sciences, Sapienza University of Rome, 00185 Rome, Italy; fabrizio.zaccheo@uniroma1.it (F.Z.); andrea.cicconetti@uniroma1.it (A.C.)
[2] Private Practice, 00199 Rome, Italy
* Correspondence: giulia.petroni@live.it

Abstract

Background: Mandibular third molars (MTMs) are the most frequently impacted teeth and a common indication for oral surgery. Anatomical root variations can complicate extractions and increase intra- and postoperative risks. Methods: This narrative review analyzes the most frequent MTM root anomalies—supernumerary roots, fusion, taurodontism, C-shaped canals, hypercementosis, and apical dilacerations—focusing on their clinical implications and the diagnostic role of cone-beam computed tomography (CBCT). Results: Root anomalies markedly influence surgical complexity. Supernumerary roots and fusions may hinder elevator use and require modified sectioning. Taurodontism and hypercementosis prolong procedures and increase incomplete extraction risk. C-shaped canals and severe apical curvatures raise the likelihood of root fracture, displacement, or nerve injury. Panoramic radiographs, though common, provide limited two-dimensional detail and may underestimate anomalies. CBCT, by contrast, offers three-dimensional visualization, enhancing diagnosis, planning, and safety. Conclusions: Knowledge of MTM root anomalies, combined with selective CBCT use, is essential for optimizing surgical strategies, minimizing complications, and improving outcomes.

Keywords: mandibular third molars; root anomalies; CBCT; surgical complications; radix entomolaris; radix paramolaris; hypercementosis; taurodontism; dilaceration; c-shaped canals

check for updates

Academic Editors: Irene Pina-Vaz and Inês Ferreira

Received: 30 September 2025
Revised: 6 November 2025
Accepted: 28 November 2025
Published: 2 December 2025

Citation: Zaccheo, F.; Petroni, G.; Cicconetti, A. Radicular Aberrations of Mandibular Third Molars: Relevance for Oral Surgery—A Comprehensive Narrative Review. *Appl. Sci.* **2025**, *15*, 12756. https://doi.org/10.3390/app152312756

Copyright: © 2025 by the authors. Licensee MDPI, Basel, Switzerland. This article is an open access article distributed under the terms and conditions of the Creative Commons Attribution (CC BY) license (https://creativecommons.org/licenses/by/4.0/).

1. Introduction

Mandibular third molars (MTMs), commonly referred to as wisdom teeth, are the most frequently impacted teeth in the human dentition, with prevalence rates ranging from 16% to 68% depending on population and diagnostic criteria [1–3]. Impaction is often associated with pathological conditions, including pericoronitis, caries of adjacent second molars, external root resorption, periodontal bone loss, cyst formation, and, rarely, odontogenic tumors [1–3]. Consequently, surgical removal of MTMs is among the most common dentoalveolar procedures performed worldwide [4].

Although widely regarded as routine, MTM surgery remains challenging due to potential complications such as pain, swelling, trismus, alveolar osteitis, inferior alveolar or lingual nerve injury, and mandibular fracture [4]. Surgical difficulty is influenced not only by tooth position but also by root morphology and its spatial relationship to surrounding anatomical structures [5].

Aberrant root morphology is a critical determinant of surgical complexity. MTM roots may present unusual forms, including dilacerations, accessory or supernumerary roots, C-shaped canals, fusion, divergence, and apical curvature [6–9]. These aberrations are particularly significant in impacted MTMs, where restricted space often leads to complex root trajectories that complicate extraction by predisposing to root fracture, apical fragment displacement, or inadvertent injury to the inferior alveolar nerve [7,10]. Accurate preoperative identification of root anomalies is essential to determine the appropriate surgical approach, anticipate technical difficulties, and minimize iatrogenic complications [11]. Moreover, knowledge of root number and configuration is valuable for procedures such as autotransplantation, where donor tooth suitability depends heavily on root morphology [11,12].

Epidemiological studies highlight considerable variability in MTM root morphology across populations. Two-rooted forms predominate, followed by single-rooted molars, while three-rooted or more complex patterns are less frequent [6–17]. Fused or divergent roots are also reported, with mesio-distal divergence particularly common in two-rooted molars [9]. CBCT studies reveal that curved or hooked apices are often associated with impacted MTMs due to limited developmental space [6]. This spectrum of radicular variation underscores the necessity of detailed imaging for safe and predictable surgical outcomes.

While panoramic radiography remains widely used for preoperative evaluation due to accessibility, cost-effectiveness, and low radiation exposure, it has significant limitations, including distortion, magnification errors, and lack of three-dimensional information [18]. Conventional radiographs may underestimate anatomical complexity, especially in atypical root morphology or when the inferior alveolar canal (IAC) lies in close proximity.

CBCT has emerged as a superior modality, providing high-resolution three-dimensional views that allow precise characterization of root morphology and topographic relationships with surrounding structures. CBCT depicts the proximity and orientation of MTM roots to the IAC in axial, coronal, and sagittal planes and offers three-dimensional reconstructions. CBCT has improved diagnostic accuracy in high-risk cases, facilitating early detection of external root resorption, assessment of root proximity to the lingual plate, evaluation of complex canal morphology, and planning for autotransplantation [19].

The clinical impact of CBCT is well documented. Ghaeminia et al. [5] demonstrated that CBCT assessment significantly influenced surgical strategy compared with panoramic imaging, altering osteotomy and root sectioning approaches. Araújo et al. [18] confirmed in a systematic review that CBCT-based planning reduces iatrogenic nerve injury risk and supports conservative surgical interventions. Recent AI-assisted CBCT models also allow preoperative prediction of surgical difficulty [19].

Despite its advantages, CBCT is not indicated for routine use in all MTM cases due to radiation and cost considerations. Its use should be reserved for complex or high-risk situations where conventional imaging is insufficient [18].

Given the frequency of MTM extractions and variability in root morphology affecting surgical difficulty, a comprehensive review of clinically relevant radicular aberrations is needed. This narrative review synthesizes current evidence on the most common MTM root variations and their implications for oral surgery, emphasizing the role of CBCT in enhancing diagnostic precision and improving treatment outcomes.

2. Materials and Methods

2.1. Study Design

This work was designed as a narrative review with a structured search strategy, following the PRISMA 2020 recommendations adapted for narrative reviews. The aim was to provide a descriptive and educational synthesis of root aberrations in mandibular

third molars (MTMs), emphasizing their clinical relevance for oral surgery rather than performing a meta-analytical or statistical evaluation.

2.2. Search Strategy

A structured literature search was conducted in PubMed/MEDLINE, Scopus, and Web of Science from January 1990 to March 2025. Search terms were grouped as follows:

Target tooth: "mandibular third molar", "lower third molar", "wisdom tooth"

Aberration terms: "radix entomolaris", "radix paramolaris", "dilaceration", "taurodontism", "root fusion", "hypercementosis", "C-shaped canal", "root morphology", "radicular variation"

Diagnostic/clinical terms: "cone beam computed tomography", "CBCT", "radiography", "oral surgery", "surgical extraction"

Boolean operators ("AND", "OR") combined terms, and reference lists of selected papers were manually screened for additional studies.

2.3. Eligibility Criteria

The inclusion criteria comprised studies describing radicular aberrations or atypical root morphologies in mandibular third molars, using radiological (CBCT, micro-CT, panoramic, or periapical) or anatomical/histological methods.

Studies on other mandibular molars were considered contextually relevant if the same aberration was anatomically documented as potentially occurring in MTMs or held clinical relevance for third molar surgery.

Studies were excluded if they:

- Lacked original or detailed morphological data;
- Involved non-human or deciduous dentition;
- Were not written in English;
- Addressed aberrations unrelated to root anatomy.

While CBCT-based evidence formed the core of the analysis, 2D radiographic and non-MTM data were included solely as contextual background, clearly indicated as such in the tables and text.

2.4. Study Selection and Data Extraction

After duplicate removal, two independent reviewers screened titles and abstracts, followed by full-text evaluation of potentially eligible studies. Extracted data included author, year, population, sample characteristics, imaging method, and aberration type.

Given the narrative and descriptive design, data synthesis was qualitative rather than quantitative.

A total of 280 records were initially identified across databases. After screening and eligibility assessment, 11 studies met the inclusion criteria and were included in the final synthesis. A simplified PRISMA-style flow diagram (Figure 1) summarizes the selection process. Representative studies excluded from the final synthesis are listed in Table 1, while included studies forming the narrative synthesis are summarized in Table 2.

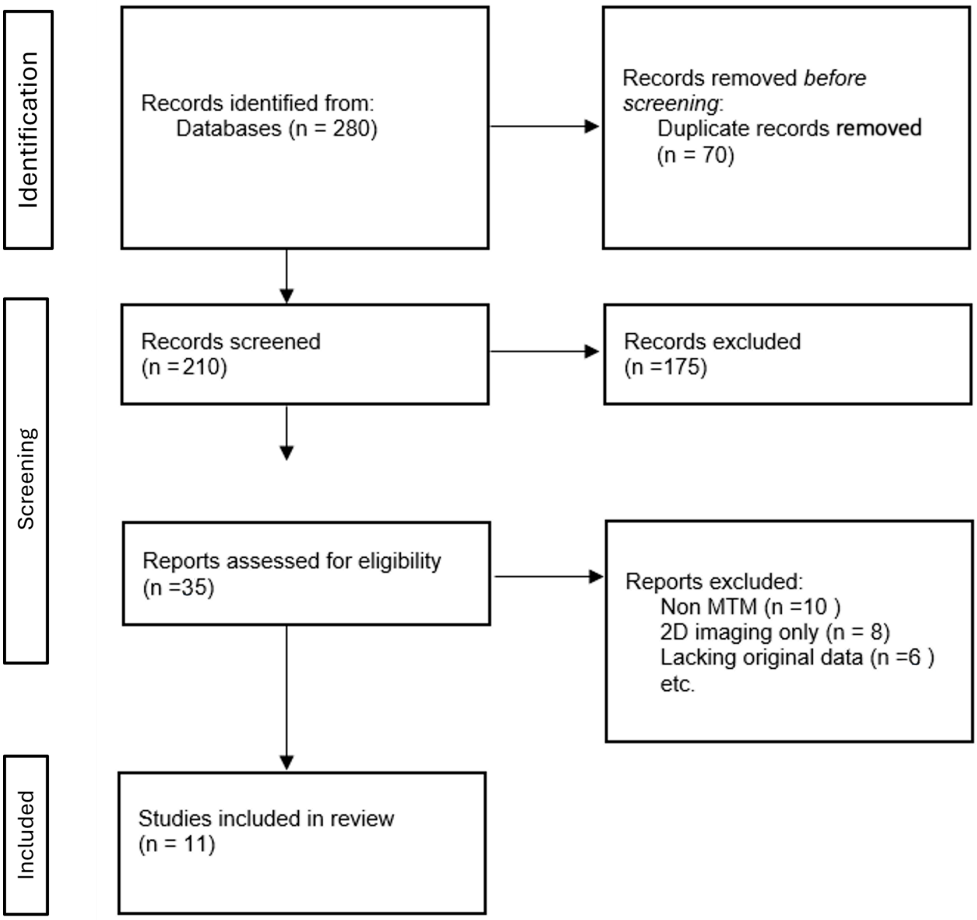

Figure 1. PRISMA Flow.

Table 1. Representative studies excluded from the final synthesis.

#	Author(s), Year	Population/Tooth Type	Imaging Method	Reason for Exclusion
1	Kantilieraki, E et al., 2019 [20]	Greek population, mandibular first and second molars	CBCT	Did not include third molars
2	Abarca J et al., 2020 [21]	Chilean population, mandibular molars	CBCT	Excluded because MTMs not included
3	D Li et al., 2025 [22]	Northern Chinese population, mixed molars	CBCT	Taurodontism in mixed molars, not MTM-specific
4	Fourneau D, Olszewski R., 2023 [23]	Review, various tooth types	CBCT	No quantitative MTM data
5	Alenezi MA et al., 2020 [24]	Kuwaiti population, first and second molars	CBCT	2D imaging only
6	Alfawaz et al., 2019 [25]	Saudi population, premolars	CBCT	Different tooth group (premolars)
7	Kim S et al., 2016 [26]	Korean population, mandibular molars	Panoramic	Lacked CBCT imaging
8	Dhillon J.K. et al., 2022 [27]	Indian population, primary molars	CBCT	Not permanent third molars
9	Ghoncheh Z et al., 2020 [28]	Iranian population, maxillary first and second molars	CBCT	Did not include mandibular third molars
10	Magalhães KM et al., 2022 [29]	Brazilian population, maxillary molars	CBCT	Non-mandibular third molars

Table 2. Summary of Selected Studies for Narrative Review.

Aberration	Author(s), Year	Population	Sample/Method	Main Findings
Root number variation	Priyank H. et al., 2023 [6]	Indian	CBCT n = 277 MTMs	Two roots ~95%; three roots ~1.5%; single root ~2.8%; four roots ~0.4%
C-shaped roots	Hiran-us et al., 2021 [7]	Thai	CBCT n = 542 MTMs	C-shaped ~16.6%; fused roots ~20%; two separate roots ~68%
Dilaceration	Miloglu et al., 2010 [8]; Malčić et al., 2006 [9]	Turkish and Croatian	Panoramic	Prevalence 10–22%; curvature mesio-distal or bucco-lingual
Taurodontism	Li et al., 2023 [10]; Kırmızı et al., 2025 [11]	Chinese and Turkish-Cypriot	CBCT	Tooth-level prevalence 7–8%; MTM-specific rare
Hypercementosis	Ohbayashi et al., 2021 [12]	Japanese	CBCT n = 1160	Prevalence rises with age; >90% ≥40 years
Radix entomolaris	Carlsen and Alexandersen, 1990 [13]; Tu et al., 2007 [14]	Morphological	Case reports; rare in MTMs	Distolingual extra root; mostly anecdotal in MTMs
Radix paramolaris	Calberson et al., 2007 [15]; Bhopatkar et al., 2023 [16]	Morphological	Case reports	Buccal accessory root; exceptionally rare in MTMs
Root fusion	Hiran-us et al., 2021 [7]; Fernandes et al., 2014 [17]	Thai and other	CBCT	Fused roots ~20%; conical morphology; surgical difficulty increased

The following table summarizes the identification, screening, eligibility, and inclusion stages of the literature selection process.

3. Results

Our search identified CBCT-based primary studies and clinically focused reviews addressing root aberrations of mandibular third molars (MTMs). High-quality data were most abundant for root number variation (including three-rooted MTMs), C-shaped root/canal morphology, root fusion, dilaceration/marked apical curvature, and hypercementosis. Evidence specific to radix entomolaris (RE) and radix paramolaris (RP) in MTMs was largely limited to case reports; most population studies on radix variants addressed first/second molars and were cited for anatomical context only (Table 2). Table 3 shows Geographic Distribution and Prevalence of Main Radicular Aberrations in MTMs.

Table 3. Geographic Distribution and Prevalence of Main Radicular Aberrations in MTMs.

Aberration	Population/Country	Region	Prevalence Range	References
Three-rooted (RE/RP)	Thai, Jordanian, Chinese	Asia	~1–10%	[6,7,14,16]
C-shaped canal	Thai, Chinese, Korean	Asia	10–17%	[7,9]
Root fusion	Thai, Brazilian	Asia/South America	~20%	[7,17]
Dilaceration	Turkish, Croatian	Europe	10–22%	[8,9]
Taurodontism	Chinese, Turkish-Cypriot	Asia/Europe	7–8% (rare in MTM)	[10,11]
Hypercementosis	Japanese	Asia	Age-dependent; >90% ≥40 y	[12]
Radix entomolaris	Chinese, Indian	Asia	<2% (rare in MTMs)	[13,14]
Radix paramolaris	Indian, Brazilian	Asia/South America	Rare; case reports	[15,16]

To provide a structured overview of the wide spectrum of root aberrations observed in mandibular third molars, we propose, for educational purposes, a didactic classification

into three principal categories: root number, root shape or morphology, and root position or orientation (Table 4). This framework is intended to simplify the complex anatomical variations and to facilitate comprehension of the different types of anomalies. Each category will be discussed in detail in the subsequent subsections, highlighting their prevalence, radiographic characteristics, and surgical implications. It is crucial to recognize that these aberrations frequently do not occur in isolation; multiple anomalies can coexist within a single tooth, further increasing extraction difficulty and potential for intraoperative complications. This structured approach allows clinicians and students alike to appreciate the interplay between anatomical complexity and surgical planning, emphasizing the need for careful preoperative assessment and imaging. Aberrations may coexist, compounding surgical difficulty.

Table 4. Didactic Classification of Radicular Aberrations.

Category	Subgroup	Definition/Description	Surgical Relevance
Number	1 root	Single-rooted MTM	Often easier extraction; may be fused or conical
	2 roots	Standard mesial and distal roots	Most common; separate roots allow predictable luxation
	3 roots	Typically includes distolingual RE	Rare; requires tri-section and careful apical leverage
	4 roots	Rare; combinations of RE/RP	Highly complex; pre-op CBCT mandatory
Shape/ Morphology	Fusion	Partial or complete coalescence of roots	Reduced interradicular septum; risk of root fracture; requires buccal troughing and crown-to-root separation
	C-shaped	Continuous or semicolon canal; lingual/buccal groove	Thin dentin; high risk of fracture; controlled sectioning advised
	Taurodontism	Elongated pulp chamber, apically displaced furcation	Short roots; limited elevator purchase; careful apical handling
	Hypercementosis	Excess cementum deposition	Enlarged root cross-section; may impede extraction; wider osteotomy may be needed
Position/ Orientation	Dilaceration	Curved or hooked apices	Impedes straight-line removal; risk of apical fracture; consider apex-first retrieval
	Divergence/ Angulation	Mesio-distal or bucco-lingual root orientation	Alters elevation path; increases risk of fracture or canal proximity injury

3.1. Root Number Variation (Single, Two, Three or More Roots)

Definition: Variation in the number of roots of the MTM, including accessory roots such as RE (distolingual) and RP (buccal) (Table 5) (Figure 2).

Table 5. Root Morphological Aberrations of Mandibular Third Molars.

Aberration	Definition	Prevalence in MTMs	Surgical Relevance	References
Single-rooted	MTM with one conical root	2–3%	Limited purchase for elevators; increased fracture risk	[6,7]
Two-rooted	MTM with mesial and distal roots	68–90%	Standard extraction technique	[6,7]
Three-rooted	MTM with accessory RE or RP	7–10%	Requires tri-section; careful apical leverage	[6,7,16]
Four-rooted	Rare; usually case reports	<1%	Complex extraction; CBCT strongly recommended	[6]
Radix Entomolaris	Distolingual accessory root	<2%	Tri-section, apical release; avoid lingual/IAC injury	[15]

Table 5. *Cont.*

Aberration	Definition	Prevalence in MTMs	Surgical Relevance	References
Radix Paramolaris	Buccal accessory root	Rare; case reports	CBCT mapping, controlled extraction	[16]
Hypo-/Meso-/Hypertaurodont	Apical displacement of pulp floor; root shortening	Tooth-level 7–8%; individual 20–29% (mostly non-MTMs)	Reduced elevator purchase; require wider coronal troughing; control sectioning	[10,11]
Root fusion	Coalescence of two or more roots	~20%	Reduced interradicular septum; increased risk of root fracture; buccal troughing and crown-to-root separation recommended	[6,7,17]
C-shaped canal	Fused root forming crescent or semicolon canal	10–17%	Thin dentin walls; controlled sectioning; avoid excessive force; apex release	[7]
Dilaceration	Curved or hooked root apex (>20–40°)	10–22%	Impedes straight-line removal; risk of apical fracture; may require coronectomy or apex-first approach	[8,9]
Hypercementosis	Cemental thickening along root	Age-dependent: 0% ≤19 y, ~14% (20–24 y), ~58% (25–29 y), >90% ≥40 y	Enlarged root cross-section; requires wider apical osteotomy and careful apical release; CBCT recommended	[12]

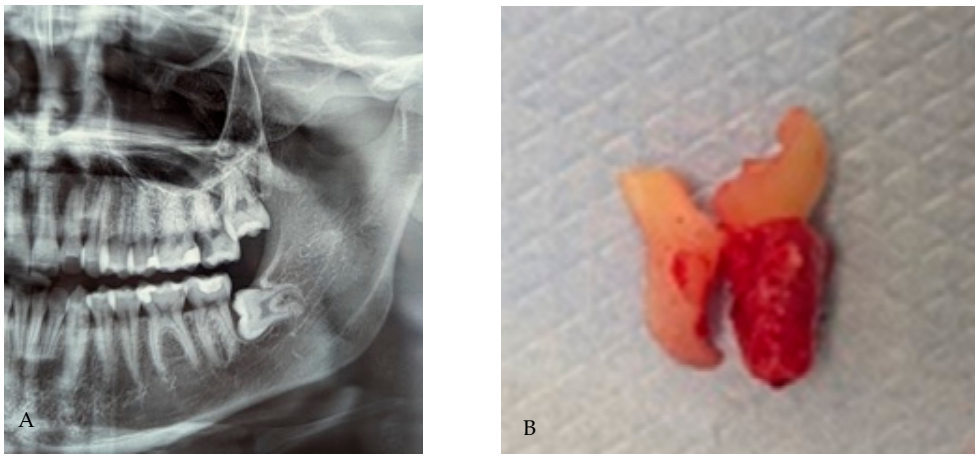

Figure 2. Tooth 3.8 with two roots. (**A**): Panoramic radiograph. (**B**): Frontal view of corono-radicular odontotomy showing mesial and distal roots.

3.2. Radix Entomolaris

Definition: The radix entomolaris (RE) is defined as a supernumerary root located distolingually in mandibular molars [15] (Table 5) (Figures 3 and 4).

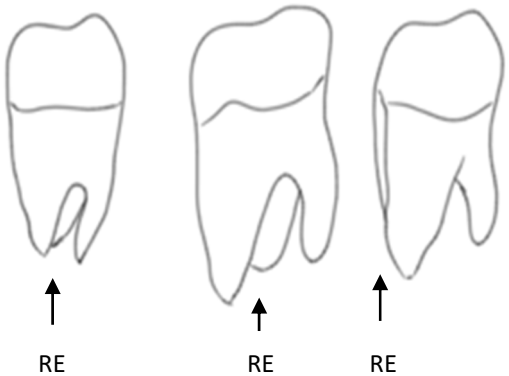

Figure 3. Schematic representation of radix entomolaris (RE).

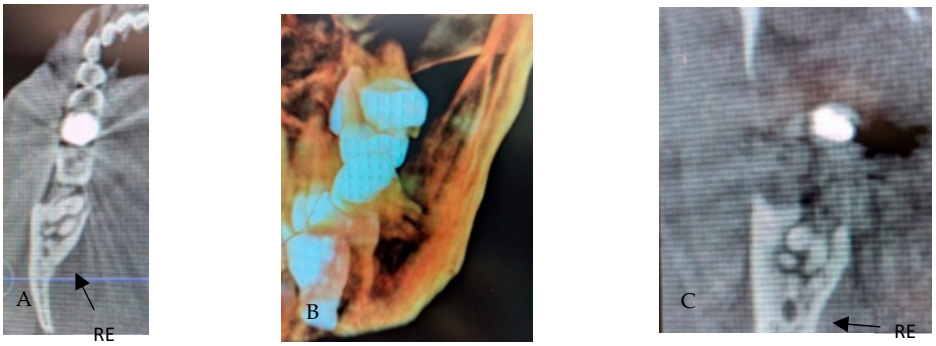

Figure 4. Tooth 3.8 with RE. (**A**): CBCT axial view; (**B**): CBCT 3D reconstruction (**C**): cbct paraxial view showing mesial and distal roots, and the supernumerary entomolaris root situated distolingually (RE).

From an oral surgery perspective, the most clinically relevant aspect is the root curvature, since it directly influences the risk of root fracture and the difficulty of tooth sectioning during third molar extraction [30]. proposed a widely adopted classification of RE according to its curvature:

- Type I: straight root/canal;
- Type II: curvature in the coronal third, followed by a straight continuation;
- Type III: curvature in the coronal third with an additional buccal curvature in the apical third.

Type III, in particular, represents the greatest surgical challenge, as the double curvature complicates the luxation path and increases the risk of accidental root breakage during extraction maneuvers [15,30].

For this reason, careful radiographic evaluation (using angulated periapical radiographs or CBCT in complex cases) is essential to identify the presence and curvature type of RE before planning mandibular third molar surgery [31,32]. A proper understanding of this anatomical variant allows the surgeon to adapt the osteotomy and sectioning technique, minimizing intraoperative complications.

3.3. Radix Paramolaris

Definition: The radix paramolaris (RP) is a supernumerary root located mesiobuccally in mandibular molars, most frequently associated with the first molar, though less common than the distolingual radix entomolaris [15] (Table 5) (Figures 5 and 6).

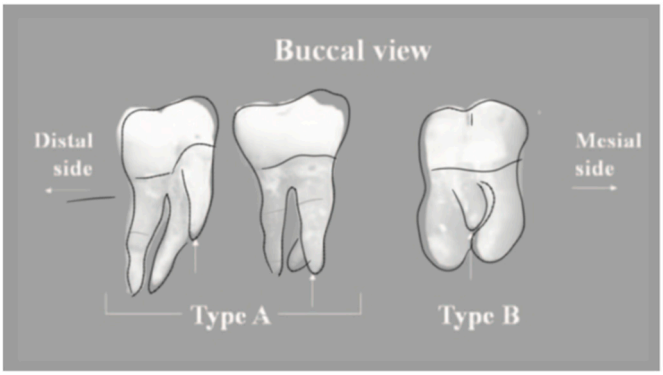

Figure 5. Carlsen and Alexandersen (1991) [13] proposed a classification of RP into two distinct types. In Type A, the cervical part is associated with the mesial root complex, whereas in Type B it is located centrally between the mesial and distal root complexes.

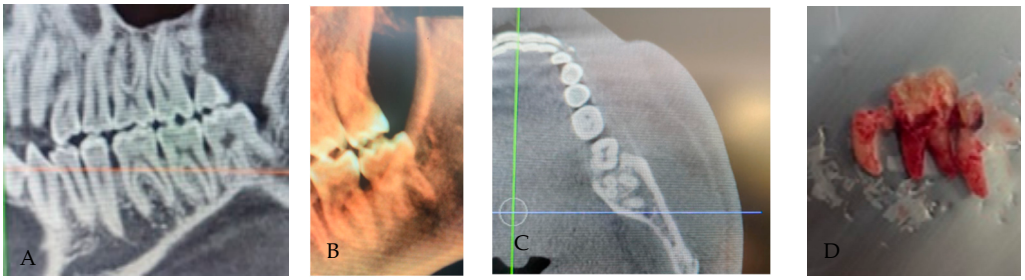

Figure 6. Tooth 3.8 with RP. (**A**,**B**): CBCT frontal view; (**C**): cbct assial view; (**D**): frontal view of corono-radicular odontototomy showing mesial and distal roots, and the supernumerary paramolaris root situated buccally, partially mesial to the mesial root complex.

From a surgical standpoint, the key element is the location of the additional root, which influences flap design, sectioning strategy, and luxation mechanics during extraction of mandibular third molars. Carlsen and Alexandersen (1991) [13] (Figure 4) proposed a classification based on the topographic relationship of the RP: Type A: the supernumerary root is situated buccally, partially mesial to the mesial root complex; Type B: the supernumerary root is located buccally, centrally between the mesial and distal root complexes.

In both cases, the presence of RP may complicate surgical extraction due to its buccal position. Type A is particularly challenging, as the RP tends to be shorter, conical, and may interfere with mesial root sectioning or elevate the risk of root fracture during buccal luxation [13,15]. Radiographic identification is often difficult, as the RP may overlap with mesial root structures on standard periapical views. Therefore, angled radiographs or CBCT imaging are recommended in cases of surgical suspicion [30,32]. Recognition of this variant prior to extraction allows the surgeon to adjust the osteotomy, anticipate altered points of resistance, and avoid leaving root fragments in situ.

3.4. Taurodontism

Definition: Taurodontism is a developmental dental anomaly characterized by an enlarged pulp chamber with an apically displaced pulpal floor and furcation, resulting in shortened roots and elongated body of the tooth [33]. The anomaly most frequently affects permanent molars and can present unilaterally or bilaterally (Table 5), (Figures 7 and 8).

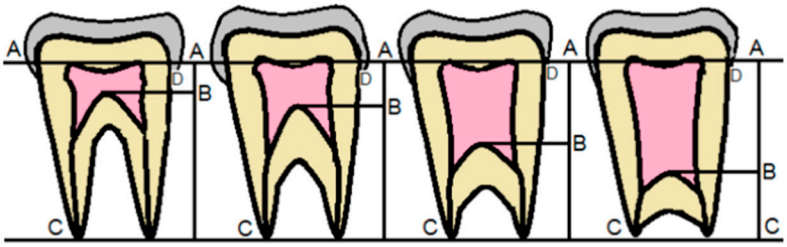

Figure 7. Shifman and Chanannel [33] Schematic representation of molar morphological variations associated with taurodontism. From left to right: normal tooth, hypotaurodont, mesotaurodont, and hypertaurodont. Reference lines indicate: A = lowest point of the pulp chamber roof; B = highest point of the pulp chamber floor; C = root apex; D = cementoenamel junction (CEJ).

From an oral surgical perspective, taurodontism is clinically significant because of: altered furcation position, which complicates surgical sectioning and root separation during extraction, shortened roots, reducing the amount of periodontal ligament attachment, sometimes facilitating luxation but also increasing the risk of tooth mobility and periapical complications, enlarged pulp chamber, which may increase intraoperative bleeding and risk of pulp exposure in endodontic-surgical procedures.

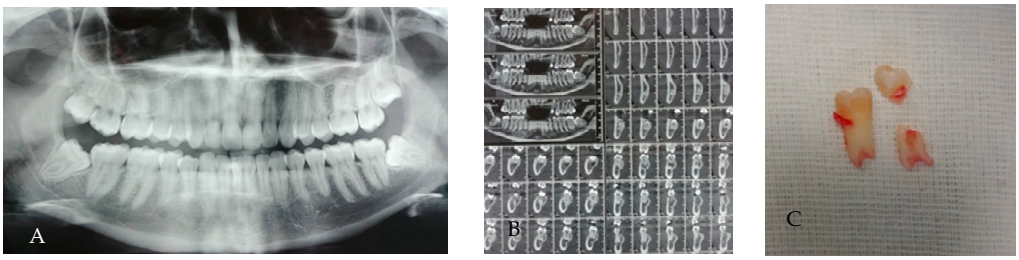

Figure 8. Tooth 4.8 with hypertaurodontism. (**A**): Panoramic radiograph. (**B**): CBCT frontal and paraxial view. (**C**): Frontal view of corono-radicular odontotomy illustrating the peculiar root anatomy.

The classification system most useful to the oral surgeon is that of Shifman and Chanannel [33] (Figure 7), which is based on the degree of apical displacement of the pulpal floor and furcation:

- Hypotaurodont: mild displacement; furcation slightly apical, root length relatively preserved.
- Mesotaurodont: moderate displacement; larger pulp chamber, shorter roots.
- Hypertaurodont: severe displacement; very elongated pulp chamber, minimal root length, furcation close to the apex.

Hypertaurodont molars are the most surgically challenging, as the minimal divergence and shortened length of roots limit sectioning and controlled extraction [33]. Preoperative radiographic evaluation—especially panoramic radiography and CBCT—remains essential to identify taurodontism and adjust surgical planning [34].

3.5. Root Fusion

Definition: Root fusion is defined as the developmental union of two or more roots, resulting in a reduction in the normal number of independent roots [34,35]. It most commonly affects mandibular molars and second premolars. For the oral surgeon, fused roots are relevant because they alter extraction mechanics: the fused mass may require different luxation forces, and the absence of a clear root bifurcation reduces the effectiveness of surgical sectioning (Table 5). According to its extent, clinically we can observe the following types of root fusion: complete fusion: roots united along their entire length, producing a single conical root; partial fusion: roots united only in the coronal, middle third or apical third (Figures 9–11). Partial Fusion of the apical third is surgically more challenging making rotation or luxation more difficult, requiring wider osteotomy or tooth sectioning [36].

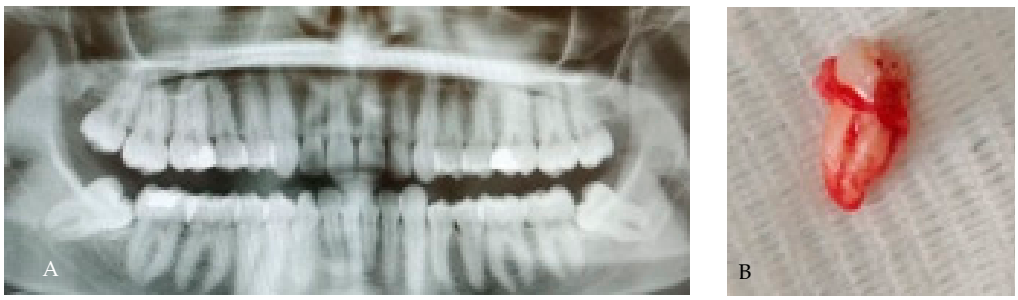

Figure 9. Tooth 4.8 with complete roots fusion. (**A**): panoramic radiograph. (**B**): Frontal view of tooth 4.8 showing complete fusion of the mesial and distal roots along their entire length, resulting in a single root structure.

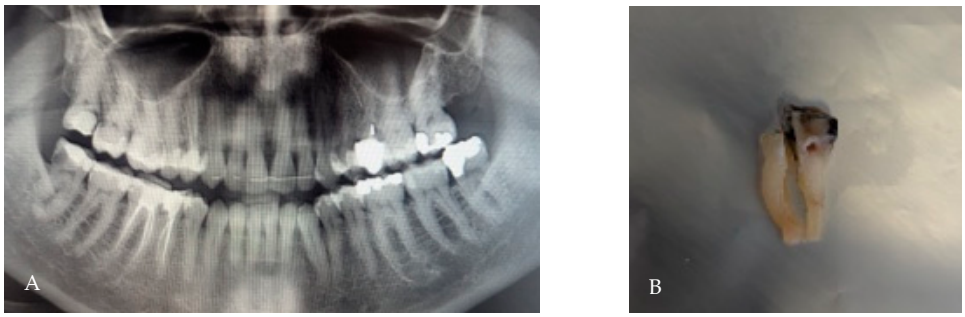

Figure 10. Tooth 4.8 with partial roots fusion. (**A**): panoramic radiograph. (**B**): Frontal view of tooth 4.8 following corono-radicular odontotomy, highlighting the peculiar anatomy of the tooth with fusion of the mesial and distal roots limited to the apical third.

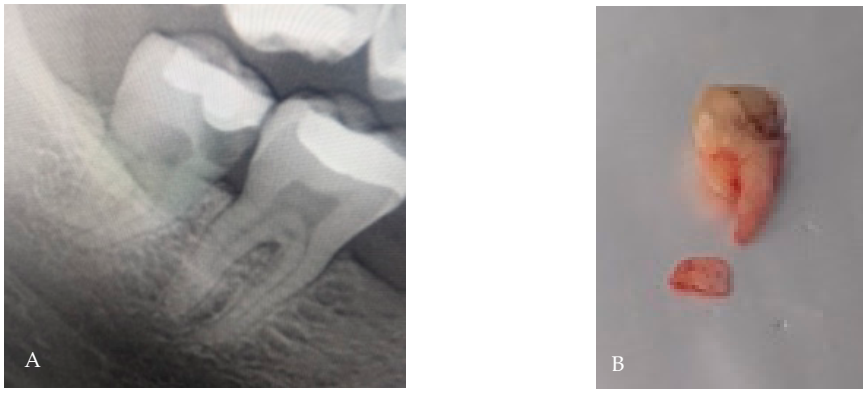

Figure 11. Tooth 4.8 with partial roots fusion. (**A**): panoramic radiograph. (**B**): Frontal view of tooth 4.8 showing its unique anatomy, with the mesial and distal roots fused only in the coronal third.

3.6. C-Shaped Morphology

Definition: A C-shaped canal is a root canal configuration characterized by a fin or web connecting individual canals, producing a continuous C-shaped outline in cross-section [37]. For the oral surgeon, the C-shaped canal is important not only for endodontics but also for surgery, as it reflects anatomic variation in the root morphology: the roots are typically fused into a single, broad, lingually curved structure, which influences extraction strategy (Table 5) (Figure 12).

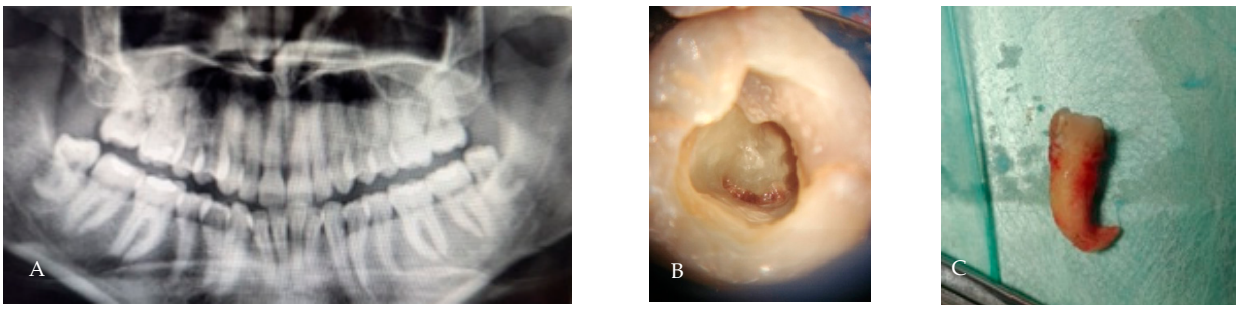

Figure 12. Tooth 3.8 with C-Shaped canal. (**A**): panoramic radiograph. (**B**): coronal view obtained with the operating microscope shows a continuous C-shaped canal (**C**): frontal view of tooth shows a single root with apical curvature (severe dilaceration).

The most widely used classification is that of Fan et al. [38], based on cross-sectional morphology:

- C1: continuous C-shaped canal.
- C2: semicolon-shaped (due to discontinuation of the "C").

- C3: two or more discrete canals without a clear C-shape.
- C4: single round or oval canal.

From a surgical standpoint, C1 and C2 types are most relevant, as they indicate broad root fusion with irregular apical anatomy. This morphology complicates tooth sectioning, increases resistance during luxation, and may predispose to root fracture if not identified preoperatively [37,38].

Preoperative CBCT imaging is recommended to differentiate fused roots and C-shaped configurations, guiding flap design, osteotomy, and sectioning to minimize complications [36].

3.7. Dilaceration/Apical Curvature

Definition: Dilaceration is defined as an abrupt deviation or sharp bend in the linear relationship of the crown and root of a tooth, usually resulting from trauma to the primary dentition or developmental disturbances [34]. It can occur in the crown, root, or both, and is of major clinical significance in oral surgery because it complicates extraction, endodontic access, and orthodontic movement (Table 5).

From an oral surgical perspective, dilaceration is relevant due to: unpredictable root path, which increases the risk of root fracture during extraction, close relationship to anatomical structures (e.g., mandibular canal, maxillary sinus) when roots deviate significantly. Challenges in surgical access, especially for impacted teeth or third molars with dilacerated roots. A practical classification is that of Chohayeb [39], which categorizes dilaceration by the degree and direction of the root curvature: Mild: <20° deviation, Moderate: 20–40° deviation, Severe: >40° deviation. Additionally, Ellis et al. [40] suggested describing the direction of curvature relative to the tooth's long axis: Mesial dilaceration, Distal dilaceration, Labial/buccal dilaceration, Lingual/palatal dilaceration (Figure 13).

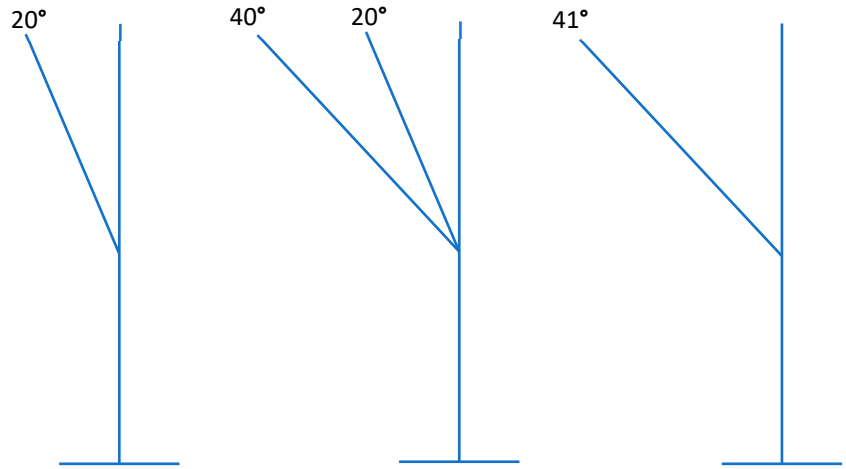

Figure 13. Schematic representation of root dilaceration, classified according to severity into mild, moderate, and severe forms.

For the oral surgeon, severe dilacerations (Figure 14)—especially in the apical third and directed buccally/lingually—are the most challenging, as they often remain hidden in two-dimensional radiographs and can only be fully appreciated with angled periapical films or CBCT [34]. Recognition of dilaceration preoperatively allows the surgeon to plan controlled sectioning, modified luxation paths, and careful osteotomy to minimize complications.

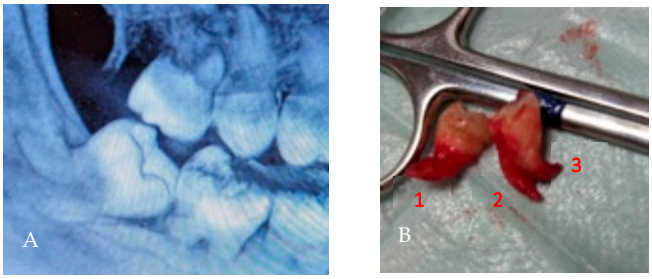

Figure 14. Tooth 4.8 with dilaceration. (**A**): Cbct radiograph. (**B**): Frontal view of tooth 4.8 following corono-radicular odontotomy, highlighting the complex root morphology with three roots showing marked distal curvature of the distal (1), mesiobuccal (2), and mesiolingual (3) roots, classified as severe distal-type dilaceration.

3.8. Hypercementosis

Definition: Hypercementosis is defined as a non-neoplastic, excessive deposition of cementum on the root surface, beyond the physiological contour of the tooth root [12] (Figures 15 and 16). It is usually asymptomatic and discovered radiographically, but it has direct surgical implications, particularly in tooth extraction, due to bulbous root morphology and potential fusion with alveolar bone (Table 5).

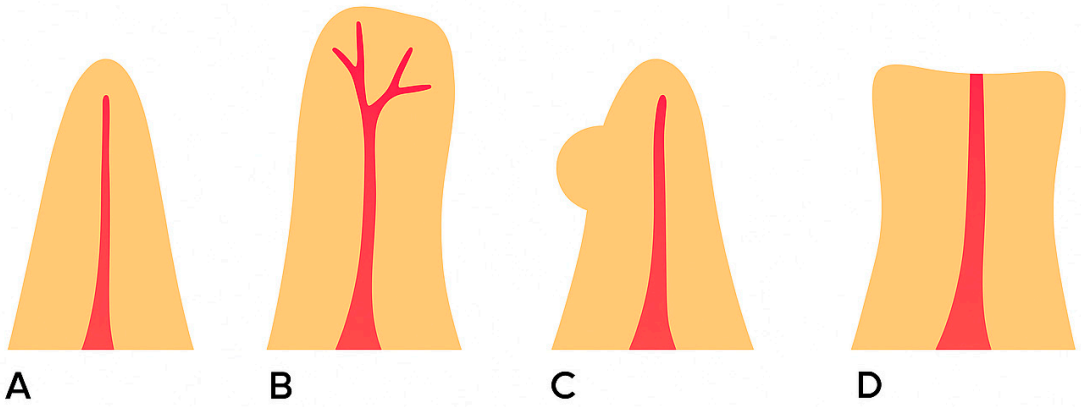

Figure 15. Types of hypercementosis morphology: (**A**) normal root contour; (**B**) diffuse form, showing a generalized, club-like thickening of the root; (**C**) focal form, limited to a localized area on one root surface; and (**D**) circumferential or 'cuff-like' form, affecting the lateral root surface but sparing the apex, typically associated with chronic periapical inflammation.

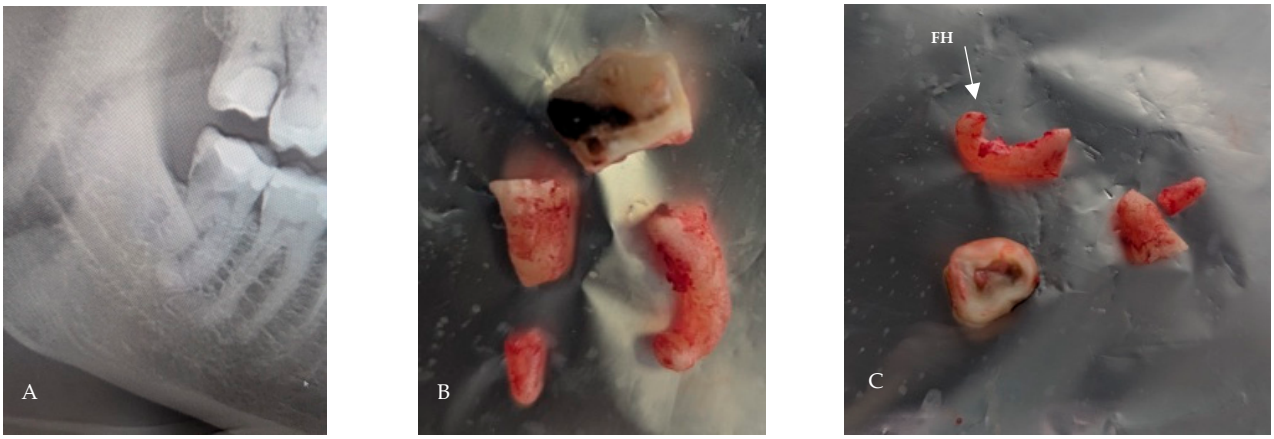

Figure 16. Tooth 4.8 with hypercementosis and root dilaceration. (**A**) Panoramic radiograph; (**B**,**C**) frontal view after corono-radicular odontotomy. Note the severe distolingual dilaceration of the distal root, and the severe dilaceration of the mesial root, which also presents focal hypercementosis (FH).

From an oral surgery perspective, the classification proposed by Thoma and Goldman [41], later modified by Consolaro [42], is most useful, as it is based on morphology and surgical implications:

- Club-shaped hypercementosis: root exhibits a generalized, smooth, thickened contour; extraction may be more difficult due to increased root diameter.
- Focal hypercementosis: localized nodular deposits on one or more aspects of the root; may create mechanical undercuts, increasing the risk of root fracture during luxation.
- Circular (or circumferential) hypercementosis: uniform thickening encircling the root, often leading to ankylosis-like resistance during extraction.

These morphological variants affect the surgeon's ability to mobilize the tooth. Nodular and circumferential forms pose the greatest surgical challenges, since they create irregularities or broadening of the apical root third, increasing the likelihood of complications such as fractured roots or retention of cemental fragments [24,42].

Careful radiographic assessment is essential: periapical radiographs often reveal bulbous or irregular root outlines, while CBCT may help define the extent and location of cementum overgrowth [42]. When hypercementosis is present, extraction should be approached with modified surgical techniques, including controlled sectioning, wider osteotomy, and gentle luxation to reduce fracture risk.

4. Discussion

The extraction of mandibular third molars (MTMs) remains one of the most frequent and challenging procedures in oral surgery, largely due to the high variability in root morphology and its direct implications for surgical planning and outcomes. Anatomical aberrations such as radix entomolaris, radix paramolaris, taurodontism, root fusion, dilaceration, C-shaped canals, and hypercementosis substantially influence both the difficulty of tooth removal and the likelihood of postoperative complications [1–5,43–45]. A precise understanding of these morphological variations is therefore essential to anticipate potential intraoperative challenges, reduce iatrogenic risks, and optimize surgical strategies.

Root number variation—notably the presence of supernumerary roots such as radix entomolaris and radix paramolaris—has been documented across populations, with prevalence ranging from 0.5% to 5% for radix entomolaris and even lower for paramolaris in MTMs [3,4]. These variations, though uncommon, present significant surgical challenges, particularly when associated with complex curvatures or fusion. Similarly, dilaceration, often attributed to restricted eruption space, represents another frequent aberration in MTMs, with studies reporting prevalence between 10% and 25% depending on population and imaging modality [6,7]. Severe curvature of root apices may complicate luxation and increase the risk of root fracture or displacement into anatomical spaces.

Equally important are C-shaped root canal configurations, although less frequent in MTMs compared to mandibular second molars, with reported prevalence ranging between 2% and 8% [8,9]. Their presence complicates not only endodontic treatments but also surgical extractions, since fused or ribbon-like roots reduce the possibility of predictable sectioning and elevate the risk of incomplete removal. Taurodontism, characterized by an elongated pulp chamber and apical displacement of the furcation, has also been observed in MTMs, albeit at lower frequencies (1–5%) [10,11]. Such aberrations are particularly relevant when planning potential autotransplantation of MTMs, as they may compromise stability and integration of the donor tooth. Hypercementosis, while rare, should not be underestimated as it can impede extraction and lead to excessive bone loss or iatrogenic fractures [12]. Table 6 summarizes the main root anomalies of mandibular third molars (MTMs), their prevalence, and the associated surgical implications. This overview is crucial for planning safe and predictable extractions, as understanding both the likelihood and the

specific challenges of each anatomical variation allows the surgeon to tailor the operative approach, anticipate potential complications, and select appropriate imaging or sectioning strategies when necessary. In this context, radiological imaging plays a pivotal role in preoperative diagnosis and treatment planning. Panoramic radiographs, despite their wide accessibility and low radiation dose, provide only a two-dimensional view of the MTM and are often inadequate in detecting root aberrations such as additional roots, dilacerations, or precise root–canal configurations [12,46,47]. Structural superimposition and distortion may obscure critical details, thereby underestimating surgical difficulty.

Table 6. Prevalence and Key Surgical Implications.

Aberration	Prevalence (MTMs)	Key Surgical Implications	References
Two roots	68–90%	Standard extraction; predictable luxation	[6]
Three roots (RE/RP)	7–10%	Tri-section; careful apical release	[6,14,16]
Single root	2–3%	May be conical; requires careful luxation	[6,7]
Fused roots	~20%	Buccal troughing; risk of fracture	[7,17]
C-shaped	10–17%	Controlled sectioning; thin dentin risk	[7,17]
Dilaceration	10–22%	Apex-first retrieval; coronectomy if near IAN	[8,9]
Taurodontism	1–5% (MTM-specific)	Wider coronal troughing; careful elevators	[10,11]
Hypercementosis	Age-dependent; up to 90% ≥40 y	Wider osteotomy; apical release	[12]

Despite this, panoramic radiographs can provide initial clues about potential root anomalies. Signs such as root discontinuities, abrupt changes in curvature, unexpected radiopacities, or unusual canal outlines may suggest underlying variations, including accessory roots, dilacerations, taurodontism, or hypercementosis [6,9,10,12]. For instance, anomalous radiopacities in the apical region may indicate hypercementosis, whereas irregular root outlines or sudden curvature shifts may be suggestive of dilacerations [8,12]. Additionally, subtle indications of extra roots, such as radix entomolaris or radix paramolaris, may be observed but can be masked by superimposition of adjacent anatomical structures [15]. Awareness of these signs enables clinicians to select cases for further three-dimensional imaging, optimizing preoperative planning and risk assessment [18].

By contrast, cone-beam computed tomography (CBCT) offers multiplanar reconstructions and volumetric assessments with high spatial resolution, enabling accurate evaluation of root morphology, apical curvature, and the relationship with critical structures such as the inferior alveolar nerve [18]. CBCT has been shown to improve surgical planning by informing flap design, osteotomy extension, and the decision to perform root sectioning, which in turn reduces the risk of nerve injury and root fragment displacement [18]. For example, in cases of dilaceration or fused roots, CBCT allows the surgeon to anticipate modifications in extraction technique, thereby reducing intraoperative surprises. Moreover, the ability to present 3D images to patients enhances preoperative counseling and supports more comprehensive informed consent.

Nevertheless, it is important to highlight that CBCT should not be employed indiscriminately. Its indication should be reserved for cases in which conventional radiography fails to provide sufficient diagnostic information or when complex root morphology significantly increases surgical difficulty [18,48,49]. In line with the ALARA principle (“As Low As Reasonably Achievable”), the use of ionizing radiation must always be justified by a clear

clinical benefit that outweighs potential risks. Selective and evidence-based application of CBCT therefore ensures optimal diagnostic yield while minimizing unnecessary exposure. Within this framework, the integration of detailed anatomical knowledge and advanced three-dimensional imaging enhances surgical planning, improves procedural safety, and contributes to more predictable clinical outcomes.

The methodological quality of the reviewed studies varied considerably. While all included investigations employed CBCT imaging, significant heterogeneity existed in acquisition parameters, voxel size, and analysis criteria. Many studies used retrospective designs with convenience sampling, which may introduce selection bias and limit generalizability. Moreover, several studies lacked standardized diagnostic thresholds for identifying root anomalies such as dilaceration or C-shaped canals, leading to discrepancies in prevalence reporting. Differences in population size and geographic distribution further influenced the comparability of findings, and only a minority of studies performed inter-examiner reliability assessments or statistical validation of morphological classifications.

From a broader perspective, this narrative review is limited by the inherent heterogeneity of the available literature. The inclusion of studies that occasionally reference other mandibular molars was necessary to provide context for rare anomalies but may have introduced indirect evidence. Furthermore, variations in CBCT protocols and limited sample sizes prevent reliable meta-analytic synthesis. The lack of longitudinal data also restricts understanding of how root morphology evolves with age or function. Future research should focus on large-scale, standardized CBCT-based studies with robust methodological design to strengthen the evidence base and enable clinically meaningful comparisons across populations.

5. Conclusions

The extraction of mandibular third molars remains a complex surgical procedure due to the wide range of root morphological variations. Aberrations such as radix entomolaris, radix paramolaris, taurodontism, root dilaceration, fusion, C-shaped roots, and hypercementosis significantly impact the degree of surgical difficulty, as well as the risk of intra- and postoperative complications. Accurate recognition and classification of these variations are therefore essential for oral surgeons to anticipate potential challenges during treatment.

Radiological imaging remains fundamental in the preoperative assessment of mandibular third molars. While panoramic radiographs provide a useful initial overview, cone-beam computed tomography (CBCT) offers superior diagnostic precision by enabling three-dimensional evaluation of root morphology and its relationship with adjacent anatomical structures. However, its use should adhere to the ALARA principle ("As Low As Reasonably Achievable"), ensuring that radiation exposure is justified only when conventional imaging proves insufficient for accurate diagnosis and safe surgical planning. A selective, evidence-based approach to CBCT—guided by anatomical complexity and clinical risk—optimizes surgical outcomes while maintaining patient safety. Ultimately, the integration of detailed anatomical understanding, advanced imaging, and careful preoperative strategy represents the cornerstone of predictable and complication-free third molar surgery.

Future research should focus on large-scale, population-based studies that systematically evaluate radicular aberrations of mandibular third molars using standardized CBCT protocols. Such efforts would provide more granular epidemiological data, refine surgical risk assessment models, and contribute to the development of evidence-based clinical guidelines. Ultimately, a comprehensive approach that integrates anatomical knowledge, advanced imaging, and meticulous surgical planning will lead to safer and more predictable outcomes in third molar surgery.

Author Contributions: Conceptualization, F.Z. and A.C.; methodology, F.Z.; software, G.P.; validation, A.C.; formal analysis, F.Z.; investigation, A.C.; resources, A.C.; data curation, G.P.; writing—original draft preparation, F.Z.; writing—review and editing, G.P.; visualization, F.Z.; supervision, A.C.; project administration, A.C. All authors have read and agreed to the published version of the manuscript.

Funding: This research received no external funding.

Institutional Review Board Statement: The study was conducted in accordance with the Declaration of Helsinki, and approved by the Review Board of the Department of Oral and Maxillofacial Sciences, Sapienza University of Rome, Italy (protocol code: 0001115; date of approval: 25 May 2025).

Informed Consent Statement: Informed consent was obtained from all subjects involved in the study.

Data Availability Statement: No new data were created or analyzed in this study. Data sharing is not applicable to this article.

Acknowledgments: The authors would like to acknowledge the administrative and technical support provided by the Department of Oral and Maxillofacial Sciences, Sapienza University of Rome.

Conflicts of Interest: The authors declare no conflicts of interest.

References

1. Santosh, P. Impacted mandibular third molars: Review of literature and a proposal of a combined clinical and radiological classification. *Ann. Med. Health Sci. Res.* **2015**, *5*, 229–234. [CrossRef] [PubMed]
2. Blondeau, F.; Daniel, N.G. Extraction of impacted mandibular third molars: Postoperative complications and their risk factors. *J. Can. Dent. Assoc.* **2007**, *73*, 325. [PubMed]
3. Jing, Q.; Song, H.; Huang, H.; Shi, Y.; Cheng, J.; Wang, D. Characterizations of three-dimensional root morphology and topological location of mandibular third molars by cone-beam computed tomography. *Surg. Radiol. Anat.* **2023**, *45*, 527–536. [CrossRef] [PubMed]
4. Hupp, J.R.; Ellis, E.; Tucker, M.R. *Contemporary Oral and Maxillofacial Surgery*, 7th ed.; Elsevier: St. Louis, MO, USA, 2018.
5. Ghaeminia, H.; Meijer, G.J.; Soehardi, A.; Borstlap, W.A.; Mulder, J.; Vlijmen, O.J.C.; Bergè, S.J.; Maal, T.J.J. The use of cone beam CT for the removal of wisdom teeth changes the surgical approach compared with panoramic radiography: A pilot study. *Int. J. Oral Maxillofac. Surg.* **2011**, *40*, 834–839. [CrossRef]
6. Priyank, H.; Viswanath, B.; Sriwastwa, A.; Hegde, P.; Abdul, N.S.; Golgeri, M.S.; Mathur, H. Radiographical evaluation of morphological alterations of mandibular third molars: A cone beam computed tomography (CBCT) Study. *Cureus* **2023**, *15*, e34114. [CrossRef]
7. Hiran-Us, S.; Benjavongkulchai, S.; Antanit, C.; Thanadrob, P.; Thongpet, P.; Onrawijit, A. Prevalence of C-shaped canals and three-rooted mandibular molars using CBCT in a selected Thai population. *Iran. Endod. J.* **2021**, *16*, 97.
8. Miloglu, O.; Cakici, F.; Çağlayan, F.; Yilmaz, A.B.; Demirkaya, F. The prevalence of root dilacerations in a Turkish population. *Oral Radiol.* **2010**, *26*, 3–10. [CrossRef]
9. Malcić, A.; Jukić, S.; Brzović, V.; Miletić, I.; Pelivan, I.; Anić, I. Prevalence of root dilaceration in adult dental patients in Croatia. *Oral Surg. Oral Med. Oral Pathol. Oral Radiol. Endod.* **2006**, *102*, 104–108. [CrossRef]
10. Li, Y.; Qian, F.; Wang, D.; Wang, Y.; Wang, W.; Tian, Y. Prevalence of taurodontism in individuals in Northwest China determined by cone-beam computed tomography images. *Heliyon* **2023**, *9*, e15531. [CrossRef]
11. Kırmızı, D.; Aksoy, U.; Aksoy, S.; İnönü, N.; Orhan, K. Evaluation of taurodont and pyramidal mandibular molars prevalence in a group of Turkish Cypriot population by cone beam computed tomography. *Cyprus J. Med. Sci.* **2025**, *10*, 8–11. [CrossRef]
12. Ohbayashi, N.; Wamasing, P.; Tonami, K.; Kurabayashi, T. Incidence of hypercementosis in mandibular third molars determined using cone beam computed tomography. *J. Oral Sci.* **2021**, *63*, 179–183. [CrossRef]
13. Carlsen, O.; Alexandersen, V. Radix entomolaris: Identification and clinical considerations. *Int. Endod. J.* **1990**, *23*, 40–46.
14. Tu, M.G.; Tsai, C.C.; Jou, M.J.; Chen, W.L.; Chang, Y.F.; Chen, S.Y.; Cheng, H.W. Prevalence of three-rooted mandibular first molars among Taiwanese individuals. *J. Endod.* **2007**, *33*, 1163–1166. [CrossRef] [PubMed]
15. Calberson, F.L.; De Moor, R.J.; Deroose, C.A. The radix entomolaris and paramolaris: Clinical approach in endodontics. *J. Endod.* **2007**, *33*, 58–63. [CrossRef]
16. Bhopatkar, J.; Ikhar, A.; Nikhade, P.; Chandak, M.; Agrawal, P.; Nikhade, P.P. Navigating challenges in the management of mandibular third molars with Radix paramolaris: A case report. *Cureus* **2023**, *15*, e45744. [CrossRef]
17. Fernandes, M.; de Ataide, I.; Wagle, R. C-shaped root canal configuration: A review of literature. *J. Conserv. Dent.* **2014**, *17*, 312–319. [CrossRef] [PubMed]

18. Araujo, G.D.T.T.; Peralta-Mamani, M.; da Silva, A.D.F.M.; Rubira, C.F.; Honório, H.M.; Rubira-Bullen, I.F. Influence of cone beam computed tomography versus panoramic radiography on the surgical technique of third molar removal: A systematic review. *Int. J. Oral Maxillofac. Surg.* **2019**, *48*, 1340–1347. [CrossRef]
19. Trachoo, V.; Taetragool, U.; Pianchoopat, P.; Sukitporn-Udom, C.; Morakrant, N.; Warin, K. Deep learning for predicting the difficulty level of removing the impacted mandibular third molar. *Int. Dent. J.* **2025**, *75*, 144–150. [CrossRef]
20. Kantilieraki, E.; Delantoni, A.; Angelopoulos, C.; Beltes, P. Evaluation of root and root canal morphology of mandibular first and second molars in a Greek population: A CBCT study. *Eur. Endod. J.* **2019**, *4*, 62–68. [CrossRef]
21. Abarca, J.; Duran, M.; Parra, D.; Steinfort, K.; Zaror, C.; Monardes, H. Root morphology of mandibular molars: A CBCT study. *Folia Morphol.* **2020**, *79*, 327–332. [CrossRef] [PubMed]
22. DLi, S.; Min, Z.; Wang, T.; Hou, B.; Su, Z.; Zhang, C. Prevalence and root canal morphology of taurodontism analyzed by cone-beam computed tomography in Northern China. *BMC Oral Health* **2025**, *25*, 5. [CrossRef] [PubMed]
23. Fourneau, E.; Olszewski, R. Taurodontic teeth in cone beam computed tomography: Pictorial review. *Nemesis. Negat. Eff. Med. Sci. Oral Maxillofac. Surg.* **2023**, *33*, 1–44. [CrossRef]
24. Alenezi, D.J.; Al-Nazhan, S.A.; Al-Maflehi, N.; Soman, C. Root and canal morphology of mandibular premolar teeth in a Kuwaiti subpopulation: A CBCT clinical study. *Eur. Endod. J.* **2020**, *5*, 248. [CrossRef] [PubMed]
25. Alfawaz, H.; Alqedairi, A.; Al-Dahman, Y.H.; Al-Jebaly, A.S.; Alnassar, F.A.; Alsubait, S.; Allahem, Z. Evaluation of root canal morphology of mandibular premolars in a Saudi population using cone beam computed tomography: A retrospective study. *Saudi Dent. J.* **2019**, *31*, 137–142. [CrossRef]
26. Kim, S.Y.; Kim, B.S.; Kim, Y. Mandibular second molar root canal morphology and variants in a Korean subpopulation. *Int. Endod. J.* **2016**, *49*, 136–144. [CrossRef]
27. Dhillon, J.K.; Ghosh, S.; Mathur, V.P. Root canal morphology of primary molars–A cone beam computed tomography (CBCT) study. *Indian J. Dent. Res.* **2022**, *33*, 14–17. [CrossRef]
28. Ghoncheh, Z.; Moghaddam-Zadeh, B.; Kharazi Fard, M.J. Root morphology of maxillary first and second molars in an Iranian population using cone-beam computed tomography. *Front. Dent.* **2020**, *17*, 128–136.
29. Magalhães, J.; Velozo, C.; Albuquerque, D.; Soares, C.; Oliveira, H.; Pontual, M.L.; Pontual, A. Morphological Study of Root Canals of Maxillary Molars by Cone-Beam Computed Tomography. *Sci. World J.* **2022**, *1*, 4766305. [CrossRef]
30. De Moor, R.J.; Deroose, C.A.; Calberson, F.L. The radix entomolaris in mandibular first molars: An endodontic challenge. *Int. Endod. J.* **2004**, *37*, 789–799. [CrossRef]
31. Ramugade, M.M.; Kuanr, S.; Pawar, S. Comprehensive management of endodontic variants Radix Entomolaris and Radix Paramolaris—A case series. *Acta Sci. Dent. Sci.* **2017**, *1*, 28–38.
32. Song, J.S.; Kim, S.O.; Choi, B.J.; Son, H.K.; Lee, J.H. Clinical management of radix entomolaris in a mandibular first molar: A case report. *J. Endod.* **2010**, *36*, 653–657. [CrossRef]
33. Shifman, A.; Chanannel, I. Prevalence of taurodontism found in radiographic dental examination of 1,200 young adult Israeli patients. *Community Dent. Oral Epidemiol.* **1978**, *6*, 200–203. [CrossRef] [PubMed]
34. Neville, B.W.; Damm, D.D.; Allen, C.M.; Chi, A.C. *Oral and Maxillofacial Pathology*, 4th ed.; Elsevier: Amsterdam, The Netherlands, 2016.
35. Zhang, Q.; Chen, H.; Fan, B.; Fan, W.; Gutmann, J.L. Root and root canal morphology in maxillary second molar with fused root from a native Chinese population. *J. Endod.* **2014**, *40*, 871–875. [CrossRef]
36. Ahmed, H.M.A.; Versiani, M.A.; De-Deus, G.; Dummer, P.M.H. A new system for classifying root and root canal morphology. *Int. Endod. J.* **2017**, *50*, 761–770. [CrossRef] [PubMed]
37. Cooke, H.G.; Cox, F.L. C-shaped canal configurations in mandibular molars. *J. Am. Dent. Assoc.* **1979**, *99*, 836–839. [CrossRef]
38. Fan, W.; Fan, B.; Gutmann, J.L.; Fan, M. Identification of C-shaped canal in mandibular second molars. Part I: Radiographic and clinical analysis. *Int. Endod. J.* **2004**, *37*, 805–810.
39. Chohayeb, A.A. Dilaceration of permanent teeth: Report of a case. *Oral Surg. Oral Med. Oral Pathol.* **1983**, *55*, 519–520. [CrossRef] [PubMed]
40. Ellis, R.G.; McNamara, J.A.; McNamara, C.M. Dental dilacerations: Etiology, clinical features, and management. *Dent. Update* **1989**, *16*, 153–156.
41. Thoma, K.H.; Goldman, H.M. The pathology of dental cementum: A critical review. *J. Am. Dent. Assoc.* **1941**, *28*, 1989–2003.
42. Consolaro, A. Hypercementosis: Concepts, clinical implications, and its possible role in dental practice. *Dent. Press J. Orthod.* **2012**, *17*, 19–29.
43. Mubarak, H.; Tajrin, A.; Gazali, M.; Rahman, F.U.A. Impacted mandibular third molars: A comparison of orthopantomography and cone-beam computed tomography imaging in predicting surgical difficulty. *Arch. Craniofacial Surg.* **2024**, *25*, 217. [CrossRef]
44. Al-Haj Husain, A.; Stadlinger, B.; Winklhofer, S.; Bosshard, F.A.; Schmidt, V.; Valdec, S. Imaging in third molar surgery: A clinical update. *J. Clin. Med.* **2023**, *12*, 7688. [CrossRef] [PubMed]

45. Steinfort, K.; Chalub, M.; Gloria Mora, C.; Zaror, C.; Monardes, H.; Abarca, J. Prevalence and Morphology of Extra-Roots in Mandibular Molars: A Cone-Beam Computed Tomography Study. *Int. J. Morphol.* **2024**, *42*, 1761–1766. [CrossRef]
46. Karkhaneh, M.; Karkehabadi, H.; Alafchi, B.; Shokri, A. Association of root morphology of mandibular second molars on panoramic-like and axial views of cone-beam computed tomography. *BMC Oral Health* **2023**, *23*, 856. [CrossRef]
47. y Baena, R.R.; Beltrami, R.; Tagliabo, A.; Rizzo, S.; Lupi, S.M. Differences between panoramic and Cone Beam-CT in the surgical evaluation of lower third molars. *J. Clin. Exp. Dent.* **2017**, *9*, e259. [CrossRef]
48. Leung, Y.Y.; Hung, K.F.; Li, D.T.S.; Yeung, A.W.K. Application of Cone Beam Computed Tomography in Risk Assessment of Lower Third Molar Surgery. *Diagnostics* **2023**, *13*, 919. [CrossRef]
49. Matzen, L.H.; Wenzel, A. Efficacy of CBCT for assessment of impacted mandibular third molars: A review–based on a hierarchical model of evidence. *Dentomaxillofacial Radiol.* **2015**, *44*, 20140189. [CrossRef]

Disclaimer/Publisher's Note: The statements, opinions and data contained in all publications are solely those of the individual author(s) and contributor(s) and not of MDPI and/or the editor(s). MDPI and/or the editor(s) disclaim responsibility for any injury to people or property resulting from any ideas, methods, instructions or products referred to in the content.