applied sciences

MDPI

Review

Tumor Microenvironment and Dermatological Conditions in Prostate Cancer

Corina Daniela Ene [1,2], Cristina Capusa [1,2], Ilinca Nicolae [3,*], Mircea Tampa [4,5,*], Madalina Irina Mitran [6], Cristina Iulia Mitran [6], Claudia Ioana Dogaru [5], Andrei Marin [7], Ecaterina Rinja [8], Clara Matei [4] and Simona Roxana Georgescu [4,5]

1 Department of Nephrology, 'Carol Davila' University of Medicine and Pharmacy, 020021 Bucharest, Romania; corina.ene@umfcd.ro (C.D.E.); cristina.capusa@umfcd.ro (C.C.)
2 Department of Nephrology, 'Carol Davila' Nephrology Hospital, 010731 Bucharest, Romania
3 Research Department, 'Victor Babes' Clinical Hospital for Infectious Diseases, 030303 Bucharest, Romania
4 Department of Dermatology, 'Carol Davila' University of Medicine and Pharmacy, 020021 Bucharest, Romania; matei_clara@yahoo.com (C.M.); srg.dermatology@gmail.com (S.R.G.)
5 Department of Dermatology, 'Victor Babes' Clinical Hospital for Infectious Diseases, 030303 Bucharest, Romania; claudia_ioana97@yahoo.com
6 Department of Microbiology, 'Carol Davila' University of Medicine and Pharmacy, 020021 Bucharest, Romania; madalina.irina.mitran@gmail.com (M.I.M.); cristina.iulia.mitran@gmail.com (C.I.M.)
7 Department of Plastic Surgery, 'Carol Davila' University of Medicine and Pharmacy, 020021 Bucharest, Romania; andrei.marin@umfcd.ro
8 Department of Gastroenterology, Clinical Emergency Hospital of Bucharest, 014461 Bucharest, Romania; ecaterina.rinja@gmail.com
* Correspondence: dermatology.mt@gmail.com (M.T.); drnicolaei@yahoo.ro (I.N.)

Abstract: Tumor initiation, progression, and invasion are closely related to the tumor microenvironment. Inflammation can modulate the activity of the cells in the TME and contribute to all stages of tumor development. The etiopathogenesis of cutaneous manifestations associated with prostate cancer is unclear. The cutaneous phenotype associated with prostate cancer could be supported by intratumoral heterogeneity, the remodeling of interactions in the tumor microenvironment, and the dynamics of the epithelial–mesenchymal transition. Among the urinary system cancers, prostate cancer presents few cutaneous signs and symptoms, most being diagnosed in the advanced stages of the disease. In this review, we analyze the cutaneous events associated with prostate cancer, represented by direct or indirect manifestations of the primary malignancy and the skin toxicities caused by oncological medications.

Keywords: prostate cancer; tumor microenvironment; inflammation; associated cutaneous manifestations

check for updates

Citation: Ene, C.D.; Capusa, C.; Nicolae, I.; Tampa, M.; Mitran, M.I.; Mitran, C.I.; Dogaru, C.I.; Marin, A.; Rinja, E.; Matei, C.; et al. Tumor Microenvironment and Dermatological Conditions in Prostate Cancer. *Appl. Sci.* **2024**, *14*, 9655. https://doi.org/10.3390/app14219655

Academic Editors: Vittorio Gentile, Francesca Silvagno and Jongsung Lee

Received: 30 August 2024
Revised: 15 October 2024
Accepted: 21 October 2024
Published: 22 October 2024

Copyright: © 2024 by the authors. Licensee MDPI, Basel, Switzerland. This article is an open access article distributed under the terms and conditions of the Creative Commons Attribution (CC BY) license (https://creativecommons.org/licenses/by/4.0/).

1. Introduction

Prostate cancer (PCa) is a major public health issue worldwide, being the second most common solid organ malignancy among men, after pulmonary neoplasms. PCa is the most frequently diagnosed neoplasm of the male genitourinary system [1]. Globally, the incidence of PCa is on the rise [2]. Renal cancer has a mortality rate of 30–40% compared to bladder cancer and PCa, which have a rate of around 20% [3]. According to the WHO classification, PCa comprises two main categories of tumors: epithelial tumors and mesenchymal tumors. Epithelial tumors are divided into two families: glandular neoplasms (prostatic cystadenoma, high-grade prostatic intraepithelial neoplasia, intraductal carcinoma of the prostate, prostatic acinar adenocarcinoma, prostatic ductal adenocarcinoma, and treatment-related neuroendocrine prostatic carcinoma) and squamous neoplasms (adenosquamous carcinoma, squamous cell carcinoma, and adenoid cystic (basal cell) carcinoma of the prostate). Mesenchymal tumors include the family of stromal tumors (prostatic stromal

tumor of uncertain malignant potential and prostatic stromal sarcoma) [4]. The vast majority are adenocarcinomas (95%) and have an acinar origin and only a small number originate at the ductal level. Most patients are diagnosed in the early stages, but it should be borne in mind that the morbidity associated with the therapy is significant [5]. The prostate gland is highly prone to cancer, showing higher malignancy rates compared to other urogenital structures. Prostate cancer development is linked to embryonic growth processes, particularly androgen hormone signaling, such as testosterone, and potentially involves other pathways like Sonic Hedgehog (Shh) and Gli-1 oncogene expression, which may drive tumor growth [6].

The main risk factors are age, family history, and race. The risk increases significantly after the age of 55, the highest risk being recorded between 70 and 74. Epidemiological studies show that among African Americans the risk of developing PCa is 60% higher than among whites. Also, among these individuals, the mortality rate is much higher. In addition, genetic factors play a significant role. There is evidence supporting the contribution of an individual's genetic profile to the genesis and progression of PCa. BRCA genes, HOX genes, ATM gene, RNase L (HPC1, lq22), MSR1 (8p), and ELAC2/HPC2 (17p11) are used as biomarkers for PCa [7]. A series of environmental factors have been reported in the development of PCa such as smoking, diet, obesity, and physical activity [8,9]. PCa is often detected in asymptomatic patients through elevated prostate-specific antigen (PSA) levels during screening. A PSA test associated with digital rectal examination helps detect prostate cancer at an early stage [10]. It can also be found incidentally during procedures for benign prostatic hyperplasia. When it is diagnosed in a symptomatic stage, PCa often presents with urinary symptoms, back pain, or blood in the urine. Advanced PCa can spread locally, through the lymphatic system or blood and metastasize to bone, the lungs, and the liver, metastasis to bone being the most commonly encountered [11].

Although prostate cancer (PCa) is the second most common urological malignancy after renal cancer, associated with cutaneous involvement, instances where a skin manifestation is classified as a paraneoplastic syndrome linked to this malignancy are rarely reported in the literature [12,13]. PCa-induced cutaneous manifestations cause considerable discomfort, and usually indicate advanced disease [14]. In the first part, this paper provides a review of the mechanisms of PCa progression, followed by a summary of the cutaneous events related to PCa, which may reflect direct metastatic spread, non-metastatic manifestations of malignancy, or the consequences of oncological treatment.

Mechanisms of PCa Progression

Inflammation is an innate defense mechanism of the body against various infectious and allergic or toxic stimuli. The inflammatory process involves the accumulation of cells such as macrophages, polymorphonuclear cells, and lymphocytes in the vessels and then their extravasation into the tissue. Over 150 years ago, Rudolph Wirchow stated that the main process involved in the appearance of cancer is inflammation. This is also confirmed by epidemiological studies that have shown that patients with inflammatory diseases have a higher risk of developing malignancies than the rest of the population [15]. Studies have shown that in almost 90% of PCa cases, histopathological examination highlights the presence of inflammatory infiltrate. In addition, a direct correlation was observed between the extent of inflammation and the grade of the tumor. The mechanisms by which chronic inflammation appears in the prostate are not fully known, but it seems that the microbial flora in the urinary tract could play a key role. The inflammatory infiltrate contains numerous types of cells that form a network, being interconnected, a network that will release a series of mediators with essential effects in tumor progression. The most important cells identified in the tumor infiltrate are CD3+ T cells (70–80%, largely CD4+ T cells), CD20+ B cells (10–15%), and macrophages (10–15%) [16].

Initially, neoplasia was considered a pathologic process that involves cell and gene expression; however, today we know that it is a disease of the tumor microenvironment (TME) [17–19]. In PCa, the mechanisms of cancer progression may be due to TME het-

erogeneity and aberrant activation of epithelial–mesenchymal transition (EMT). The TME supports tumor cell mobility, metastasis, and cell survival in distant organs, and EMT promotes tumor invasion and metastasis [13,20,21].

The TME is a dynamic system in which the tumor interacts with multiple host cells [17]. Host components include various cells, including stromal, endothelial, or immune cells, which interact with the extracellular matrix and soluble factors (e.g., cytokines, chemokines, etc.). Tumor cells in the TME stimulate angiogenesis and the release of growth factors, support the aggressiveness of the tumor, and increase the Gleason score [10]. PCa cells can use hexoses as an energy source. PCa overexpresses fructose transporters, but not glucose transporters, compared to benign cells. Therefore, fructose can modulate the biology of PCa. As tumors progress, a series of complex transformations take place in the microenvironment due to the interplay between cancer cells and the surrounding cells [22]. The occurrence of cancer is largely driven by the bidirectional relationship between cancer cells and the tumor microenvironment. These interactions can have significant impacts, influencing tumor cell survival, growth, the formation of new blood vessels, resistance to treatments, evasion of immune detection, and the spread of cancer cells [16]. It should be borne in mind that cells will have a beneficial or harmful effect on the malignant process depending on their needs and metabolic activity.

Multiple lines of evidence show that inflammation, which is the key factor in the development of prostate cancer, plays a decisive role in TME processes. The generation and release of increased amounts of cytokines by TME-associated cells support the development of the primary tumor and allow the progression of the disease to an advanced state by activating EMT and angiogenesis [10,23,24]. Recently, it has been suggested that the periprostatic adipose tissue is part of the PCa tumor microenvironment and is regarded as an active secretory organ. Periprostatic adipose tissue in a paracrine, endocrine, or exocrine manner has the ability to release lipids and adipokines but also hormones that will later participate in the growth of the tumor, which will be followed by invasion of surrounding tissues and metastasis [1]. In recent years, different cells and molecules influenced or stimulated by the TME have been found to impact tumor survival. The metabolic complexity and plasticity of the TME facilitate cancer cells to establish an invasive phenotype. One of the main characteristics of the TME in PCa is the very low or even absent number of T lymphocytes that exhibit antitumor activity in association with an increased number of macrophages. Therefore, macrophages can account for up to 50% of the inflammatory cells found in the TME. A recent study focused on the analysis of the role of Yin Yang 1, a transcription factor, in the pathogenesis of PCa. It has been observed that M2 macrophages expressing this factor in increased amounts contribute to the progression of PCa by promoting IL6 overexpression [25]. Tumor-associated M2 macrophages promote growth and induce immunosuppression. Macrophages could also be crucial in metastatic disease, as a recent study involving patients with metastases treated with docetaxel revealed elevated levels of cytokines linked to macrophages in the blood of these patients. Consequently, in prostate cancer, macrophages seem to play a major role in promoting the development and progression of the disease [26].

CD47 is overexpressed in PCa, where it helps cancer cells evade immune detection by preventing macrophages from phagocytosing them. A recent study found that blocking CD47 enhances macrophage phagocytosis of tumor cells, suggesting that CD47 plays a key role in the tumor's immune microenvironment. As a result, CD47 may serve as a promising target for developing new immunotherapy strategies for PCa [27].

An important role is also played by cancer-associated fibroblasts, which are activated by various mediators, and in turn release a series of cytokines and extracellular matrix (ECM) proteins. The released mediators exhibit a chemoattractant effect and thus infiltrating lymphocytes including NKT, NK, or T cells will migrate to the tumor site and release antiproliferative factors resulting in the activation of apoptosis mechanisms with the final result of tumor death. At the same time, the released cytokines activate immune cells that will produce ECM remodeling factors with consequences on the tissue architecture and its

vascularization and tumor progression will be promoted (Figure 1) [28]. Many exosomes produced by mesenchymal cells increase the migration of cancer cells. Moreover, cancer-associated fibroblasts and the ECM are important players in cancer cell migration and tumor progression and can also impact the therapeutic outcome. In the tumor microenvironment, numerous interactions take place between cells and structural elements, interactions that promote the aggressive behavior and the dissemination of malignant cells that contribute to hypoxia, and promote the development of lesions in distant locations [18].

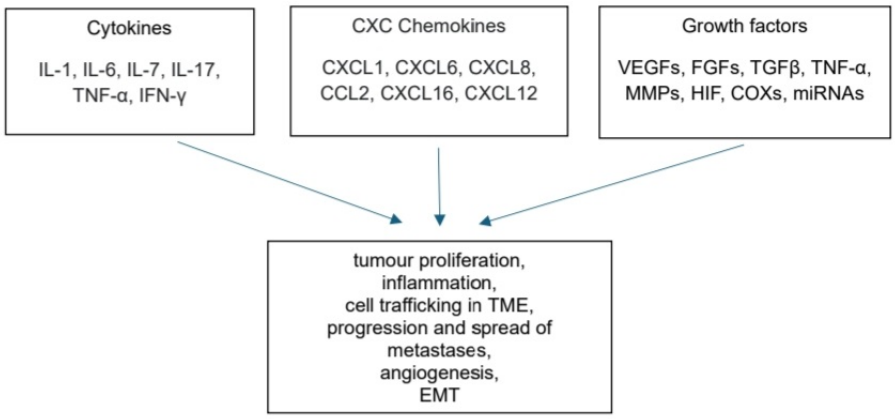

Figure 1. Cytokine/chemokine profile in PCa progression. C and X represent cysteine and non-cysteine residue; VEGFs = Vascular endothelial growth factors; ILs = Interleukins, MMPs = Matrix metalloproteinases; FGFs = Fibroblast growth factors; TGFβ = Transforming growth factor beta; TNF-α = Tumor necrosis factor alpha; IFN-γ = Interferon gamma; COXs = Cyclooxygenases; miRNAs = microRNAs; HIF = Hypoxia inducible factor; TME = tumor microenvironment; EMT = epithelial–mesenchymal transition.

Immunosuppressive neutrophils are a group of myeloid cells that are associated with tumor proliferation and poor response to therapy. It has been shown that immunosuppressive neutrophils in the TME exhibit markers of senescence on the surface. Apolipoprotein E secreted by tumor cells promotes senescence into neutrophils expressing triggering receptor expressed on myeloid cells 2 (TREM2). These cells have been shown to induce a stronger immunosuppressive effect compared to classic immunosuppressive neutrophils. The presence of TREM2+ neutrophils in the TME correlates with an unfavorable outcome [29].

The subset of immune cells predominant in the TME decisively influences the immune response and the antitumor response through the cytokines and chemokines they release. Thus, Tregs acting as immunosuppressants promote tumor progression and have been associated with a low survival rate. On the other hand, an increased number of CD8 T cells, or cytotoxic T lymphocytes, was associated with a favorable outcome of the disease. As for the activity of B lymphocytes, this depends on the immune cells and mediators released into the TME. Thus, for example, IL-21-induced regulatory B cells produce granzyme B and participate to tumorigenesis through the recruitment of Tregs and favor tumor progression and invasion [15,16]

EMT denotes the process by which tumor cells exhibiting epithelial properties shift towards a mesenchymal-like state. In relation to the advancement of PCa, EMT triggers an increase in the expression of growth factors (such as transforming growth factor-beta (TGF-β) and insulin-like growth factor (IGF-1)); activates signaling cascades (including mitogen-activated protein kinase (MAPK) and phosphatidylinositol 3-kinase (PI3K)); stimulates androgen receptor (AR) signaling and suppresses testosterone production; induces the overexpression of some transcription factors (SNAI1/2, ZEB1, TWIST1, and ETS,); activates tumor suppressor genes (RB1, PTEN, and TP53); inhibits the expression of epithelial cell–cell contact factors (E-cadherin and β-catenin); increases the expression of mesenchymal factors (vimentin and N-cadherin); promotes loss of cell–cell adhesion; and, eventually, facilitates cell migration [23].

A major role in the regulation of EMT and TEM remodeling is attributed to epigenetic mechanisms. Epigenetic changes exert their effect at the chromosomal level (DNA methylation, histone modification, nucleosome positioning, and chromatin organization) and at the RNA level (RNA changes and microRNA regulation) [23,24].

A recent hypothesis supports the concept that genetic and epigenetic changes, clonal expansion, EMT, Wnt, Sonic Hedgehog, and Notch signaling pathways favor the emergence of cancer stem cells in PCa. PCa stem cells, capable of self-renewal, pluripotency, and plasticity, have been shown to be essential factors in the processes associated with carcinogenesis (tumor growth, invasion, and metastasis) and in the emergence of resistance to antitumor therapies [30–32].

In summary, the available evidence demonstrates that EMT and the TME orchestrate tumor progression (Figure 2).

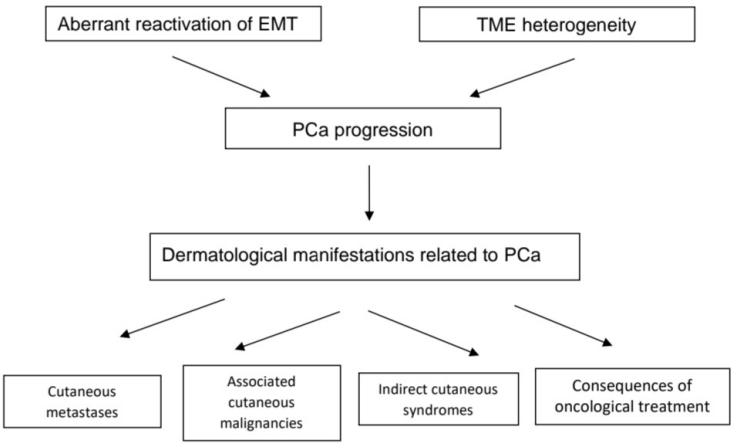

Figure 2. Dermatological conditions related to PCa (EMT—epithelial–mesenchymal transition; TME—tumor microenvironment; PCa—prostate cancer).

2. The Cutaneous Manifestations Associated with PCa

The skin is a viable substrate for the development of signs and symptoms associated with malignancy. Cutaneous manifestations are rare disorders that may be triggered by an altered immune system response to a neoplasm [33–35], TME dynamics [20], EMT activation [23,24], inflammation [17], angiogenesis [10,13], and genetic and epigenetic changes [21,32]. In the following subsections, we have summarized the malignant and nonmalignant skin manifestations induced by PCa and the consequences of oncological treatment. The majority of PCa-associated skin symptoms and signs, commonly reported in the medical literature, have occurred in advanced PCa and may coincide with the initial presentation of malignancy, or may represent the first sign of disease progression in those with known PCa. It is crucial to recognize these syndromes for proper patient management and to prevent further complications [36].

2.1. Cutaneous Metastases Derived from Pca

The skin was defined as "a mirror of metastatic destiny" [35]. Metastasis is a laborious process that occurs when the primary tumor grows large enough that it can invade other tissues. Several stages of metastasis have been described. The first stage consists of local invasion, and then the tumor cells penetrate the vessels, manage to survive in circulation, and thus reach distant organs where extravasation and the formation of metastases take place [14,18,37,38]. Regarding solid cancers, it was reported that cutaneous metastases could be the first sign of malignancy (early metastases); they can develop concomitantly with the primary malignancy (synchronous metastases) or they can indicate the recurrence or progression of malignancy (metachronous metastases) [34,35].

Cutaneous metastases develop predominantly through vascular invasion (lymphatic or hematogenous) or direct tumor invasion (contiguity) [14]. It is estimated that 0.7–9%

(global mean incidence of 5.3%) of metastases derived from solid tumors occur in the skin [35]. In addition, skin metastases associated with carcinomas of the genitourinary tract come from the kidneys (66%), bladder (17%), prostate (12%), and testicles (4%) [39]. Cutaneous metastases developed from PCa are rare (0.36%), cause considerable discomfort, and have a serious impact on survival [39–41].

The clinical presentation of PCa metastases is diverse. The metastases appear as single or multiple nodules or plaques, edema, a nonspecific rash, or ulcers. The recently reported atypical cases are described as telangiectatic lesions or vesicular lesions [37,39,42–44]. PCa skin metastases show varied morphological models: solid/poorly differentiated, glandular/ductal, infiltrative, mucinous with a signet ring, telangiectatic, lymphangitic, and with epidermotropism [45–47]. Cutaneous metastases developed from PCa are located in the groin and penis (28%), abdomen (23%), head and neck (16%), chest (14%), extremities (10%), and back (9%) [48]. Cutaneous metastases from PCa are positive for PSA, prostatic acid phosphatase, and negative for CK7, CK20, and thrombomodulin [14]. From the data presented, we deduce that there is no clear predilection for the skin region affected by PCa metastases.

2.2. Metachronous and Synchronous Skin Malignancies Associated with PCa

There are case reports that present patients diagnosed with simultaneous tumors, including squamous cell carcinoma and melanoma [41,49–52].

The description of several types of primary cancer in the same individual is a rarity. The presence of three primary malignancies in the same patient was reported. In the first stage, squamous cell carcinoma of the mandible, with moderate differentiation, was identified. After three years, two types of synchronous cancer were detected in the same patient, namely poorly differentiated axillary squamous cell cancer and PCa [50,51]. In the literature, the development of two simultaneous tumors (adenocarcinoma of the prostate and undifferentiated carcinoma of the submandibular gland) in the same patient was also presented [52]. In conclusion, the simultaneous presence of several primary tumors with different origins in PCa patients could be approached as a possible syndrome in prostatic malignancies.

Numerous studies have explored the bidirectional relationship between melanoma and PCa. In a recent epidemiological study, it was estimated that men who had multiple melanomas were at least twice as likely to be diagnosed with PCa compared to men who had never had melanomas [53]. There are several factors that can be involved in the development of the two forms of cancer, such as genetic factors, lifestyle factors, possible similar pathogenic mechanisms, UV exposure, or absence of PTEN function [41,51,54].

2.3. Potential Nonmalignant Cutaneous Manifestations Associated with PCa

Paraneoplastic syndromes are conditions linked to cancer that are not caused by direct tumor invasion. These syndromes are considered indirect systemic manifestations related to the tumor. PCa in advanced stages is the second most frequent urological neoplasm connected to paraneoplastic syndromes, following renal cell carcinoma [13,55].

SAPHO syndrome (synovitis, acne, pustulosis, hyperostosis, and osteitis) is an uncommon autoimmune disorder exceptionally associated with cutaneous metastasis of PCa. In general, paraneoplastic arthritides represent immune-mediated inflammatory diseases that can occur in conjunction with occult or manifest malignancy [56].

The coexistence of malignant acanthosis nigricans and PCa is rare, and few cases have been reported. Acanthosis nigricans most probably appears due to substances produced by tumors that stimulate keratinocytes, melanocytes, and fibroblasts. Hyperpigmentation and hyperkeratosis are clinical features found in patients with acanthosis nigricans; sometimes, the lesions may also involve the mucous membranes [49].

PCa has been linked to simultaneous paraneoplastic manifestations of the skin in the same patient, such as Bazex syndrome, acquired ichthyosis, or the Leser–Trélat sign [57].

Paraneoplastic acrokeratosis (Bazex syndrome) is defined by the symmetrical occurrence of of erythemato-squamous plaques with undefined margins in the acral areas and nail damage (hyperkeratosis, onycholysis, growth and thickening, and yellow pigmentation) [57]. In addition to the connection with paraneoplastic lesions, Bazex syndrome has been detected in association with multiple simultaneous genitourinary tumors (multifocal basal cell carcinoma, squamous cell carcinoma of the lung, PCa, and possibly undifferentiated bladder carcinoma) [58]. Occasionally, Bazex syndrome has developed simultaneously with PCa, undifferentiated carcinoma of the submandibular gland, or psoriasiform acral dermatitis [52].

Adult-onset ichthyosis should be seen as a marker of systemic disease, including malignancy [57]. A case of PCa associated with cutaneous lymphangitis and paraneoplastic ichthyosis was reported. A large angiomatous skin lesion, axillary nodule, and paraneoplastic ichthyosis demonstrated prostatic origin with carcinomatous metastases to lymphatic vessels [59].

The Leser–Trelat sign is a rare paraneoplastic manifestation that indicates an internal malignancy. The Leser–Trélat sign has been described as the sudden appearance of numerous seborrheic keratoses of different sizes; in some cases, the lesions are pruriginous [57]. It has been most commonly reported in association with colon or breast cancer, but it has also been described among patients with prostate cancer. The mechanism of occurrence is not fully understood, but it seems that cytokines and growth factors have an important role in the sudden onset of numerous seborrheic keratoses. In most cases, the diagnosis is easy, but histopathological examination may sometimes be necessary [60].

Hematological neoplasms are the most frequently associated with Sweet. The association of Sweet syndrome with solid tumors is unusual. The simultaneous presence of Sweet syndrome with PCa and transitional cell carcinoma of the urinary bladder, occurring in the same patient, has been reported. Sweet syndrome, also known as acute febrile neutrophilic dermatosis, is defined as an eruption consisting of painful plaques or nodules, predominantly located on the head, neck, and upper extremities. In some cases, the mucous membranes are involved [61].

Occasionally, metastatic PCa has been associated with immune-mediated cytopenias such as Evans syndrome. Evans syndrome can cause petechiae, ecchymosis, spontaneous bleeding, or autoimmune thrombocytopenic purpura [55].

Darier disease, an autosomal dominant hereditary acantholytic dermatosis associated with metastatic PCa, is an unusual presentation [62]. Darier's disease is characterized by the appearance of gray-brown hyperkeratotic papules primarily distributed in the seborrheic areas; in some cases, changes in the nails (brittle nails and red and white longitudinal striae) and mucosal lesions can appear [63].

Concomitant scleroderma and PCa can develop independently of each other; scleroderma can be induced by the tumor or the tumor can be induced by immunosuppressive therapy used in scleroderma. Paraneoplastic scleroderma is characterized by immunological dysregulation, vasculopathy, and extracellular matrix hyperproduction by activated fibroblasts [64].

The coexistence of dermatomyositis with a prostate tumor is associated with a gradual expression of skin involvement; initially, classic skin marks appear, which evolve into vesicular lesions and, later, into myopathy [65]. In a patient with typical skin abnormalities and muscle weakness, dermatomyositis and the presence of a possible underlying malignancy should be considered. Treatment with prednisone has been shown to be successful [66]. Dermatomyositis, systemic sclerosis, and mixed connective tissue disease associated with diabetes mellitus have been described in the setting of PCa [67].

It has been reported that anti-laminin-332 mucous membrane pemphigoid, an autoimmune bullous disease, can develop as a paraneoplastic condition in patients with solid organ neoplasms. In the medical literature, the association between metastatic PCa and anti-laminin-332 mucous membrane pemphigoid has been described. The connection between

the two diseases is not clear, the pathogenic mechanisms involved being incompletely elucidated [68].

An early detailed history and routine screening led to the diagnosis of erythroderma (also known as generalized exfoliative dermatitis) in a patient with PCa. Exfoliative dermatitis is an uncommon inflammatory dermatological disorder with a clinical picture consisting of a widespread erythematous rash, hair loss, and nail changes (subungual hyperkeratosis, onycholysis, nail fragility, or nail loss). It has been described as a complication of diseases such as psoriasis or allergies or as an adverse event of drugs, or in the context of infections or neoplasms [69,70]. Even though it has various etiological possibilities, erythroderma has been defined as a paraneoplastic effect of PCa.

The association of paraneoplastic pemphigus with PCa is extremely unusual. The histological features of paraneoplastic pemphigus are represented by epidermal acantholysis, keratinocyte necrosis, interface lichenoid dermatitis, and the presence of IgG and C3 deposits either intercellularly or along the dermo-epidermal junction. The clinical picture and the histopathological characteristics show similarities in paraneoplastic pemphigus and classical pemphigus [71]. The cutaneous and mucosal lesions seen in paraneoplastic pemphigus are induced by tumor-induced autoantibodies [72,73].

Data on numb chin syndrome in the context of malignancy are scarce. This condition occurs late in the course of PCa [74].

PCa is a neoplastic disease that can induce chronic pruritus. Chronic pruritus is a distressing symptom that can often reveal several pathological findings [75]. Absence of biliary obstruction and liver metastases, jaundice, and pruritus were associated with cholestasis [75,76].

A patient who presented long-lasting episodes of idiopathic urticaria, followed by a sudden increase in frequency, was diagnosed with PCa. Treatment with a luteinizing hormone antagonist resolved the urticaria [77].

The detailed early history of PCa patients and routine screening have led to the occasional detection of cutaneous manifestations such as fulminant distal phalangeal necrosis of the lower extremities after a diagnosis of PCa [33], erytema gyratum repens [78], eosinophilic annular erythema [79], paraneoplastic palmar fasciitis and polyarthritis syndrome [80], erythema annulare centrifugum of the legs, fulminant digital necrosis [81], subcutaneous bleeding [82], acanthosis nigricans [83], transient acantholytic dermatosis [84], and pityriasis rubra pilaris [85].

The previously presented dermatological manifestations associated with PCa have several characteristics of a paraneoplastic syndrome: they appear at a distance from the tumor, they evolve synchronously or metachronously with the neoplasia, they are remitted after a successful PCa surgical intervention, they can develop through immunological or non-immunological mechanisms, and clinical manifestations are not associated with the clinical or pathological stage of the underlying malignancy, nor are they prognostic indicators [86]. Based on the current data, summarized for the first time in this article, it is difficult to clearly establish the paraneoplastic syndromes associated with PCa because these manifestations can occur in up to 8% of cancer patients; their incidence and prevalence are unknown and have heterogeneous manifestations [12,86].

2.4. Adverse Cutaneous Drug Events in PCa Patients

PCa treatment options include prostatectomy, radiotherapy, chemotherapy, immunotherapy, hormonal therapy, corticosteroids, and targeted therapy. The severity of drug-induced cutaneous adverse reactions is variable. Mild reactions to severe and sometimes even life-threatening forms were described. There are few articles in the literature that discuss these reactions [18,87–95].

Radiotherapy can cause mild or severe changes in the skin (itching, erythema, edema, pigment spots, desquamation, wounds, infections, and alteration of the barrier function) and pathological changes in the nails (onychomycosis and melanonychia) [88,89].

Chemotherapy can induce cutaneous changes (minor or severe rash, photosensitivity, desquamation, itching, erythema, bullous lesions, hypersensitivity reactions, urticaria, and hypo/hyperpigmentation); hair changes (alopecia, seborrheic dermatitis, and hair fragility); and nail changes (onycholysis, subungual abscesses, onychoschizia, and brittle and cracked nails) [88,89].

The effects of a response to immunotherapy (inhibitors of the programmed death receptor 1-PD-1) can be systematized as follows: changes in the mucous membranes (severe, extensive, and painful blisters); cutaneous changes (acneiform eruptions, dry or blistered skin, hand–foot syndrome, hypo/hyperpigmentation spots, eruptive melanocytic nevi, pruritus, keratoacanthoma, phototoxic and photoallergic reactions, erythema, and angioedema); nail changes (cracked and yellow nails, disorganized cuticles, melanonychia, and acute paronychia); and hair changes (alopecia areata) [87,88].

Hormonal therapy for PCa (luteinizing hormone-releasing hormone agonists and antiandrogens) causes hypersensitivity reactions (anaphylaxis, urticaria, and angioedema), pruritus, arthralgia, hot flashes, peripheral edema, or acne vulgaris [87]. PCa patients treated with the androgen receptor inhibitor apalutamide frequently develop skin rashes, distributed on the trunk, extremities, head/neck, and genitals. The most common cutaneous manifestations caused by androgen receptor inhibitor apalutamide are as follows: xerosis, maculopapular rash, erythematous rash, eczematous rash, acneiform rash, psoriasiform rash, urticaria, pruritus with/without rash, petechiae, alopecia, oral lichen planus [90], acute generalized exanthematous pustulosis, and Stevens–Johnson syndrome/toxic epidermal necrolysis [91,93,94].

Genomic targeted therapy, recently approved for patients with castration-resistant PCa, includes the use of olaparib and rucaparib as blockers for PARP proteins. These chemotherapeutic agents inhibit poly(adenosine diphosphate-ribose) polymerase, a DNA repair factor [87,95,96]. Although there are few reports, olaparib could induce purpuric eruptions limited to the fingers, erythema nodosum, arthralgia, peripheral edema, skin rash, hypersensitivity, and alopecia [87,95]. The management of adverse dermatological events gives dermatology a fundamental role in the multidisciplinary team support for cancer patients.

3. Conclusions

The mechanisms that underlie the progression of PCa are unclear. In summary, this review provides an understanding of the relationship between TME heterogeneity, the mechanisms controlling EMT, and PCa-induced skin remodeling. For the first time, this comprehensive approach to the relationship between TME and EMT roles in PCa development and progression will provide a conceptual shift for the study of the relationship tumor–immunity–secondary determinations–precision medicine. The evidence analyzed in this article supports the hypothesis that the skin is a fertile ground for the development of PCa-related events, which may reflect direct metastatic spread, indirect manifestations of malignancy, or the consequences of the applied treatment. However, the involved mechanisms are not elucidated. There is a possibility that some of the manifestations are coincidental. That is why we believe that such a summarization can underlie further research on the link between skin manifestations and PCa. Close collaboration between multidisciplinary teams of healthcare professionals is essential to start preventive measures in time to provide better management of PCa patients.

Funding: This research received no external funding.

Conflicts of Interest: The authors declare no conflicts of interest.

References

1. Cao, H.; Wang, Y.; Zhang, D.; Liu, B.; Zhou, H.; Wang, S. Periprostatic Adipose Tissue: A New Perspective for Diagnosing and Treating Prostate Cancer. *J. Cancer* **2024**, *15*, 204–217. [CrossRef] [PubMed]
2. Huang, J.; Chan, E.O.-T.; Liu, X.; Lok, V.; Ngai, C.H.; Zhang, L.; Xu, W.; Zheng, Z.-J.; Chiu, P.K.-F.; Vasdev, N.; et al. Global Trends of Prostate Cancer by Age, and Their Associations with Gross Domestic Product (GDP), Human Development Index (HDI), Smoking, and Alcohol Drinking. *Clin. Genitourin. Cancer* **2023**, *21*, e261–e270.e50. [CrossRef]
3. Yang, Z.; Hou, Y.; Li, J.; Xu, D.; Yang, Z.; Wang, X. Activating Transcription Factor 3 Is a New Biomarker Correlation with Renal Clear Cell Carcinoma Progression. *Int. J. Immunopathol. Pharmacol.* **2024**, 38. [CrossRef]
4. Surintrspanont, J.; Zhou, M. Prostate Pathology: What is New in the 2022 WHO Classification of Urinary and Male Genital Tumors? *Pathologica* **2023**, *115*, 41. [CrossRef]
5. Wasim, S.; Lee, S.-Y.; Kim, J. Complexities of Prostate Cancer. *Int. J. Mol. Sci.* **2022**, *23*, 14257. [CrossRef] [PubMed]
6. Murray, T.B.J. The Pathogenesis of Prostate Cancer. In *Prostate Cancer*; Exon Publications: Camberley, UK, 2021. [CrossRef]
7. Sekhoacha, M.; Riet, K.; Motloung, P.; Gumenku, L.; Adegoke, A.; Mashele, S. Prostate Cancer Review: Genetics, Diagnosis, Treatment Options, and Alternative Approaches. *Molecules* **2022**, *27*, 5730. [CrossRef] [PubMed]
8. Matsushita, M.; Fujita, K.; Nonomura, N. Influence of Diet and Nutrition on Prostate Cancer. *Int. J. Mol. Sci.* **2020**, *21*, 1447. [CrossRef]
9. Gann, P. Risk Factors for PCa. *Rev. Urol.* **2002**, *4* (Suppl. S5), S3–S10. [PubMed] [PubMed Central]
10. Cosmin, E.; Ilinca, N.; Daniela, E. Angiogenic Systemic Response to the Hypoxic Microenvironment in Prostate Tumorigenesis: A Pilot Study. *Exp. Ther. Med.* **2023**, *26*, 483. [CrossRef]
11. Wells, K.V.; Krackeler, M.L.; Jathal, M.K.; Parikh, M.; Ghosh, P.M.; Leach, J.K.; Genetos, D.C. Prostate Cancer and Bone: Clinical Presentation and Molecular Mechanisms. *Endocr.-Relat. Cancer* **2023**, *30*, e220360. [CrossRef]
12. Raghavan, D. Cutaneous Manifestations of Genitourinary Malignancy. *Semin. Oncol.* **2016**, *43*, 347–352. [CrossRef] [PubMed]
13. Ene, C.D.; Tampa, M.; Georgescu, S.R.; Matei, C.; Leulescu, I.M.T.; Dogaru, C.I.; Penescu, M.N.; Nicolae, I. Disturbances in Nitric Oxide Cycle and Related Molecular Pathways in Clear Cell Renal Cell Carcinoma. *Cancers* **2023**, *15*, 5797. [CrossRef] [PubMed]
14. Souza, B.d.C.e.; Miyashiro, D.; Pincelli, M.S.; Sanches, J.A. Cutaneous Metastases from Solid Neoplasms—Literature Review. *An. Bras. Dermatol.* **2023**, *98*, 571–579. [CrossRef] [PubMed]
15. Rani, A.; Dasgupta, P.; Murphy, J.J. Prostate Cancer: The Role of Inflammation and Chemokines. *Am. J. Pathol.* **2019**, *189*, 2119–2137. [CrossRef]
16. Shiao, S.L.; Chu, G.C.-Y.; Chung, L.W. Regulation of Prostate Cancer Progression by the Tumor Microenvironment. *Cancer Lett.* **2016**, *380*, 340–348. [CrossRef]
17. Ene, C.-V.; Nicolae, I.; Geavlete, B.; Geavlete, P.; Ene, C.D. IL-6 Signaling Link between Inflammatory Tumor Microenvironment and Prostatic Tumorigenesis. *Anal. Cell. Pathol.* **2022**, *2022*, 5980387. [CrossRef]
18. Wang, Q.; Shao, X.; Zhang, Y.; Zhu, M.; Wang, F.X.C.; Mu, J.; Li, J.; Yao, H.; Chen, K. Role of Tumor Microenvironment in Cancer Progression and Therapeutic Strategy. *Cancer Med.* **2023**, *12*, 11149–11165. [CrossRef]
19. Georgescu, S.R.; Tocut, S.M.; Matei, C.; Ene, C.D.; Nicolae, I.; Tampa, M. A Panel of Potential Serum Markers Related to Angiogenesis, Antioxidant Defense and Hypoxia for Differentiating Cutaneous Squamous Cell Carcinomas from Actinic Keratoses. *J. Pers. Med.* **2024**, *14*, 103. [CrossRef] [PubMed]
20. Avolio, P.P.; Polascik, T.J.; Rastinehad, A.; de la Rosette, J.; Sanchez-Salas, R. Focal Therapy for Prostate Cancer: Evolutionary Parallels to Breast Cancer Treatment. Letter. *J. Urol.* **2023**, *209*, 848–849. [CrossRef]
21. Ene, C.D.; Penescu, M.N.; Georgescu, S.R.; Tampa, M.; Nicolae, I. Posttranslational Modifications Pattern in Clear Cell Renal Cell Carcinoma. *Metabolites* **2020**, *11*, 10. [CrossRef]
22. Carreño, D.V.; Corro, N.B.; Cerda-Infante, J.F.; Echeverría, C.E.; Asencio-Barría, C.A.; Torres-Estay, V.A.; Mayorga-Weber, G.A.; Rojas, P.A.; Véliz, L.P.; Cisternas, P.A.; et al. Dietary Fructose Promotes Prostate Cancer Growth. *Cancer Res.* **2021**, *81*, 2824–2832. [CrossRef] [PubMed]
23. Yu, E.-M.; Hwang, M.W.; Aragon-Ching, J.B. Mechanistic Insights on Localized to Metastatic Prostate Cancer Transition and Therapeutic Opportunities. *Res. Rep. Urol.* **2023**, *15*, 519–529. [CrossRef] [PubMed]
24. Luo, Z.; Wang, W.; Xiang, L.; Jin, T. Association between the Systemic Immune-Inflammation Index and Prostate Cancer. *Nutr. Cancer* **2023**, *75*, 1918–1925. [CrossRef]
25. Chen, S.; Lu, K.; Hou, Y.; You, Z.; Shu, C.; Wei, X.; Wu, T.; Shi, N.; Zhang, G.; Wu, J.; et al. YY1 complex in M2 macrophage promotes prostate cancer progression by upregulating IL-6. *J. Immunother. Cancer* **2023**, *11*, e006020. [CrossRef]
26. Mahon, K.L.; Lin, H.-M.; Castillo, L.; Lee, B.Y.; Lee-Ng, M.; Chatfield, M.D.; Chiam, K.; Breit, S.N.; Brown, A.D.; Molloy, M.P.; et al. Cytokine profiling of docetaxel-resistant castration-resistant prostate cancer. *Br. J. Cancer* **2015**, *112*, 1340–1348. [CrossRef] [PubMed]
27. Wang, Q.; Feng, C.; Chen, Y.; Peng, T.; Li, Y.; Wu, K.; Pu, X.; Chen, H.; Liu, J. Evaluation of CD47 in the Suppressive Tumor Microenvironment and Immunotherapy in Prostate Cancer. *J. Immunol. Res.* **2023**, *2023*, 2473075. [CrossRef]
28. Nair, S.S.; Weil, R.; Dovey, Z.; Davis, A.; Tewari, A.K. The Tumor Microenvironment and Immunotherapy in Prostate and Bladder Cancer. *Urol. Clin. N. Am.* **2020**, *47*, e17–e54. [CrossRef]

29. Bancaro, N.; Calì, B.; Troiani, M.; Elia, A.R.; Arzola, R.A.; Attanasio, G.; Lai, P.; Crespo, M.; Gurel, B.; Pereira, R.; et al. Apolipoprotein E Induces Pathogenic Senescent-Like Myeloid Cells in Prostate Cancer. *Cancer Cell* **2023**, *41*, 602–619.e11. [CrossRef]
30. Wolf, I.; Gratzke, C.; Wolf, P. Prostate Cancer Stem Cells: Clinical Aspects and Targeted Therapies. *Front. Oncol.* **2022**, *12*, 935715. [CrossRef]
31. Koukourakis, I.M.; Platoni, K.; Kouloulias, V.; Arelaki, S.; Zygogianni, A. Prostate Cancer Stem Cells: Biology and Treatment Implications. *Int. J. Mol. Sci.* **2023**, *24*, 14890. [CrossRef]
32. Al Salhi, Y.; Sequi, M.B.; Valenzi, F.M.; Fuschi, A.; Martoccia, A.; Suraci, P.P.; Carbone, A.; Tema, G.; Lombardo, R.; Cicione, A.; et al. Cancer Stem Cells and Prostate Cancer: A Narrative Review. *Int. J. Mol. Sci.* **2023**, *24*, 7746. [CrossRef] [PubMed]
33. Akin, Y.; Yucel, S.; Baykara, M. Distal Phalangeal Necrosis in the Extremities as a Paraneoplastic Syndrome in Prostate Cancer: An Extremely Rare Case. *Urol. Int.* **2014**, *93*, 244–246. [CrossRef] [PubMed]
34. Siegel, R.L.; Giaquinto, A.N.; Jemal, A. Cancer statistics, 2024. *CA Cancer J. Clin.* **2024**, *74*, 12–49. [CrossRef] [PubMed]
35. Monteiro, R.; Madhumita, M.; Kumar, H.; Martis, J. A Mirror of Metastatic Destiny—A Case Series of Cutaneous Metastases. *Clin. Dermatol. Rev.* **2024**, *8*, 58–62. [CrossRef]
36. Abufaraj, M.; Ramadan, R.; Alkhatib, A. Paraneoplastic Syndromes in Neuroendocrine Prostate Cancer: A Systematic Review. *Curr. Oncol.* **2024**, *31*, 1618–1632. [CrossRef]
37. Kavak, A.; Yılmaz, M.; Çam, H.; Tuğcu, V.; Albayrak, H.; Sakız, D.; Yıldırım, Ü. Cutaneous Metastasis in Prostate Cancer: Two Cases with Similar Clinical Findings. *J. Cancer Res. Ther.* **2018**, *14*, S1213–S1216. [CrossRef]
38. Flores-Terry, M.; de Boom, R.C.-C.; García-Arpa, M.; de Lara-Simón, I. Metástasis Cutáneas de Adenocarcinoma de Próstata. *Actas Dermo-Sifiliogr.* **2018**, *109*, 360. [CrossRef]
39. Marampon, F.; Parisi, M.; Cicco, P.R.; Serpone, M.; Tomaciello, M.; Musio, D.; De Felice, F.; Tombolini, V. Skin Metastases from Prostate Cancer Successfully Treated with Radiation Therapy. *BJR Case Rep.* **2023**, *9*, 20200142. [CrossRef]
40. Telis, L.; Wolf, V.; Yaskiv, O.; Pearson, B.J.; Katsigeorgis, M.; Jazayeri, S.B.; Samadi, D.B.; Unger, P.D. Skin Metastasis, an Uncommon Course of Prostate Carcinoma: A Report of Two Cases. *Malays. J. Pathol.* **2016**, *38*, 165–168.
41. Venkata, S.A.; Hakobyan, N.; Yadav, R.; Pokhrel, A.; Jamal, F.; Boris, A.; Kay, A.; Oudit, O.A. Simultaneous Thoracic Spine Metastatic Melanoma and Pre-existing Prostate Adenocarcinoma: A Unique Case Presentation and Literature Review. *Cureus* **2023**, *15*, e43429. [CrossRef]
42. Patel, A.; Kataria, P.; Kendre, P.; Dalsaniya, S. Cutaneous Metastasis Leading to the Diagnosis of Carcinoma of the Prostate: A Rare Case Report and Review of Literature. *Indian J. Dermatol.* **2018**, *63*, 182–185. [CrossRef] [PubMed]
43. Mak, G.; Chin, M.; Nahar, N.; De Souza, P. Cutaneous Metastasis of Prostate Carcinoma Treated with Radiotherapy: A Case Presentation. *BMC Res. Notes* **2014**, *7*, 505. [CrossRef] [PubMed]
44. Wong, J.K.; Minni, J.P.; Nowak, M.A. A Novel Case of NKX3.1-Positive Metastatic Cutaneous Prostate Cancer. *Dermatol. Online J.* **2018**, *24*, 7. [CrossRef]
45. Petcu, E.B.; Gonzalez-Serva, A.; Wright, R.G.; Slevin, M.; Brinzaniuc, K. Prostate Carcinoma Metastatic to the Skin as an Extrammamary Paget's Disease. *Diagn. Pathol.* **2012**, *7*, 106. [CrossRef] [PubMed]
46. Onalaja-Underwood, A.A.; Sokumbi, O. Eruptive Papules as a Cutaneous Manifestation of Metastatic Prostate Adenocarcinoma. *Am. J. Dermatopathol.* **2023**, *45*, 828–830. [CrossRef]
47. Rodríguez-Lojo, R.; Castiñeiras, I.; Rey-Sanjurjo, J.; Fernández-Díaz, M. Metástasis Cutáneas A Distancia De Cáncer De Próstata: 2 Casos. *Actas Dermo-Sifiliogr.* **2016**, *107*, e52–e56. [CrossRef]
48. Dills, A.; Obi, O.; Bustos, K.; Jiang, J.; Gupta, S. Cutaneous Metastasis of Prostate Adenocarcinoma: A Rare Presentation of a Common Disease. *J. Investig. Med. High Impact Case Rep.* **2021**, *9*, 2324709621990769. [CrossRef]
49. Kubicka-Wołkowska, J.; Dębska-Szmich, S.; Lisik-Habib, M.; Noweta, M.; Potemski, P. Malignant acanthosis nigricans associated with prostate cancer: A case report. *BMC Urol.* **2014**, *14*, 88. [CrossRef]
50. Maruyama, N.; Nakasone, T.; Arakaki, O.; Matsumoto, H.; Maruyama, T.; Matayoshi, A.; Goto, T.; Saito, S.; Yoshimi, N.; Arasaki, A.; et al. Triple Primary Cancer of the Head and Neck, Skin and Prostate: A Case Report and Literature Review. *Oncol. Lett.* **2018**, *16*, 5249–5256. [CrossRef]
51. Patasius, A.; Urbonas, V.; Smailyte, G. Skin Melanoma and Subsequent Risk of Prostate Cancer: A Lithuanian Cancer Registry Study. *Int. J. Environ. Res. Public Health* **2019**, *16*, 3915. [CrossRef]
52. Figueroa-Silva, O.; Espasandín-Arias, M.; García-Martínez, F.J.; Fernández-Redondo, V.; Toribio, J. Is It Just a Psoriasiform Dermatitis? *Dermatol. Online J.* **2017**, 23. [CrossRef]
53. Egger, S.; Egger, S.; Smith, D.P.; Smith, D.P.; Patel, M.I.; Patel, M.I.; Kimlin, M.G.; Kimlin, M.G.; Armstrong, B.K.; Armstrong, B.K.; et al. Cutaneous Melanoma, Prostate-Specific Antigen Testing and the Subsequent Risk of Prostate Cancer Diagnosis: A Prospective Analysis of the 45 and Up Study. *Br. J. Cancer* **2022**, *128*, 71–79. [CrossRef] [PubMed]
54. Ene, C.D.; Nicolae, I. Hypoxia-Nitric Oxide Axis and the Associated Damage Molecular Pattern in Cutaneous Melanoma. *J. Pers. Med.* **2022**, *12*, 1646. [CrossRef] [PubMed]
55. Sidda, A.; Manu, G.; Abdallah, M.; Griswold, D.; Alsharedi, M.; Pacioles, T. Paraneoplastic Evans Syndrome in a Patient with Prostate Cancer with Small Cell Transformation. *Cureus* **2022**, *14*, e24505. [CrossRef] [PubMed]
56. Sehgal, R.; Virata, A.R.; Bansal, P.; Hart, M. Metastatic Carcinoma of Prostate as a Mimicker of SAPHO Syndrome. *Clin. Med. Res.* **2021**, *19*, 141–147. [CrossRef]

57. da Rosa, A.C.M.; Pinto, G.M.; Bortoluzzi, J.S.; Duquia, R.P.; de Almeida, H.L. Three Simultaneous Paraneoplastic Manifestations (Ichthyosis Acquisita, Bazex Syndrome, And Leser–Trélat Sign) with Prostate Adenocarcinoma. *J. Am. Acad. Dermatol.* **2009**, *61*, 538–540. [CrossRef]
58. Atilla, M.K.; Yilmaz, Y.; Bekerecioğlu, M.; Akpolat, N.; Kösem, M.; AydIn, S. Bazex Syndrome: *Acrokeratosis paraneoplastica* in Association With Simultaneous Multiple Genitourinary Tumors. *Urology* **2000**, *56*, 153. [CrossRef]
59. Drappier, J.-C.; Mahé, E.; Memin, A.; Grossin, M.; Descamps, V.; Belaïch, S.; Legrain, S.; Crickx, B. Cutaneous Lymphangitic Carcinomatosis and Acquired Ichtyosis Associated with Prostatic Carcinoma. *Ann. Dermatol. Venereol.* **2003**, *130*, 345–347.
60. Bernett, C.N.; Davidson, C.L.; Schmieder, G.J. Leser-Trélat Sign. In *StatPearls [Internet]*; StatPearls Publication: Treasure Island, FL, USA, 2024.
61. Hussein, K.; Nanda, A.; Al-Sabah, H.; Alsaleh, Q. Sweet's Syndrome (Acute Febrile Neutrophilic Dermatosis) Associated with Adenocarcinoma of Prostate and Transitional Cell Carcinoma of Urinary Bladder. *J. Eur. Acad. Dermatol. Venereol.* **2005**, *19*, 597–599. [CrossRef]
62. Pararajasingam, A.; Ponnambath, N. Acquired Darier Disease in a Patient with Metastatic Prostate Cancer: A Paraneoplastic Process? *Dermatol. Online J.* **2020**, 26. [CrossRef]
63. Kumar, P.; Suryawanshi, H.; Dhobley, A.; Sharma, A. Darier Disease: A Rare Genodermatosis. *J. Oral Maxillofac. Pathol.* **2017**, *21*, 321. [CrossRef] [PubMed]
64. Khamaganova, I. Localized Scleroderma: Predisposing and Triggering Factors. *Open Dermatol. J.* **2017**, *11*, 1–11. [CrossRef]
65. Caratta, P.R.; Mafort, T.; Pamplona, M.; Schau, B.; Estrella, R.R.; Ramos, R.C. Paraneoplastic Vesiculobullous Dermatomyositis With Synchronic Prostate And Tongue Tumors: Case Report. *Rev. Bras. Reumatol.* **2011**, *51*, 394–396, 407.
66. Wennekers, M.M.; Appelman, M.; Van Der Weele, W.F. Dermatomyositis Als Paraneoplastisch Syndroom. *Ned. Tijdschr. Geneeskd.* **2018**, *162*, D1916.
67. Zerdes, I.; Tolia, M.; Nikolaou, M.; Tsoukalas, N.; Velentza, L.; Hajiioannou, J.; Mitsis, M.; Kyrgias, G. How Can We Effectively Address the Paraneoplastic Dermatomyositis: Diagnosis, Risk Factors and Treatment Options. *J. Buon* **2017**, *22*, 1073–1080.
68. Young, A.L.; Bailey, E.E.; Colaço, S.M.; Engler, D.E.; Grossman, M.E. Anti-Laminin-332 Mucous Membrane Pemphigoid Associated with Recurrent Metastatic Prostate Carcinoma: Hypothesis for a Paraneoplastic Phenomenon. *Eur. J. Dermatol.* **2011**, *21*, 401–404. [CrossRef]
69. Momm, F.; Pflieger, D.; Lutterbach, J. Paraneoplastic Erythroderma in a Prostate Cancer Patient. *Strahlenther. Onkol.* **2002**, *178*, 393–395. [CrossRef]
70. Ghafouri, S.R.; Escriba-Omar, A.; Wahdatyar, I.; Whited, N.; Hakim, M.N.; Gaur, S.; Dihowm, F. Exfoliative Dermatitis as a Para-neoplastic Syndrome of Prostate Adenocarcinoma: A Rare Case Report with Literature Review. *Cancer Diagn. Progn.* **2021**, *1*, 289–295. [CrossRef]
71. Fournet, M.; Roblot, P.; Levillain, P.; Guillet, G.; Machet, L.; Misery, L. Étude Rétrospective d'une Série de Pemphigus Paranéoplasiques. *Ann. Dermatol. Venereol.* **2018**, *145*, 564–571. [CrossRef]
72. Hui, H.-Z.M.; Guo, H.-X.M.; Wang, Y.-J.M.; Shi, B.-J. Rare Case of Paraneoplastic Pemphigus Associated with Prostatic Cancer. *Am. J. Dermatopathol.* **2022**, *44*, 940–942. [CrossRef]
73. Mignogna, M.D.; Fortuna, G.; Leuci, S.; Adamo, D.; Ruoppo, E. Metastatic Prostate Cancer Presenting as Paraneoplastic Pemphigus: A Favourable Clinical Response to Combined Androgen Blockade and Conventional Immunosuppressive Therapy. *Br. J. Dermatol.* **2009**, *160*, 468–470. [CrossRef] [PubMed]
74. Tejani, N.; Cooper, A.; Rezo, A.; Pranavan, G.; Yip, D. Numb Chin Syndrome: A Case Series of a Clinical Syndrome Associated With Malignancy. *J. Med. Imaging Radiat. Oncol.* **2014**, *58*, 700–705. [CrossRef] [PubMed]
75. Weisshaar, E. Intractable Chronic Pruritus in a 67-year-old Man. *Acta Derm.-Venereol.* **2008**, *88*, 488–490. [CrossRef]
76. Kim, Y.H.; Park, J.M.; Kang, C.D.; Seo, S.O.; Lee, K.; Song, G. Prostate Cancer Presenting with Pruritus and Cholestasis. *Korean J. Gastroenterol.* **2021**, *78*, 59–64. [CrossRef]
77. Gibb, J.; Babawale, O.; Phan, Y.C.; Karim, O. Dermatological Manifestation of Metastatic Prostate Cancer. *BMJ Case Rep.* **2020**, *13*, e237115. [CrossRef]
78. Votquenne, N.; Richert, B. Erythema Gyratum Repens. *JAMA Dermatol.* **2020**, *156*, 912. [CrossRef] [PubMed]
79. González-López, M.A.; López-Escobar, M.; Fernández-Llaca, H.; González-Vela, M.C.; López-Brea, M. Eosinophilic Annular Erythema in a Patient with Metastatic Prostate Adenocarcinoma. *Int. J. Dermatol.* **2015**, *54*, e80–e82. [CrossRef]
80. Nadal, R.; McMahan, Z.H.; Antonarakis, E.S. Paraneoplastic Palmar Fasciitis and Polyarthritis Syndrome in a Patient with Advanced Prostate Cancer. *Clin. Genitourin. Cancer* **2013**, *11*, e15–e23. [CrossRef]
81. Paolini, M.; Jankilevich, G.; Graziano, C.; Romero, D.F. Fulminant Digital Necrosis in a Patient with Prostate Adenocarcinoma. *Allergol. Immunopathol.* **2010**, *38*, 48–50. [CrossRef]
82. Jensen, J.D.; Madsen, J.K.; Jensen, L.W. Comparison of Dose Requirement, Serum Erythropoietin and Blood Pressure Following Intravenous and Subcutaneous Erythropoietin Treatment of Dialysis Patients: IV and SC Erythropoietin. *Eur. J. Clin. Pharmacol.* **1996**, *50*, 171–177. [CrossRef]
83. Tammaro, A.; Giulianelli, V.; Parisella, F.; Persechino, S. Bilaterally Mammary Acanthosis Nigricans as Paraneoplastic Manifestation of Prostate Adenocarcinoma. *G. Ital. Dermatol. Venereol.* **2016**, *151*, 578–579. [PubMed]
84. Khan, M.S.; Khan, M.; Aivaz, O. Transient Acantholytic Dermatosis in a Patient with Prostate Cancer. *Dermatol. Online J.* **2020**, *26*, 6. [CrossRef]

85. Fekete, G.L.; Boda, D.; Căruntu, C.; Fekete, L. Paraneoplastic Pityriasis Rubra Pilaris in Association with Prostate Carcinoma: A Case Report and Literature Review. *Exp. Ther. Med.* **2019**, *18*, 5052–5055. [CrossRef]
86. Liu, R.B.; Leavens, J.; Smart, C. Case of Cutaneous Metastatic Prostate Carcinoma as Initial Evidence of Neuroendocrine Differentiation. *Am. J. Dermatopathol.* **2021**, *43*, 819–821. [CrossRef] [PubMed]
87. Ballard, L.; Gowan, L.; Boyd, K.; Kyle, J.A. An Overview of Prostate Cancer. *U.S. Pharm.* **2023**, *48*, 40–45.
88. Cury-Martins, J.; Eris, A.P.M.; Abdalla, C.M.Z.; Silva, G.d.B.; de Moura, V.P.T.; Sanches, J.A. Management of Dermatologic Adverse Events from Cancer Therapies: Recommendations of an Expert Panel. *An. Bras. Dermatol.* **2020**, *95*, 221–237. [CrossRef] [PubMed]
89. Bonomo, P.; Wolf, J.R. Shedding Light on the Management of Acute Radiation Dermatitis: Insight from the MASCC Oncodermatology Study Group. *Support. Care Cancer* **2023**, *31*, 568. [CrossRef]
90. Pan, A.; Reingold, R.E.; Zhao, J.L.; Moy, A.; Kraehenbuehl, L.; Dranitsaris, G.; McBride, S.M.; Scher, H.I.; Kollmeier, M.A.; Xiao, H.; et al. Dermatological Adverse Events in Prostate Cancer Patients Treated with the Androgen Receptor Inhibitor Apalutamide. *J. Urol.* **2022**, *207*, 1010–1019. [CrossRef]
91. Osawa, K.; Kiniwa, Y.; Shimosato, Y.; Midorikawa, H.; Shirai, T.; Sano, T.; Nakamura, K.; Okuyama, R. Toxic Epidermal Necrolysis Caused by Apalutamide: A Case Report of Treatment Using Etanercept with Conventional Steroid Therapy. *Acta Derm.-Venereol.* **2022**, *102*, adv00723. [CrossRef]
92. Siegel, R.L.; Miller, K.D.; Fuchs, H.E.; Jemal, A. Cancer statistics. *CA Cancer J. Clin.* **2022**, *72*, 7–33. [CrossRef]
93. Honda, T.; Tohi, Y.; Kaku, Y.; Kimura, N.; Kato, T.; Haba, R.; Dainichi, T.; Sugimoto, M. Acute Generalized Exanthematous Pustulosis During Apalutamide Treatment in a Patient with Prostate Cancer. *IJU Case Rep.* **2022**, *5*, 497–500. [CrossRef] [PubMed]
94. Katsuta, M.; Nobeyama, Y.; Hirafuku, K.; Tashiro, K.; Kimura, T.; Asahina, A. Characteristics of Mild and Severe Apalutamide-Related Cutaneous Adverse Events in Patients with Prostate Cancer: A Review of the Literature. *J. Dermatol.* **2024**, *51*, 110–114. [CrossRef] [PubMed]
95. Sekine, M.; Terui, H.; Fujimura, T.; Asano, Y. Olaparib-Induced Purpuric Drug Eruption in a Patient with Castration-Resistant Prostate Cancer. *Case Rep. Oncol.* **2023**, *16*, 434–436. [CrossRef] [PubMed]
96. Bourlon, M.T.; Valdez, P.; Castro, E. Development of PARP Inhibitors in Advanced Prostate Cancer. *Ther. Adv. Med. Oncol.* **2024**, *16*, 1–15. [CrossRef]

Disclaimer/Publisher's Note: The statements, opinions and data contained in all publications are solely those of the individual author(s) and contributor(s) and not of MDPI and/or the editor(s). MDPI and/or the editor(s) disclaim responsibility for any injury to people or property resulting from any ideas, methods, instructions or products referred to in the content.