

Article

Cone-Beam Computed Tomography Analysis of the Root Canal Morphology of Lower Second Molars in the Croatian Subpopulation

Sarah Mimica ¹, Paris Simeon ², Ivana Miletić ² , Anja Baraba ² and Silvana Jukić Krmek ^{2,*} ¹ School of Dental Medicine, University of Zagreb, 10000 Zagreb, Croatia; skolak@sfzg.unizg.hr² Department of Endodontics and Restorative Dentistry, School of Dental Medicine, University of Zagreb, 10000 Zagreb, Croatia; simeon@sfzg.hr (P.S.); miletc@sfzg.hr (I.M.); baraba@sfzg.hr (A.B.)

* Correspondence: jukic@sfzg.hr

Abstract: The aim of this study was to investigate the root canal morphology of lower second molars in the Croatian subpopulation of the Zagreb region using cone-beam computed tomography (CBCT). We analyzed 3212 CBCT scans from the two radiology centers in Zagreb. The number of roots and root canals, the occurrence of C-shaped canals and additional roots were recorded. “C”-shaped roots were classified according to Melton classification. Canals in the mesial root were classified according to Vertucci. Lower second molars were found on 608 CBCT scans from a total number of 859. Among them, 78 (9.1%) had a “C”-shaped form. In the mesial roots, the frequencies of Vertucci types were: Type I in ninety-four cases (12.0%), Type II in three hundred and twenty cases (41.0%), Type III in six cases (0.8%), Type IV in three hundred and fifty-two cases (45.1%), Type V in three cases (0.4%), Type VI was found in four cases (0.5%) and Type VIII was found in one case (0.1%). Radix entomolaris and paramolaris were found in 29 (3.4%) lower second molars. The lower second molars in the Zagreb population show significant diversity in internal anatomy with a relatively high prevalence of “C”-shaped root canals and merged root canals in the mesial root.

Keywords: cone-beam computed tomography; molar; endodontics; dental pulp cavity; tooth roots



Citation: Mimica, S.; Simeon, P.; Miletić, I.; Baraba, A.; Jukić Krmek, S. Cone-Beam Computed Tomography Analysis of the Root Canal Morphology of Lower Second Molars in the Croatian Subpopulation. *Appl. Sci.* **2024**, *14*, 871. <https://doi.org/10.3390/app14020871>

Academic Editors: Paola Gandini and Andrea Scribante

Received: 5 December 2023

Revised: 16 January 2024

Accepted: 18 January 2024

Published: 19 January 2024



Copyright: © 2024 by the authors. Licensee MDPI, Basel, Switzerland. This article is an open access article distributed under the terms and conditions of the Creative Commons Attribution (CC BY) license (<https://creativecommons.org/licenses/by/4.0/>).

1. Introduction

Endodontic treatment is one of the most challenging procedures in dentistry, and knowledge of the common anatomy of the endodontic space and its variations is critical to the success of endodontic treatment [1]. According to the American Association of Endodontists, the difficulty of endodontic treatment depends on anatomical variations in the tooth and its position in the jaw, among other factors [2].

The morphology of the tooth is formed during the late bell stage, and root development represents the interaction between the dental sac, dental papilla and Hertwig’s sheath, where, after complex and unique interactions, the full length of the root is achieved with an appropriate system of root canals [3]. During tooth formation, deviations from the usual morphology, and numerous anatomical variations can occur in each tooth type, including the number and shape of roots and root canals [4].

The lower second molar, although it usually has two roots, the mesial, which usually has two canals, and the distal, which usually has one canal, is often subject to anatomic variations. One of the most common anatomical variations affecting the roots and canals of lower second molars is the occurrence of a “C”-shaped canal [5,6]. In addition to mandibular molars, it can also be found in maxillary molars [7,8].

The “C”-shaped root is thought to be caused by a defect in the fusion of the Hertwig’s sheath or by the deposition of cementum over time [9]. A “C”-shaped root always contains a “C”-shaped canal due to the fusion of either the buccal or lingual aspect of the mesial and distal roots while the two roots stay connected by an interradicular ribbon [10].

The peculiarity of this anatomical anomaly is that the pulp chamber is positioned below the cemento-enamel junction. Although it is named a canal, it is rare to find a classic cylindrical or conical space containing pulp tissue. “C”-shaped canal actually refers either to an irregular space resembling the letter “C”, or to multiple canals connected by a network of accessory canals [10]. Furthermore, “C”-shaped root canals have thin lingual walls, which presents a further challenge for root canal instrumentation [11]. According to Fan et al. [12], for a lower second molar to be diagnosed with having a “C”-shaped root canal it must exhibit three main characteristics: fused roots, a longitudinal groove on the lingual or buccal surface of the root and at least one cross section of the root canal having the continuous C or semicolon shape.

Clinically, a “C”-shaped root canal can be recognized according to the appearance of the floor of the pulp chamber and a large pulp chamber with low bifurcation. One of the first clinical indications of this anatomical variation may be localized periodontal disease due to narrow grooves on the root surface [13].

Among other morphological anomalies and variations in the lower molars, the presence of an additional root is also possible. An additional root on the lingual side is radix entomolaris while radix paramolaris is an additional root located buccally [6].

Before root canal treatment, in the majority of cases, a preoperative radiograph is available, and it can provide certain clues regarding root canal morphology. However, it is debatable if X-rays are helpful in diagnosing a “C”-shaped root canal. According to some data from the literature, a few radiographic characteristics can help predict “C”-shaped root canals: radicular fusion, radicular proximity, a large distal canal or a blurred image of a third canal in between [14,15]. In the case of a lower second molar, signs of a “C”-shaped canal on X-ray include the appearance of a single root or as two roots with communication or a large and deep pulp chamber which is usually present in “C”-shaped roots [13]. However, despite certain clues which might be present on orthopantomograms or periapical X-ray images, which are mainly used in daily clinical practice, radiographs are two-dimensional and it is often difficult to detect the presence of anatomical anomalies such as the “C”-shaped canal, radix entomolaris or paramolaris, or to determine the shape of multiple root canals and their possible merging into one canal. Therefore, cone-beam computed tomography (CBCT), which provides a three-dimensional analysis, is now widely used for diagnosis and in epidemiology as it is considered a suitable method to study the aforementioned anatomical variations in root canals, especially in epidemiologic studies [16–19]. It is a non-invasive method that allows the observation and analysis of teeth in all three planes, coronal, sagittal and transversal [20]. CBCT analysis is indicated and can offer insight into root canal morphology in cases with unusual findings on intraoral radiographs and should only be used when examining the anatomy of endodontic space or diagnosis is not possible using lower-dose conventional dental radiographs. Furthermore, CBCT scans can be helpful for treatment planning in teeth with a challenging root canal morphology such as a “C”-shaped root canal, as 3D images can help identify number, shape, location, and size of the canals and detect potentially dangerous zones which present a risk for stripping perforation.

In the Croatian population, no radiological analysis of the lower second molars, including the frequency of the “C”-shaped canal, the occurrence of additional roots and the morphology of root canals in mesial roots, has been conducted. Šutalo et al. [21] investigated “C”-shaped canals in lower second molars by only analyzing the cross-sections of the extracted teeth. Therefore, the aim of this study was to investigate the morphological variations in the endodontic space of lower second molars using CBCT scans of a Croatian subpopulation in the city of Zagreb.

2. Materials and Methods

The research was approved by the Ethics Committee of the School of Dental Medicine, University of Zagreb (05-PA-30-IX-6/2022).

The databases of two private dental radiology centers were used, and the images were taken during the period from April 2019 to October 2022 for diagnostic reasons unrelated to the present research. The device used for imaging was the Cranex 3D CBCT system (Soredex, Tusuula, Finland), the observed field size was 5×10 FOV. The voxel size was 0.2 mm with exposure time duration of 3 s. The recordings were analyzed using OnDemand 3D Dental software (<https://www.ondemand3d.com/en/>; Cybermed, Seoul, Korea). During the analysis, the contrast and brightness of the images were adjusted using tools in the program to ensure optimal visualization.

In total, 3212 CBCT scans were reviewed and 1784 were scans of the lower jaw. Criteria for inclusion in the study were lower second molars with completed growth and root development that were not endodontically treated and were without the presence of external and internal root resorption. A total of 608 recordings met the stated criteria and 859 lower second molars were analyzed. Age and gender of the subjects, number and morphology of root canals in the mesial and distal roots and the presence of radix entomolaris and paramolaris were recorded. The “C”-shaped root canals were classified according to Melton’s classification [22] by observing the cross-sections of teeth at three levels of the root (Figure 1). Canals in the mesial root were classified according to Vertucci [23]. Teeth with a “C”-shaped canal shape were not assigned a Vertucci type.

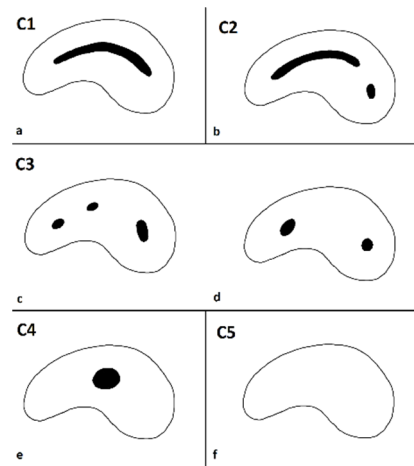


Figure 1. Melton’s classification: (a) CATEGORY I (C1): continuous “C” shaped canal running from the canal orifice to the apex; (b) CATEGORY II (C2): the shape of the canal resembles a semicolon (;), which is the result of “C”-shaped canal separated from another distinct canal; (c,d) CATEGORY III (C3): two or three separate canals; (e) CATEGORY IV (C4): one round or oval canal; (f) CATEGORY V (C5): the canal lumen is not visible and cannot be observed.

Two evaluators assessed the CBCT scans after initial instruction and calibration. Forty, randomly chosen, CBCT scans of lower second molars were used for inter- and intra-observer reliability, with a two-week interval between repeated evaluations. Cohen’s kappa test for “C”-shaped anatomy and intraclass correlation coefficient (ICC) for root and canal number were calculated. High levels of inter-observer agreement were shown with Kappa test (0.89) and ICC (0.91), as well as for intra-observer reliability for both evaluators with Kappa test (0.92 and 0.90) and ICC (0.95 and 0.93).

The results were statistically analyzed using the Chi-square test with a level of significance set at $p < 0.05$ and a 95% confidence interval (CI), determined using the computer program SPSS 21.0 for Windows (SPSS Inc, Chicago, IL, USA).

3. Results

608 CBCT images were included in the study and 859 lower second molars were analyzed; 423 (49.2%) belonging to the third quadrant and 436 (50.8%) to the fourth quadrant. Data were collected from 608 subjects, with 251 (41.2%) subjects having lower second

molars present on both sides; while in 357 subjects, a lower second molar was present unilaterally.

The analyzed sample of 859 teeth included 282 males and 577 females with an average age of 30 years. Given that in the Croatian population mandibular molars are the most frequently extracted or endodontically treated teeth, which excludes them from this research, the majority of the subjects whose scans could be used for the purpose of this study were scans of subjects between the ages of 18 and 35.

A “C”-shaped canal was present in 78 subjects (9.1%, with a confidence interval of CI 7.2–11.0%). The canal was divided into three thirds: coronal, middle and apical, and each third was classified according to Melton’s classification (Figures 2 and 3). The results of the frequency of different types of “C”-shaped canals in all three thirds of root canals are shown in Table 1.

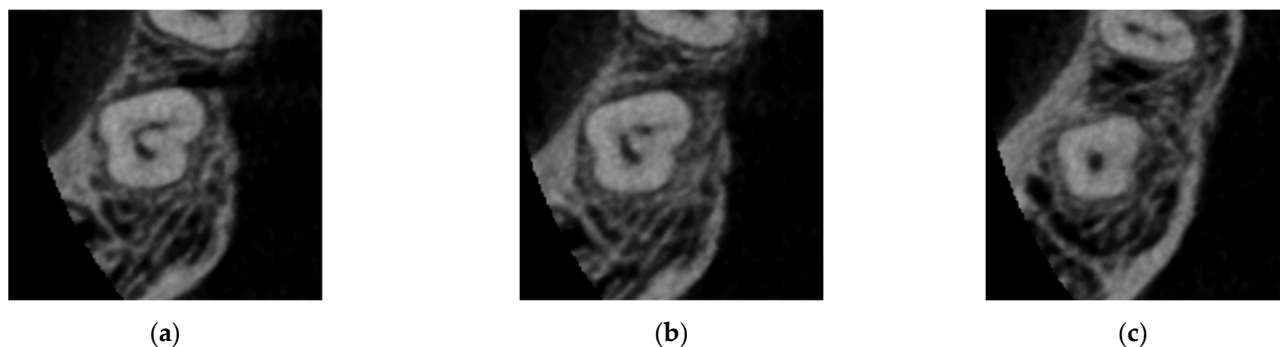


Figure 2. Horizontal cross section of coronal (a), middle (b) and apical third (c) of “C”-shaped canal in lower second molar showing different categories according to Melton’s classification (C1, C2, C4, respectively).

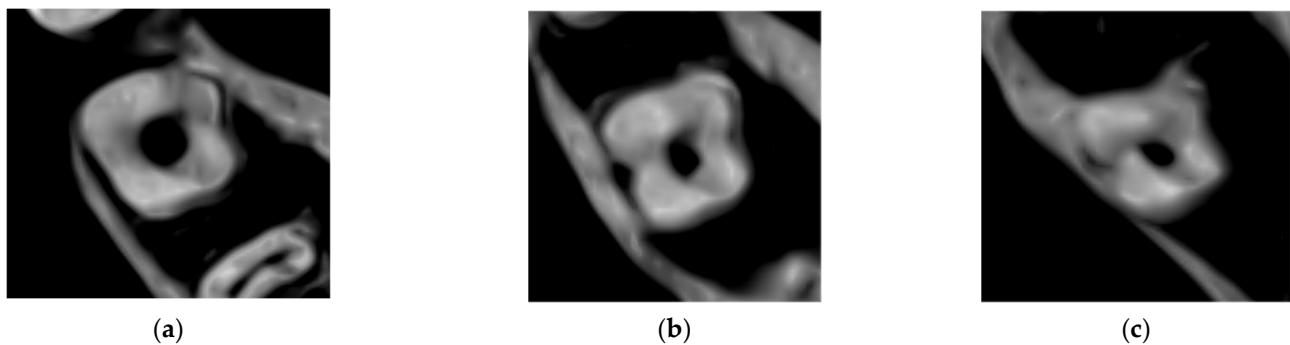


Figure 3. Horizontal cross section of coronal (a), middle (b) and apical third (c) of the same category of “C”-shaped canal in lower second molar (C4).

Table 1. Frequency of different Melton’s types of “C”-shaped canals in lower second molars in all three cross sections.

Root Canal Cross-Section	Root Canal Type According Melton’s Classification				
	C1	C2	C3c	C3d	C4
Coronal third	14.1%	24.4%	35.9%	15.4%	10.3%
Middle third	6.4%	21.8%	44.9%	19.2%	7.7%
Apical third	10.3%	14.1%	33.3%	26.9%	15.4%

In the mesial root, two canals were the most frequently present, in six hundred and eighty-nine cases (88.2%, CI 86.0–90.5%), in ninety-one roots, one root canal was found (11.7%, CI 9.4–13.9%), while three canals were found in only one root (0.1%, CI 0.1–0.4%). In

the distal root, one root canal was most frequently present, in 758 teeth (97%, CI 95.9–98.2%), and two canals were found in 23 teeth (3.0%, CI 1.8–4.1%). No statistically significant differences were found in the number of mesial root canals in teeth on the left side of mandible when compared to the teeth on the right side (Chi Square test, $p = 0.592$).

Regarding the Vertucci classification of the canals in the mesial roots, the most frequently observed types of root canals were: Type IV in 352 cases (45.1%, CI 41.6–48.6%), Type II in 320 cases (41.0%, CI 37.5–44.4%) and Type I in 94 cases (12.0%, CI 7.8–14.3%) (Table 2).

Table 2. Frequency of Vertucci types in mesial roots of lower second molars.

Vertucci Type	Type I	Type II	Type III	Type IV	Type V	Type VI	Type VII	Type VIII
Frequency	12.0%	41.0%	0.8%	45.1%	0.4%	0.5%	0%	0.1%

4. Discussion

The root canal morphology of mandibular second molars is of special interest due to the high incidence of distal caries lesions reported for second molars [24,25] which might progress over time and end up with dental pulp involvement and endodontic treatment. The potential problem is that mandibular second molars are known for the large number of possible root canal morphology variations and detailed knowledge of all possible variations is needed for successful endodontic treatment. The higher incidence of anomalies in the second lower molar in comparison to the first one could be explained by evolutionary and environmental theories. According to Butler–Dahlberg’s evolutionary Field theory, the jaws are divided in four morphogenetic fields (incisors, canines, premolars and molars) and the more distal tooth is in this field, the less genetically stable it is considered, except for the lower incisors group. Other theories are based on environmental conditions affecting dental lamina during specific areas of tooth development, such as the fusion of the bones for the upper lateral incisors or during the development of the tooth’s innervation [26].

Root and root canal morphology of different types of teeth has been analyzed in different populations, such as the Indian, Chinese, Korean, Israeli, Brazilian and Saudi Arabian populations, and the results obtained indicate that certain variations in root and root canal morphology are genetically determined [17–20,27–29]. Furthermore, these observations can be used for various epidemiological studies or the study of the ethnic origin of an individual. CBCT analysis has proven to be a useful method in these studies because it is non-invasive, provides a three-dimensional view of anatomical structures and is increasingly being used for the diagnosis of various conditions in the oral cavity [30]. Therefore, it is not surprising that numerous studies investigating anatomical variations in different types of teeth using CBCT scans have been published [31], but there is still no data for the Croatian population.

In this study, an analysis of the morphology of endodontic space of the lower second molars in the population of the Zagreb area using CBCT showed that “C”-shaped root canals were found in 9.1% of cases. This is not in agreement with a study by Šutalo et al. [21] which was conducted on extracted teeth, and “C”-shaped canals were found in 12.5% of lower second molars. A possible explanation for the different results might be the different methodologies, i.e., there is a greater possibility that, among the extracted teeth, more teeth will have certain anatomical variations, because dentists will be more inclined to extract such teeth in contrast to teeth with normal morphology that will receive the treatment needed and thus be preserved.

Interestingly, large variations can be found in the occurrence of “C”-shaped root canals in different countries. Countries where, as in Croatia, the frequency of “C”-shaped canals is up to 10% are Serbia (5.53%), Israel (4.6%), Brazil (3.5%), the Middle East (7.9%) and Pakistan (10%), while the frequency is high in Jordan (12%), Egypt (12.8%) India (13.1%), Venezuela (19.5%) and Iran (21.4%) and an extremely high frequency is found in Asian

populations, where studies show results between 36.8% and 41.3% [5,6,17,19,20,27,32–42]. Moreover, studies have reported the influence of ethnicity and race on the root canal morphology of mandibular second molars [7,31] which highlights the importance of studies of root canal morphology in different populations. Before endodontic treatment, clinicians should consider general patient data such as ethnicity or age to increase the chances of successful treatment. Data about root canal morphology and variations obtained from studies in different populations, such as the present study, are necessary because it can help clinicians to plan and modify endodontic treatment accordingly but also to avoid procedural mistakes. Furthermore, it is necessary to be aware of differences in root canal anatomy along its length, from the coronal to the apical part, given that the results of this study indicate a different frequency of a certain categories of “C”-shaped canal in different cross sections of the root. Bilateral occurrence of “C”-shaped canals was found in 41.2% of patients in the present study, in contrast to significantly lower occurrence in the Korean and Chinese populations [19,34]. These data can direct the clinician if the anomaly is found to be uni- or bilateral. Data obtained by these types of studies may also help to avoid unnecessary CBCTs, following the principle of “as low as reasonably achievable” (ALARA), due to high doses of radiation [43].

Differences in the availability of dental care, preventive and therapeutic procedures within a given population may also influence the results of epidemiological studies. “C”-shaped canals and extra roots were found more frequently in the younger population. This can be explained by the fact that the diagnosis and treatment of such teeth is extremely difficult and challenging. The frequency of extracted teeth having a “C”-shaped canal or an additional root increases with age, which decreases their frequency in the older population, and this is inversely proportional to the quality of preventive dental care and the preservation of the dentition of a given population.

Although some studies used periapical X-rays and orthopantomograms [28,44,45], standard radiographs provide only limited information and CBCT is an appropriate three-dimensional technique that can more precisely detect certain morphological variations. Therefore, many recent epidemiological studies on anatomical variations in the endodontic space are carried out using CBCT analysis, and due to ethical reasons, i.e., avoiding unnecessary exposure to relatively high doses of ionizing radiation, the studies usually include those patients for whom CBCT is indicated for various diagnostic or therapeutic reasons. The selection of such participants carries the risk of potential differences in comparison to the general population, and the risk is lower if the number of dental patients included is as high as possible. In total, 608 patients were included in the current study, the same as in the study of the Chinese population [38], which is a relatively high number of subjects in comparison to some other studies [32,33].

The occurrence of additional roots (radix entomolaris and paramolaris) on lower second molars has not been investigated in the Croatian population so far. Although this study showed that the occurrence of this anomaly in these teeth is low (3.4%), there should be awareness of the possibility of additional roots during endodontic treatment as one of the common reasons for endodontic failure are missed root canals, especially if additional roots and canals are present, which is more common for premolar or molar teeth [46]. One of the reasons for overlooking that supernumerary root is common superimposition with distal root in bucco-lingual direction which makes diagnosis difficult on 2D radiographs. An additional root on the lower molars is more common in the Mongolian race, where it is found in up to 30% of molars [47], and it is considered a normal anatomical variation for this group of ethnicities in contrast to Caucasians where this is rare condition, reported in only 3.4% to 4.2% of patients, and it is considered an anatomical aberration [48].

The root canal system is complex with root canals apically splitting and uniting during its course. Root canal classification may be useful during diagnostic procedure and treatment planning. Over time, different root canal classifications, including their modifications, were proposed. Vertucci’s classification is well known because of its simplicity and the fact that it is used by numerous authors [4,49]. Despite its many advantages, it has certain limi-

tations. Given that it represents eight types of root canals, it excludes and does not describe certain anomalies and certain morphologic forms that do not correspond to any of the described types. It also excludes the description of communications between the canals and does not describe the number of roots in the anterior teeth and premolars [4]. Nevertheless, Vertucci's classification was used in this study. Our results show that the Vertucci types IV (45.1%) and II (41.0%) are the most common in the subpopulation of Zagreb, which is consistent with the results of a study on the population of Saudi Arabia [29], while another study on the population of the Emirates found that, among the mesial roots of second lower molars, Type II and Type III are most commonly found [50]. The differences in the reported prevalence of specific anatomical variations in some studies could be explained by variations in the methods used in different studies. In the study of Neelakantan et al. [51] on the Indian population of Mumbai, in which the staining and clearing method was used, type IV was most frequently (63.1%) observed on lower second molars with two roots, while Pawar et al. [17] reported a lower percentage of type IV (45.2%) in the same population using the CBCT analysis.

The "C"-shaped canal and certain other types according to Vertucci (Type III, Type V, Type VI, Type VII) represent a complex and irregular space with a high potential for retaining infected soft tissue and debris after traditional root canal instrumentation. Therefore, once one of these canal forms is detected, special attention and time should be invested in planning and performing endodontic treatment. Knowledge and data from the studies of the root canal morphology, like the present study, might be helpful in recognizing this specific morphological variation [7]. Mechanical debridement of the root canal space of "C"-shaped root canals is difficult due to transverse anastomoses, lateral canals and apical deltas [38]. Special attention should be given to thin lingual dentine walls in curved canal due to increased risk of a stripping perforation [12,52–54]. According to Lim and Stock [55], a minimum of dentine thickness of 0.2–0.3 mm is needed to resist fracture due to pressure during a root canal filling procedure which highlights the importance of careful and non-invasive root canal preparation with smaller size files, especially in the coronal third of root canal. The most common causes of failure in cases with "C"-shaped root canals are leakage of canals, isthmus, missing canal, overinstrumentation and iatrogenic mistakes [56]. It is also particularly important for the clinician to recognize the root canal fusion (Types II and III), which, according to this research, is quite common (41.8%) in the lower second molars, to avoid breaking the instrument in an attempt to treat both canals separately while reaching the full working length.

The limitations of this study are that the ethnicity of the patients was not recorded because this information was not available to collect and analyze, and that only scans of the subpopulation of the city of Zagreb were included in the study.

5. Conclusions

The lower second molars of the Croatian subpopulation of the city of Zagreb show considerable diversity in internal anatomy, with a relatively high prevalence of "C"-shaped root canals and fused root canals in the mesial root. This finding demonstrates the need for a thorough analysis of root canal morphology prior to endodontic treatment. Understanding the etiology, variations, or challenges regarding root canal treatment of "C"-shaped root canals is imperative for correct diagnosis, proper chemomechanical debridement, obturation and successful endodontic treatment of teeth with this anatomic variation. The results of the present study can be used in everyday clinical practice to enhance the quality and success of root canal treatment.

Author Contributions: Conceptualization, S.J.K.; methodology, S.M.; software, I.M.; validation, I.M.; formal analysis, S.M. and P.S.; investigation, S.J.K.; resources, S.J.K.; data curation, S.M.; writing—original draft preparation, A.B.; writing—review and editing, S.M.; visualization, I.M.; supervision, S.J.K.; project administration, P.S. All authors have read and agreed to the published version of the manuscript.

Funding: This research received no external funding.

Institutional Review Board Statement: The study was conducted in accordance with the Declaration of Helsinki and approved by the Ethics Committee the School of Dental Medicine, University of Zagreb (05-PA-30-IX-6/2022) for studies involving humans.

Informed Consent Statement: Informed consent was obtained from all subjects involved in the study.

Data Availability Statement: The data presented in this study are available on request from the corresponding author. The data are not publicly available due to general data protection regulation in Croatia.

Conflicts of Interest: The authors declare no conflicts of interest.

References

- Ng, Y.L.; Mann, V.; Rahbaran, S.; Lewsey, J.; Gulabivala, K. Outcome of primary root canal treatment: Systematic review of the literature—Part 2. Influence of clinical factors. *Int. Endod. J.* **2008**, *41*, 6–31. [CrossRef] [PubMed]
- American Endodontic Association (AEA). Endodontic Case Difficulty Assessment and Referral. Endodontics: Colleagues for Excellence, Spring/Summer 2005. Available online: <https://www.aae.org/specialty/wp-content/uploads/sites/2/2017/07/ss05ecfe.pdf> (accessed on 12 October 2023).
- Zeichner-David, M.; Oishi, K.; Su, Z.; Zakartchenko, V.; Chen, L.S.; Arzate, H.; Bringas, P., Jr. Role of Hertwig's epithelial root sheath cells in tooth root development. *Dev. Dyn.* **2003**, *28*, 651–663. [CrossRef] [PubMed]
- Ahmed, H.M.A.; Versiani, M.A.; De-Deus, G.; Dummer, P.M.H. A new system for classifying root and root canal morphology. *Int. Endod. J.* **2017**, *50*, 761–770. [CrossRef] [PubMed]
- Shemesh, A.; Levin, A.; Katzenell, V.; Itzhak, J.B.; Levinson, O.; Avraham, Z.; Solomonov, M. C-shaped canals-prevalence and root canal configuration by cone beam computed tomography evaluation in first and second mandibular molars—a cross-sectional study. *Clin. Oral Investig.* **2017**, *21*, 2039–2044. [CrossRef] [PubMed]
- Kim, S.Y.; Kim, B.S.; Kim, Y. Mandibular second molar root canal morphology and variants in a Korean subpopulation. *Int. Endod. J.* **2016**, *49*, 136–144. [CrossRef] [PubMed]
- Martins, J.N.R.; Marques, D.; Silva, E.J.N.L.; Caramês, J.; Mata, A.; Versiani, M.A. Prevalence of C-shaped canal morphology using cone beam computed tomography—A systematic review with meta-analysis. *Int. Endod. J.* **2019**, *52*, 1556–1572. [CrossRef] [PubMed]
- Martins, J.N.; Mata, A.; Marques, D.; Caramês, J. Prevalence of Root Fusions and Main Root Canal Merging in Human Upper and Lower Molars: A Cone-beam Computed Tomography In Vivo Study. *J. Endod.* **2016**, *42*, 900–908. [CrossRef] [PubMed]
- Raisingani, D.; Gupta, S.; Mital, P.; Khullar, P. Anatomic and diagnostic challenges of C-shaped root canal system. *Int. J. Clin. Pediatr. Dent.* **2014**, *7*, 5–9.
- Jafarzadeh, H.; Wu, Y.N. The C-shaped root canal configuration: A review. *J. Endod.* **2007**, *33*, 517–523. [CrossRef]
- Fernandes, M.; de Ataíde, I.; Wagle, R. C-shaped root canal configuration: A review of literature. *J. Conserv. Dent.* **2014**, *17*, 312–319. [CrossRef]
- Fan, B.; Cheung, G.-S.; Fan, M.; Gutmann, J.L.; Bian, Z. C-shaped canal system in mandibular second molars: Part I—Anatomical features. *J. Endod.* **2004**, *30*, 899–903. [CrossRef] [PubMed]
- Gulabivala, K.; Opananon, A.; Ng, Y.L.; Alavi, A. Root and canal morphology of Thai mandibular molars. *Int. Endod. J.* **2002**, *35*, 56–62. [CrossRef] [PubMed]
- Haddad, G.Y.; Nehme, W.B.; Ounsí, H.F. Diagnosis, classification, and frequency of C-shaped canals in mandibular second molars in the Lebanese population. *J. Endod.* **1999**, *25*, 268–271. [CrossRef] [PubMed]
- Al-Fouzan, K.S. C-shaped root canals in mandibular second molars in a Saudi Arabian population. *Int. Endod. J.* **2002**, *35*, 499–504. [CrossRef] [PubMed]
- Mashyakh, M.; Gambarini, G. Root and Root Canal Morphology Differences Between Genders: A Comprehensive in-vivo CBCT Study in a Saudi Population. *Acta Stomatol. Croat.* **2019**, *53*, 231–246. [CrossRef] [PubMed]
- Pawar, A.M.; Pawar, M.; Kfir, A.; Singh, S.; Salve, P.; Thakur, B.; Neelakantan, P. Root canal morphology and variations in mandibular second molar teeth of an Indian population: An in vivo cone-beam computed tomography analysis. *Clin. Oral Investig.* **2017**, *21*, 2801–2809. [CrossRef] [PubMed]
- Xia, Y.; Qiao, X.; Huang, Y.J.; Li, Y.H.; Zhou, Z. Root Anatomy and Root Canal Morphology of Maxillary Second Permanent Molars in a Chongqing Population: A Cone-Beam Computed Tomography Study. *Med. Sci. Monit.* **2020**, *26*, e922794. [CrossRef]
- Yang, S.E.; Lee, T.Y.; Kim, K.J. Prevalence and Morphology of C-Shaped Canals: A CBCT Analysis in a Korean Population. *Scanning* **2021**, *2021*, 9152004. [CrossRef]
- Shemesh, A.; Levin, A.; Katzenell, V.; Itzhak, J.B.; Levinson, O.; Zini, A.; Solomonov, M. Prevalence of 3- and 4-rooted first and second mandibular molars in the Israeli population. *J. Endod.* **2015**, *41*, 338–342. [CrossRef]
- Šutalo, J.; Simeon, P.; Tarle, Z.; Prskalo, K.; Pevalek, J.; Staničić, T.; Udovčić, M. C-shaped canal configuration of mandibular second permanent molar. *Coll. Antropol.* **1998**, *22*, 179–186.

22. Melton, D.C.; Krell, K.V.; Fuller, M.W. Anatomical and histological features of C-shaped canals in mandibular second molars. *J. Endod.* **1991**, *17*, 384–388. [\[CrossRef\]](#) [\[PubMed\]](#)
23. Vertucci, F.; Seelig, A.; Gillis, R. Root canal morphology of the human maxillary second premolar. *Oral Surg. Oral Med. Oral Pathol. Oral Radiol.* **1974**, *38*, 456–464. [\[CrossRef\]](#) [\[PubMed\]](#)
24. Van der Linden, W.; Cleaton-Jones, P.; Lownie, M. Diseases and lesions associated with third molars. Review of 1001 cases. *Oral Surg. Oral Med. Oral Pathol. Oral Radiol.* **1995**, *79*, 142–145.
25. Altıparmak, N.; Oguz, Y.; Neto, R.S.; Bayram, B.; Aydin, U. Prevalence of distal caries in mandibular second molars adjacent to impacted third molars: A retrospective study using panoramic radiography. *J. Dent. Health Oral Disord. Ther.* **2017**, *8*, 641–645. [\[CrossRef\]](#)
26. Al-Ani, A.H.; Antoun, J.S.; Thomson, W.M.; Merriman, T.R.; Farella, M. Hypodontia: An Update on Its Etiology, Classification, and Clinical Management. *BioMed Res. Int.* **2017**, *2017*, 9378325. [\[CrossRef\]](#) [\[PubMed\]](#)
27. Ladeira, D.B.; Cruz, A.D.; Freitas, D.Q.; Almeida, S.M. Prevalence of C-shaped root canal in a Brazilian subpopulation: A cone-beam computed tomography analysis. *Braz. Oral. Res.* **2014**, *28*, 39–45. [\[CrossRef\]](#) [\[PubMed\]](#)
28. Wang, Y.; Guo, J.; Yang, H.B.; Han, X.; Yu, Y. Incidence of C-shaped root canal systems in mandibular second molars in the native Chinese population by analysis of clinical methods. *Int. J. Oral Sci.* **2012**, *4*, 161–165. [\[CrossRef\]](#)
29. Mashyakh, M.; AlTuwaijri, N.; Alessa, R.; Alazzam, N.; Alotaibi, B.; Almutairi, R.; Alroomy, R.; Thota, G.; Abu Melha, A.; Alkahtany, M.F.; et al. Anatomical Evaluation of Root and Root Canal Morphology of Permanent Mandibular Dentition among the Saudi Arabian Population: A Systematic Review. *BioMed Res. Int.* **2022**, *2022*, 2400314. [\[CrossRef\]](#)
30. Nasseh, I.; Al-Rawi, W. Cone Beam Computed Tomography. *Dent. Clin. N. Am.* **2018**, *62*, 361–391. [\[CrossRef\]](#)
31. Von Zuben, M.; Martins, J.N.R.; Berti, L.; Cassim, I.; Flynn, D.; Gonzalez, J.A.; Gu, Y.; Kottoor, J.; Monroe, A.; Aguilar, R.R. Worldwide prevalence of mandibular second molar C-shaped morphologies evaluated by cone-beam computed tomography. *J. Endod.* **2017**, *43*, 1442–1447. [\[CrossRef\]](#)
32. Martins, J.N.R.; Kishen, A.; Marques, D.; Nogueira Leal Silva, E.J.; Caramês, J.; Mata, A.; Versiani, M.A. Preferred Reporting Items for Epidemiologic Cross-sectional Studies on Root and Root Canal Anatomy Using Cone-beam Computed Tomographic Technology: A Systematized Assessment. *J. Endod.* **2020**, *46*, 915–935. [\[CrossRef\]](#) [\[PubMed\]](#)
33. Živanović, S.; Papić, M.; Radović, M.; Mišić, M.; Živić, M.; Popović, M. Prevalence of C-shaped mandibular second molar canals in the population of central Serbia: A cone-beam computed tomography study. *Vojnosanit. Pregl.* **2021**, *78*, 9–15. [\[CrossRef\]](#)
34. Gomez, F.; Brea, G.; Gomez-Sosa, J.F. Root canal morphology and variations in mandibular second molars: An in vivo cone-beam computed tomography analysis. *BMC Oral Health* **2021**, *21*, 424. [\[CrossRef\]](#) [\[PubMed\]](#)
35. Wadhvani, S.; Singh, M.P.; Agarwal, M.; Somasundaram, P.; Rawtiya, M.; Wadhvani, P.K. Prevalence of C-shaped canals in mandibular second and third molars in a central India population: A cone beam computed tomography analysis. *J. Conserv. Dent.* **2017**, *20*, 351–354. [\[CrossRef\]](#) [\[PubMed\]](#)
36. Silva, E.J.; Nejaim, Y.; Silva, A.V.; Haiter-Neto, F.; Cohenca, N. Evaluation of root canal configuration of mandibular molars in a Brazilian population by using cone-beam computed tomography: An in vivo study. *J. Endod.* **2013**, *39*, 849–852. [\[CrossRef\]](#) [\[PubMed\]](#)
37. Martins, J.N.R.; Gu, Y.; Marques, D.; Francisco, H.; Carames, J. Differences on the root and root canal morphologies between Asian and white ethnic groups analyzed by cone-beam computed tomography. *J. Endod.* **2018**, *44*, 1096–1104. [\[CrossRef\]](#) [\[PubMed\]](#)
38. Zheng, Q.; Zhang, L.; Zhou, X.; Wang, Q.; Wang, Y.; Tang, L.; Song, F.; Huang, D. C-shaped root canal system in mandibular second molars in a Chinese population evaluated by cone-beam computed tomography. *Int. Endod. J.* **2011**, *44*, 857–862. [\[CrossRef\]](#)
39. Janani, M.; Rahimi, S.; Jafari, F.; Johari, M.; Nikniaz, S.; Ghasemi, N. Anatomic Features of C-shaped Mandibular Second Molars in a Selected Iranian Population Using CBCT. *Iran. Endod. J.* **2018**, *13*, 120–125.
40. Al Omari, T.; AlKhader, M.; Ateş, A.A.; Wahjuningrum, D.A.; Dkmak, A.; Khaled, W.; Alzenate, H. A CBCT based cross sectional study on the prevalence and anatomical feature of C shaped molar among Jordanian. *Sci. Rep.* **2022**, *12*, 17137. [\[CrossRef\]](#)
41. Saber, S.M.; Seoud, M.A.E.; Sadat, S.M.A.E.; Nawer, N.N. Root and canal morphology of mandibular second molars in an Egyptian subpopulation: A cone-beam computed tomography study. *BMC Oral Health* **2023**, *23*, 217. [\[CrossRef\]](#)
42. Ulfat, H.; Ahmed, A.; Javed, M.Q.; Hanif, F. Mandibular second molars' C-shaped canal frequency in the Pakistani subpopulation: A retrospective cone-beam computed tomography clinical study. *Saudi Endod. J.* **2021**, *11*, 383–387.
43. Patel, S.; Brown, J.; Pimentel, T.; Kelly, R.D.; Abella, F.; Durack, C. Cone Beam Computed Tomography in Endodontics—A Review of the Literature. *Int. Endod. J.* **2019**, *52*, 1138–1152. [\[CrossRef\]](#)
44. Lambrianidis, T.; Lyroudia, K.; Pandelidou, O.; Nicolaou, A. Evaluation of periapical radiographs in the recognition of C-shaped mandibular second molars. *Int. Endod. J.* **2001**, *34*, 458–462. [\[CrossRef\]](#) [\[PubMed\]](#)
45. Jung, H.J.; Lee, S.S.; Huh, K.H.; Yi, W.J.; Heo, M.S.; Choi, S.C. Predicting the configuration of a C-shaped canal system from panoramic radiographs. *Oral Surg. Oral Med. Oral Pathol. Oral Radiol.* **2010**, *109*, e37–e41. [\[CrossRef\]](#) [\[PubMed\]](#)
46. Giuseppe, C.; Elio, B.; Arnaldo, C. Missed anatomy: Frequency and clinical impact. *Endod. Top.* **2009**, *15*, 3–31.
47. Ferraz, J.A.; Pécora, J.D. Three-rooted mandibular molars in patients of Mongolian, Caucasian and Negro origin. *Braz. Dent. J.* **1993**, *3*, 113–117. [\[PubMed\]](#)
48. Calberson, F.L.; De Moor, R.J.; Deroose, C.A. The radix entomolaris and paramolaris: Clinical approach in endodontics. *J. Endod.* **2007**, *33*, 58–63. [\[CrossRef\]](#)

49. Karobari, M.I.; Parveen, A.; Mirza, M.B.; Makandar, S.D.; Nik Abdul Ghani, N.R.; Noorani, T.Y.; Marya, A. Root and Root Canal Morphology Classification Systems. *Int. J. Dent.* **2021**, *2021*, 6682189. [[CrossRef](#)]
50. Khawaja, S.; Alharbi, N.; Chaudhry, J.; Khamis, A.H.; El Abed, R.; Ghoneima, A.; Jamal, M. The C-shaped root canal systems in mandibular second molars in an Emirati population. *Sci. Rep.* **2021**, *11*, 23863. [[CrossRef](#)]
51. Neelakantan, P.; Subbarao, C.; Subbarao, C.V.; Ravindranath, M. Root and canal morphology of mandibular second molars in an Indian population. *J. Endod.* **2010**, *36*, 1319–1322. [[CrossRef](#)]
52. Fan, B.; Cheung, G.S.; Fan, M.; Gutmann, J.L.; Fan, W. C-shaped canal system in mandibular second molars: Part II—Radiographic features. *J. Endod.* **2004**, *30*, 904–908. [[CrossRef](#)] [[PubMed](#)]
53. Jin, G.C.; Lee, S.J.; Rob, B.D. Anatomical study of C-shaped canals in mandibular second molars by analysis of computed tomography. *J. Endod.* **2006**, *32*, 10–13. [[CrossRef](#)] [[PubMed](#)]
54. Gao, Y.; Fan, B.; Cheung, G.S.; Gutmann, J.L.; Fan, M. C-shaped canal system in mandibular second molars part IV: 3-D morphological analysis and transverse measurement. *J. Endod.* **2006**, *32*, 1062–1065. [[CrossRef](#)] [[PubMed](#)]
55. Lim, S.S.; Stock, C.J.R. The risk of perforation in the curved canal: Anticurvature filing compared with the stepback technique. *Int. Endod. J.* **1987**, *20*, 33–39. [[CrossRef](#)]
56. Kim, Y.; Lee, D.; Kim, D.V.; Kim, S.Y. Analysis of cause of endodontic failure of C-shaped root canals. *Scanning* **2018**, *2018*, 2516832. [[CrossRef](#)]

Disclaimer/Publisher’s Note: The statements, opinions and data contained in all publications are solely those of the individual author(s) and contributor(s) and not of MDPI and/or the editor(s). MDPI and/or the editor(s) disclaim responsibility for any injury to people or property resulting from any ideas, methods, instructions or products referred to in the content.