applied sciences

MDPI

Systematic Review

Root Resorption during Orthodontic Treatment with Clear Aligners vs. Fixed Appliances—A Systematic Review

Francesco Inchingolo [1], Angelo Michele Inchingolo [1], Giulia Palmieri [1], Chiara Di Pede [1], Grazia Garofoli [1], Elisabetta de Ruvo [1], Alessio Danilo Inchingolo [1], Andrea Palermo [2], Antonio Mancini [1], Daniela Di Venere [1], Giuseppina Malcangi [1] and Gianna Dipalma [1,*]

[1] Department of Interdisciplinary Medicine, University of Bari "Aldo Moro", 70124 Bari, Italy; francesco.inchingolo@uniba.it (F.I.); angeloinchingolo@gmail.com (A.M.I.); giuliapalmieri13@gmail.com (G.P.); c.dipede1@studenti.uniba.it (C.D.P.); graziagarofoli.g@libero.it (G.G.); studio.deruvo@libero.it (E.d.R.); ad.inchingolo@libero.it (A.D.I.); dr.antonio.mancini@gmail.com (A.M.); daniela.divenere@uniba.it (D.D.V.); giuseppinamalcangi@libero.it (G.M.)

[2] Implant Dentistry College of Medicine and Dentistry Birmingham, University of Birmingham, Birmingham B4 6BN, UK; andrea.palermo2004@libero.it

* Correspondence: giannadipalma@tiscali.it; Tel.: +39-339-698-9939

Abstract: The external apical root resorption that occurs during orthodontic treatment was the focus of this study, using either fixed appliances (FA) or clear aligners (CA). Using the Boolean keywords "APICAL ROOT RESORPTION" and "CLEAR ALIGNERS", the study searched PubMed, Scopus, and Web of Science, with a restriction to English-language publications. A total of 50 publications were found by the computerized search, but after eliminating duplicates, completing reviews, and determining eligibility, only 9 papers could be used in the study. In conclusion, apical root resorption (ARR) is a frequent consequence of orthodontic tooth movement that mainly affects the lower incisors, which may compromise the success of the procedure and the health of the patient's teeth. Several variables, including the type of tooth, have an impact on the severity of ARR.

Keywords: apical root resorption; clear aligner; CBCT; fixed orthodontic appliances; root resorption

Citation: Inchingolo, F.; Inchingolo, A.M.; Palmieri, G.; Di Pede, C.; Garofoli, G.; de Ruvo, E.; Inchingolo, A.D.; Palermo, A.; Mancini, A.; Di Venere, D.; et al. Root Resorption during Orthodontic Treatment with Clear Aligners vs. Fixed Appliances—A Systematic Review. *Appl. Sci.* **2024**, *14*, 690. https://doi.org/10.3390/app14020690

Academic Editors: Simone Parrini, Gabriele Rossini and Andrea Deregibus

Received: 12 December 2023
Revised: 7 January 2024
Accepted: 10 January 2024
Published: 13 January 2024

1. Introduction

In orthodontics, the research into a more comfortable appliance that is able to meet aesthetic needs of the patient has led to the spread of aligner therapy [1–6]. The classic fixed orthodontic treatment, despite its clinical efficacy, sometimes encounters poor patient acceptance, and this has led to the search for alternative therapies [7–11]. Both appliances work on the basis of bone remodeling theory, according to which the orthodontic tooth movement is caused by bone resorption that is induced by osteoclasts in pressure zones, as well as by bone formation in the area of tension due to osteoblasts [12]. The advantage of the fixed appliance is that patient compliance is not necessary, while the aligners must be worn at least 22 h a day. Furthermore, aligners are aesthetic and make home oral hygiene easier.

Among the most common adverse reactions to orthodontic treatment is the orthodontically induced apical root resorption [13,14]. Although apical root resorption (ARR) can affect any tooth in the oral cavity, the teeth most susceptible to resorption are the maxillary central and lateral incisors [15–17]. Multiple biological, mechanical, and clinical factors can provoke root resorption after orthodontic therapy, but the precise mechanism underlying this event is still unknown [18]. The literature concerning the effect of clear aligners on apical root resorption is controversial. There are different stages of root resorption, and they may differ in the way we clinically approach them (in Figure 1, apical root resorption is represented by the black area of the root). This is a process not

yet well understood; it might be caused by inflammation, infection, periodontal disease, or orthodontic movements that are too strong or too fast to be handled by the roots. To avoid, or lower, the chances of root resorption, it is suggested to use light and regular orthodontic forces instead of shorter and stronger ones. If root resorption occurs, it should be considered an irreversible process that can lead, in severe cases, to the extraction of the tooth (Figure 1) [19–21]. The type of orthodontic movement, depending on the degrees and directions of forces, and on the treatment duration, can influence apical root resorption [22].

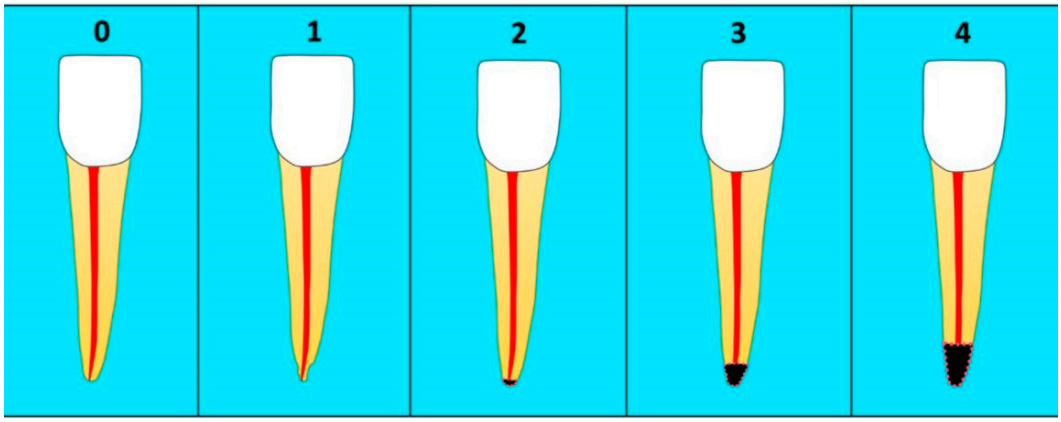

Figure 1. Different stages of root resorption. The part of the root that is colored black represents apical root resorption.

External apical root resorption (EARR) consists of a loss of cementum or dentine accompanied by irreparable damage to the root structure, resulting in a reduction in the length of the root apex. This adverse event could cause tooth mobility and can reduce the viability of teeth [23,24]. In fact, orthodontic tooth movement may result in a concentration of forces on the periodontium, mostly on the apical third of the root, causing a loss of protective cells on the surface layer which consequently causes a loss of root structure that, in some cases, can be linked with episodes of orofacial pain [25–30]. In the first phase, the damage to this structure leads to exposed denuded mineralized tissue; in the second phase, this tissue is colonized by inflammatory cells with consequent bone resorption. If the inflammatory stimulus persists, root structures are damaged, as revealed by radiographic evidence [31–34]. Cone beam computed tomography (CBCT), a three-dimensional radiography tomography, has a demonstrably higher accuracy in diagnosis and measurement of ARR (Figure 2) [35–39]. Being an irreversible process, it is fundamental to study this process carefully, along with its protective and risk factors [40–43].

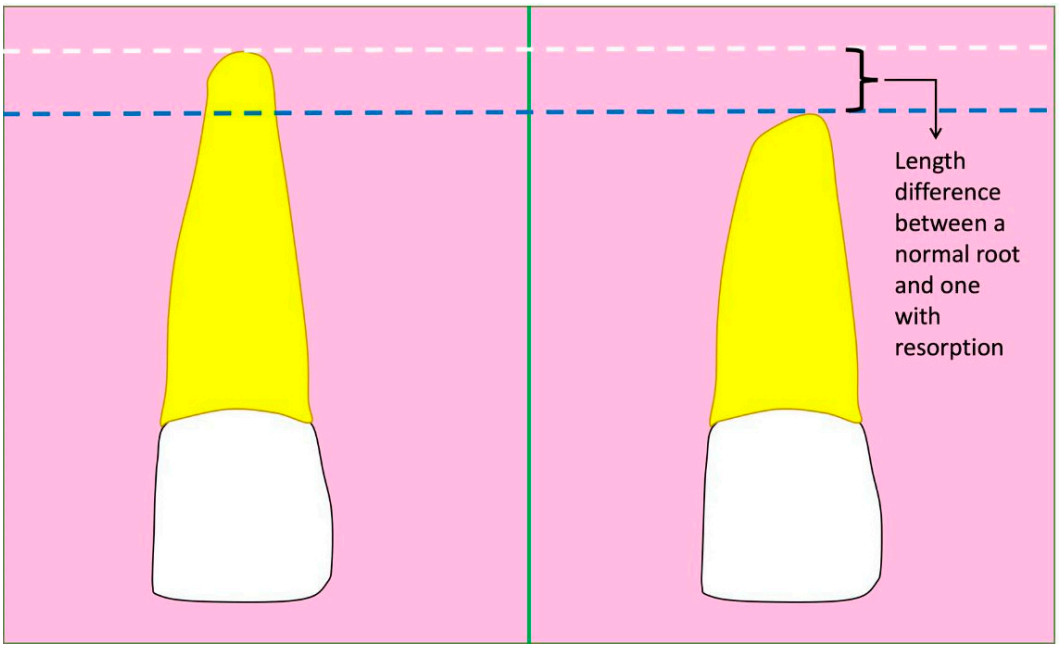

Figure 2. Length difference between a normal root and one with resorption. The white line indicates the length of the healthy dental root, while the blue line indicates the length of the dental rooteriassorbed.

Apart from the potential advantages of better aesthetics and comfort, the potential of predictability, reproducibility, and objectivity of aligners will potentially allow for controlling the stress derived from orthodontic forces, especially in the third apical of the radicular area [44–46].

The best strategy for treating root resorption is to take risk factors into account, talk to the patient in need of orthodontic treatment about the factors that were found, and include these factors in the treatment consent form. Among these risk factors is the length of the course of treatment. The longer a treatment is administered, the higher the risk of root resorption [47–49]. Resorption is more likely to occur in roots with a thin, tapered, and dilated morphology [50–53]. Furthermore, the risk of root resorption is elevated in cases of past trauma related to the anterior teeth [54]. There is a chance that root resorption from prior orthodontic treatment will cause additional root shortening [55].

In these cases, conservative orthodontic re-treatment should be used, and the scope of the treatment should be constrained. Root resorption may be more likely in people who have a history of chronic bruxism, occlusal trauma, or thumb sucking [56,57].

It is advised to assess the situation, using advancement radiographs, six to twelve months following the initiation of the orthodontic treatment. Periapical or panoramic radiographs may be used for these assessments. The patient should be advised that the active treatment should be stopped for a minimum of three months if root resorption is seen [58]. The root resorption reparative process starts two weeks after the end of the active treatment [47]. When severe root resorption is seen at this point, a different treatment strategy should be taken into consideration, and treatment should be stopped.

The purpose of this study is the proper evaluation of the relationship between orthodontically induced apical root resorption and the orthodontic treatment with aligners. Therefore, this study also aims to compare aligner therapy with fixed orthodontic appliances as regards apical root resorption following orthodontic treatment.

2. Materials and Methods

In order to achieve the aims presented above, a literature review was carried out as described in the following subsections.

2.1. Protocol and Registration

This review was conducted in accordance with the standards of the Preferred Reporting Items for Systematic Reviews and Meta-Analyses (PRISMA), and it was submitted to PROSPERO (International Prospective Register of Systematic Reviews) with the number 460,848 [59].

2.2. Search Processing

APICAL ROOT RESORPTION and CLEAR ALIGNED were the terms with which databases (Scopus, Web of Science, and PubMed) were searched to identify the papers under evaluation. Searches were combined using the Boolean operator "AND".

The search was restricted to include only items published in English and during the previous ten years (2013–2023) (Table 1).

Table 1. Database search indicators.

Article Screening Strategy	Databases: Scopus, Web of Science, and PubMed Keywords: A "APICAL ROOT RESORPTION"; B "CLEAR ALIGNES" Boolean variable: "AND" Timespan: 2013–2023 Language: English

2.3. Eligibility Criteria

Working in pairs, the reviewers selected publications that met two criteria for inclusion: (1) research using human subjects only; and (2) clinical studies or case reports.

The following studies were excluded: (1) in vitro investigations; (2) animal research; and (3) narrative reviews, meta-analyses, and systematic reviews.

The review was conducted using the PICO criteria:

Population: adult patients in need of orthodontic treatment, both male and female;
Intervention: fixed orthodontic appliances or clear aligners for orthodontic therapy;
Comparison: apical root resorption following fixed orthodontic therapy or clear aligners;
Outcome: root volume variation before and after treatment.

2.4. Data Processing

Any publications that deviated from the themes examined were excluded through the screening process, which involved reading the titles and abstracts of articles selected in the previous identification step. After that, the full texts of publications that met the preset inclusion requirements were perused. Disagreements among reviewers regarding the article selection were resolved through discussion.

3. Results

A total of fifty articles were found using keyword searches in the Web of Science (21), Scopus (14), and PubMed (15) databases. Twenty-four articles were included after duplicates (26 total) were eliminated. Fourteen of these twenty-four studies were eliminated because they did not meet the predetermined inclusion criteria. Of the 14, 10 were systematic reviews, 2 were in vitro studies, and 2 were animal research studies. Nine publications were chosen for this work at the end of the screening process (Figure 3). Each study's findings are presented in Table 2.

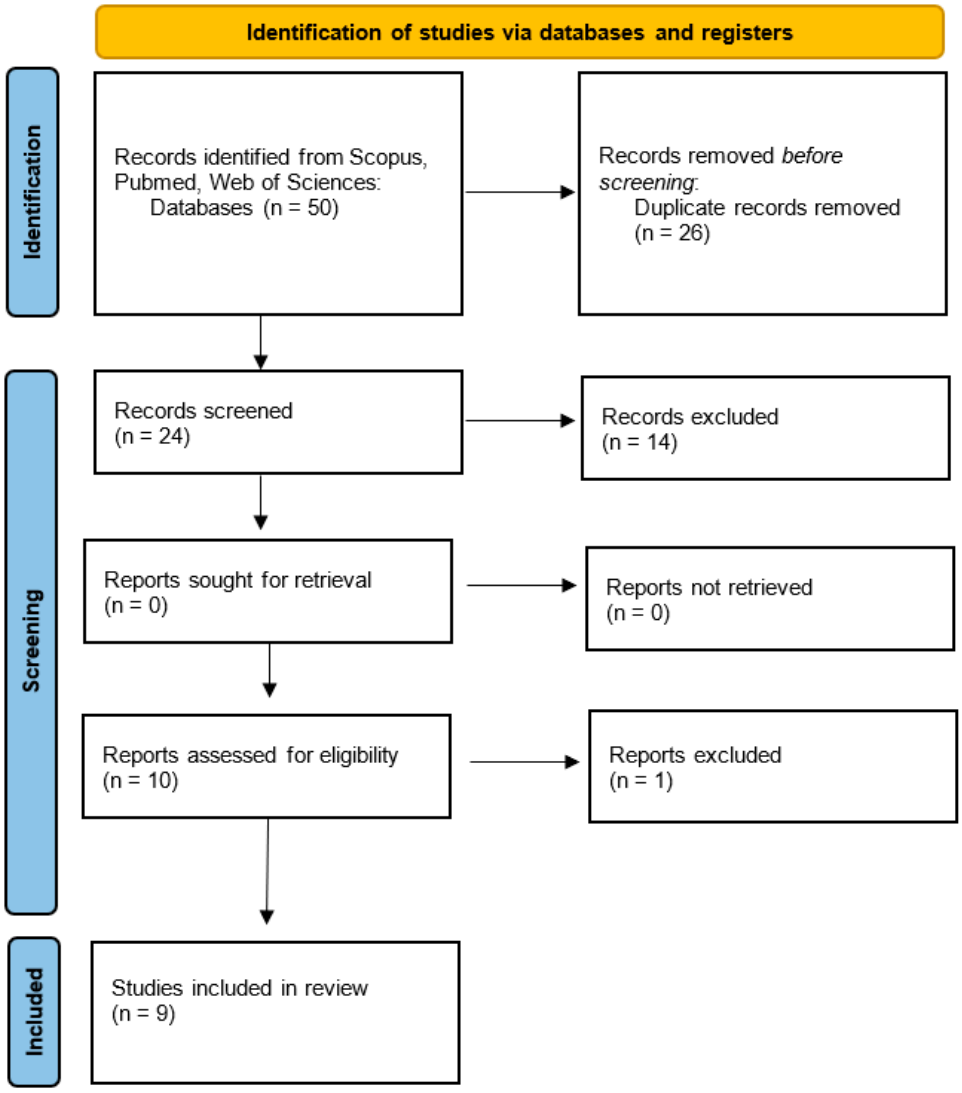

Figure 3. PRISMA flowchart.

Table 2. Results table.

Authors (Year)	Type of the Study	Aim of the Study	Materials	Results
Gay et al. [31] 2017	Radiometric study	The study's goal was to look at the prevalence and severity of root resorption in adult patients wearing aligners.	Panoramic radiographs taken at the start (T0) and end (T1) of the clear aligner therapy were used to measure the lengths of 1083 teeth's roots and crowns.	Root resorption (RR) could result from Invisalign® orthodontic treatment. However, it turned out that its incidence was extremely comparable to that which was described for orthodontic mild forces.
Iglesias-linares et al. [44] 2017	Case-control genetic association study	To evaluate risk factors of EARR after CAT or FOT.	Genetic and clinical factors were evaluated in 172 patients treated with CA or fixed appliances.	Similar results were obtained after both treatments.
Aman et al. [60] 2018	Retrospective study	The aim of the study was to investigate the incidence and severity of orthodontically induced root resorption with clear aligner therapy.	Maxillary incisor root lengths were measured using CBCT before and after treatment in 160 patients treated with clear aligners.	Minimal root resorption was the consequence of thorough treatment with clear aligners.

Eissa et al. [19] 2018	Pilot study	The aim of this study was to evaluate the root resorption of maxillary incisors after treatment with aligners, compared with fixed appliances.	Thirty-three patients were divided into three groups. group 1: patients treated with clear aligners; group 2: patients treated with Damon brackets; group 3: patients treated with twin brackets. Maxillary incisor tooth lengths were evaluated using CBCT.	Root resorption after orthodontic treatment was a complication with various orthodontic techniques. Less root resorption was reported with the use of invisible aligners.
Yi et al. [61] 2018	Clinical study	The amount of EARR in non-extraction patients undergoing CAT or fixed orthodontic treatment.	Panoramic radiographs of 80 patients treated with FOT and CAT.	EARR was lower in non-extraction patients treated with CA than in those treated with fixed appliances.
Li et al. [35] 2020	Cone beam computed tomography study	This study used CBCT to examine and evaluate the prevalence and severity of ARR in individuals receiving treatment with clear aligners and fixed appliances.	Total of 373 roots from 70 subjects divided into two groups (clear aligners group and fixed appliances group). The root length of each anterior tooth was measured on the basis of CBCT images. The ARR on each tooth was calculated as the difference in root length before and after orthodontic treatment.	Clear aligner patients had lower prevalence and severity of ARR than fixed appliance patients, as determined by CBCT.
Liu et al. [62] 2021	Retrospective study	The purpose of the study was to investigate the prevalence and severity of root resorption with clear aligner therapy using CBCT.	This research included 320 incisors from 40 Class II patients with Invisalign aligners. Pre-treatment (T0) and post-treatment (T1) CBCT pictures were collected.	During aligner therapy, the majority of incisors had mild to moderate resorption; a very small proportion displayed severe resorption.
Toyokawa-Sperandio et al. [63] 2021	Randomized clinical trial	To compare the amount of ARR after orthodontic therapy (fixed appliances vs. CA).	Intraoral radiographs of anterior teeth from 40 patients before (T0) and after 6 months (T1) of CAT or FOT.	Intraoral radiographs showed how both techniques resulted in a comparable ARR that does not affect the longevity of the teeth.
Almagramgi et al. [64] 2023	Retrospective study	The study's goal was to examine the severity of orthodontically caused root resorption of maxillary incisors in those who used transparent aligners vs. fixed appliances.	One hundred and sixty maxillary incisors from 40 patients. Quantitative dentoalveolar changes were analyzed using pre- (T0) and post-treatment (T1) CBCT.	Treatments with clear aligners and fixed appliances appeared to cause increased root resorption in the maxillary incisor, with a higher incidence in fixed appliance treatments.

Quality Assessment and Risk of Bias

Figure 4 reports the risk of bias in the included studies. One study shows a significant risk of bias with regard to the randomization procedure and allocation concealment. Low risk of bias is ensured by all other studies. Of the included studies, two display an increased risk of detection bias (self-reported outcome); two show a low risk of detection bias (objective measures); and only one study exhibits performance bias (Figure 4). Two studies ensure a low risk regarding attrition and reporting bias.





Figure 4. Risk of bias: red indicates high risk of bias, and green indicates low risk of bias. Almagrami et al. [64], Aman et al. [60], Eissa et al. [19], Gay et al. [31], Iglesias et al. [44], Li et al. [35], Liu et al. [62], Toyokawa-Sperandio et al. [63], Yi et al. [63].

4. Discussion

Although numerous works can be found in the literature comparing these two orthodontic therapies, answers to several questions are still missing, including whether the amount of apical root resorption is predictable, and whether therapy with aligners brings advantages in terms of apical resorption compared to fixed therapy. Therefore, a broader review is important.

One of the most undesirable effects of orthodontic therapy is apical root resorption (ARR), which is a permanent loss of hard tissue on the root apex of a tooth. The incidence of ARR in orthodontic patients ranges from 20% to 100% [60]. Severe ARR is uncommon, with a frequency of 1 to 5%; however, resorption can be greater than 5 mm, or one-fourth of the root length [60]. ARR can result in an uneven crown-to-root ratio in the afflicted teeth, as well as tooth loss, thus compromising patients' quality of life and orthodontic

treatment outcome [63]. Clear aligners are becoming increasingly popular for orthodontic treatment; nevertheless, ARR during clear aligner therapy is still poorly understood.

The ARR in patients treated with clear aligners and conventional fixed appliances was evaluated and compared in this study [63]. The type of tooth movement can contribute to an increased occurrence of root resorption [65,66]. The removal of the hyaline zone is believed to be necessary to initiate natural tooth movement, but it can also lead to the absorption of the root's cement, making the exposed dentine more vulnerable to resorption by scavenger cells. To avoid or lower the chances of root resorption, it is suggested to use light and regular orthodontic forces instead of shorter and stronger ones. Some argue that intermittent forces, such as those exerted by aligners, versus continuous forces from fixed appliances, result in distinct types of pressure [67–69]. According to certain sources, intermittent pressure may permit the cementum around the root to repair itself. In a randomized controlled clinical trial, Toyokawa-Sperandio et al. compared the amount of root resorption six months into orthodontic treatment between fixed appliances and orthodontic aligners (OA) [63]. Intraoral X-rays of the front teeth demonstrated that both methods resulted in comparable root resorption rates that did not impact tooth longevity. Similar findings were reported by Iglesias-Linares et al., who considered various clinical, genetic, and radiographic factors [44]. However, Yi et al. suggested that external apical root resorption (EARR) was lower in non-extraction patients treated with OA compared to those treated with fixed appliances, indicating that OA might be more effective in safeguarding teeth from root resorption [61].

Given that ARR is a three-dimensional topographical change, the accuracy of ARR assessment is limited in two-dimensional radiography, such as in panoramic and periapical radiographs [60]. Cone beam computed tomography (CBCT), on the other hand, has demonstrated considerably higher accuracy in the diagnosis and quantification of ARR [60].

Li et al. conducted a study analyzing the prevalence and severity of root resorption using fixed orthodontic treatment and aligners. They used cone beam computed tomography (CBCT) to measure root resorption, defined as the difference, in millimeters, between tooth lengths before and after orthodontic treatment [35]. A total of 373 roots from 70 subjects were considered. The prevalence of root resorption was significantly lower in the clear aligner group (56.30%) compared to the fixed appliance group (82.11%). In the fixed appliance group, all teeth examined before and after treatment showed a statistically significant reduction in root length, whereas in the clear aligner group, only the maxillary incisors and mandibular central incisors exhibited a statistically significant change in root length [35]. Li et al. compared the severity of root resorption in individuals undergoing treatment with fixed braces versus transparent aligners. The maxillary canine and lateral incisor in the fixed appliance group experienced the most severe root resorption, while the mandibular canine and lateral incisor in the transparent aligner group displayed the least severe root resorption [35]. They observed reduced severity and lower prevalence of root resorption in patients who were treated with aligners.

In contrast, Gay et al. employed panoramic X-rays to compare the lengths of 1083 teeth (incisors, canines, and premolars) before and after aligner therapy [31]. All 71 adult patients examined in their study showed a minimal reduction in root length, where root length is considered the distance between the apex and the cement–enamel junction. However, only 3.69% of the assessed teeth (41.81%) had roots shorter than 20% of their original pre-treatment length. This incidence of root resorption can be compared to any orthodontic therapy with light orthodontic forces. Upper lateral incisors, lower lateral incisors, and central incisors were the teeth most affected by severe root resorption [31].

Liu et al.'s study exclusively evaluated incisors in patients who used aligners to address class II malocclusion. They defined root resorption as the difference in root volume before and after treatment [62]. Following treatment with clear aligners, most teeth exhibited mild to moderate resorption, with only a few displaying severe resorption.

Risk factors for root volume loss included tooth type and intrusion–extrusion changes [62].

In 2023, Ibtehal Almagrami et al. conducted a retrospective study to assess the dimensions of alveolar bone alterations associated with orthodontic tooth movement (OTM), as well as the prevalence and severity of orthodontically induced inflammatory root resorption (OIIRR) in maxillary incisors treated with clear aligners (CA) or fixed orthodontic appliances (FA) [64]. The secondary goal of this study was to compare post-treatment alveolar bone alterations and root resorption in maxillary incisors treated with either approach. A total of 40 patients were randomly assigned to one of two groups (CA or FA). In the CA group, 20 patients were treated with Invisalign (Align Technology, San Jose, CA, USA). The FA group included 20 patients (29.67 ± 7.71 months) who had fixed orthodontic appliances (Victory Series; 3 M Unitek, San Jose, CA, USA). Baseline characteristics and treatment duration were identical across both groups; moreover, both groups were treated with mild to moderate crowding on a non-extraction basis. Crowding was reduced by posterior teeth distalization, dental arch expansion, and anterior tooth proclination. Pre-treatment (T0) and post-treatment (T1) CBCT was used to assess dentoalveolar quantitative alterations. Alveolar bone thickness (ABT), alveolar bone height (ABH), root length (OIIRR), and maxillary incisor inclinations were among the parameters assessed. CA and FA treatments appeared to generate a substantial reduction in ABT, and both treatment methods reduced ABH significantly, with the greatest reduction reported on the labial side of the lateral incisors in the CA group. FA and CA treatments resulted in statistically significant increases in OIIRR in the maxillary incisor area, with FA patients displaying a greater frequency and severity of OIIRR.

CBCT was also used in Aman et al.'s study to investigate the occurrence and severity of OIIRR in patients who had undergone complete treatment with clear aligners (Invisalign; Align Technologies, Santa Clara, CA, USA), and to identify potential risk factors for OIIRR [60]. The root lengths of 160 patients who had completed orthodontic treatment with clear aligners were assessed, using orthogonal images from pre-treatment and post-treatment cone-beam computed tomography exams.

The proportion of change in root length was strongly impacted by gender, malocclusion, crowding, and post-treatment approximation to the cortical plates. Based on the results of this study, comprehensive treatment with clear aligners resulted in minimal root resorption, and the best predictor of root resorption was the post-treatment location of the root apices relative to the palatal cortical plate [60].

Osama Eissa et al. used CBCT to compare the root lengths of upper incisors as an indicator of orthodontically induced apical root resorption following treatment with Smart Track® aligners versus two different types of fixed orthodontic appliances—regular and Damon brackets [19]. The research featured 33 patients with class I malocclusion (4–6 mm crowding) who were randomly assigned to one of three groups: Smart Track® aligners, Damon brackets, or conventional brackets. Using Dolphin imaging software, the lengths of maxillary incisor teeth were measured before and after treatment. When compared to typical pre-adjusted edgewise appliances in instances of class I malocclusion with mild to moderate crowding, Smart Track® aligners showed less reduction in root length, indicating reduced root resorption. In terms of root resorption, there was no statistically significant difference between aligners and passive self-ligating Damon Q devices [19].

5. Conclusions

In conclusion, orthodontic therapy, while highly effective in achieving desired tooth movements, is associated with the potential side effect of apical root resorption (ARR). This permanent loss of hard tissue at the root apex can range in severity, with severe cases compromising the crown-to-root ratio and, in extreme instances, leading to tooth loss. The incidence of ARR in orthodontic patients varies widely, and its impact on patients' quality

of life and treatment outcomes underscores the need for a comprehensive understanding and effective management of ARR.

Clear aligners have gained popularity as an alternative to conventional fixed appliances for orthodontic treatment. The mechanism of tooth movement during clear aligner therapy and its association with ARR remain areas of ongoing research and debate. The nature of forces exerted, whether intermittent forces from aligners, or continuous forces from fixed appliances, may influence the occurrence and severity of root resorption. Studies comparing ARR in patients treated with clear aligners versus fixed appliances have yielded varying results, indicating the complexity of this phenomenon.

The assessment of ARR is crucial for accurate diagnosis and treatment planning. Traditional two-dimensional radiography has limitations in capturing the three-dimensional topographical changes associated with root resorption. Cone beam computed tomography (CBCT) emerges as a valuable tool, offering higher accuracy in the diagnosis and quantification of ARR. Recent studies utilizing CBCT have provided insights into the prevalence and severity of ARR in patients undergoing orthodontic treatment with clear aligners or fixed appliances.

Comparative studies, such as the one conducted by Li et al., revealed differences in the prevalence and severity of root resorption between clear aligner and fixed appliance groups. The choice of treatment modality and its impact on ARR may vary depending on tooth type and other factors. Additionally, investigations into the dimensions of alveolar bone alterations and orthodontically induced inflammatory root resorption (OIIRR) further contribute to our understanding of the consequences of orthodontic tooth movement. Recent research, such as the retrospective study by Ibtehal Almagrami et al., highlights the importance of considering post-treatment alveolar bone alterations and root resorption when comparing different orthodontic approaches. Comparing clear aligners with fixed orthodontic appliances, the study demonstrated distinct effects on alveolar bone thickness, height, and root length, emphasizing the need for careful evaluation in treatment planning.

In summary, while ARR remains a concern in orthodontic therapy, ongoing research, particularly with the use of advanced imaging techniques like CBCT, contributes to a better understanding of the factors influencing root resorption. Clinicians should weigh the risks and benefits of different treatment modalities, considering individual patient characteristics and the potential impact on root health. As orthodontic techniques continue to evolve, addressing and minimizing the risk of ARR will be crucial for optimizing treatment outcomes and ensuring long-term oral health for patients undergoing orthodontic therapy.

The variability in treatment protocols, patient populations, and orthodontic techniques across different regions and practices may limit the generalizability of the results and should be considered in future research endeavors.

Author Contributions: Conceptualization, A.D.I., F.I., D.D.V., and G.D.; methodology, A.D.I., A.M.I., and G.G.; software, C.D.P. and G.D.; validation, E.d.R. and G.P.; formal analysis, A.M.I., A.P., and G.M.; investigation, A.D.I.; resources, A.M., A.M.I., and F.I.; data curation, G.D., D.D.V., and G.G.; writing—original draft preparation, A.D.I., A.M.I., G.D., and F.I.; writing—review and editing, F.I., G.P., G.G., G.M., and C.D.P.; visualization, E.d.R., A.P., A.M., and G.M.; supervision, D.D.V., F.I., A.M., and A.D.I.; project administration, F.I. All authors have read and agreed to the published version of the manuscript.

Funding: This research received no external funding.

Institutional Review Board Statement: Not applicable.

Informed Consent Statement: Not applicable.

Data Availability Statement: Not applicable.

Conflicts of Interest: The authors declare no conflict of interest.

References

1. Robertson, L.; Kaur, H.; Fagundes, N.C.F.; Romanyk, D.; Major, P.; Flores Mir, C. Effectiveness of Clear Aligner Therapy for Orthodontic Treatment: A Systematic Review. *Orthod. Craniofac. Res.* **2020**, *23*, 133–142. https://doi.org/10.1111/ocr.12353.
2. Upadhyay, M.; Arqub, S.A. Biomechanics of Clear Aligners: Hidden Truths & First Principles. *J. World Fed. Orthod.* **2022**, *11*, 12–21. https://doi.org/10.1016/j.ejwf.2021.11.002.
3. Bichu, Y.M.; Alwafi, A.; Liu, X.; Andrews, J.; Ludwig, B.; Bichu, A.Y.; Zou, B. Advances in Orthodontic Clear Aligner Materials. *Bioact. Mater.* **2022**, *22*, 384–403. https://doi.org/10.1016/j.bioactmat.2022.10.006.
4. Lynch, N.M.; Shroff, B.; Carrico, C.K.; Sawicki, V.; Sabol, M.; Lindauer, S.J. Clear Aligner Therapy in the Mixed Dentition: Indications and Practitioner Perspectives. *Am. J. Orthod. Dentofac. Orthop.* **2023**, *164*, 172–182. https://doi.org/10.1016/j.ajodo.2022.11.018.
5. Smith, J.M.; Weir, T.; Kaang, A.; Farella, M. Predictability of Lower Incisor Tip Using Clear Aligner Therapy. *Prog. Orthod.* **2022**, *23*, 37. https://doi.org/10.1186/s40510-022-00433-4.
6. Simon, M.; Keilig, L.; Schwarze, J.; Jung, B.A.; Bourauel, C. Treatment Outcome and Efficacy of an Aligner Technique—Regarding Incisor Torque, Premolar Derotation and Molar Distalization. *BMC Oral. Health* **2014**, *14*, 68. https://doi.org/10.1186/1472-6831-14-68.
7. Rapone, B.; Ferrara, E.; Santacroce, L.; Topi, S.; Gnoni, A.; Dipalma, G.; Mancini, A.; Di Domenico, M.; Tartaglia, G.M.; Scarano, A.; et al. The Gaseous Ozone Therapy as a Promising Antiseptic Adjuvant of Periodontal Treatment: A Randomized Controlled Clinical Trial. *Int J Environ Res Public Health* **2022**, *19*, 985, doi:10.3390/ijerph19020985.
8. Marrelli, M.; Tatullo, M.; Dipalma, G.; Inchingolo, F. Oral Infection by Staphylococcus Aureus in Patients Affected by White Sponge Nevus: A Description of Two Cases Occurred in the Same Family. *Int J Med Sci* **2012**, *9*, 47–50, doi:10.7150/ijms.9.47.
9. Inchingolo, F.; Tatullo, M.; Abenavoli, F.M.; Marrelli, M.; Inchingolo, A.D.; Villabruna, B.; Inchingolo, A.M.; Dipalma, G. Severe Anisocoria after Oral Surgery under General Anesthesia. *Int J Med Sci* **2010**, 314–318, doi:10.7150/ijms.7.314.
10. Inchingolo, A.D.; Patano, A.; Coloccia, G.; Ceci, S.; Inchingolo, A.M.; Marinelli, G.; Malcangi, G.; Montenegro, V.; Laudadio, C.; Pede, C. Di; et al. The Efficacy of a New AMCOP® Elastodontic Protocol for Orthodontic Interceptive Treatment: A Case Series and Literature Overview. *Int J Environ Res Public Health* **2022**, *19*, 988, doi:10.3390/ijerph19020988.
11. Jung, W.-S.; Kim, K.; Cho, S.; Ahn, S.-J. Adhesion of Periodontal Pathogens to Self-Ligating Orthodontic Brackets: An in-Vivo Prospective Study. *Am. J. Orthod. Dentofac. Orthop.* **2016**, *150*, 467–475. https://doi.org/10.1016/j.ajodo.2016.02.023.
12. Di Paola, A.; Tortora, C.; Argenziano, M.; Marrapodi, M.M.; Rossi, F. Emerging Roles of the Iron Chelators in Inflammation. *Int. J. Mol. Sci.* **2022**, *23*, 7977. https://doi.org/10.3390/ijms23147977.
13. Coloccia, G.; Inchingolo, A.D.; Inchingolo, A.M.; Malcangi, G.; Montenegro, V.; Patano, A.; Marinelli, G.; Laudadio, C.; Limongelli, L.; Di Venere, D.; et al. Effectiveness of Dental and Maxillary Transverse Changes in Tooth-Borne, Bone-Borne, and Hybrid Palatal Expansion through Cone-Beam Tomography: A Systematic Review of the Literature. *Medicina (B Aires)* **2021**, *57*, 288, doi:10.3390/medicina57030288.
14. Rapone, B.; Inchingolo, A.D.; Trasarti, S.; Ferrara, E.; Qorri, E.; Mancini, A.; Montemurro, N.; Scarano, A.; Inchingolo, A.M.; Dipalma, G.; et al. Long-Term Outcomes of Implants Placed in Maxillary Sinus Floor Augmentation with Porous Fluorohydroxyapatite (Algipore® FRIOS®) in Comparison with Anorganic Bovine Bone (Bio-Oss®) and Platelet Rich Plasma (PRP): A Retrospective Study. *J Clin Med* **2022**, *11*, 2491, doi:10.3390/jcm11092491.
15. Feller, L.; Khammissa, R.A.G.; Thomadakis, G.; Fourie, J.; Lemmer, J. Apical External Root Resorption and Repair in Orthodontic Tooth Movement: Biological Events. *Biomed. Res. Int.* **2016**, *2016*, 4864195. https://doi.org/10.1155/2016/4864195.
16. Malcangi, G.; Inchingolo, A.D.; Patano, A.; Coloccia, G.; Ceci, S.; Garibaldi, M.; Inchingolo, A.M.; Piras, F.; Cardarelli, F.; Settanni, V.; et al. Impacted Central Incisors in the Upper Jaw in an Adolescent Patient: Orthodontic-Surgical Treatment—A Case Report. *Appl. Sci.* **2022**, *12*, 2657. https://doi.org/10.3390/app12052657.
17. Inchingolo, A.D.; Patano, A.; Coloccia, G.; Ceci, S.; Inchingolo, A.M.; Marinelli, G.; Malcangi, G.; Montenegro, V.; Laudadio, C.; Palmieri, G.; et al. Genetic Pattern, Orthodontic and Surgical Management of Multiple Supplementary Impacted Teeth in a Rare, Cleidocranial Dysplasia Patient: A Case Report. *Medicina* **2021**, *57*, 1350. https://doi.org/10.3390/medicina57121350.
18. Vimercati, L.; De Maria, L.; Quarato, M.; Caputi, A.; Gesualdo, L.; Migliore, G.; Cavone, D.; Sponselli, S.; Pipoli, A.; Inchingolo, F.; et al. Association between Long COVID and Overweight/Obesity. *J Clin Med* **2021**, *10*, 4143, doi:10.3390/jcm10184143.
19. Malcangi, G.; Inchingolo, A.D.; Inchingolo, A.M.; Piras, F.; Settanni, V.; Garofoli, G.; Palmieri, G.; Ceci, S.; Patano, A.; Mancini, A.; et al. COVID-19 Infection in Children and Infants: Current Status on Therapies and Vaccines. *Children* **2022**, *9*, 249, doi:10.3390/children9020249.
20. Yassir, Y.A.; Nabbat, S.A.; McIntyre, G.T.; Bearn, D.R. Clinical Effectiveness of Clear Aligner Treatment Compared to Fixed Appliance Treatment: An Overview of Systematic Reviews. *Clin. Oral. Investig.* **2022**, *26*, 2353–2370. https://doi.org/10.1007/s00784-021-04361-1.
21. Inchingolo, F.; Tatullo, M.; Abenavoli, F.M.; Marrelli, M.; Inchingolo, A.D.; Inchingolo, A.M.; Dipalma, G. Non-Hodgkin Lymphoma Affecting the Tongue: Unusual Intra-Oral Location. *Head Neck Oncol* **2011**, *3*, 1, doi:10.1186/1758-3284-3-1.
22. Tortora, C.; Di Paola, A.; Argenziano, M.; Creoli, M.; Marrapodi, M.M.; Cenni, S.; Tolone, C.; Rossi, F.; Strisciuglio, C. Effects of CB2 Receptor Modulation on Macrophage Polarization in Pediatric Celiac Disease. *Biomedicines* **2022**, *10*, 874. https://doi.org/10.3390/biomedicines10040874.
23. Di Cosola, M.; Cazzolla, A.P.; Charitos, I.A.; Ballini, A.; Inchingolo, F.; Santacroce, L. *Candida albicans* and Oral Carcinogenesis. A Brief. Review. *J. Fungi* **2021**, *7*, 476. https://doi.org/10.3390/jof7060476.

24. Lin, E.; Julien, K.; Kesterke, M.; Buschang, P.H. Differences in Finished Case Quality between Invisalign and Traditional Fixed Appliances. *Angle Orthod.* **2022**, *92*, 173–179. https://doi.org/10.2319/032921-246.1.
25. Reddy, L.K.V.; Madithati, P.; Narapureddy, B.R.; Ravula, S.R.; Vaddamanu, S.K.; Alhamoudi, F.H.; Minervini, G.; Chaturvedi, S. Perception about Health Applications (Apps) in Smartphones towards Telemedicine during COVID-19: A Cross-Sectional Study. *J Pers Med* **2022**, *12*, 1920, doi:10.3390/jpm12111920.
26. Rathi, S.; Chaturvedi, S.; Abdullah, S.; Rajput, G.; Alqahtani, N.M.; Chaturvedi, M.; Gurumurthy, V.; Saini, R.; Bavabeedu, S.S.; Minervini, G. Clinical Trial to Assess Physiology and Activity of Masticatory Muscles of Complete Denture Wearer Following Vitamin D Intervention. *Medicina (B Aires)* **2023**, *59*, 410, doi:10.3390/medicina59020410.
27. Minervini, G.; Franco, R.; Marrapodi, M.M.; Ronsivalle, V.; Shapira, I.; Cicciù, M. Prevalence of Temporomandibular Disorders in Subjects Affected by Parkinson Disease: A Systematic Review and Metanalysis. *J. Oral. Rehabil.* **2023**, *50*, 877–885. https://doi.org/10.1111/joor.13496.
28. Crescente, G.; Minervini, G.; Spagnuolo, C.; Moccia, S. Cannabis Bioactive Compound-Based Formulations: New Perspectives for the Management of Orofacial Pain. *Molecules* **2022**, *28*, 106, doi:10.3390/molecules28010106.
29. Minervini, G.; Franco, R.; Marrapodi, M.M.; Di Blasio, M.; Ronsivalle, V.; Cicciù, M. Children Oral Health and Parents Education Status: A Cross Sectional Study. *BMC Oral Health* **2023**, *23*, 787, doi:10.1186/s12903-023-03424-x.
30. Deregibus, A.; Ferrillo, M.; Grazia Piancino, M.; Chiara Domini, M.; de Sire, A.; Castroflorio, T. Are Occlusal Splints Effective in Reducing Myofascial Pain in Patients with Muscle-Related Temporomandibular Disorders? A Randomized-Controlled Trial. *Turk. J. Phys. Med. Rehabil.* **2021**, *67*, 32–40. https://doi.org/10.5606/tftrd.2021.6615.
31. Gay, G.; Ravera, S.; Castroflorio, T.; Garino, F.; Rossini, G.; Parrini, S.; Cugliari, G.; Deregibus, A. Root Resorption during Orthodontic Treatment with Invisalign®: A Radiometric Study. *Prog. Orthod.* **2017**, *18*, 12. https://doi.org/10.1186/s40510-017-0166-0.
32. Pasini, M.; Giuca, M.R.; Ligori, S.; Mummolo, S.; Fiasca, F.; Marzo, G.; Quinzi, V. Association between Anatomical Variations and Maxillary Canine Impaction: A Retrospective Study in Orthodontics. *Appl. Sci.* **2020**, *10*, 5638. https://doi.org/10.3390/app10165638.
33. Adina, S.; Dipalma, G.; Bordea, I.R.; Lucaciu, O.; Feurdean, C.; Inchingolo, A.D.; Septimiu, R.; Malcangi, G.; Cantore, S.; Martin, D.; et al. Orthopedic Joint Stability Influences Growth and Maxillary Development: Clinical Aspects. *J. Biol. Regul. Homeost. Agents* **2020**, *34*, 747–756. https://doi.org/10.23812/20-204-E-52.
34. Cirulli, N.; Inchingolo, A.D.; Patano, A.; Ceci, S.; Marinelli, G.; Malcangi, G.; Coloccia, G.; Montenegro, V.; Pede, C.D.; Ciocia, A.M.; et al. Innovative Application of Diathermy in Orthodontics: A Case Report. *Int. J. Environ. Res. Public. Health* **2022**, *19*, 7448. https://doi.org/10.3390/ijerph19127448.
35. Li, Y.; Deng, S.; Mei, L.; Li, Z.; Zhang, X.; Yang, C.; Li, Y. Prevalence and Severity of Apical Root Resorption during Orthodontic Treatment with Clear Aligners and Fixed Appliances: A Cone Beam Computed Tomography Study. *Prog. Orthod.* **2020**, *21*, 1. https://doi.org/10.1186/s40510-019-0301-1.
36. Fanali, S.; Tumedei, M.; Pignatelli, P.; Inchingolo, F.; Pennacchietti, P.; Pace, G.; Piattelli, A. Implant Primary Stability with an Osteocondensation Drilling Protocol in Different Density Polyurethane Blocks. *Comput Methods Biomech Biomed Engin* **2021**, *24*, 14–20, doi:10.1080/10255842.2020.1806251.
37. Zhang, X.; Zhou, H.; Liao, X.; Liu, Y. The Influence of Bracket Torque on External Apical Root Resorption in Bimaxillary Protrusion Patients: A Retrospective Study. *BMC Oral. Health* **2022**, *22*, 7. https://doi.org/10.1186/s12903-022-02042-3.
38. Quinzi, V.; Saccomanno, S.; Manenti, R.; Giancaspro, S.; Paskay, L.; Marzo, G. Efficacy of Rapid Maxillary Expansion with or without Previous Adenotonsillectomy for Pediatric Obstructive Sleep Apnea Syndrome Based on Polysomnographic Data: A Systematic Review and Meta-Analysis. *Appl. Sci.* **2020**, *10*, 6485. https://doi.org/10.3390/app10186485.
39. De Felice, M.E.; Nucci, L.; Fiori, A.; Flores-Mir, C.; Perillo, L.; Grassia, V. Accuracy of Interproximal Enamel Reduction during Clear Aligner Treatment. *Prog. Orthod.* **2020**, *21*, 28. https://doi.org/10.1186/s40510-020-00329-1.
40. Inchingolo, A.D.; Dipalma, G.; Palmieri, G.; Di Pede, C.; Semjonova, A.; Patano, A.; Ceci, S.; Cardarelli, F.; Montenegro, V.; Garibaldi, M.; et al. Functional Breastfeeding: From Nutritive Sucking to Oral Health. *J. Biol. Regul. Homeost. Agents* **2022**, *36*, 121–137.
41. Maspero, C.; Cappella, A.; Dolci, C.; Cagetti, M.G.; Inchingolo, F.; Sforza, C. Is Orthodontic Treatment with Microperforations Worth It? A Scoping Review. *Children* **2022**, *9*, 208. https://doi.org/10.3390/children9020208.
42. Folco, A.A.; Benítez-Rogé, S.C.; Iglesias, M.; Calabrese, D.; Pelizardi, C.; Rosa, A.; Brusca, M.I.; Hecht, P.; Mateu, M.E. Gingival Response in Orthodontic Patients: Comparative Study between Self-Ligating and Conventional Brackets. *Acta Odontol. Latinoam.* **2014**, *27*, 120–124. https://doi.org/10.1590/S1852-48342014000300004.
43. Zhang, L.; Lin, S.; Chen, J.; Huang, L.; Huang, Z.; Li, H. Risk Factors for Midcourse Correction during Treatment of First Series of Aligners with Invisalign. *Am. J. Orthod. Dentofac. Orthop.* **2022**, *162*, e96–e102. https://doi.org/10.1016/j.ajodo.2021.12.018.
44. Iglesias-Linares, A.; Sonnenberg, B.; Solano, B.; Yañez-Vico, R.-M.; Solano, E.; Lindauer, S.J.; Flores-Mir, C. Orthodontically Induced External Apical Root Resorption in Patients Treated with Fixed Appliances vs. Removable Aligners. *Angle Orthod.* **2017**, *87*, 3–10. https://doi.org/10.2319/02016-101.1.
45. Inchingolo, A.D.; Ceci, S.; Patano, A.; Inchingolo, A.M.; Montenegro, V.; Di Pede, C.; Malcangi, G.; Marinelli, G.; Coloccia, G.; Garibaldi, M.; et al. Elastodontic Therapy of Hyperdivergent Class II Patients Using AMCOP® Devices: A Retrospective Study. *Appl. Sci.* **2022**, *12*, 3259. https://doi.org/10.3390/app12073259.

46. Jiang, T.; Wu, R.Y.; Wang, J.K.; Wang, H.H.; Tang, G.H. Clear Aligners for Maxillary Anterior En Masse Retraction: A 3D Finite Element Study. *Sci. Rep.* **2020**, *10*, 10156. https://doi.org/10.1038/s41598-020-67273-2.
47. Krishnan, V. Critical Issues Concerning Root Resorption: A Contemporary Review. *World J. Orthod.* **2005**, *6*, 30–40.
48. Brezniak, N.; Wasserstein, A. Root Resorption after Orthodontic Treatment: Part 2. Literature Review. *Am. J. Orthod. Dentofac. Orthop.* **1993**, *103*, 138–146. https://doi.org/10.1016/S0889-5406(05)81763-9.
49. Baumrind, S.; Korn, E.L.; Boyd, R.L. Apical Root Resorption in Orthodontically Treated Adults. *Am. J. Orthod. Dentofac. Orthop.* **1996**, *110*, 311–320. https://doi.org/10.1016/s0889-5406(96)80016-3.
50. Mirabella, A.D.; Artun, J. Risk Factors for Apical Root Resorption of Maxillary Anterior Teeth in Adult Orthodontic Patients. *Am. J. Orthod. Dentofac. Orthop.* **1995**, *108*, 48–55. https://doi.org/10.1016/s0889-5406(95)70065-x.
51. Levander, E.; Bajka, R.; Malmgren, O. Early Radiographic Diagnosis of Apical Root Resorption during Orthodontic Treatment: A Study of Maxillary Incisors. *Eur. J. Orthod.* **1998**, *20*, 57–63. https://doi.org/10.1093/ejo/20.1.57.
52. Killiany, D.M. Root Resorption Caused by Orthodontic Treatment: An Evidence-Based Review of Literature. *Semin. Orthod.* **1999**, *5*, 128–133. https://doi.org/10.1016/s1073-8746(99)80032-2.
53. Sameshima, G.T.; Sinclair, P.M. Predicting and Preventing Root Resorption: Part II. Treatment Factors. *Am. J. Orthod. Dentofac. Orthop.* **2001**, *119*, 511–515. https://doi.org/10.1067/mod.2001.113410.
54. Malmgren, O.; Goldson, L.; Hill, C.; Orwin, A.; Petrini, L.; Lundberg, M. Root Resorption after Orthodontic Treatment of Traumatized Teeth. *Am. J. Orthod.* **1982**, *82*, 487–491. https://doi.org/10.1016/0002-9416(82)90317-7.
55. Brezniak, N.; Wasserstein, A. Orthodontically Induced Inflammatory Root Resorption. Part. II: The Clinical Aspects. *Angle Orthod.* **2002**, *72*, 180–184. https://doi.org/10.1043/0003-3219(2002)072<0180:OIIRRP>2.0.CO;2.
56. Linge, L.; Linge, B.O. Patient Characteristics and Treatment Variables Associated with Apical Root Resorption during Orthodontic Treatment. *Am. J. Orthod. Dentofac. Orthop.* **1991**, *99*, 35–43. https://doi.org/10.1016/S0889-5406(05)81678-6.
57. Harris, E.F. Root Resorption during Orthodontic Therapy. *Semin. Orthod.* **2000**, *6*, 183–194. https://doi.org/10.1053/sodo.2000.8084.
58. Levander, E.; Malmgren, O.; Eliasson, S. Evaluation of Root Resorption in Relation to Two Orthodontic Treatment Regimes. A Clinical Experimental Study. *Eur. J. Orthod.* **1994**, *16*, 223–228. https://doi.org/10.1093/ejo/16.3.223.
59. Liberati, A.; Altman, D.G.; Tetzlaff, J.; Mulrow, C.; Gøtzsche, P.C.; Ioannidis, J.P.A.; Clarke, M.; Devereaux, P.J.; Kleijnen, J.; Moher, D. The PRISMA Statement for Reporting Systematic Reviews and Meta-Analyses of Studies That Evaluate Healthcare Interventions: Explanation and Elaboration. *BMJ* **2009**, *339*, b2700. https://doi.org/10.1136/bmj.b2700.
60. Aman, C.; Azevedo, B.; Bednar, E.; Chandiramami, S.; German, D.; Nicholson, E.; Nicholson, K.; Scarfe, W.C. Apical Root Resorption during Orthodontic Treatment with Clear Aligners: A Retrospective Study Using Cone-Beam Computed Tomography. *Am. J. Orthod. Dentofac. Orthop.* **2018**, *153*, 842–851. https://doi.org/10.1016/j.ajodo.2017.10.026.
61. Yi, J.; Xiao, J.; Li, Y.; Li, X.; Zhao, Z. External Apical Root Resorption in Non-Extraction Cases after Clear Aligner Therapy or Fixed Orthodontic Treatment. *J. Dent. Sci.* **2018**, *13*, 48–53. https://doi.org/10.1016/j.jds.2017.09.007.
62. Liu, W.; Shao, J.; Li, S.; Al-Balaa, M.; Xia, L.; Li, H.; Hua, X. Volumetric Cone-Beam Computed Tomography Evaluation and Risk Factor Analysis of External Apical Root Resorption with Clear Aligner Therapy. *Angle Orthod.* **2021**, *91*, 597–603. https://doi.org/10.2319/111820-943.1.
63. Toyokawa-Sperandio, K.C.; Conti, A.C.d.C.F.; Fernandes, T.M.F.; Almeida-Pedrin, R.R.; Almeida, M.R.; Oltramari, P.V.P. External Apical Root Resorption 6 Months after Initiation of Orthodontic Treatment: A Randomized Clinical Trial Comparing Fixed Appliances and Orthodontic Aligners. *Korean J. Orthod.* **2021**, *51*, 329–336. https://doi.org/10.4041/kjod.2021.51.5.329.
64. Almagrami, I.; Almashraqi, A.A.; Almaqrami, B.S.; Mohamed, A.S.; Wafaie, K.; Al-Balaa, M.; Qiao, Y. A Quantitative Three-Dimensional Comparative Study of Alveolar Bone Changes and Apical Root Resorption between Clear Aligners and Fixed Orthodontic Appliances. *Prog. Orthod.* **2023**, *24*, 6. https://doi.org/10.1186/s40510-023-00458-3.
65. Alqadasi, B.; Xia, H.Y.; Alhammadi, M.S.; Hasan, H.; Aldhorae, K.; Halboub, E. Three-Dimensional Assessment of Accelerating Orthodontic Tooth Movement-Micro-Osteoperforations vs. Piezocision: A Randomized, Parallel-Group and Split-Mouth Controlled Clinical Trial. *Orthod. Craniofac. Res.* **2021**, *24*, 335–343. https://doi.org/10.1111/ocr.12437.
66. Patianna, A.G.; Ballini, A.; Meneghello, M.; Cantore, S.; Inchingolo, A.M.; Dipalma, G.; Inchingolo, A.D.; Inchingolo, F.; Malcangi, G.; Lucchese, A.; et al. Comparison of Conventional Orthognathic Surgery and "Surgery-First" Protocol: A New Weapon against Time. *J. Biol. Regul. Homeost. Agents* **2019**, *33*, 59–67.
67. Inchingolo, A.D.; Patano, A.; Coloccia, G.; Ceci, S.; Inchingolo, A.M.; Marinelli, G.; Malcangi, G.; Di Pede, C.; Garibaldi, M.; Ciocia, A.M.; et al. Treatment of Class III Malocclusion and Anterior Crossbite with Aligners: A Case Report. *Medicina* **2022**, *58*, 603. https://doi.org/10.3390/medicina58050603.
68. Pasciuti, E.; Coloccia, G.; Inchingolo, A.D.; Patano, A.; Ceci, S.; Bordea, I.R.; Cardarelli, F.; Venere, D.D.; Inchingolo, F.; Dipalma, G. Deep Bite Treatment with Aligners: A New Protocol. *Appl. Sci.* **2022**, *12*, 6709. https://doi.org/10.3390/app12136709.
69. Patano, A.; Malcangi, G.; Inchingolo, A.D.; Garofoli, G.; De Leonardis, N.; Azzollini, D.; Latini, G.; Mancini, A.; Carpentiere, V.; Laudadio, C.; et al. Mandibular Crowding: Diagnosis and Management—A Scoping Review. *J. Pers. Med.* **2023**, *13*, 774. https://doi.org/10.3390/jpm13050774.