applied sciences

MDPI

Article

Safety and Efficacy of a Modified Technique of Holmium Laser Enucleation of the Prostate (HoLEP) for Benign Prostatic Hyperplasia

Giovanni Cochetti, Michele Del Zingaro, Mattia Panciarola, Alessio Paladini *, Paolo Guiggi, Sara Ciarletti, Andrea Nogara, Morena Turco, Matteo Marsico, Graziano Felici, Giuseppe Maiolino, Gianluca Gaudio and Ettore Mearini

Department of Medicine and Surgery, Urology Clinic, University of Perugia, 06129 Perugia, Italy; giovannicochetti@libero.it (G.C.); michele.delzingaro@ospedale.perugia.it (M.D.Z.); mattia.panciarola@studenti.unipg.it (M.P.); paologuiggi@libero.it (P.G.); sara.ciarletti@studenti.unipg.it (S.C.); andrea.nogara@studenti.unipg.it (A.N.); morena.turco@ospedale.perugia.it (M.T.); matteo.marsico@studenti.unipg.it (M.M.); graziano.felici@studenti.unipg.it (G.F.); giuseppe.maiolino@studenti.unipg.it (G.M.); gianluca.gaudio@studenti.unipg.it (G.G.); ettore.mearini@unipg.it (E.M.)

* Correspondence: alessiopaladini89@gmail.com or alessio.paladini@ospedale.perugia.it; Tel.: +39-3475526984

Abstract: Holmium laser enucleation of the prostate (HoLEP) is a valid alternative to transurethral resection of the prostate and open simple prostatectomy for the treatment of a larger prostate, demonstrating comparable efficacy and lower morbidity. One of the most bothersome symptoms after HoLEP is urinary incontinence (UI), which is present in almost 20% of patients, with a recovery rate of over 80% at 3 months. A relevant risk factor linked to UI is the damage of the external sphincter during the enucleation of adenoma tissue close to it. In our modified HoLEP technique named Cap HoLEP, we preserve the anterior prostate portion proximal to the external sphincter. This cap of adenoma could reduce mechanical stress and laser energy widespread on the sphincter, acting as a protective barrier. The aim of this study was to describe the Cap HoLEP technique and to evaluate its safety and efficacy by assessing peri-operative and functional outcomes. We enrolled all patients who consecutively underwent Cap HoLEP from December 2017 to October 2019 in our hospital. Baseline characteristics; the International Prostate Symptom Score; uroflow findings; intraoperative data, intraoperative, and postoperative complications; and UI were all assessed. The median operative time was 122 min with 138 kJ of laser energy delivered. Median ΔHb was 0.8 gr/dL. Seven low-grade complications were recorded. At 1 month, 34.8% of patients presented UI, 16.7% urge incontinence, 13.6% stress incontinence, and 4.5% mixed incontinence. At 3 months, UI showed a significant improvement, decreasing to 12.1%. At 6 and 12 months, UI was 7.6% and 3%, respectively. Our modified HoLEP technique is safe and effective, allowing significant improvement in the postoperative UI rate.

Keywords: holmium; laser therapy; prostatic hyperplasia; prostate; lower urinary tract symptoms; urinary incontinence

check for updates

Citation: Cochetti, G.; Del Zingaro, M.; Panciarola, M.; Paladini, A.; Guiggi, P.; Ciarletti, S.; Nogara, A.; Turco, M.; Marsico, M.; Felici, G.; et al. Safety and Efficacy of a Modified Technique of Holmium Laser Enucleation of the Prostate (HoLEP) for Benign Prostatic Hyperplasia. *Appl. Sci.* **2021**, *11*, 2467. https://doi.org/10.3390/app11062467

Academic Editor: George Mylonas

Received: 1 January 2021
Accepted: 8 March 2021
Published: 10 March 2021

Publisher's Note: MDPI stays neutral with regard to jurisdictional claims in published maps and institutional affiliations.

Copyright: © 2021 by the authors. Licensee MDPI, Basel, Switzerland. This article is an open access article distributed under the terms and conditions of the Creative Commons Attribution (CC BY) license (https://creativecommons.org/licenses/by/4.0/).

1. Introduction

Lower urinary tract symptoms (LUTS) secondary to bladder outlet obstruction (BOO) due to benign prostatic hyperplasia (BPH) are one of the most common problems affecting aging men, with almost 80% of men older than 70 years affected [1,2]. Although historically, transurethral resection of the prostate (TURP) and open simple prostatectomy (OSP) for a larger prostate have been considered the gold standard in the treatment of symptomatic BPH for many years [3], the contemporary literature indicates that laser enucleation of the prostate—whether holmium (HoLEP) or thulium (ThuLEP)—is a valid alternative to TURP and OSP as the size-independent best surgical option for BPH treatment [4], demonstrating

at least comparable efficacy and significantly decreased morbidity [5–7]. The literature highlights the efficacy, durability, and favorable risk profile of HoLEP, proposing it as a valid option also in patients who are not candidates for other procedures due to age, prostate size, or bleeding risk [8–10]. One of the most bothersome symptoms after HoLEP is urinary incontinence (UI), which is present in almost 20% of patients with a recovery rate of over 80% at 3 months. Generally, it is mixed stress and urge urinary incontinence, and anticholinergic or anti-inflammatory drugs in combination with pelvic floor muscle training could be efficacious. The main risk factors linked to UI are the operation time, large prostate volume, patient age, preoperative detrusor overactivity, and damage of the external sphincter due to mechanical and thermal stress during the enucleation of adenoma tissue close to it [11]. In our modified HoLEP technique named Cap HoLEP, we preserve the anterior prostate portion proximal to the external sphincter. This cap of adenoma can reduce the mechanical stress and laser energy widespread on the sphincter, acting as a protective barrier. The aim of this study was to describe our Cap HoLEP technique and to evaluate its safety and efficacy by assessing peri-operative and functional outcomes.

2. Materials and Methods

In this retrospective study, we collected data of all patients who consecutively underwent HoLEP from December 2017 to October 2019 in our high-volume tertiary hospital. The study was conducted according to the guidelines of the Declaration of Helsinki and approved by the ethics committee (CEAS n. 3154/18). Written informed consent was obtained from all patients. All procedures were performed by a single HoLEP-naive urologist with high endoscopic experience, tutored by a skilled HoLEP surgeon for the first 18 cases. Inclusion criteria were patients with prostate volume of $\geq$30 mL, moderate/severe LUTS, pathologic uroflow parameters and/or significant post-void residual (PVR), and a negative urine sample culture. Exclusion criteria included the first 25 patients treated during the learning curve; patients with asymptomatic BPH, prostate volume of <30 mL, prostate cancer (PCa) on prostate biopsy, and ongoing urinary tract infection (UTI); and unfit for surgical treatment. All data were retrospectively analyzed.

Preoperative baseline characteristics such as age, drugs, LUTS, and history of urinary retention were collected. A digital rectal examination, ultrasound of the urinary system, prostate transrectal ultrasound, prostate-specific antigen (PSA) dosage, uroflow test, prostate MRI, and/or biopsy, when indicated, were performed before surgery. The International Prostate Symptom Score (IPSS) was used to objectify LUTS. Uroflow findings, including the maximum flow rate (Qmax) and post-void residual urine, were considered pathologic when they were $\leq$15 mL/s and $\geq$50 mL, respectively.

We evaluated the operative time (OT), delivered amount of energy (DaE), intraoperative bleeding, time to catheter removal, intra- and postoperative complications, and length of stay (LOS). Intraoperative complications were reported according to the Intraoperative Adverse Incident Classification by the European Association of Urology (EAUiaiC) ad hoc Complications Guidelines Panel [12]. Intraoperative bleeding was estimated by calculating the difference between preoperative and postoperative (at 24 h after surgery) hemoglobin (Hb) values. Postoperative complications were assessed according to the Clavien–Dindo classification.

The postoperative outcomes were assessed as follows: evaluation of LUTS at 1, 3, 6, and 12 months, including urinary incontinence, as defined by the International Continence Society [13]; the IPSS; uroflow parameters at 1, 3, and 6 months from surgery; postoperative serum PSA at 3 months; and detection of incidental PCa (iPCa).

A descriptive statistical analysis summarizes the data of our study. Continuous variables are presented as the median value and interquartile range (IQR) and qualitative variables as a frequency and percentage. We performed univariate and multivariate analyses (logistic regression) to identify potential predicted factors for UI at one postoperative month with preoperative variables. All reported *p*-values are two sided, and statistical

significance was set at 0.05. Statistical analysis was performed using SPSS v.25 software (IBM Corp., Armunch, NY, USA).

Surgical Technique

All procedures were performed under general anesthesia. A single preoperative dose of 2 grof intravenous ceftriaxone antibiotic prophylaxis was administered 30 min before the procedure according to patient allergies and renal function. Heparin and mechanical prophylaxis were administered when thromboembolic risk was significant [14]. The patient was placed in the lithotomic position.

The procedure was performed using a 26-French Iglesias continuous-saline-flow resectoscope with a laser bridge, while morcellation was carried out by a tissue morcellator (Lumenis VersaCut system). A 120-watt Ho:YAG laser (VersaPulse Select, Lumenis Inc., Yokneam, Israel) and a 550-micron end-firing laser fiber (SlimLine 550, Lumenis Inc.) were used with an energy setting of 2 Joules (J) and frequency settings of 60 and 30 Hertz (Hz) for cutting and hemostasis, respectively. After performing a urethro-cystoscopy to exclude bladder and urethral disease and to assess low urinary tract anatomy, the ureteral orifices, bladder neck, and veru montanum were identified. The prostatic adenoma was enucleated using a two-lobe or a three-lobe technique, depending on the presence or absence of the median lobe.

The first step in our technique consists of mucosal incision on the prostate roof, about 1 cm from the external sphincter between the 10 and 2 o'clock positions (Figure 1). Subsequently, two incisions were performed in the para-collicular site at the 5 and 7 o'clock positions in order to identify the dissection plane (Figure 2); then, we carried two incisions at the 5 and 7 o'clock positions proximally at the bladder neck in the case of the three-lobe technique or only on one side in the case of the two-lobe technique (Figure 3). The incision was carried on in depth until circular fibers of the bladder neck were visible and then were joined to those proximal to the veru montanum. The enucleation was carried out by the two- or three-lobe standard technique. At the time of enucleation of the roof of the adenoma from the external urinary sphincter, we spared a portion of adenoma 1 cm proximal to the external sphincter using the mucosal incision between the 10 and 2 o'clock positions. This residual adenoma serves as a cap to protect the external sphincter (Figures 4–6). Enucleated tissue was then removed by a morcellator.

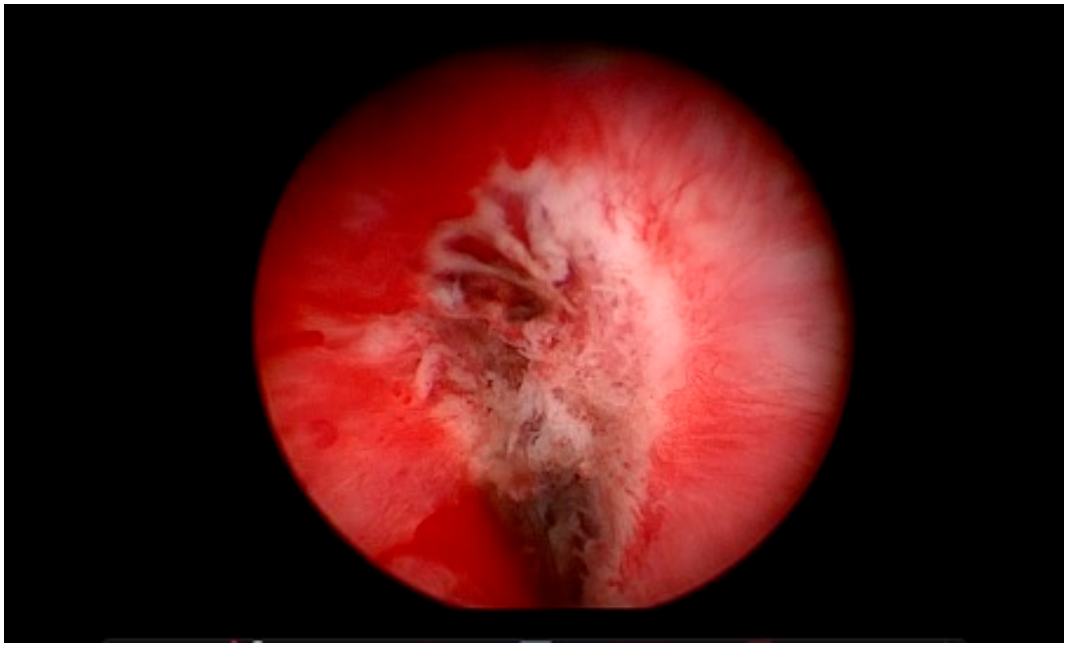

Figure 1. Laser mucosal incision on the prostate roof about 1 cm from the external sphincter between the 10 and 2 o'clock positions.

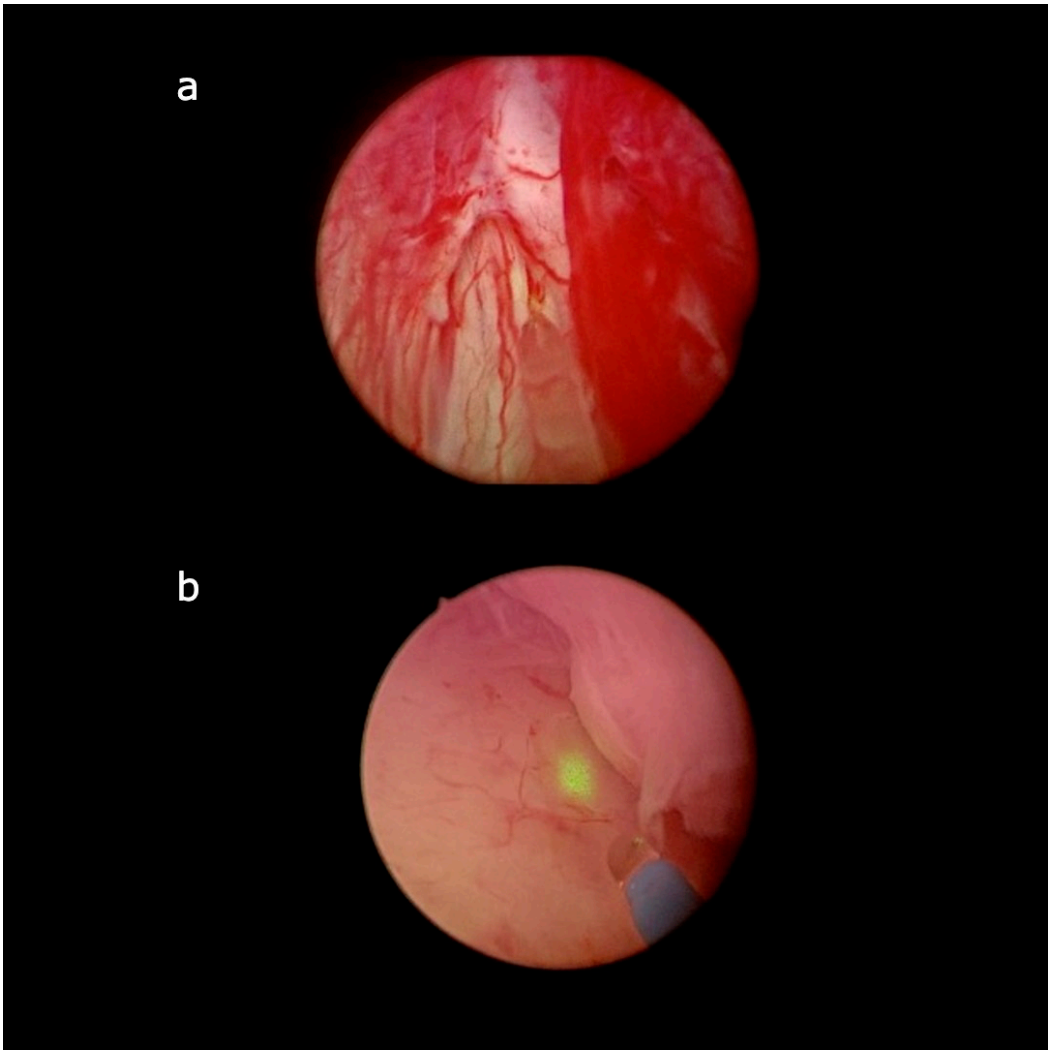

Figure 2. Para-collicular incision site (**a**) at the 5 and 7 o'clock positions to identify the dissection plane (**b**).

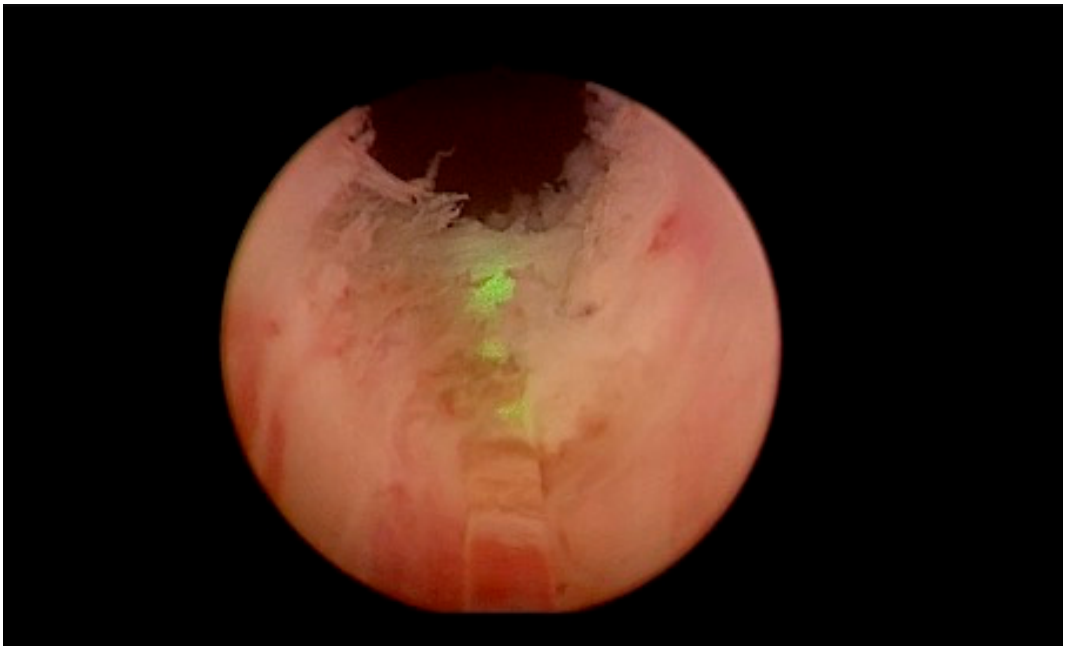

Figure 3. Bladder neck incision.

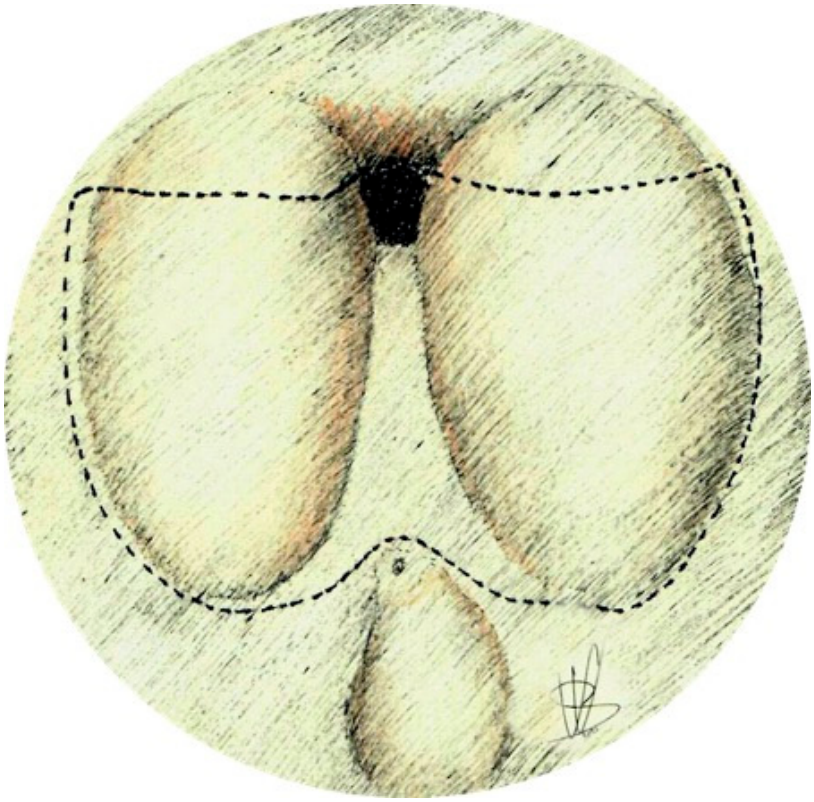

Figure 4. Graphical representation of an endoscopic adenoma incision.

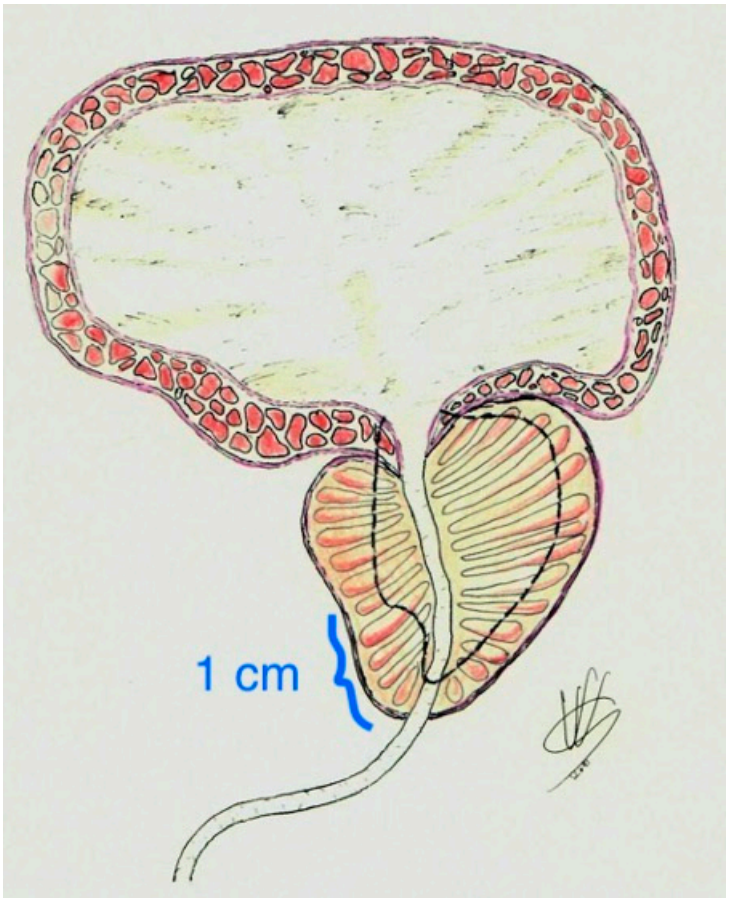

Figure 5. Graphical representation of the adenoma Cap HoLEP technique.

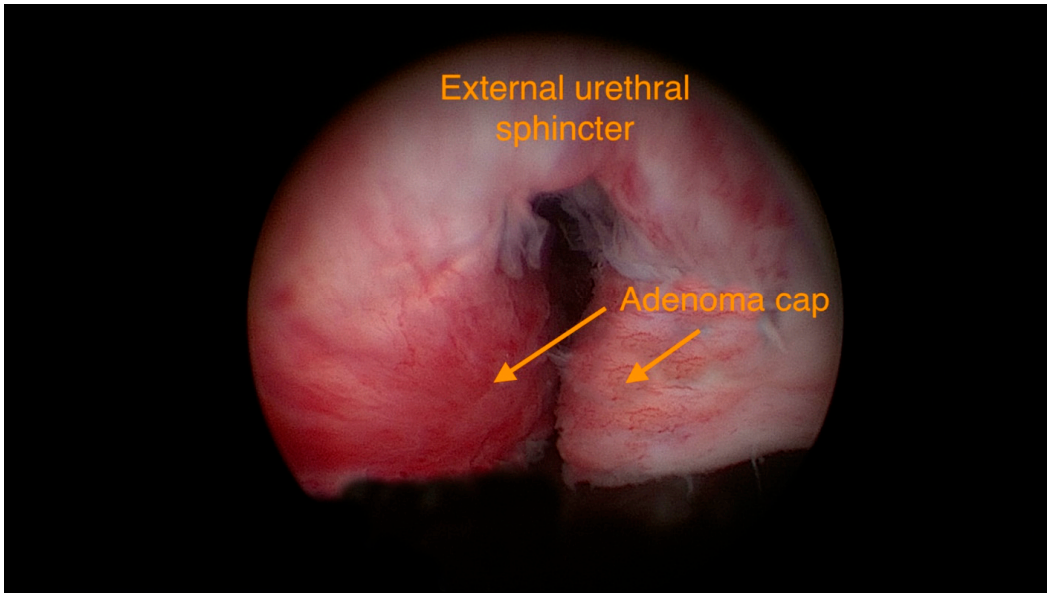

Figure 6. Final result: endoscopic view.

3. Results

A total of 66 patients were enrolled. Preoperative characteristics are listed in Table 1.

Table 1. Patients' characteristics.

Characteristic	Value
Mean age, years (range)	69.1 (60–78)
Previous alpha-blockers, *n* (%)	63 (95%)
History of urinary retention, *n* (%)	21 (32%)
Mean serum PSA, ng/mL (range)	4.28 (2.5–6.39)
Mean prostate volume, mL (range)	86 (61–110)
Mean Qmax, mL/s (range)	10.7 (7–14)
Mean PVR, mL (range)	65 (30–100)
IPSS, points (range)	21 (12.5–24.5)
IIEF-5 (range 4–31)	16.3 (2–25)

PSA: prostate-specific antigen; Qmax: maximum flow rate; PVR: post-void residual; IIEF-5: 5-item version of the International Index of Erectile Function.

The mean patient age was 69.1 years (range 55–82). About one-third (32%) of the patients had a history of at least one episode of urinary retention prior to surgery. The prostate volume was higher than 60 mL in 76.7% of patients, with a mean prostate volume of 91 mL (range 40–202). The mean values of Qmax and PVR were 10.3 mL/s (range 4–14) and 80 mL (range 0–250), respectively. Preoperatively, the IPSS and International Index of Erectile Function 5-item (IIEF-5) assessment resulted in values of 19.3 (range 4–31) and 16.3 (range 2–25), respectively. The mean preoperative PSA was 4.9 ng/mL (range 0.31–22). Intra- and peri-operative data are shown in Table 2.

In our series, the median OT was 122 min (range 95–153), the median DaE was 138 kJ, (range 105–165), and the median ΔHb was 0.8 gr/dL (range (0.3–2.1)). The median percentage of enucleated tissue was 61% (range 42–70%). The catheterization time and LOS were 32 h (range 24–55) and 48 h (range 24–86), respectively. The mean postoperative PSA value was 0.77 ng/mL (range 0.05–2.91). The detection rate of iPCa was 3%: one patient was diagnosed with an adenocarcinoma Gleason score (GS) of 3+3 pT1a, while in another case, a stromal tumor of uncertain malignant potential (STUMP) was incidentally found. In both cases, a conservative watchful waiting strategy was carried out. The overall complication rate was 7/66 (10.5%). A small bladder perforation (grade 1 EAUiaiC) occurred during the

morcellator phase, which was treated by an indwelling bladder catheter for four days. No conversion to TURP or OSP occurred.

Table 2. Intra- and peri-operative data.

Variable	Value
Operative time, minutes (range)	122 (95–153)
Mean DaE, kilojoules (range)	138 (105–165)
ΔHb, g/dL (range)	0.8 (0.3–2.1)
Median % of enucleated tissue (range)	61% (42–70%)
Median catheterization, hours (range)	32 (25–55)
Mean LOS, hours (IQR)	48 (24–86)

DaE: delivered amount of energy; LOS: length of stay; iPCA: detection of incidental prostate cancer.

One (1.5%) intra-operative complication, a bladder perforation during the morcellation time, occurred. Postoperative complications (Table 3) were 6/66 (9%), and all were of grade II according to the Clavien–Dindo classification: one patient (1.5%) developed thrombophlebitis of the lower extremity, which was treated with cortisone and heparin therapy; two patients (3%) were recatheterized for acute urinary retention and were discharged with a Foley catheter, which was removed after 4 days; and one patient (1.5%) experienced urethral stricture, thus needing urethro-cystoscopy with concomitant urethral dilatation. Two patients (3%) reported UTI in the postoperative period; they were successfully treated by adequate antibiotic therapy. At a median follow-up of 15 months (range 1–24), there were no cases of reoperation or sclerosis of the bladder neck/prostatic loggia.

Table 3. Intra- and postoperative complications.

Event	Value	EAUiaiC (Grade)	Clavien–Dindo (Grade)
Bladder perforation	1 (1.5%)	1	-
Thrombophlebitis	1 (1.5%)	-	II
Acute urinary retention	2 (3%)	-	II
Urethral stricture	1 (1.5%)	-	II
UTI	2 (3%)	-	II

UTIs: urinary tract infections; EAUiaiC, Intraoperative Adverse Incident Classification by the European Association of Urology.

Concerning the functional outcomes (Table 4), the mean Qmax and PVR at 1 month were 28 mL/s (range 7–63) and 12 mL (range 0–100), respectively, with subsequent further improvements at 6 months with mean values of 35 mL/s (range 15–68) and 5 mL (range 0–38), respectively. At 1, 3, and 6 months, the IPSS and the IIEF-5 were 11.4 (range 2–25) and 13.8 (range 0–25), 4.3 (range 2–11) and 16.1 (range 0–25), and 2.7 (range 0–16) and 15.3 (range 0–25), respectively. At the first postoperative month, 23/66 (34.8%) of the patients were affected by UI, narrowly 16.7% by UUI, 13.6% by stress urinary incontinence (SUI), and 4.5% by mixed urinary incontinence (MUI). This transient UI showed a significant improvement at 3 and 6 months: UI was 12.1% (UUI = 3%, SUI = 9.1%) and 7.6% (UUI = 1.5%, SUI = 6.1%), respectively. At 12 postoperative months, UI was 3%, of which UUI was 1.5% and SUI 1.5%. To identify any potential predictor associated with detection of UI at the first postoperative month, univariate and multivariate analyses were performed (Table 5). Age (years), prostate volume (mm^3), and IPSS (total score) were significantly correlated with UI at the first postoperative month ($p < 0.05$). Further multivariate analysis revealed that only the prostate volume and IPSS score were independent predictive factors of UI at the first postoperative month ($p = 0.01$, OR = 1.05; $p = 0.001$, OR = 1.60; OR: Odds Ratio). For every cubic centimeter of prostate volume, the risk of UI at one postoperative month increases by 5%, and for every 1 point on the IPSS, the risk of UI at one postoperative month increases by 60%.

Table 4. Functional outcomes.

Variable	1 Month	3 Months	6 Months	12 Months
Median Qmax, mL/s (range)	24.5 (17.25–40.5)	25 (18.5–39)	27 (19.5–36)	26 (19–38)
Median PVR, mL (range)	0 (0–20)	0 (0–22)	0 (0–28)	0 (0–24)
Median IPSS, pt. (range)	10.5 (8–14.5)	5 (2.5–6.5)	5 (2–8)	5 (2–10)
UI, *n* (%)	23 (34.8%)	8 (12.1%)	5 (7.6%)	2 (3%)
UUI, *n* (%)	11 (16.7%)	2 (3%)	1 (1.5%)	1 (1.5%)
SUI, *n* (%)	9 (13.6%)	6 (9.1%)	4 (6.1%)	1 (1.5%)
MUI, *n* (%)	3 (4.5%)	0 (0%)	0 (0%)	0 (0%)

Qmax: maximum flow rate; IQR: interquartile range; PVR: post-void residual; IPSS: International Prostate Symptom Score; UI: urinary incontinence; UUI: urge urinary incontinence; SUI: stress urinary incontinence; MUI: mixed urinary incontinence.

Table 5. Univariate and multivariate analyses (logistic regression) predicting UI at one month with preoperative variables.

Variable	UI at One Postoperative Month		
	Univariate Analysis	Multivariate Analysis	
	p-Value	*p*-Value	OR (95% CI)
Age (years)	*0.008* *	0.20	1.09 (0.95–1.24)
Serum PSA (ng/mL)	0.61	0.64	1.08 (0.95–1.24)
Prostate volume (mm^3)	*0.012* *	*0.01**	1.05 (1.01–1.10)
Previous alpha-blockers (yes vs. no)	0.51	0.99	1.04 (0.01–433.54)
Qmax (mL/s)	0.49	0.64	1.05 (0.85–1.30)
PVR (mL)	0.91	0.35	0.99 (0.97–1.01)
IPSS (total score)	*<0.001* *	*0.001* *	1.60 (1.20–2.12)
IIEF-5 (total score)	0.667	0.49	1.08 (0.85–1.39)
Operative time (min)	0.83	0.06	0.98 (0.96–1.00)
DaE (kJ)	0.44	0.43	1.00 (0.99–1.02)
Catheterization (hours)	0.41	0.06	2.72 (0.96–7.67)

UI: urinary incontinence; Qmax: maximum flow rate; PVR: post-void residual; IPSS: International Prostate Symptom Score; IIEF-5: International Index of Erectile Function 5-item; DaE: delivered amount of energy; OR: Odds Ratio; *: significant value.

4. Discussion

To date, HoLEP represents an effective and safe surgical option for the treatment of BPH, resulting in a valid alternative to TURP and OSP. During HoLEP, the adenoma is completely enucleated from the surgical capsule and displaced into the bladder before removal by a transurethral soft-tissue morcellator [15]. By taking advantage of the distinct anatomical planes to remove the entire prostatic transition zone, the HoLEP technique allows removal of more tissue than through TURP, thus leading to a lower retreatment rate [16]. As regard the durability of outcomes, several studies have shown they are stable up to a 10-year follow-up [17], similarly to those of OSP [18]. Conversely, compared to HoLEP, TURP provides lower long-term outcomes and, consequently, a higher reoperation rate [7,19]. The main obstacle to the widespread use of HoLEP lies in the steepness of the learning curve, estimated from 20 to 50 cases, depending on the presence of a mentorship program [20–22]. HoLEP allows a less restricted selection of patients [3], extending the eligibility for surgery to those with smaller and larger glands [23–26], to the elderly [27], to those on antithrombotic or antiplatelet therapy [28–31], to men with obstructive BPH and urodynamic evidence of detrusor hypo- or acontractility [32], to cases requiring reoperation for adenoma regrowth after prior BPH surgery [33,34], as well as concomitant surgery for other pathologies [35–37], including bladder stones, which can advantageously be treated using the same instrument [38,39]. Moreover, HoLEP does not appear to be affected by previous prostate biopsy, allowing its possible use also in patients with prostate cancer under active surveillance [40].

One of the advantages of HoLEP is to be less bleeding in comparison to OSP and TURP. In our study cohort, median bleeding was evaluated by calculating the difference between preoperative and postoperative (at 24 h after surgery) Hb values and it was about 0.8 gr/dL. The reduced risk of intra- and postoperative bleeding is due to enucleation performed by developing the natural plane between adenoma and the peripheral zone. Consequently, HoLEP can also be safely performed in patients under anticoagulant or antiplatelet therapy [30]. In our experience, anticoagulant and antiplatelet therapies have been discontinued in all patients except those at greater thromboembolic risk, in whom they have been switched to low-molecular-weight heparin therapy.

In our series, the mean operative time was 122 min, longer than that reported by Ryoo et al. [41] and Alkan et al. [42] in their experiences (79 min and 97 min, respectively), probably due to the greater mean prostate volume of our cases (91 mL vs. 66 mL and 75 mL) as well as the inclusion of learning curve cases of this new technique. The median catheterization time and LOS were 32 h and 48 h, respectively, compared to 1.8–3.9 days reported by Ryoo et al. and 2 days reported by Porreca et al. [43]. HoLEP, as well as TURP, OSP, and other endoscopic enucleation of the prostate, allows performing the histological examination of the removed tissue. Our findings showed an iPCa detection rate of 3%. This result is in line with data of the literature, reporting a detection rate of 5.6–8.1% [44]. Unfortunately, the short duration of our follow-up did not allow to evaluate the medium- and long-term oncological outcomes of our patients.

Regarding complications, we reported an overall complication rate of 10.6%, all minor grade. These findings are consistent with those reported in the literature, showing a range of 12–17% [19]. No patient needed any re-intervention during the follow-up, thus demonstrating the mid-term durability of the effectiveness of HoLEP.

Concerning functional outcomes, our results are comparable to those found in the literature. Elmansy [45] and Chen [46] reported a mean postoperative increase of Qmax of 16 mL/s and 20 mL/s, respectively, while the IPSS decreased by 18 and 15.4 points, respectively. In our study, the mean increase of Qmax was 17.7 mL/s at 1 month, with further 7 mL/s improvement at 6 months. The IPSS decreased by 7.9 points after 1 month and then by a further 7.1 and 1.6 points at 3 and 6 months, respectively.

The postoperative continence status is one of the most important goals of HoLEP, and different techniques have been described to improve this outcome by reducing the potential damage of the external urinary sphincter, which is a key factor for continence. However, currently, which of these techniques is the gold standard has not been established. Endo et al. described a decreased transient SUI rate to 2.7% through their anteroposterior dissection HoLEP technique, which reproduces the steps of the antegrade open simple prostatectomy procedure in order to prevent damage to the external sphincter [47]. This technique appeared safe and effective also for inexperienced surgeons according to Anan et al., who also demonstrated an improvement in terms of continence by preoperative pelvic floor muscle training [48,49].

An anatomical study by Wallner et al. demonstrated that the superior part of the external sphincter covers the anterior parts of the prostate and urethra, with a larger contact surface at the level of the 10–2 o'clock positions [50]. We feel that the increased risk for SUI following HoLEP could be due to both widespread laser energy and the mechanical stretching of the sphincter during apical dissection. The most important step in our technique is the early incision of the mucosa that is performed about 1 cm proximal to the sphincter between the 10 and 2 o'clock positions, leaving a small part of the anterior adenoma attached to the sphincter. This cap of the adenoma tissue should contribute to better preservation of the sphincter structure, reducing the damage related to laser energy and mechanical stretching. In our series, at the first postoperative month postoperatively, the UI rate was 34.8%, of which 16.7% was UUI, 13.6% SUI, and 4.5% MUI. This transient UI decreased to 12.1%, 7.6%, and 3% at 3, 6, and 12 months, respectively. In particular, the SUI rate was 9%, 6%, 4%, and 1.5% at 1, 3, 6, and 12 months, respectively. By univariate analysis, we found that the age, prostate volume, and IPSS were significantly

correlated with UI at the first postoperative month. Further multivariate analysis confirmed the prostate volume and IPSS score as independent predictive factors of UI at the first postoperative month. The progressive improvement of urinary continence, especially at 3 months, could be due to the resolution of neuropraxia and the inflammation related to the intervention, leading to progressive restoration of the physiological activity and function of the sphincter structure. Our findings are almost comparable to those of other studies, especially considering the small sample size as well as the inclusion in our series also of the first cases of this new technique. Recently, Houssin et al. conducted an observational multicentric study evaluating UI at 3 and 6 months after Holep in 2346 patients, which is the largest series reported in the literature. The authors found that UI occurred in 14.5% of patients at 3 months and 4.2% at 6 months. The authors suggested that surgeon experience and diabetes disorder were the main predictive factors of early and persistent UI, respectively [51].

In a prospective study including 330 consecutive cases of HoLEP, Vavassori et al. [52] reported a transient (within 3 months) SUI rate of 7.3% and a persistent (at 36 months) SUI rate of 0.6%. In a recent retrospective study, Tunc described a personal technique named the Omega sign, like ours and consisting of an incision of the mucosa between the 2 and 10 o'clock positions in the anterior part of the prostate that was performed as the first step before beginning the enucleation. The authors reported an SUI rate of 3% and 1% at the removal of the catheter and at the first postoperative month, respectively. The authors believe that this exciting result is due to the early release of the sphincter from the prostate apex [53]. The main limitations of our study were the retrospective nature, the small sample size, and the relatively short follow-up.

5. Conclusions

Our findings show the safety and efficacy of our modified HoLEP technique in the surgical treatment of symptomatic BPH. We strongly believe that the preservation of anterior adenoma cap close to external sphincter could significantly improve the postoperative urinary continence rate.

Author Contributions: Conceptualization, G.C., E.M., and M.D.Z.; methodology, A.P.; formal analysis, G.M.; investigation, M.P., P.G., and S.C.; data curation, G.F.; writing—original draft preparation, G.C.; writing—review and editing, A.N., M.T., and M.M.; supervision, M.D.Z., G.G.; project administration, E.M. All authors have read and agreed to the published version of the manuscript.

Funding: This research received no external funding.

Institutional Review Board Statement: The study was conducted according to the guidelines of the Declaration of Helsinki and approved by the ethics committee (CEAS n. 3154/18).

Informed Consent Statement: Informed consent was obtained from all subjects involved in the study.

Data Availability Statement: Data are available on request due to privacy restrictions.

Conflicts of Interest: The authors declare no conflict of interest.

References

1. Wei, J.T.; Calhoun, E.; Jacobsen, S.J. Urologic Diseases in America Project: Benign Prostatic Hyperplasia. *J. Urol.* **2005**, *173*, 1256–1261. [CrossRef]
2. Cochetti, G.; Poli, G.; Guelfi, G.; Boni, A.; Egidi, M.G.; Mearini, E. Different levels of serum microRNAs in prostate cancer and benign prostatic hyperplasia: Evaluation of potential diagnostic and prognostic role. *OncoTargets Ther.* **2016**, *9*, 7545–7553. [CrossRef] [PubMed]
3. McVary, K.T.; Roehrborn, C.G.; Avins, A.L.; Barry, M.J.; Bruskewitz, R.C.; Donnell, R.F.; Foster, H.E.; Gonzalez, C.M.; Kaplan, S.A.; Penson, D.F.; et al. Update on AUA Guideline on the Management of Benign Prostatic Hyperplasia. *J. Urol.* **2011**, *185*, 1793–1803. [CrossRef] [PubMed]
4. Foster, H.E.; Barry, M.J.; Dahm, P.; Gandhi, M.C.; Kaplan, S.A.; Kohler, T.S.; Lerner, L.B.; Lightner, D.J.; Parsons, J.K.; Roehrborn, C.G.; et al. Surgical Management of Lower Urinary Tract Symptoms Attributed to Benign Prostatic Hyperplasia: AUA Guideline. *J. Urol.* **2018**, *200*, 612–619. [CrossRef] [PubMed]

5. Michalak, J.; Tzou, D.; Funk, J. HoLEP: The gold standard for the surgical management of BPH in the 21st Century. *Am. J. Clin. Exp. Urol.* **2015**, *3*, 36–42. [PubMed]
6. Jones, P.; Alzweri, L.; Rai, B.P.; Somani, B.K.; Bates, C.; Aboumarzouk, O.M. Holmium laser enucleation versus simple prostatectomy for treating large prostates: Results of a systematic review and meta-analysis. *Arab. J. Urol.* **2016**, *14*, 50–58. [CrossRef] [PubMed]
7. Gilling, P.J.; Wilson, L.C.; King, C.J.; Westenberg, A.M.; Frampton, C.M.; Fraundorfer, M.R. Long-term results of a randomized trial comparing holmium laser enucleation of the prostate and transurethral resection of the prostate: Results at 7 years. *BJU Int.* **2011**, *109*, 408–411. [CrossRef]
8. Mmeje, C.O.; Nunez-Nateras, R.; Warner, J.N.; Humphreys, M.R. Age-stratified outcomes of holmium laser enucleation of the prostate. *BJU Int.* **2013**, *112*, 982–989. [CrossRef]
9. Krambeck, A.E.; Handa, S.E.; Lingeman, J.E. Holmium Laser Enucleation of the Prostate for Prostates Larger Than 175 Grams. *J. Endourol.* **2010**, *24*, 433–437. [CrossRef] [PubMed]
10. Humphreys, M.R.; Miller, N.L.; Handa, S.E.; Terry, C.; Munch, L.C.; Lingeman, J.E. Holmium Laser Enucleation of the Prostate—Outcomes Independent of Prostate Size? *J. Urol.* **2008**, *180*, 2431–2435. [CrossRef]
11. Shigemura, K.; Fujisawa, M. Current status of holmium laser enucleation of the prostate. *Int. J. Urol.* **2017**, *25*, 206–211. [CrossRef]
12. Biyani, C.S.; Pecanka, J.; Rouprêt, M.; Jensen, J.B.; Mitropoulos, D. Intraoperative Adverse Incident Classification (EAUiaiC) by the European Association of Urology ad hoc Complications Guidelines Panel. *Eur. Urol.* **2020**, *77*, 601–610. [CrossRef]
13. D'Ancona, C.; Haylen, B.; Oelke, M.; Abranches-Monteiro, L.; Arnold, E.; Goldman, H.; Hamid, R.; Homma, Y.; Marcelissen, T.; Rademakers, K.; et al. The International Continence Society (ICS) report on the terminology for adult male lower urinary tract and pelvic floor symptoms and dysfunction. *Neurourol. Urodyn.* **2019**, *38*, 433–477. [CrossRef]
14. Tikkinen, K.A.O.; Cartwright, R.; Gould, M.K.; Naspro, R.; Novara, G.; Sandset, P.M.; Violette, P.D.; Guyatt, G.H. EAU Guidelines Thromboprophylaxis in Urological Surgery. In *EAU Guidelines*; European Association of Urology Guidelines Office: Arnhem, The Netherlands, 2020; Available online: https://uroweb.org/guideline/thromboprophylaxis/ (accessed on 5 March 2021).
15. Das, A.K.; Teplitsky, S.; Humphreys, M.R. Holmium laser enucleation of the prostate (HoLEP): A review and update. *Can. J. Urol.* **2019**, *26*, 13–19.
16. Ahyai, S.A.; Chun, F.K.; Lehrich, K.; Dahlem, R.; Zacharias, M.S.; Fisch, M.M.; Kuntz, R.M. Transurethral Holmium Laser Enucleation Versus Transurethral Resection of the Prostate and Simple Open Prostatectomy—Which Procedure is Faster? *J. Urol.* **2012**, *187*, 1608–1613. [CrossRef]
17. Elmansy, H.M.; Kotb, A.; Elhilali, M.M. Holmium Laser Enucleation of the Prostate: Long-Term Durability of Clinical Outcomes and Complication Rates during 10 Years of Followup. *J. Urol.* **2011**, *186*, 1972–1976. [CrossRef] [PubMed]
18. Kuntz, R.M.; Lehrich, K.; Ahyai, S.A. Holmium Laser Enucleation of the Prostate versus Open Prostatectomy for Prostates Greater than 100 Grams: 5-Year Follow-Up Results of a Randomised Clinical Trial. *Eur. Urol.* **2008**, *53*, 160–168. [CrossRef] [PubMed]
19. Gu, M.; Chen, Y.-B.; Liu, C.; Wan, X.; Cai, Z.-K.; Chen, Q.; Wang, Z. Comparison of Holmium Laser Enucleation and Plasmakinetic Resection of Prostate: A Randomized Trial with 72-Month Follow-Up. *J. Endourol.* **2018**, *32*, 139–143. [CrossRef] [PubMed]
20. Peyronnet, B.; Robert, G.; Comat, V.; Rouprêt, M.; Gomez-Sancha, F.; Cornu, J.-N.; Misrai, V. Learning curves and perioperative outcomes after endoscopic enucleation of the prostate: A comparison between GreenLight 532-nm and holmium lasers. *World J. Urol.* **2017**, *35*, 973–983. [CrossRef] [PubMed]
21. Robert, G.; Cornu, J.-N.; Fourmarier, M.; Saussine, C.; Descazeaud, A.; Azzouzi, A.-R.; Vicaut, E.; Lukacs, B. Multicentre prospective evaluation of the learning curve of holmium laser enucleation of the prostate (HoLEP). *BJU Int.* **2016**, *117*, 495–499. [CrossRef] [PubMed]
22. Kampantais, S.; Dimopoulos, P.; Tasleem, A.; Acher, P.; Gordon, K.; Young, A. Assessing the Learning Curve of Holmium Laser Enucleation of Prostate (HoLEP). A Systematic Review. *Urology* **2018**, *120*, 9–22. [CrossRef] [PubMed]
23. Lee, M.H.; Yang, H.J.; Kim, D.S.; Lee, C.H.; Jeon, Y.S. Holmium Laser Enucleation of the Prostate is Effective in the Treatment of Symptomatic Benign Prostatic Hyperplasia of Any Size Including a Small Prostate. *Korean J. Urol.* **2014**, *55*, 737–741. [CrossRef] [PubMed]
24. Shah, H.N.; Sodha, H.S.; Kharodawala, S.J.; Khandkar, A.A.; Hegde, S.S.; Bansal, M.B. Influence of prostate size on the outcome of holmium laser enucleation of the prostate. *BJU Int.* **2008**, *101*, 1536–1541. [CrossRef]
25. Seki, N.; Tatsugami, K.; Naito, S. Holmium Laser Enucleation of the Prostate: Comparison of Outcomes According to Prostate Size in 97 Japanese Patients. *J. Endourol.* **2007**, *21*, 192–196. [CrossRef] [PubMed]
26. Matlaga, B.R.; Kim, S.C.; Kuo, R.L.; Watkins, S.L.; Lingeman, J.E. Holmium laser enucleation of the prostate for prostates of >125 mL. *BJU Int.* **2006**, *97*, 81–84. [CrossRef]
27. Piao, S.; Choo, M.S.; Kim, M.; Jeon, H.J.; Oh, S.-J. Holmium Laser Enucleation of the Prostate is Safe for Patients above 80 Years: A Prospective Study. *Int. Neurourol. J.* **2016**, *20*, 143–150. [CrossRef] [PubMed]
28. El Tayeb, M.M.; Jacob, J.M.; Bhojani, N.; Bammerlin, E.; Lingeman, J.E.; Bammerlin, M.E. Holmium Laser Enucleation of the Prostate in Patients Requiring Anticoagulation. *J. Endourol.* **2016**, *30*, 805–809. [CrossRef]
29. Bishop, C.V.; Liddell, H.; Ischia, J.; Paul, E.; Appu, S.; Frydenberg, M.; Pham, T. Holmium Laser Enucleation of the Prostate: Comparison of Immediate Postoperative Outcomes in Patients with and without Antithrombotic Therapy. *Curr. Urol.* **2013**, *7*, 28–33. [CrossRef]

30. Tyson, M.D.; Lerner, L.B. Safety of Holmium Laser Enucleation of the Prostate in Anticoagulated Patients. *J. Endourol.* **2009**, *23*, 1343–1346. [CrossRef]
31. Elzayat, E.; Habib, E.; Elhilali, M. Holmium Laser Enucleation of the Prostate in Patients on Anticoagulant Therapy or with Bleeding Disorders. *J. Urol.* **2006**, *175*, 1428–1432. [CrossRef]
32. Mitchell, C.R.; Mynderse, L.A.; Lightner, D.J.; Husmann, U.A.; Krambeck, A.E. Efficacy of Holmium Laser Enucleation of the Prostate in Patients With Non-neurogenic Impaired Bladder Contractility: Results of a Prospective Trial. *Urology* **2014**, *83*, 428–432. [CrossRef] [PubMed]
33. Jaeger, C.D.; Krambeck, A.E. Holmium Laser Enucleation of the Prostate for Persistent Lower Urinary Tract Symptoms after Prior Benign Prostatic Hyperplasia Surgery. *Urology* **2013**, *81*, 1025–1029. [CrossRef] [PubMed]
34. ElShal, A.M.; Elmansy, H.M.; Elhilali, M.M. Feasibility of holmium laser enucleation of the prostate (HoLEP) for recurrent/residual benign prostatic hyperplasia (BPH). *BJU Int.* **2012**, *110*, E845–E850. [CrossRef] [PubMed]
35. Patel, A.; Nunez, R.; Mmeje, C.O.; Humphreys, M.R. Safety and feasibility of concomitant surgery during holmium laser enucleation of the prostate (HoLEP). *World J. Urol.* **2014**, *32*, 1543–1549. [CrossRef] [PubMed]
36. Shah, H.N.; Shah, R.H.; Hegde, S.S.; Shah, J.N.; Bansal, M.B. Sequential Holmium Laser Enucleation of the Prostate and Laparoscopic Extraperitoneal Bladder Diverticulectomy: Initial Experience and Review of Literature. *J. Endourol.* **2006**, *20*, 346–350. [CrossRef] [PubMed]
37. Kim, S.C.; Tinmouth, W.W.; Kuo, R.L.; Paterson, R.F.; Lingeman, J.E. Simultaneous Holmium Laser Enucleation of Prostate and Upper-Tract Endourologic Stone Procedures. *J. Endourol.* **2004**, *18*, 971–975. [CrossRef] [PubMed]
38. Tangpaitoon, T.; Marien, T.; Kadihasanoglu, M.; Miller, N.L. Does Cystolitholapaxy at the Time of Holmium Laser Enucleation of the Prostate Affect Outcomes? *Urology* **2017**, *99*, 192–196. [CrossRef] [PubMed]
39. Shah, H.N.; Hegde, S.S.; Shah, J.N.; Mahajan, A.P.; Bansal, M.B. Simultaneous transurethral cystolithotripsy with holmium laser enucleation of the prostate: A prospective feasibility study and review of literature. *BJU Int.* **2007**, *99*, 595–600. [CrossRef]
40. Yılmaz, S.; Kaya, E.; Gazel, E.; Yalcın, S.; Aybal, H.C.; Yılmaz, M.; Açıkgöz, O.; Özdemir, H.; Tunc, L. HoLEP after prostate biopsy: Does it have any impact? *World J. Urol.* **2020**, *10*, 1–7. [CrossRef]
41. Ryoo, H.S.; Suh, Y.S.; Kim, T.H.; Sung, H.H.; Jeong, J.; Lee, K.-S. Efficacy of Holmium Laser Enucleation of the Prostate Based on Patient Preoperative Characteristics. *Int. Neurourol. J.* **2015**, *19*, 278–285. [CrossRef]
42. Alkan, I.; Ozveri, H.; Akin, Y.; Ipekci, T.; Alican, Y. Holmium laser enucleation of the prostate: Surgical, functional, and quality-of-life outcomes upon extended follow-up. *Int. Braz. J. Urol.* **2016**, *42*, 293–301. [CrossRef]
43. Porreca, A.; Giampaoli, M.; Bianchi, L.; D'Agostino, D.; Romagnoli, D.; Bianchi, F.M.; Del Rosso, A.; Corsi, P.; Schiavina, R.; Artibani, W.; et al. Preoperative multiparametric prostate magnetic resonance imaging: A safe clinical practice to reduce incidental prostate cancer in Holmium laser enucleation of the prostate. *Central Eur. J. Urol.* **2019**, *72*, 106–112. [CrossRef]
44. Tominaga, Y.; Sadahira, T.; Mitsui, Y.; Maruyama, Y.; Tanimoto, R.; Wada, K.; Munemasa, S.; Kusaka, N.; Nishiyama, Y.; Kurashige, T.; et al. Favorable long-term oncological and urinary outcomes of incidental prostate cancer following holmium laser enucleation of the prostate. *Mol. Clin. Oncol.* **2019**, *10*, 605–609. [CrossRef] [PubMed]
45. Elmansy, H.; Baazeem, A.; Kotb, A.; Badawy, H.; Riad, E.; Emran, A.; Elhilali, M. Holmium Laser Enucleation Versus Photoselective Vaporization for Prostatic Adenoma Greater than 60 Ml: Preliminary Results of a Prospective, Randomized Clinical Trial. *J. Urol.* **2012**, *188*, 216–221. [CrossRef]
46. Chen, Y.-B.; Chen, Q.; Wang, Z.; Peng, Y.-B.; Ma, L.-M.; Zheng, D.-C.; Cai, Z.-K.; Li, W.-J.; Ma, L.-H. A Prospective, Randomized Clinical Trial Comparing Plasmakinetic Resection of the Prostate with Holmium Laser Enucleation of the Prostate Based on a 2-Year Followup. *J. Urol.* **2013**, *189*, 217–222. [CrossRef] [PubMed]
47. Endo, F.; Shiga, Y.; Minagawa, S.; Iwabuchi, T.; Fujisaki, A.; Yashi, M.; Hattori, K.; Muraishi, O. Anteroposterior Dissection HoLEP: A Modification to Prevent Transient Stress Urinary Incontinence. *Urology* **2010**, *76*, 1451–1455. [CrossRef] [PubMed]
48. Anan, G.; Kaiho, Y.; Iwamura, H.; Kohada, Y.; Mikami, J.; Ito, J.; Sato, M. Anteroposterior dissection three-lobe technique: An effective surgical method for inexperienced surgeons performing holmium laser enucleation of the prostate. *Int. Urol. Nephrol.* **2020**, *52*, 1821–1828. [CrossRef]
49. Anan, G.; Kaiho, Y.; Iwamura, H.; Ito, J.; Kohada, Y.; Mikami, J.; Sato, M. Preoperative pelvic floor muscle exercise for early continence after holmium laser enucleation of the prostate: A randomized controlled study. *BMC Urol.* **2020**, *20*, 1–7. [CrossRef]
50. Wallner, C.; Dabhoiwala, N.F.; DeRuiter, M.C.; Lamers, W.H. The Anatomical Components of Urinary Continence. *Eur. Urol.* **2009**, *55*, 932–944. [CrossRef]
51. Houssin, V.; Olivier, J.; Brenier, M.; Pierache, A.; Laniado, M.; Mouton, M.; Theveniaud, P.E.; Baumert, H.; Mallet, R.; Marquette, T.; et al. Predictive factors of urinary incontinence after holmium laser enucleation of the prostate: A multicentric evaluation. *World J. Urol.* **2021**, *39*, 143–148. [CrossRef]
52. Vavassori, I.; Valenti, S.; Naspro, R.; Vismara, A.; Dell'Acqua, V.; Manzetti, A.; Hurle, R. Three-Year Outcome following Holmium Laser Enucleation of the Prostate Combined with Mechanical Morcellation in 330 Consecutive Patients. *Eur. Urol.* **2008**, *53*, 599–606. [CrossRef] [PubMed]
53. Tunc, L.; Yalcin, S.; Kaya, E.; Gazel, E.; Yılmaz, S.; Aybal, H.C.; Yılmaz, M.; Tokas, T. The "Omega Sign": A novel HoLEP technique that improves continence outcomes after enucleation. *World J. Urol.* **2021**, *39*, 135–141. [CrossRef] [PubMed]