


Article

Peri-Implantitis Management: Surgical versus Non-Surgical Approach Using Photodynamic Therapy Combined with Hydrogen Peroxide (OHLLT—Oxygen High Level Laser Therapy): A Retrospective Controlled Study

Gianluigi Caccianiga ¹ , Gérard Rey ², Paolo Caccianiga ^{1,*}, Alessandro Leonida ¹, Marco Baldoni ¹, Alessandro Baldoni ³ and Saverio Ceraulo ¹

¹ School of Medicine and Surgery, University of Milano-Bicocca, 20900 Monza, Italy; gianluigi.caccianiga@unimib.it (G.C.); leo.doc73@libero.it (A.L.); marco.baldoni@unimib.it (M.B.); saverio.ceraulo@unimib.it (S.C.)

² School of Dentistry Garancière, University of Paris Diderot, 75100 Paris, France; dr.gerardrey@sfr.fr

³ Independent Researcher, C.O.S., 20100 Monza, Italy; ale_1492@hotmail.it

* Correspondence: p.caccianiga@campus.unimib.it



Citation: Caccianiga, G.; Rey, G.; Caccianiga, P.; Leonida, A.; Baldoni, M.; Baldoni, A.; Ceraulo, S. Peri-Implantitis Management: Surgical versus Non-Surgical Approach Using Photodynamic Therapy Combined with Hydrogen Peroxide (OHLLT—Oxygen High Level Laser Therapy): A Retrospective Controlled Study. *Appl. Sci.* **2021**, *11*, 5073. <https://doi.org/10.3390/app11115073>

Academic Editor: Luca Testarelli

Received: 31 March 2021

Accepted: 25 May 2021

Published: 30 May 2021

Publisher's Note: MDPI stays neutral with regard to jurisdictional claims in published maps and institutional affiliations.



Copyright: © 2021 by the authors. Licensee MDPI, Basel, Switzerland. This article is an open access article distributed under the terms and conditions of the Creative Commons Attribution (CC BY) license (<https://creativecommons.org/licenses/by/4.0/>).

Abstract: Peri-implantitis management could be performed either with a surgical or non-surgical approach to the implant surfaces. Various treatment options have been proposed in the literature, such as antiseptic and antibiotic therapies, chemical agents, curettes, ultrasonic, air abrasive, rotary titanium brushes and laser treatments; in particular, photodynamic therapy combined with hydrogen peroxide (OHLLT) has proved to be efficient in the removal of bacterial biofilm from implant surfaces. The aim of our study is to compare OHLLT performed with a surgical approach to a non-surgical approach. We selected a cluster of 227 implants affected by peri-implantitis: 139 implants were treated with a non-surgical approach and 88 implants with a surgical approach. Bone loss pre-operative and post-operative (with a follow-up of five years) have been registered. The collected data were entered on the Statistical Package for Social Sciences (SPSS) version 11.5. The results indicate a statistically significant difference between the two groups, with a mean bone loss after treatment of 2.3 mm for OHLLT with a surgical approach and 3.8 mm for OHLLT with a non-surgical approach; according to the Kolmogorov–Smirnov test, the overall data followed a normal distribution (value of the Kolmogorov–Smirnov test statistic = 0.0891; $p = 0.35794$). Thus, a surgical approach in the case of peri-implantitis seems to be more effective, probably due to the possibility of a deeper sanitization of implant surfaces, hardly reachable with only non-surgical approach.

Keywords: diode laser; high frequency; hydrogen peroxide; peri-implantitis; photodynamic therapy

1. Introduction

Dental implants represent an excellent treatment option for the rehabilitation of atrophic jaws; nevertheless, even this clinical option is not free from complications [1]. Similarly, for natural teeth undergoing periodontal problems (periodontitis), dental implants could be affected by peri-implant mucositis (inflammation of soft tissues, reversible) or peri-implantitis (involvement of hard and soft tissues) [1].

A recent change in the classification of peri-implantitis has lead to an increased difficulty in the interpretation of the prevalence of this disease [2]. Nowadays, we can assume for peri-implantitis the presence of bleeding or suppuration with gentle pressure on probing and some variations from previous examinations, such as increased probing depth and increased bone loss; in the case of the absence of previous examinations, peri-implantitis is defined as presence of bleeding and/or suppuration on gentle probing, probing depths ≥ 6 mm, and bone levels ≥ 3 mm apical to the most coronal portion of the

intraosseous part of the implant, as stated by the American Academy of Periodontology and the European Federation of Periodontology [3].

This consensus report attempts to overcome the limits derived from a variety of different classifications that resulted in a wide range of prevalence reported, limiting the possibility of a real evaluation of peri-implantitis spread [4].

Risk factors generically recognized are history of periodontitis, smoking, diabetes and patient compliance, while other conditions discussed in the literature are the presence or absence of keratinized mucosa around implants, bone augmentation procedures, type of implant surface and implant positioning [5].

A recent study drew attention to the differences of bacterial biofilm between natural teeth and implants: in fact, Kotsakis et al. reported that peri-implantitis are resistant to beta-lactam antibiotics, which are effective against periodontal communities even as monotherapies [6].

The primary goal of peri-implantitis treatments is the reduction of bacteria from implant surfaces, achieving deep decontamination; in order to obtain this result, both a non-surgical and surgical approach to implant surfaces have been proposed [5].

The main treatment options are represented by:

- Antiseptic and antibiotic therapies (local or systemic) [6,7]
- Mechanical debridement: curettes, ultrasonic, air abrasive, rotary titanium brushes [5]
- Laser treatments: diode, Er:YAG, CO₂, Nd:YAG, Er,Cr:YSGG [8–16]
- PDT: photodynamic therapy [15]
- Chemical agents: H₂O₂, H₃PO₄, EDTA [5]

In the surgical treatment, the aim of decontamination is obtained through an open flap in order to perform deep sanitization and to create an implant morphology easier to clean, with the further possibility of obtaining guided bone regeneration [5].

The above-mentioned treatments could be combined in order to enhance clinical results.

Laser treatments for peri-implantitis show increasing attention in the literature; PDT seems to be effective only in the reduction of inflammatory status, but as a result of its scarce peak power (<2 W), PDT has only limited possibility of eliminating bacteria from implant surfaces, due to poor penetration capacity of the laser light in tissues imbibed with photosensitizer [17,18].

In order to overcome these limitations, G. Rey [12–15] proposed a modified protocol, named OHLLT (oxygen high-level laser therapy), combining a 980 nm laser (Wiser, Doctor Smile) with hydrogen peroxide, leading to higher bioavailability and deeper penetration in the biofilms; moreover, this protocol has reduced interference of the irradiation performed respect to photoactivating agents with absorption within the visible band (Figure 1).

The aim of this retrospective controlled study is to assess clinical outcomes of OHLLT alone in a non-surgical approach and OHLLT adjunct to a surgical approach.

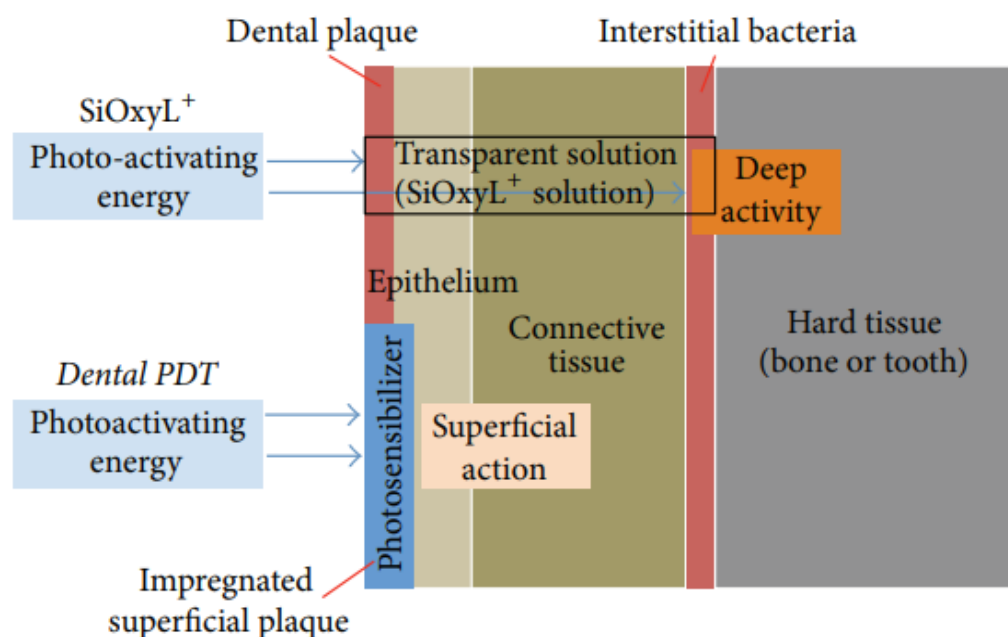


Figure 1. Effects of the transparent photosensitizer.

2. Materials and Methods

The present retrospective controlled study was approved by the Ethics Committee of the School of Medicine and Surgery at the Milano Bicocca University, (protocol n. 11/17), derived from the approval of Italian National Institute of Health (ISS), prot. 30/07/2007-0040488, and it was conducted in observance of the declaration of Helsinki.

In this study, we selected a cluster of 227 implants affected by peri-implantitis, subdivided in 121 in the upper arch and 106 in the mandible (Table 1).

Table 1. Total amount of implants with peri-implantitis.

Implants	Upper	Lower	Tot
Total Amount	121	106	227

We stated the following inclusion criteria in order to normalize the sample: both male and female, peri-implantitis without previous surgical treatment in the last year, bleeding on probing, peri-implant pockets >4 mm, non-smoking history, absence of allergies, absence of uncontrolled systemic disease, absence of pregnancy or lactating, absence of abuse of alcohol or drugs, and acceptance of the surgical intervention by signing an informed consensus. The exclusion criteria were: peri-implantitis with previous surgical treatment in the last year, absence of bleeding on probing, peri-implant pockets <4 mm, smoking history, presence of allergies, presence of uncontrolled systemic disease, presence of pregnancy or lactating, abuse of alcohol or drugs, and non-acceptance of the surgical intervention by signing an informed consensus. All patients agreed with the following oral hygiene maintenance protocol at home: sonic brush with vertical movement (Broxo), interdental brushes, and oral irrigators (Broxo) at least two times every day.

Our cluster of implants consisted of different types of implant surfaces: 59 machined implants, 141 nano-roughness implants, 24 hydroxyapatite-coated implants and three zirconia implants. All implants were finalized with screwed fixed dental prostheses.

Implants were assessed for BOP (bleeding on probing) and presence of suppuration: at T₀, in fact, all the implants analyzed reported bleeding on probing and the presence of suppuration. All implants were analyzed through periapical radiographs using the long cone paralleling technique with a grid template. We adopted DIB (the distance from

the implant shoulder to the alveolar bone crest) as a reliable radiographic parameter for long-term monitoring in clinical practice. Bone level measurements have been realized from implant neck to bone crest, both in the mesial and distal side of implants; for each implant, the lowest measurement between mesial and distal aspect was considered. The measurements were made by the same operator.

The software used to realize the measurements is Soredex Digora®.

Each implant was evaluated before and after treatment, at T_0 (time of diagnosis of peri-implantitis) and at T_1 (most recent follow-up of implant treated for peri-implantitis). We stated five years as the minimum follow-up period for T_1 .

Bone level measurements were organized in Excel to examine bone levels around implants at the two different time periods.

The cumulative (the test group is considered the non-surgical OHLLT group; the control group is considered the surgical OHLLT group, the protocol more investigated in the past) mean bone loss preoperative (t_0) was 5.8 mm; in particular, the mean bone loss was 6.1 for implants positioned in the upper arch and 5.4 mm for implants positioned in the mandible (Table 2).

Table 2. Bone loss pre-operative (t_0).

Implants	Upper	Lower	Tot
Total Amount	121	106	227
Bone Loss Pre-Operative	5.8 mm	5.2 mm	5.6 mm

OHLLT were performed with a non-surgical approach in 139 implants and with a surgical approach in 88 implants.

In the group of OHLLT with a non-surgical approach (OHLLT non-s.a.; test group) 67 implants were performed in the upper arch, 72 in the mandible; for the group of OHLLT with surgical approach (OHLLT s.a., control group) 54 implants were performed in the upper arch, 34 in the mandible (Table 3).

Table 3. Number of implants for the two groups.

Implants	Upper	Lower	Tot
Surgical Approach	54	34	88
Non-Surgical Approach	67	72	139

We investigated bone loss post-operative for both groups. We stated five years as the minimum follow-up period for T_1 .

The collected data were entered on the Statistical Package for Social Sciences (SPSS) version 11.5. The results were thus expressed as proportions using appropriate tables.

2.1. Non-Surgical Procedure (139 Implants: 67 in the Maxilla, 72 in the Mandible)

The OHLLT non-surgical procedure consisted of (Figures 2–4): local anesthesia, ultrasonic instrumentation for supra and subgingival scaling combined with water–betadine irrigation (5:1 ratio), an air flow device with sodium bicarbonate powder (high-abrasive powder), mechanical instrumentation and the removal of necrotic tissues with Gracey curettes. Then, the OHLLT protocol (Wiser, Doctor Smile, Vicenza, Italy) was performed: irrigation of peri-implant pockets with Sioxyl solution; aspiration of Sioxyl solution emerging from the gingival sulcus and leaving the remaining solution inside the pocket for 2 min; introduction of the HF Diode Laser Fiber 400 microns within the pocket and reaching the bottom; and radiation of subgingival tissues with a movement back and forth using the dedicated program, 60 s per side (2.5 W peak power, high frequency, 10 KHz, power average 0.5 W, fluency 25,000 J/cm², 416.66 J/cm² per second).

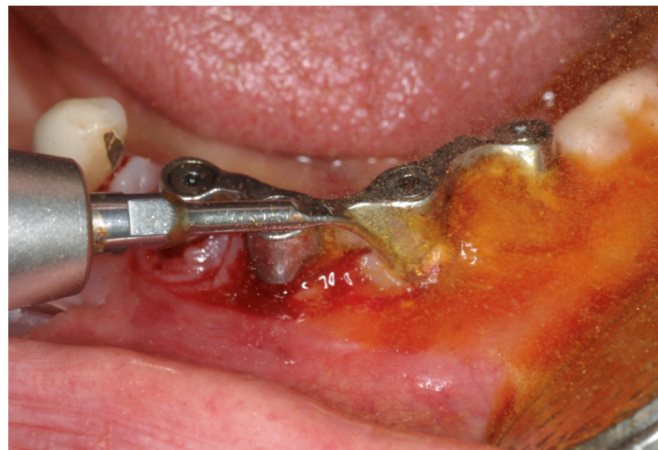

Figure 2. OHLLT surgical approach. Ultrasonic instrumentation for supra- and subgingival scaling with water–betadine irrigation (5:1 ratio).

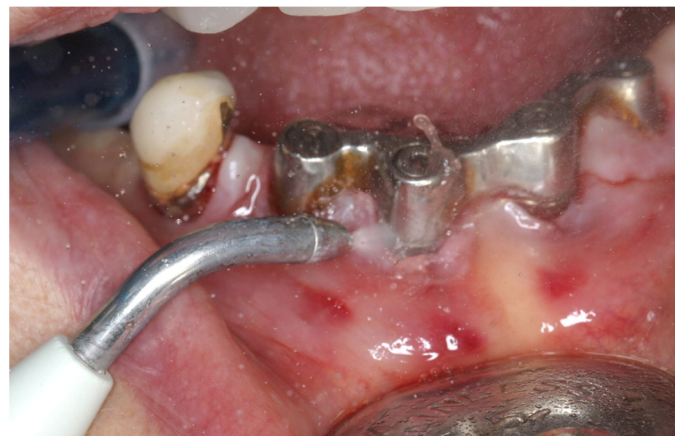

Figure 3. OHLLT surgical approach. Air flow device with sodium bicarbonate powder (high abrasive powder).

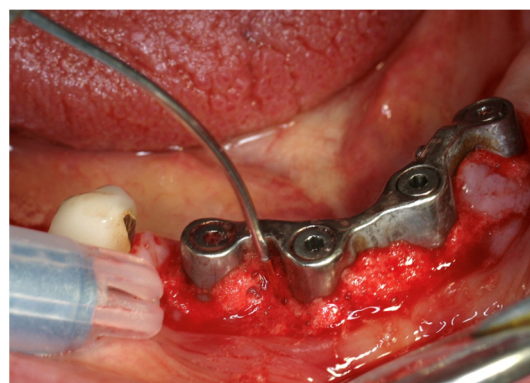


Figure 4. OHLLT non-surgical approach. Laser irradiation combined with hydrogen peroxide 10 vol. 3%.

2.2. Surgical Procedure (88 Implants: 54 in the Maxilla, 34 in the Mandible)

The OHLLT surgical procedure consisted of (Figures 5 and 6): local anesthesia, intra-sulcular incision for a full thickness periodontal flap, mechanical instrumentation and the removal of necrotic tissues with Gracey curettes, ultrasonic instrumentation for supra

and subgingival scaling combined with water–betadine irrigation (5:1 ratio), and an air flow device with sodium bicarbonate powder (high-abrasive powder). Then, the OHLLT protocol (Wiser, Doctor Smile, Vicenza, Italy) was performed: irrigation of peri-implant pockets with Sioxyl solution; aspiration of Sioxyl solution emerging from the gingival sulcus and leaving the remaining solution inside the pocket for 2 min; introduction of the HF Diode Laser Fiber 400 microns within the pocket and reach the bottom; and radiation of subgingival tissues with a movement back and forth using the dedicated program, 60 s per side (2.5 W peak power, high frequency, 10 KHz, power average 0.5 W, fluency 25,000 J/cm², 416.66 J/cm² per second). After the decontamination with OHLLT, the site was grafted with a mix of Bio-Oss granules 25, autologous bone chips, PRF (platelet-rich fibrin) and collagen membranes (45% Bio-Oss 25, 45% PRF, 10% autologous bone chips). At the end, flap repositioning and suture was performed.

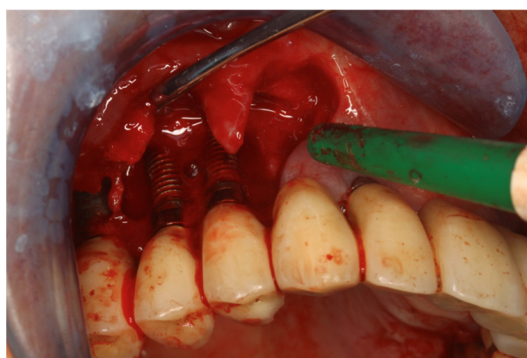


Figure 5. OHLLT surgical approach. Full thickness periodontal flap.

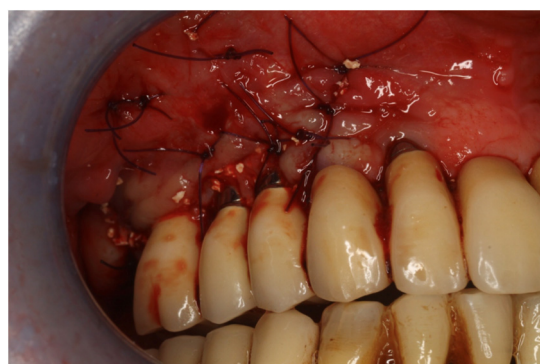

Figure 6. OHLLT surgical approach. Flap repositioning and suture.

3. Results

We realized a retrospective controlled study establishing as control group the implants treated with surgical OHLLT, a choice that is supported by extensive literature reporting successful treatments with this modality; in this way, the test group has been represented by non-surgical OHLLT treatment.

All peri-implant pockets were treated successfully with clinical signs of soft and hard tissues healing. In fact, at t_1 , all implants showed the absence of suppuration and contemporary resolution of bleeding on probing (BOP).

The percentage of bone loss has been analyzed for each implant.

The data collected show an enhancement of bone level at t_1 for all implants treated.

In the implants that underwent OHLLT with a surgical approach, we noticed a mean bone loss after treatment of 2.3 mm, with a mean bone loss of 2.1 for the implants positioned in the upper arch and 2.4 mm for implants in the mandible (Table 4).

Table 4. Bone loss post-operative (t1) for implants with surgical approach (S.A.).

OHLT S.A.	Upper	Lower	Tot
Total Amount	54	34	88
Bone Loss Post-Operative	2.1 mm	2.4 mm	2.3 mm

In the OHLT non-surgical approach group, we observed a mean bone loss after treatment of 3.8 mm, with a mean bone loss of 3.9 in the upper arch and 3.8 in the mandible (Table 5).

Table 5. Bone loss post-operative (t1) for implants with non-surgical approach (non-S.A.).

OHLT Non-S.A.	Upper	Lower	Tot
Total Amount	67	72	139
Bone Loss Post-Operative	3.9 mm	3.8 mm	3.8 mm

Statistical analysis revealed a significant difference in post-operative bone loss between the two groups. According to the Kolmogorov–Smirnov test, overall data followed a normal distribution (value of the Kolmogorov–Smirnov test statistic = 0.0891; $p = 0.35794$). The statistical analysis is represented in Tables 6 and 7.

Table 6. Peri-implant parameters among test group and control group pre-treatment.

	Test Group	Control Group	<i>p</i> Value
	Mean \pm SD	Mean \pm SD	
BoP	2.14 \pm 0.49	2.16 \pm 0.51	<0.014 *
P.S.	0.94 \pm 0.19	0.97 \pm 0.21	<0.017 *
P.D.	5.79 \pm 0.21	5.84 \pm 0.18	<0.015 *

BoP—bleeding on probing; P.S.—presence of suppuration P.D.—peri-implant depth; *— p value < 0.001 statistically significant.

Table 7. Peri-implant parameters among test group and control group pre-treatment.

	Test Group	Control Group	<i>p</i> Value
	Mean \pm SD	Mean \pm SD	
BoP	0.71 \pm 0.14	0.32 \pm 0.12	<0.0008 *
P.S.	0.03 \pm 0.05	0.03 \pm 0.02	0.002
P.D.	3.85 \pm 0.12	2.23 \pm 0.21	<0.0009 *

BoP—bleeding on probing; P.S.—presence of suppuration; P.D.—peri-implant depth; *— p value < 0.001 statistically significant.

4. Discussion

Peri-implantitis treatment is a crucial topic widely discussed in dentistry.

During the last few years, various protocols for peri-implantitis have been developed, without clear evidence of which is the best way to approach this unwilling complication [16].

In the present study, we aim to establish if there are differences between surgical or non-surgical approach to peri-implantitis.

A recent randomized clinical trial by Wagner et al. [19] compared surgical and non-surgical debridement with a 12-month period of observation, evidencing no statistical differences between the two groups; the authors concluded that non-surgical debridement should be considered the first therapeutic choice for peri-implantitis, mainly mild to moderate cases.

On the contrary, in an in vitro study, Tuchscheerer et al. [20], comparing air polishing efficacy conveyed through surgical or non-surgical modality, concluded that a surgical approach results in significant better surface decontamination.

Non-surgical treatment of peri-implantitis has been widely discussed in the literature. Nart et al. [21] conducted a 12-month clinical and radiographical case series utilizing ultrasonic scaler debridement, glycine air abrasive, and metronidazole followed by supportive maintenance; the authors reported effectiveness in reducing peri-implant pocket depth and suppuration, but no effects in reducing bleeding on probing.

A systematic descriptive review by Suárez-López del Amo [22] reported that non-surgical treatment of peri-implant mucositis achieved significant positive results while peri-implantitis lesions cannot be completely resolved with only this treatment modality.

Another important key factor in determining usability of non-surgical approach is the timing of peri-implant diagnosis: Chang et al. [23] stated that early diagnosis of peri-implantitis could lead to a higher possibility of success of non-surgical management; similarly, Schwarz et al. [24] stated that non-surgical treatment is recommended for marginal bone loss less than 2 mm around the implant, whilst surgical treatment (apically positioned flap or flap surgery) is recommended for marginal bone loss greater than 2 mm. Therefore, earlier detection of the disease may result in less-invasive treatment modality for peri-implantitis treatment.

On the other hand, in the literature, there are many studies focusing on the surgical approach to peri-implantitis. Berghlund et al. [25] conducted a retrospective study in which peri-implant probing depth, bleeding on probing and crestal bone level demonstrated a considerable enhancement, even considering long-term time span (2 to 11 years).

Carcuac et al. [26] performed a three-year randomized controlled clinical trial of surgical treatment in association or not with antibiotics: they reported a significant mean reduction in probing depth and bleeding/suppuration on probing, with the maintenance of stable bone levels, without evidence of clinical enhancement with the use of antibiotics over the three years of follow-up.

Overall, a surgical approach has been recommended in the presence of severe peri-implant lesions [27–29] and to avoid the high recurrence rate with correlated incomplete resolution associated with non-surgical treatments [5].

In our retrospective controlled study, we aim to establish if a surgical approach is to be considered superior in peri-implantitis treatment with respect to a non-surgical approach, investigating these two treatment modalities using OHLLT as the basis of peri-implant treatment; in fact, several studies have proved its efficacy in successfully removing bacterial biofilm from implant surfaces, thus resulting in clinical improvement of peri-implantitis disease [14,15].

The results obtained in our retrospective controlled study attest that a surgical approach seems to be more effective in peri-implantitis treatment; in fact, we noticed a statistically significant improvement in bone loss post-operative (t_1) with this treatment with respect to a non-surgical approach.

The explanation to these results could be found in a greater difficulty to efficiently decontaminate implant surfaces in the case of the non-surgical approach; in fact, in this way, air abrasives and ultrasonics could not completely reach implant surface, while with a surgical approach, these devices are clearly able to perform deep sanitization of the bacterial biofilm.

5. Conclusions

Notwithstanding peri-implantitis treatment still remains discussed in the literature, our retrospective controlled study showed that a surgical approach, with the fundamental adjunct of OHLLT, seems to be effective in obtaining clinical success in peri-implantitis management, compared to non-surgical protocols.

Author Contributions: Conceptualization, G.C., G.R. and S.C.; methodology, M.B. and G.R.; software, P.C.; validation, G.C., M.B. and S.C.; formal analysis, A.L.; investigation, G.C. and G.R.; resources, M.B.; data curation, A.L.; writing—original draft preparation, A.B.; writing—review and editing, P.C.; visualization, P.C.; supervision, G.C. and G.R.; project administration, S.C.; funding acquisition, M.B. All authors have read and agreed to the published version of the manuscript.

Funding: This research received no external funding.

Institutional Review Board Statement: The study was conducted according to the guidelines of the Ethics Committee of the School of Medicine and Surgery at the Milano Bicocca University, (protocol n. 11/17), and derived from the approval of Italian National Institute of Health (ISS), protocol 30 July 2007-0040488.

Informed consent Statement: Informed consent was obtained from all subjects involved in the study.

Data Availability Statement: No applicable.

Conflicts of Interest: The authors declare no conflict of interest.

References

1. Mahato, N.; Wu, X.; Wang, L. Management of peri-implantitis: A systematic review, 2010–2015. *SpringerPlus* **2016**, *5*, 1–9. [\[CrossRef\]](#)
2. Shimchuk, A.A.; Weinstein, B.F.; Daubert, D.M. Impact of a change in classification criteria on the prevalence of peri-implantitis: A cross-sectional analysis. *J. Periodontol.* **2020**. [\[CrossRef\]](#)
3. Berglundh, T.; Armitage, G.; Araujo, M.G.; Avila-Ortiz, G.; Blanco, J.; Camargo, P.M.; Chen, S.; Cochran, D.; Derks, J.; Figuero, E.; et al. Peri-implant diseases and conditions: Consensus report of workgroup 4 of the 2017 World Workshop on the Classification of Periodontal and Peri-Implant Diseases and Conditions. *J. Periodontol.* **2018**, *89*, S313–S318. [\[CrossRef\]](#)
4. Cosgarea, R.; Sculean, A.; Shibli, J.A.; Salvi, G.E. Prevalence of peri-implant diseases—A critical review on the current evidence. *Braz. Oral Res.* **2019**, *33*, e063. [\[CrossRef\]](#) [\[PubMed\]](#)
5. Kormas, I.; Pedercini, C.; Pedercini, A.; Raptopoulos, M.; Alassy, H.; Wolff, L.F. Peri-Implant Diseases: Diagnosis, Clinical, Histological, Microbiological Characteristics and Treatment Strategies. A Narrative Review. *Antibiotics* **2020**, *9*, 835. [\[CrossRef\]](#) [\[PubMed\]](#)
6. Kotsakis, G.A.; Olmedo, D.G. Peri-implantitis is not periodontitis: Scientific discoveries shed light on microbiome-biomaterial interactions that may determine disease phenotype. *Periodontol.* **2021**, *86*, 231–240. [\[CrossRef\]](#) [\[PubMed\]](#)
7. Renvert, S.; Roos-Jansåker, A.M.; Claffey, N. Non-surgical treatment of peri-implant mucositis and peri-implantitis: A literature review. *J. Clin. Periodontol.* **2008**, *35* (Suppl. 8), 305–315. [\[CrossRef\]](#) [\[PubMed\]](#)
8. Caccianiga, G.; Cambini, A.; Donzelli, E.; Baldoni, M.; Rey, G.; Paiusco, A. Effects of laser biostimulation on the epithelial tissue for keratinized layer differentiation: An in vitro study. *J. Biol. Regul. Homeost. Agents* **2016**, *30*, 27469555.
9. Leonida, A.; Paiusco, A.; Rossi, G.; Carini, F.; Baldoni, M.; Caccianiga, G. Effects of low-level laser irradiation on proliferation and osteoblastic differentiation of human mesenchymal stem cells seeded on a three-dimensional biomatrix: In vitro pilot study. *Lasers Med. Sci.* **2012**, *28*, 125–132. [\[CrossRef\]](#) [\[PubMed\]](#)
10. Caccianiga, G.L.; Urso, E.; Monguzzi, R.; Gallo, K.; Rey, G. Efecto bactericida del láser de diodo en periodoncia. *Av. Periodoncia Implantol. Oral* **2007**, *19*, 131–140. [\[CrossRef\]](#)
11. Caccianiga, G.; Urso, E.; Monguzzi, R.; Gallo, K.; Rey, G. Efecto bactericida del láser Nd: YAP. Estudio in vitro. *Av. Odontostomatol.* **2007**, *23*, 127–133. [\[CrossRef\]](#)
12. Caccianiga, G.; Cambini, A.; Rey, G.; Paiusco, A.; Fumagalli, T.; Giacomello, M. The Use of Laser Diodes Superpulses in Implantology. *Eur. J. Inflamm.* **2012**, *10*, 97–100. [\[CrossRef\]](#)
13. Rey, G. L'apport du laser dans le traitement des poches paradontales. *Implantodontie* **2000**, *38*, 27–34.
14. Caccianiga, G.; Rey, G.; Paiusco, A.; Lauritano, D.; Cura, F.; Ormianer, Z.; Carinci, F. Oxygen high level laser therapy is efficient in treatment of chronic periodontitis: A clinical and microbiological study using PCR analysis. *J. Biol. Regul. Homeost. Agents* **2016**, *30*, 87–97.
15. Caccianiga, G.; Baldoni, M.; Ghisalbetti, C.A.; Paiusco, A. A Preliminary In Vitro Study on the Efficacy of High-Power Photodynamic Therapy (HLLT): Comparison between Pulsed Diode Lasers and Superpulsed Diode Lasers and Impact of Hydrogen Peroxide with Controlled Stabilization. *BioMed Res. Int.* **2016**, *2016*, 1–6. [\[CrossRef\]](#)
16. Świder, K.; Dominiak, M.; Grzech-Leśniak, K.; Matys, J. Effect of Different Laser Wavelengths on Periodontopathogens in Peri-Implantitis: A Review of In Vivo Studies. *Microorganisms* **2019**, *7*, 189. [\[CrossRef\]](#) [\[PubMed\]](#)
17. Carroll, J.; Milward, M.R.; Cooper, P.R.; Hadis, M.; Palin, W.M. Developments in low level light therapy (LLLT) for dentistry. *Dent. Mater.* **2014**, *30*, 465–475. [\[CrossRef\]](#) [\[PubMed\]](#)
18. Bombeccari, G.P.; Guzzi, G.; Gualini, F.; Gualini, S.; Santoro, F.; Spadari, F. Photodynamic therapy to treat periimplanti-tis. *Implant Dent.* **2013**, *22*, 631–638. [\[CrossRef\]](#) [\[PubMed\]](#)
19. Wagner, T.P.; Pires, P.R.; Rios, F.S.; de Oliveira, J.A.P.; Costa, R.D.S.A.; Cunha, K.F.; Silveira, H.L.D.; Pimentel, S.; Casati, M.Z.; Rosing, C.K.; et al. Surgical and non-surgical debridement for the treatment of peri-implantitis: A two-center 12-month randomized trial. *Clin. Oral Investig.* **2021**, 1–11. [\[CrossRef\]](#)
20. Tuchscheerer, V.; Eickholz, P.; Dannewitz, B.; Ratka, C.; Zuh, O.; Petsos, H. In vitro surgical and non-surgical air-polishing efficacy for implant surface decontamination in three different defect configurations. *Clin. Oral Investig.* **2021**, *25*, 1743–1754. [\[CrossRef\]](#)
21. Nart, J.; Pons, R.; Valles, C.; Esmatges, A.; Sanz-Martín, I.; Monje, A. Non-surgical therapeutic outcomes of peri-implantitis: 12-month results. *Clin. Oral Investig.* **2019**, *24*, 675–682. [\[CrossRef\]](#)

22. Del Amo, F.S.; Yu, S.-H.; Wang, H.-L. Non-Surgical Therapy for Peri-Implant Diseases: A Systematic Review. *J. Oral Maxillofac. Res.* **2016**, *7*, e13. [[CrossRef](#)]
23. Chang, H.-Y.; Park, S.-Y.; Kim, J.-A.; Kim, Y.-K.; Lee, H.-J. Early radiographic diagnosis of peri-implantitis enhances the outcome of peri-implantitis treatment: A 5-year retrospective study after non-surgical treatment. *J. Periodontal Implant. Sci.* **2015**, *45*, 82–93. [[CrossRef](#)]
24. Schwarz, F.; Jepsen, S.; Hertten, M.; Sager, M.; Rothamel, D.; Becker, J. Influence of different treatment approaches on non-submerged and submerged healing of ligature induced peri-implantitis lesions: An experimental study in dogs. *J. Clin. Periodontol.* **2006**, *33*, 584–595. [[CrossRef](#)] [[PubMed](#)]
25. Berglundh, T.; Wennström, J.L.; Lindhe, J. Long-term outcome of surgical treatment of peri-implantitis. A 2-11-year retrospective study. *Clin. Oral Implant. Res.* **2018**, *29*, 404–410. [[CrossRef](#)]
26. Carcuac, O.; Derks, J.; Abrahamsson, I.; Wennström, J.L.; Petzold, M.; Berglundh, T. Surgical treatment of peri-implantitis: 3-year results from a randomized controlled clinical trial. *J. Clin. Periodontol.* **2017**, *44*, 1294–1303. [[CrossRef](#)] [[PubMed](#)]
27. Patel, A. Non-Surgical Management of Peri-Implant Diseases. *Prim. Dent. J.* **2014**, *3*, 62–65. [[CrossRef](#)]
28. Matys, J.; Świder, K.; Flieger, R.; Dominiak, M. Assessment of the primary stability of root analog zirconia implants designed using cone beam computed tomography software by means of the Periotest[®] device: An ex vivo study. A preliminary report. *Adv. Clin. Exp. Med.* **2017**, *26*, 803–809. [[CrossRef](#)] [[PubMed](#)]
29. Matys, J.; Flieger, R.; Dominiak, M. Effect of diode lasers with wavelength of 445 and 980 nm on a temperature rise when uncovering implants for second stage surgery—An ex-vivo study in pigs. *Adv. Clin. Exp. Med.* **2017**, *26*, 687–693. [[CrossRef](#)]