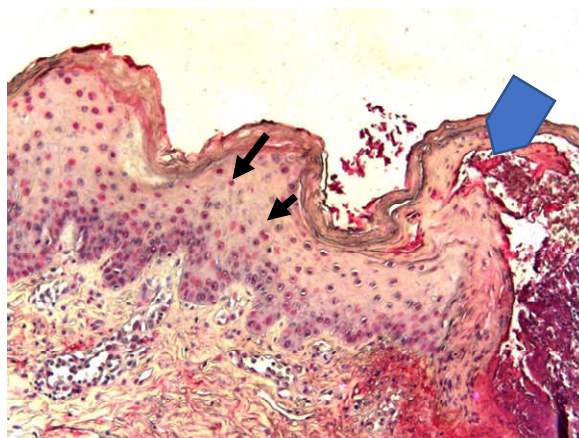
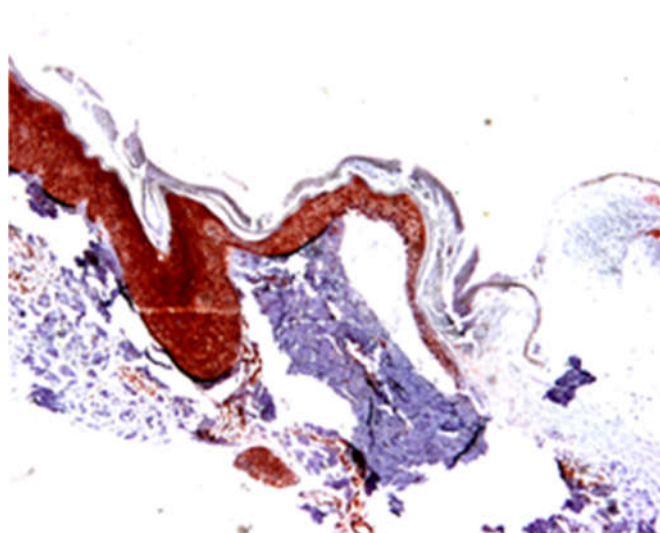


Review

# Burn Injury: Mechanisms of Keratinocyte Cell Death-Supplement



**Figure S1.** TUNEL staining of nuclei (arrows, red colour) at the wound edge of a burn wound; wound margin (bold arrow) is a figure. Schemes follow another format.



**Figure S2.** Strong active Caspase 3 immunoreactivity (red staining) is seen in keratinocytes and some dermal cells in human burn wounds.