medical sciences

MDPI

Review

Perspectives on Artificial Intelligence Enabled Heart Sound Analysis for Cardiac Amyloidosis

Tanisha Jindal [1], Jay Gohri [2], Vardhan Chalasani [3], Prudvi Jakkireddy [1], Anoushka Arora [1], Abdul Rauf [1], Simardeep Kaur Bumrah [1], Anmolpreet Kaur [1], Farshi Farook [1], Kaaviyashri Saraboji [1], Divaakar Siva Baala Sundaram [1,4], Jieun Lee [1], Mohammed Naveed Shariff [1], Gayathri Yerrapragada [1], Thangeswaran Natarajan [1], Jayarajasekaran Janarthanan [1], Poonguzhali Elangovan [1], Sancia Mary Jerold Wilson [1], Shiva Sankari Karuppiah [1], Divyanshi Sood [5], Lakshmi Sree Pugalenthi [6], Rashi Bilgaiyan [1], Suganti Shivaram [1], Scott A. Helgeson [1,7,8] and Shivaram P. Arunachalam [1,4,7,8,*]

1 Digital Engineering & Artificial Intelligence Laboratory (DEAL), Mayo Clinic, Jacksonville, FL 32224, USA; raufbhatti1997@gmail.com (A.R.); anmolpreetkgrewal@gmail.com (A.K.)
2 Reno School of Medicine, University of Nevada, Reno, NV 89557, USA
3 Department of Internal Medicine, Kasturba Medical College, Manipal 576104, Karnataka, India; vardhan2505@gmail.com
4 Department of Biomedical Informatics & Computational Biology (BiCB), University of Minnesota, Minneapolis, MN 55455, USA
5 Department of Internal Medicine, UCHealth Parkview Medical Center, Pueblo, CO 81003, USA
6 Department of Internal Medicine, Mercy Catholic Medical Center, Philadelphia, PA 19143, USA
7 Department of Critical Care Medicine, Mayo Clinic, Jacksonville, FL 32224, USA
8 Division of Pulmonary Medicine, Department of Medicine, Mayo Clinic, Jacksonville, FL 32224, USA
* Correspondence: poigaiarunachalam.shivaram@mayo.edu

Abstract

Cardiac amyloidosis was long considered rare and untreatable, but both assumptions have given way, and the disease is now recognized as an underdiagnosed and increasingly treatable cause of heart failure. The available therapies work by slowing amyloid deposition, so their benefit depends on early diagnosis, yet the condition is still identified late and usually only after referral for specialized imaging. Artificial intelligence has started to shorten this path. Models built on the electrocardiogram and the echocardiogram detect amyloid infiltration with high accuracy and have reached external validation, while artificial-intelligence-based analysis of heart sound, the cheapest and most widely available cardiac signal, has not yet been directly evaluated in this disease. The physiological rationale for studying it is strong, because a ventricle stiffened by amyloid is expected to alter the low-frequency diastolic sounds that reflect ventricular compliance, although whether these changes are specific to amyloidosis remains unknown. This review brings together the acoustic manifestations of cardiac amyloidosis, the signal-processing and machine learning methods relevant to heart sounds, the clinical evidence across imaging and acoustic modalities, and the practical and equity questions that deployment raises. Heart sound analysis remains the most scalable and least explored opportunity in the field. We outline the mechanistic rationale, the available methods, the lessons from the more mature electrocardiographic and echocardiographic literature, and a set of minimum design requirements for a first disease-specific study.

Keywords: cardiac amyloidosis; heart sounds; phonocardiography; artificial intelligence; deep learning; auscultation; transthyretin amyloidosis; screening

Check for updates

Academic Editor: Antonio Artigas

Received: 13 August 2026
Revised: 21 October 2026
Accepted: 26 October 2026
Published: 27 October 2026

Copyright: © 2026 by the authors. Licensee MDPI, Basel, Switzerland. This article is an open access article distributed under the terms and conditions of the Creative Commons Attribution (CC BY) license.

1. Introduction

For most of its history, cardiac amyloidosis was treated as a rare and largely untreatable diagnosis, sought infrequently because little could be done once it was found. That understanding has since been overturned on both counts. The disease is now recognized as substantially underdiagnosed rather than genuinely uncommon, and it has become treatable, which has changed what is at stake in identifying it early [1,2]. Amyloidosis develops when misfolded protein fibrils, derived most often from immunoglobulin light chains in amyloid light-chain (AL) disease or from transthyretin in transthyretin amyloidosis (ATTR), accumulate within the myocardial interstitium, and left untreated its prognosis is poor [1,3,4]. Cardiac involvement is referred to as AL cardiac amyloidosis or transthyretin amyloid cardiomyopathy (ATTR-CM), the latter being hereditary (ATTRv-CM) or wild-type (ATTRwt-CM).

The move toward effective treatment has made timing matter. In ATTR-CM the transthyretin stabilizer tafamidis reduced mortality and cardiovascular hospitalization in a randomized trial [5], the near-complete stabilizer acoramidis later showed benefit in a comparable population [6], and gene-silencing agents that lower circulating transthyretin, initially the RNA-interference therapeutic patisiran and the antisense agent inotersen in hereditary polyneuropathy [7,8] and more recently vutrisiran in cardiomyopathy [9], have widened the therapeutic repertoire further. In AL amyloidosis, adding the anti-CD38 antibody daratumumab to standard therapy has improved hematologic and organ responses and become the first approved regimen for newly diagnosed patients [10]. These treatments slow or halt amyloid deposition rather than reverse established damage, so their benefit depends on reaching patients before the heart has been irreversibly infiltrated, and delay reduces the benefit that disease-modifying therapy can provide, although a later diagnosis still informs supportive management, family assessment where appropriate, and prognosis. This would matter less if the disease were as rare as once believed. However, systematic screening has repeatedly uncovered it where it was never suspected, in a meaningful share of patients with heart failure with preserved ejection fraction, severe aortic stenosis, and carpal tunnel syndrome [11], and autopsy series have found unsuspected amyloid in the hearts of older patients with preserved ejection fraction [12]. The rising recognition of cardiac amyloidosis reflects not only its true prevalence but also greater clinical awareness, the availability of non-invasive diagnostic pathways, and the systematic investigation of populations previously labeled as heart failure with preserved ejection fraction, aortic stenosis, or age-related ventricular hypertrophy, a shift documented in both in vivo and autopsy series [13]. A disease that is treatable, that does most harm when found late, and that turns out to be more common than assumed is worth looking for before it declares itself.

Diagnosis nonetheless remains slow and easily missed, because amyloidosis presents through vague and overlapping symptoms that resemble more common disorders, and confirming it still depends on resources concentrated in referral centers rather than at the point of first contact [14]. The modern pathway relies on echocardiography and cardiac magnetic resonance to raise suspicion, conducted on bone scintigraphy with a bone-avid tracer (99mTc-PYP, DPD, or HMDP, according to regional practice), where grade 2 or 3 myocardial uptake in a patient with a compatible phenotype and no evidence of a monoclonal protein establishes ATTR-CM noninvasively, whereas a positive scan in the presence of a monoclonal protein requires tissue confirmation and amyloid typing [15], and on biochemical testing and occasionally biopsy to secure the diagnosis [15–17]. These methods are accurate but resource-intensive, and none of them suit the first encounter, where suspicion must first be raised (Figure 1). Artificial intelligence has begun to contribute at exactly this point, between a diagnosis that matters more than ever and a pathway

that remains hard to navigate. Its progress, though, has been uneven. Algorithms built on the electrocardiogram and the echocardiogram have reached external validation and regulatory clearance, learning the electrical and structural signatures of amyloid infiltration with considerable accuracy [18–20]. Heart sound analysis has lagged well behind, which is hard to justify given that it carries the lowest barrier to deployment of any cardiac modality. A stethoscope is inexpensive, portable, and already present at the first clinical encounter, so a model able to interpret heart sounds could screen at a reach that imaging will never achieve.

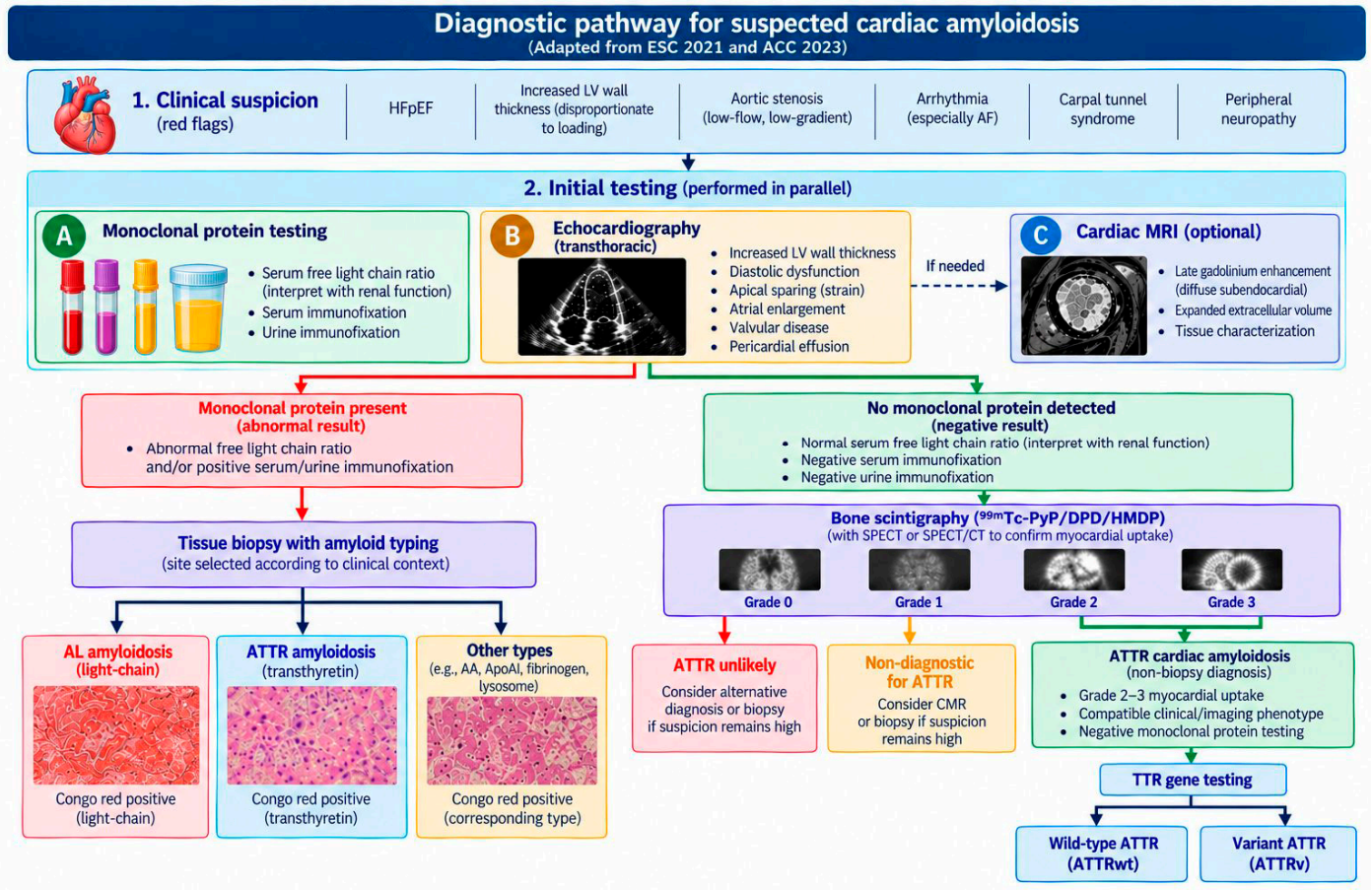

Figure 1. Current diagnostic pathway for cardiac amyloidosis and its limitations. Clinical suspicion prompts early testing for a plasma cell dyscrasia (serum-free light chains with serum and urine immunofixation) alongside echocardiography, with cardiac magnetic resonance used where needed. Without a monoclonal protein, bone scintigraphy with a bone-avid tracer (99mTc-PYP, DPD, or HMDP) establishes ATTR-CM noninvasively when myocardial uptake is grade 2 or 3 and the phenotype is compatible; a monoclonal protein or an equivocal scan requires tissue biopsy with amyloid typing. Each step depends on infrastructure concentrated in referral centers, and although electrocardiographic artificial intelligence has been cleared as a triage aid, it still requires a tracing to be acquired and interpreted, so bedside screening at the very first encounter remains unaddressed.

The physiology gives good reason to expect this to work. A ventricle stiffened by amyloid is expected to alter the low-frequency diastolic filling sounds that reflect ventricular compliance, which provides a mechanistic rationale, although not yet direct evidence, for analyzing heart sounds in this disease. Whether these changes constitute an acoustic phenotype specific to amyloidosis, rather than one shared with other causes of impaired filling, remains unknown. This review examines that opportunity. It begins with the acoustic manifestations of the disease and the methods used to analyze heart sounds, sets the clinical evidence for acoustic analysis against the more developed imaging literature,

and asks how such tools might be deployed and what limitations and inequities they would have to overcome. Heart sounds are at once the cheapest cardiac signal to capture and the least studied in this disease, and the gap between what their physiology promises and what has actually been tested is one the field should now close. Figure 1 summarizes the current diagnostic pathway and where it leaves an early-detection gap.

2. Search Strategy and Scope

This article is a narrative review and perspective, not a systematic review. To support the central observation that no artificial intelligence heart sound model has been evaluated in cardiac amyloidosis, we searched PubMed, Embase, and Scopus from database inception to June 2026. Search terms combined concepts for cardiac amyloidosis (cardiac amyloidosis, transthyretin, ATTR, AL amyloidosis) with concepts for heart sound analysis (heart sound, phonocardiography, phonocardiogram, auscultation, acoustic) and for artificial intelligence (artificial intelligence, machine learning, deep learning, neural network). English-language peer-reviewed articles, conference proceedings, and preprints were eligible, and preprints are identified as such throughout. No study applying artificial intelligence to heart sounds for the detection, monitoring, or characterization of cardiac amyloidosis was identified. Supporting literature on pathophysiology, imaging-based artificial intelligence, and heart sound analysis in other cardiovascular conditions was selected narratively for relevance rather than by systematic criteria.

3. Fundamentals of Heart Sound Analysis in Cardiac Amyloidosis

3.1. Pathophysiology and Its Acoustic Manifestations

Cardiac amyloidosis arises from the extracellular deposition of misfolded protein fibrils within the myocardial interstitium [21,22]. In AL amyloidosis the precursor is a monoclonal immunoglobulin light chain produced by a clonal plasma cell population. In ATTR amyloidosis it is transthyretin, a hepatically synthesized transport protein that circulates as a tetramer and must dissociate into monomers before it can misfold and aggregate into fibrils [4,23]. ATTRv is driven by a destabilizing point mutation in the transthyretin gene, whereas ATTRwt reflects an aging-related loss of tetramer stability, which is why ATTRwt-CM is increasingly recognized in older adults [24]. Both routes end at the same point, the accumulation of insoluble amyloid within the interstitial space, and this accumulation produces the cardiac phenotype.

The increased wall thickness seen in amyloidosis differs from the cellular enlargement of hypertrophic and hypertensive remodeling, since it reflects infiltration of the interstitial space rather than true myocyte hypertrophy. That difference explains one of the disease's most recognizable signatures, a disproportion between the degree of ventricular thickening and the electrocardiographic voltage, classically described as low QRS voltage despite increased wall thickness. Low voltage is a useful red flag but is neither required nor sensitive for the diagnosis, and it is less frequent in ATTR than in AL disease, so the broader concept of voltage-to-mass disproportion is the more reliable signature [2,14]. The same infiltrative process expands the extracellular volume, a change that cardiac magnetic resonance can quantify and that helps separate amyloid from other causes of a thickened ventricle [25]. As amyloid accumulates, the myocardium grows progressively thicker and stiffer, and the ventricle loses its capacity to relax and fill normally during diastole, producing the restrictive filling physiology that characterizes this cardiomyopathy [1,26]. Diastolic dysfunction is the earliest and dominant functional consequence, frequently progressing to a restrictive transmitral filling pattern while systolic ejection fraction stays relatively preserved until late, even as longitudinal contraction declines in a base-to-apex gradient that underlies the echocardiographic pattern of relative apical sparing [27]. Elevated filling pressures

and impaired compliance lead to atrial dilation, and direct infiltration of the atria further impairs their mechanical function, which raises the prevalence of atrial fibrillation even in patients who remain in sinus rhythm [1,26]. Infiltration may also involve the specialized conduction system, producing sinus node dysfunction, atrioventricular block, and bundle branch block.

These structural and functional changes translate directly into altered heart sounds. Heart sounds are mechanical vibrations generated by valve closure, myocardial motion, and the deceleration of blood as it strikes a noncompliant chamber. When the ventricle is stiffened by amyloid, the abrupt arrest of early diastolic filling against a rigid wall generates a low-frequency vibration audible as a third heart sound, while forceful atrial contraction against the same chamber may generate a fourth heart sound. The acoustic consequences of restrictive physiology therefore are mechanistically linked to the tissue-level remodeling of the disease, which is the rationale for investigating heart sounds as a candidate diagnostic signal. These sounds are not specific to amyloidosis, and whether they can discriminate it from other causes of impaired ventricular filling has not been established [28]. Figure 2 summarizes this pathophysiological sequence and its acoustic consequences.

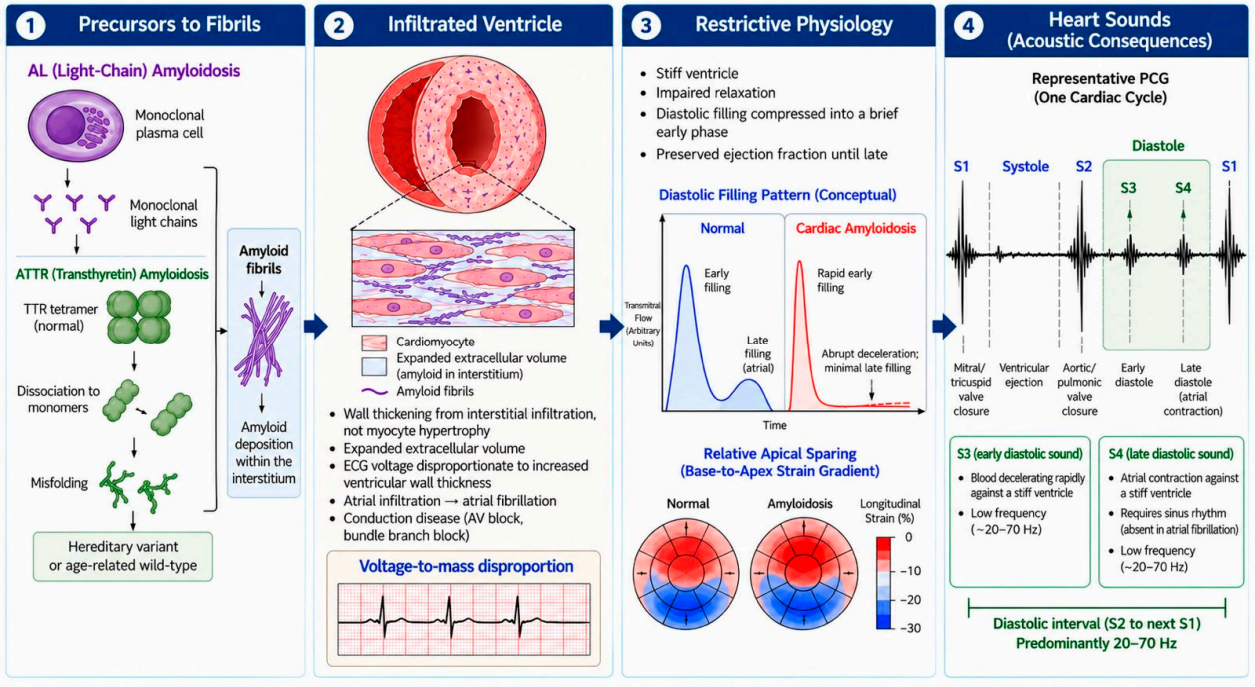

Figure 2. Pathophysiological progression and acoustic consequences of cardiac amyloidosis. Misfolded immunoglobulin light chains in AL amyloidosis or transthyretin (ATTR) proteins deposit as extracellular amyloid fibrils within the myocardial interstitium, producing ventricular wall thickening without true myocyte hypertrophy. Progressive interstitial infiltration expands the extracellular volume, causes a disproportion between electrocardiographic voltage and ventricular mass (classically low QRS voltage despite increased wall thickness), and leads to restrictive ventricular physiology with impaired relaxation and preserved ejection fraction until late disease. These mechanical alterations modify ventricular filling dynamics and may generate low-frequency diastolic heart sounds, including the third heart sound (S3) during rapid early filling and the fourth heart sound (S4) during atrial contraction in patients with preserved sinus rhythm. Together, these candidate acoustic manifestations provide a mechanistic rationale for phonocardiographic analysis of cardiac amyloidosis and for artificial intelligence models that might use heart sounds as a diagnostic signal. The depicted features and applications have not been validated in cardiac amyloidosis.

3.2. Traditional Heart Sound Findings

The auscultatory findings in cardiac amyloidosis are dominated by the diastolic filling sounds that reflect impaired ventricular compliance. How these sounds arise has been studied for more than a century and is best understood through the deceleration of blood during ventricular filling [29,30]. A third heart sound corresponds to the phase of rapid early diastolic filling and appears when inflowing blood decelerates abruptly against a stiff ventricle [1]. Its generation depends not only on ventricular stiffness but also on the rate and volume of early filling, on filling pressures, and on systolic function, and a third heart sound occurs in many conditions other than amyloidosis, including heart failure of any cause. The fourth heart sound is more closely tied to reduced ventricular compliance, but it requires effective atrial contraction and is therefore absent in atrial fibrillation. These distinctions matter if the sounds are proposed as candidate features for an automated model. A physiologic third heart sound is normal in children and young adults and disappears with age, so its reappearance in an older adult signals augmented early filling against a stiff, high-pressure ventricle and becomes pathological [31]. Advanced diastolic dysfunction is the expected state in established amyloidosis, which ties the third heart sound closely to the degree of stiffening and to elevated filling pressure. The sound matters for signal processing because it is a low-frequency, low-amplitude event confined to the diastolic interval, the same window that automated analysis must resolve.

The fourth heart sound, produced by atrial contraction propelling blood into a poorly compliant ventricle in late diastole, relates to amyloid subtype in a less straightforward way. Classical teaching held that it is exceedingly rare in AL cardiac amyloidosis despite the presence of restrictive physiology, a finding attributed to early loss of atrial mechanical function. Recent phonocardiographic work has shown that the picture differs in ATTRwt-CM, where a fourth heart sound was detected in roughly half of patients in sinus rhythm, and where its presence was associated with more preserved left atrial function and a more favorable short-term prognosis [32]. A sound that depends on intact atrial contraction can therefore serve as a marker of atrial functional reserve, which shows that heart sounds carry information well beyond simple detection and may even stratify patients within the same disease category. There is a practical caveat, since a fourth heart sound cannot be expected in patients who have progressed to atrial fibrillation, common in this population, which removes the atrial contribution to filling altogether. Beyond the gallop sounds, amyloid infiltration commonly thickens the valves and papillary muscles and may generate murmurs of regurgitation [31]. None of these findings are specific for amyloidosis, and many are subtle and easily overlooked at the bedside, which is the exact limitation that computational analysis is meant to address.

3.3. Structural Remodeling and Heart Sound Changes

The relationship between structural remodeling and the acoustic phenotype rests on the features already described, and its most important aspect for automated analysis is where the diagnostic information sits. Increased stiffness is the principal determinant of the diastolic gallop sounds, because a wall that resists deformation decelerates inflowing blood more abruptly. Restrictive physiology then shapes how acoustic energy is distributed across the cardiac cycle. In a healthy ventricle diastole is acoustically quiet, whereas in the restrictive ventricle filling is compressed into a brief, high-velocity early phase that concentrates diastolic energy into the narrow window in which the third heart sound is generated [1]. The ratio of diastolic to systolic acoustic energy, together with where that energy sits within diastole, therefore becomes a potentially informative quantitative feature. These are low-frequency events, generally between roughly 20 and 70 Hz, which places them at the lower boundary of what conventional auscultation and many automated

segmentation methods reliably capture. The acoustic manifestations of amyloidosis are diffuse and subtle, reflecting a gradual infiltrative process rather than a focal lesion [33], and they differ in this from the discrete, high-amplitude murmurs that dominate classical valvular disease and most existing classification benchmarks [28,32]. The difficulty lies in how quiet and diffuse these findings are, and it explains why methods developed for general murmur detection need deliberate adaptation before they can be applied here.

4. Techniques and Machine Learning Methods for Heart Sound Analysis

4.1. Cardiac Auscultation and Phonocardiography

Cardiac auscultation has long been the primary method of bedside cardiovascular assessment, but recent advances in digital phonocardiography have changed how heart sounds are captured and analyzed. A phonocardiogram is an electronic recording of the acoustic signals produced by the mechanical activity of the heart, including valvular closure, myocardial vibration, and turbulent flow, which typically fall within a frequency range of roughly 20 to 1000 Hz [34]. Conventional acoustic stethoscopes remain widely used, yet their effectiveness depends heavily on signal quality, clinician experience, and subjective interpretation. Digital stethoscopes address many of these limitations, since they capture the heart sound as a digital signal that can be amplified, transmitted wirelessly to analytical software, and processed by noise-robust algorithms [35]. Not all devices capture the low-frequency band equally, so amplification, filtering, and microphone response should be specified when recordings are intended for analysis. Contemporary systems such as the Eko CORE 500 Digital Stethoscope, which has received United States Food and Drug Administration clearance and pairs with artificial-intelligence-based murmur detection software, record heart sounds digitally and could support scalable deployment in lower-resource settings [36].

The shift toward automated analysis accelerated after the 2016 PhysioNet/Computing in Cardiology Challenge, which established standardized benchmarks for recognizing abnormal heart sounds from phonocardiogram recordings [37]. The 2022 George B. Moody PhysioNet Challenge then introduced the CirCor DigiScope dataset, which comprised 5272 recordings from 1452 patients collected at the four standard auscultation sites and provided a benchmark for both murmur detection and clinical outcome prediction [38]. These open access initiatives drove substantial progress in segmentation, feature extraction, and classification, and they established shared evaluation frameworks that continue to guide algorithm development.

4.2. Signal Processing for Segmentation and Feature Extraction

Before heart sounds can be classified, the raw phonocardiogram must be preprocessed and segmented into the major phases of the cardiac cycle, namely, the first heart sound, systole, the second heart sound, and diastole. Segmentation matters because it underpins the rest of the pipeline, and errors introduced at this stage propagate through later processing and degrade performance [39]. Preprocessing aims to improve signal quality while preserving clinically meaningful information, suppressing respiratory noise, environmental interference, and high-frequency artefacts while retaining the frequency components most relevant to auscultation, after which amplitude normalization reduces the variability introduced by different recording conditions and sites [40,41].

Segmentation has traditionally relied on energy-based methods such as the Shannon energy envelope, which accentuates the high-energy components of the signal to make the first and second heart sounds easier to identify. Liang and colleagues introduced this approach, and Springer and colleagues later enhanced it through a logistic regression hidden semi-Markov model that treats the cardiac cycle as a sequence of four physiological

states and combines acoustic features with probabilistic duration constraints, assigning each segment to its corresponding phase and improving segmentation substantially under controlled conditions [42]. Methods of this kind remain relevant. Arjoune and colleagues developed a noise-robust Shannon-energy algorithm that identified the boundaries of the first and second heart sounds with sub-millisecond precision, 0.28 and 0.29 milliseconds respectively; ran roughly four times faster than logistic-regression hidden semi-Markov approaches; and reached a segmentation success rate of 87.4% on a real-world pediatric dataset [35]. Recurrent neural networks have improved segmentation further by capturing temporal relationships between adjacent portions of the signal that frame-by-frame classifiers cannot model, which matters because cardiac sounds occur in a highly structured, repetitive sequence. The hybrid recurrent-network and parallel hidden semi-Markov architecture of McDonald and colleagues won first place in both tasks of the 2022 PhysioNet Challenge and showed that combining deep learning with physiologically informed state-based modeling can improve accuracy and generalization while keeping the output interpretable to clinicians [39].

Once the signal has been segmented, it must be converted into quantitative features suitable for machine learning, drawn from the time domain, the frequency domain, or combined time–frequency representations [43]. Mel-frequency cepstral coefficients are the most widely used, since they condense the signal into a compact set of coefficients on the logarithmic Mel scale that approximates human auditory perception while reducing sensitivity to noise, and their temporal derivatives add information about the rate of spectral change [44]. Log-Mel spectrograms have become a popular alternative in deep learning, mapping acoustic energy across the Mel scale over time in a two-dimensional format that lets convolutional networks learn hierarchical representations directly from the data, and they have been shown to reduce cross-domain variability [45]. More advanced methods, including higher-order spectral analysis such as bispectral features, capture nonlinear couplings between frequency components and have been used to classify heart sounds [46]. Together these methods expand the information available to a model and may improve detection of the subtle pathological changes that conventional auscultation cannot discern.

4.3. Deep Learning Architectures for Classification

Deep learning applied to phonocardiogram analysis has moved from handcrafted features toward systems that learn directly from audio, chiefly convolutional, recurrent, and transformer-based networks. Convolutional networks are the most widely used because they learn complex patterns automatically from spectrograms and allow established image-recognition architectures to be reused through transfer learning [47], and a review of studies published between 2017 and 2022 found them to be the dominant approach in the field [48]. Their main limitation is that they do not explicitly model long-range temporal relationships, which prompted hybrid convolutional–recurrent designs that pair convolutional feature extraction with long short-term memory layers across the cardiac cycle. Nguyen and colleagues reported an accuracy of 99.67% for multiclass classification with such a model on Log-Mel spectrograms, although the figure came from a small, curated five-class dataset and should be read with that constraint in mind [49].

Transformer-based architectures replace convolution and recurrence with self-attention, which suits long-range time–frequency dependencies. The Audio Spectrogram Transformer, the first fully attention-based architecture developed for audio classification, learns global relationships across a Log-Mel spectrogram divided into patches and achieves state-of-the-art results on several benchmarks when pretrained on large datasets [50], and in heart sound analysis such models, including hybrid vision–transformer and convolutional de-

signs, have shown performance comparable to and sometimes exceeding convolutional networks [51]. End-to-end pipelines that bypass explicit segmentation have also emerged, although results from the 2022 PhysioNet Challenge showed that hybrid approaches combining segmentation and classification remained highly competitive and offered greater interpretability [38], which will matter more as artificial-intelligence-assisted auscultation moves closer to routine use.

4.4. Feature Extraction and Ensemble Methods for Amyloidosis Acoustic Signatures

The acoustic manifestations of cardiac amyloidosis are hard to classify. General heart sound analysis focuses on identifying abnormal sounds, whereas amyloidosis requires detecting the subtle changes produced by progressive infiltration of a thickened, noncompliant ventricle. The resulting signatures are complex, low in amplitude, and variable across disease stages, and feature sets developed for murmur detection or binary classification may not capture them adequately. The diastolic phase deserves particular attention, since it contains the third and fourth heart sounds, and resolving them requires segmentation that can capture subtle activity within the diastolic window, where traditional Shannon-energy approaches may have limited sensitivity. Alternative methods such as the tunable quality wavelet transform and the frequency-band-shrinkage empirical wavelet transform provide improved time–frequency resolution at lower frequencies and have shown promise for characterizing valvular heart sounds [52]. Features likely to be informative in amyloidosis include the ratio of diastolic to systolic energy, the temporal distribution of diastolic acoustic energy, and the presence of low-frequency components consistent with a third or fourth heart sound.

Two strategies suit the central obstacle in this setting, the rarity of the disease and the resulting scarcity of labeled data. Ensemble methods combine predictions from several models to improve robustness on unseen recordings, and they have performed well on multi-disease phonocardiogram datasets, which suggests they could pair models trained on limited disease-specific recordings with models pretrained on larger cardiac sound databases [53]. Transfer learning addresses the same problem more directly, initializing a model with weights learned from large audio or cardiac sound datasets before fine-tuning on smaller amyloid-specific cohorts, and resources such as AudioSet and the CirCor DigiScope dataset provide acoustic representations that may partly generalize to the pathological features of amyloidosis [44]. A substantial domain shift separates the available open phonocardiogram datasets from the intended population. The CirCor DigiScope resource is predominantly pediatric, whereas ATTR-CM mainly affects older adults with higher rates of atrial fibrillation, conduction and valve disease, different heart rates, and different chest-wall characteristics. Transfer learning from these resources may help, but its biological and technical generalizability to amyloidosis cannot be assumed and will require disease-specific fine-tuning and external validation. CardioPHON, a publicly available model pretrained specifically on phonocardiogram recordings, has recently shown that large-scale pretraining can substantially improve data efficiency in rare-disease applications [54].

Multimodal learning offers a further opportunity, because amyloidosis affects several physiological domains at once and produces acoustic, electrical, and structural abnormalities. Models that integrate heart sounds with electrocardiographic features, demographic information, circulating biomarkers, and imaging-derived measures may outperform acoustic-only approaches. The 2022 PhysioNet Challenge supplied demographic and clinical variables alongside the recordings, and combining these with the phonocardiogram was a common strategy among entries [38], while similar frameworks that merge electrocardiographic and echocardiographic information have been explored in cardiovascular artificial intelligence [55]. Extending these approaches to include acoustic biomarkers could support a fully non-invasive, point-of-care diagnostic pipeline for cardiac amyloidosis.

5. Clinical Evidence and Current AI Applications

The evidence in this section falls into two categories that should not be conflated. Direct evidence comes from artificial intelligence applied to the electrocardiogram and echocardiogram in cardiac amyloidosis. Indirect evidence comes from heart sound analysis in other cardiovascular conditions. Only the former has been evaluated in the disease itself.

Artificial intelligence has advanced unevenly across the cardiac amyloidosis diagnostic pathway. Electrocardiographic and echocardiographic models have reached external validation, and both have received regulatory clearance, whereas acoustic analysis of heart sounds has not yet been studied directly in this disease, despite carrying the lowest barrier to deployment of any cardiac modality. The evidence base is therefore heavily skewed toward imaging, even though the modality that would be easiest to deploy remains the least explored.

The electrocardiographic evidence is the most mature. Grogan et al. at Mayo Clinic developed a deep neural network using 12-lead electrocardiograms from 2541 patients with light-chain or transthyretin amyloidosis, matched to 2454 controls [18]. The 12-lead model reached an area under the curve of 0.91, with a sensitivity of 0.84 and a specificity of 0.85 at the optimal threshold, and it identified amyloidosis more than six months before clinical diagnosis in 59% of cases, while a single-lead version using lead V5 retained an area under the curve of 0.86, which raised the prospect of screening through smartphone-enabled electrodes [18]. Real-world validation tempered these figures. Harmon and colleagues applied the algorithm to 440 patients diagnosed after model development against 6600 matched controls, where the area under the curve settled at 0.84, and although performance held across age, sex, and most racial groups, it declined in patients with left bundle branch block or left ventricular hypertrophy and fell to 0.66 in Hispanic patients [56]. Strong performance at development, followed by modest attrition on subsequent post-development validation and disparities in particular subgroups, is a pattern that recurs throughout the field, and it should temper expectations for any single modality. The approach also generalizes beyond a single institution and signal format. Croon, Sangha, and colleagues trained a convolutional network on images of 12-lead electrocardiograms rather than raw waveforms, and in a substantially expanded analysis reported an area under the curve of 0.87 (95% confidence interval 0.82 to 0.91), with performance maintained across eight multinational validation cohorts in the United States and Europe spanning a wide range of disease prevalence, and across three prospective screening cohorts that included older Black and Hispanic adults with heart failure and patients with prior carpal tunnel surgery [57]. An image-based model matters for low-resource settings, where electrocardiograms are often archived as paper or scans, and it establishes that the electrical signature of amyloid infiltration is robust to how the tracing is captured. In April 2026 the first artificial intelligence electrocardiographic algorithm for cardiac amyloidosis received United States Food and Drug Administration clearance, validated in a multicenter study of more than 25,000 patients that included both ATTR and AL disease, with a reported sensitivity of 78.9% and specificity of 91.2% [19]. The software is cleared as a notification and triage aid that flags patients for further evaluation, not as a stand-alone diagnostic test. An echocardiographic algorithm that analyzes a single apical four-chamber clip was cleared in 2024 as a screening aid for adults aged 65 years and older with heart failure [20].

Echocardiographic models have achieved comparable and, in several respects, more rigorously validated results. Automated analysis extends established echocardiographic markers, since the relative apical sparing pattern of longitudinal strain is a useful echocardiographic red flag, although its diagnostic performance is lower in real-world and multicenter cohorts than in the original selected series, and the pattern can occur in phenocopies, so it is best interpreted within a multiparametric assessment [27], and deep learning can

now recognize such patterns directly from images. EchoNet-LVH, a computer-vision algorithm operating on parasternal long-axis and apical four-chamber videos, was evaluated by Duffy and colleagues across five geographically and ethnically diverse cohorts in the United States and Japan, spanning 574 amyloidosis patients and 979 controls, and achieved an area under the curve of 0.896 with a sensitivity of 0.644 and a specificity of 0.988 at a threshold deliberately optimized to maximize positive predictive value in a rare disease, with discrimination consistent across sites, sex, age, body mass index, subtype, and vendor [58]. More recent work has compressed the input requirement. Slivnick and colleagues developed a model requiring only a single apical four-chamber clip, validated in an international cohort of 2719 patients with a 22% amyloidosis prevalence, where it reached an area under the curve of 0.93 with 85% sensitivity and 93% specificity and outperformed both a transthyretin clinical score and wall thickness alone [59]. Simpler inputs still can carry signal. Chang and colleagues built a random forest model that used only 19 routine echocardiographic report measurements to detect amyloidosis with an area under the curve of 0.84, drawing chiefly on mitral A-wave velocity, global longitudinal strain, and posterior wall thickness, though the model was developed at a single center and validated only internally [60]. Across these studies the input has shrunk from multi-view acquisition to a single clip and then to tabular measurements already in the chart, which follows the same deployment logic that a heart sound classifier would extend further still.

The most instructive evidence comes from combining modalities. Goto and colleagues built a fully automated pipeline using electrocardiography or echocardiography as inputs, trained and validated across three and five academic medical centers respectively, reporting C-statistics of 0.85 to 0.91 for electrocardiography and 0.89 to 1.00 for echocardiography [55]. The electrocardiographic model alone yielded a positive predictive value of only 3 to 4% at 52 to 71% recall, which reflects the difficulty of screening a rare disease, yet prescreening with electrocardiography raised the echocardiographic positive predictive value at 67% recall from 33% to between 74 and 77% [55]. A cheaper upstream test need not be accurate on its own to be useful, because its role is to concentrate disease prevalence before confirmatory imaging, and a heart sound classifier could occupy that position in the pathway. The same logic reaches the preclinical window, since Oikonomou and colleagues showed that artificial intelligence applied to routine electrocardiograms and echocardiograms can track the preclinical progression of ATTR-CM, detecting signal before clinical diagnosis [61]. Beyond detecting the disease, these tools can now follow how it progresses over time.

Against this backdrop the acoustic literature is almost silent. Sato and colleagues showed, in hypertrophic cardiomyopathy, that the third heart sound independently predicted myocardial fibrosis on late gadolinium enhancement imaging, with an odds ratio of 10.4 and a specificity of 97% [28], so a heart sound carries information about the same tissue-level remodeling that defines infiltrative disease. The transferable evidence is substantial. Chorba and colleagues trained a deep neural network and tested it in 962 patients, detecting murmurs with a sensitivity of 76.3% and a specificity of 91.4% and identifying moderate or greater aortic stenosis with a sensitivity of 93.2% [62], and Ghanayim and colleagues showed that an artificial-intelligence-based stethoscope with infrasound capability identified moderate or severe aortic stenosis with 86% sensitivity and 100% specificity in derivation and 84% sensitivity and 92% specificity in validation [63]. Aortic stenosis is an apt analogue, since it shares an elderly population, a stiffened ventricle, and low-flow physiology with amyloidosis, and the two coexist often enough that unrecognized transthyretin amyloidosis is found in a meaningful fraction of older patients with severe aortic stenosis [64]. Ogawa and colleagues offer the most direct evidence, having trained an ensemble model to estimate a B-type natriuretic peptide of 100 pg/mL or greater from eight

seconds of heart sound and electrocardiographic data; validated it prospectively across multiple centers in 140 patients, where it reached an area under the curve of 0.895 rising to 0.959 in patients of normal body mass index; and found that the model drew on the first heart sound and the diastolic interval, the same physiology that amyloid infiltration disrupts [65]. These studies establish technical feasibility that clinically relevant information can be extracted from acoustic signals, rather than evidence of an amyloidosis-specific acoustic signature. Aortic stenosis models detect a valvular systolic signal, hypertrophic cardiomyopathy represents a different myocardial substrate, and B-type natriuretic peptide prediction reflects hemodynamic load, so none of them shows that an amyloid-specific phenotype can be learned. The evidence is suggestive rather than confirmatory, since it comes from adjacent conditions and from cohorts smaller than those that have validated the imaging models. A dataset, a model, and a prospective trial directed at amyloidosis are all still missing, and that absence, more than any acoustic limitation, is why heart sound analysis sits behind its imaging counterparts. The landmark imaging studies that anchor this evidence base are summarized in Table 1.

Table 1. Landmark artificial intelligence studies for cardiac amyloidosis on the electrocardiogram and echocardiogram.

Study	Status	Modality and Model	Cohort (Cases/Controls)	Performance	Validation Type	Ref
Grogan et al., 2021	Peer-reviewed	12-lead ECG: Deep neural network	2541/2454 (51%); AL and ATTR	AUC 0.91; Sn 0.84; Sp 0.85; single-lead V5 AUC 0.86; detected >6 months before diagnosis in 59%	Internal (single-center, retrospective)	[18]
Harmon et al., 2023	Peer-reviewed	12-lead ECG; post-development validation of the Grogan model	440/6600 (6%)	AUC 0.84; reduced with LBBB or LVH; AUC 0.66 in Hispanic patients	Temporal; patients diagnosed after model development	[56]
Croon et al., 2026	Preprint (medRxiv)	12-lead ECG images; convolutional neural network	Multinational; 8 validation cohorts; ATTR-CM	AUC 0.87 (95% CI 0.82–0.91); consistent across 8 cohorts and 3 prospective screening cohorts	External; 8 multinational cohorts (US and Europe) plus 3 prospective screening cohorts	[57]
Duffy et al., 2025	Peer-reviewed	Echocardiography (PLAX and A4C videos); computer vision (EchoNet-LVH)	574/979 (37%) across 5 cohorts (US and Japan); AL and ATTR	AUC 0.896; Sn 0.644; Sp 0.988; site-level AUC 0.860–0.944	External; multi-site, multi-ethnic, multi-vendor	[58]
Slivnick et al., 2025	Peer-reviewed	Single A4C echocardiographic clip; deep learning	2719 (22% amyloidosis prevalence)	AUC 0.93; Sn 85%; Sp 93%; outperformed ATTR clinical score and wall thickness	External; international cohort	[59]
Chang et al., 2024	Peer-reviewed	19 echocardiographic report measurements; random forest	Single-center	AUC 0.84; top predictors mitral A-wave, GLS, posterior wall thickness	Internal only	[60]

Table 1. *Cont.*

Study	Status	Modality and Model	Cohort (Cases/Controls)	Performance	Validation Type	Ref
Goto et al., 2021	Peer-reviewed	ECG and echocardiography (combined); automated multimodal pipeline	3 (ECG) and 5 (echo) academic centers	C-statistic ECG 0.85–0.91; echo 0.89–1.00; ECG pre-screen raised echo PPV at 67% recall from 33% to 74–77%	Multi-center	[55]
Oikonomou et al., 2025	Peer-reviewed	ECG and echocardiography (longitudinal); deep learning	ATTR-CM, preclinical cohort	Detected signal before clinical diagnosis of ATTR-CM	External	[61]

Status is peer-reviewed full publication unless stated. Validation type: internal, held-out data from the development site; temporal, later patients from the same health system; external, independent sites or populations. Percentages show cases as a share of the reported case and control counts, reflect study design rather than population prevalence, and, together with the case–control and enriched cohorts used, are likely to overstate performance in real-world screening populations where prevalence is low. Confidence intervals, calibration, and patient-level versus ECG-level sampling were not reported uniformly and should be taken from the source publications. Subtype is shown where the source analysis specified it. Abbreviations: ECG, electrocardiogram; AUC, area under the receiver operating characteristic curve; Sn, sensitivity; Sp, specificity; PPV, positive predictive value; LBBB, left bundle branch block; LVH, left ventricular hypertrophy; PLAX, parasternal long-axis; A4C, apical four-chamber; GLS, global longitudinal strain; ATTR-CM, transthyretin amyloid cardiomyopathy.

6. Clinical Implementation and Workflow Integration

6.1. Point-of-Care Screening Using Digital Stethoscopes

Point-of-care screening with digital stethoscopes and artificial intelligence offers a way to detect cardiac disease earlier, which matters in amyloidosis because the diagnosis is so often delayed and many patients first present with heart failure symptoms. Traditional auscultation remains part of daily practice because it is quick, inexpensive, and familiar, but it depends heavily on the listener's skill and experience, and many relevant sounds are faint or fall outside the range of reliable human hearing. Ogawa and colleagues attribute these limitations to skill gaps, poor sound quality, and the absence of objective measurement [66]. Digital stethoscopes address several of them by recording heart sounds as phonocardiogram signals that can be stored, shared, and analyzed by artificial intelligence, which makes interpretation less subjective and lets the sounds themselves serve as potential biomarkers. The same group described the Super StethoScope system, which records heart sounds and electrocardiographic signals at the same time, a pairing that is useful because the two reflect the mechanical and electrical activity of the heart respectively and together may improve screening [66].

Artificial intelligence adds value by identifying patterns within heart sounds. Reviewing deep learning methods, Partovi and colleagues found that convolutional networks were most often used for classification while recurrent networks were applied to segmentation, and they cautioned that high reported accuracy does not always translate into clinical usefulness and depends on the dataset, the testing method, the disease, and the quality of the recording [67]. That caution applies with particular force in amyloidosis, where disease-specific data remain limited. Several studies still illustrate what low-cost acoustic screening can achieve. Roy and colleagues built an ear-contactless stethoscope whose convolutional network reached 99.65% accuracy, with 98.8% sensitivity and 98.2% specificity, in screening for valvular disease [68], and although the device cannot confirm amyloidosis, it shows that artificial intelligence can classify heart sounds with high accuracy. Accuracy values

approaching 100% derive from small or curated datasets, and performance in real-world settings, with noisier and more heterogeneous recordings and in a subtle, low-amplitude phenotype such as amyloidosis, is likely to be substantially lower. Portable tools may extend this reach beyond the hospital. Lee and colleagues developed a finger-ring-shaped smart stethoscope that records phonocardiographic and photoplethysmographic signals together, detects the first and second heart sounds with performance close to professional systems, and is small enough for self-monitoring [69]. Work in congenital and valvular disease points the same way. Xu and colleagues reported that artificial intelligence stethoscopes can improve detection of congenital heart disease while calling for better databases and standardized methods [70], and Ainiwaer and colleagues reached similar conclusions while stressing that the field remains early and that models must be tested across different devices and patient groups before they can be applied to amyloidosis [71]. Because amyloidosis frequently presents as heart failure, work applying phonocardiographic machine learning to heart failure care, which may aid both diagnosis and prognosis [72], is directly relevant, as is the observation that renewed interest in phonocardiography could see acoustic analysis fit naturally into cardiology workflow [73]. In amyloidosis these tools would raise suspicion and prompt referral earlier, while patients still require imaging, biomarkers, and specialist review for the diagnosis itself. The next steps are to build dedicated acoustic datasets and to test them in patients with suspected disease under real-world conditions.

6.2. Integration into Outpatient, Primary Care, and Resource-Limited Settings

Cardiac amyloidosis is often diagnosed late because patients first present with common and nonspecific symptoms, including heart failure, fatigue, arrhythmias, neuropathy, and orthopedic complaints, which resemble other conditions and lead the diagnosis to be missed. The consequences of delay are greatest in AL cardiac amyloidosis, which De Michieli and colleagues describe as a medical emergency because cardiac involvement sharply reduces survival, noting that many patients first present to non-specialist clinicians and that testing for serum-free light chains with serum and urine immunofixation should not be delayed once the disease is suspected [74]. Delay is equally common in ATTR-CM. Rozenbaum and colleagues found that patients with ATTRwt-CM waited about six years for a diagnosis, that those with ATTRv-CM faced similar delays, and that many were misdiagnosed and saw several providers before the correct diagnosis was reached [75]. Much of this delay reflects how closely ATTR-CM mimics heart failure with preserved ejection fraction, aortic stenosis, arrhythmias, and conduction disease, an overlap that artificial-intelligence-assisted auscultation could help resolve by flagging patients who need further testing, even though it cannot confirm the disease itself.

Primary care has an important part to play, because amyloidosis affects more than one organ system. Gertz and colleagues developed recommendations for general practitioners, noting that ATTR amyloidosis is often missed because its symptoms span cardiac, neurological, gastrointestinal, and general presentations, and they proposed a pathway built around warning signs [76], while Gill and colleagues advised clinicians to consider the disease in patients with heart failure, arrhythmias, aortic stenosis, or otherwise unexplained cardiac findings [77]. Acoustic analysis could support these pathways by helping decide who needs an electrocardiogram, biomarkers, echocardiography, bone scintigraphy, genetic testing, or specialist review, and because many such patients already undergo routine cardiac assessment, an artificial-intelligence-enabled stethoscope could fit into that workflow with little additional equipment. The case for targeted rather than population-wide screening is strong, since Aimo and colleagues identified cardiac amyloidosis in 12% of patients with heart failure with preserved ejection fraction, 8% of those with severe aortic stenosis, and 7% of patients undergoing carpal tunnel surgery, with similar rates among patients

showing a hypertrophic cardiomyopathy pattern [11]. The extracardiac associations are increasingly recognized as early windows onto the disease, since amyloid is found in the tenosynovial tissue of a meaningful fraction of older patients undergoing carpal tunnel release, often years before cardiac involvement is apparent [78], and transthyretin amyloidosis is now actively sought in older patients with severe aortic stenosis, in whom it alters prognosis [64]. Targeted screening of this kind may be especially useful where resources are limited and advanced imaging is hard to access, since a low-cost stethoscope could serve as the first step and abnormal findings could be referred onward. Caponetti and colleagues similarly supported screening in selected settings, describing amyloidosis as a disease that hides behind other conditions and stressing the value of warning signs and combined assessment [79], and awareness of non-cardiac features matters just as much, since Nativi-Nicolau and colleagues noted that carpal tunnel syndrome may appear years before diagnosis, alongside lumbar spinal stenosis, distal biceps tendon rupture, autonomic dysfunction, and neuropathy [80].

A stepwise pathway may therefore work best. During a routine visit a clinician could use an artificial-intelligence-enabled stethoscope, and if it detected unusual sound patterns the clinician could review other warning signs before proceeding to NT-proBNP, troponin, serum-free light chains and immunofixation, echocardiography, bone scintigraphy, cardiac magnetic resonance imaging, or specialist referral, which allows early screening while keeping current diagnostic standards intact. That safeguard matters most in AL amyloidosis, where a screening tool must never delay urgent hematological assessment. Fontana and colleagues reported that imaging and artificial intelligence are already changing amyloidosis care and may help identify at-risk patients during routine testing [81], although such tools must be affordable, simple, and properly validated, and their results should guide the next step in care rather than simply label a sound as abnormal, since without clear referral pathways screening risks confusion, false reassurance, or unnecessary referrals.

6.3. Role in Prognosis and Disease Monitoring

Prognosis and long-term monitoring remain difficult in cardiac amyloidosis, because the disease presents late, affects patients in different ways, and continues to damage the heart over time. Established biomarkers such as NT-proBNP, troponin, and serum-free light chains help clinicians assess risk and follow the response to treatment [82], yet they may not fully predict outcomes, since many patients also carry other cardiac or systemic disease [83]. Machine learning can support these tools by combining clinical data, electrocardiographic findings, imaging results, and laboratory tests to predict progression, classify risk, and guide treatment choices [84], and artificial intelligence electrocardiographic models can detect small electrical changes linked to a higher risk of death that may not be apparent on routine review. An amyloid artificial intelligence electrocardiographic score, for example, predicted mortality in both AL and ATTR amyloidosis independently of established risk factors including Mayo stage [85], and electrocardiographic changes such as wider QRS complexes and conduction delay are also associated with advanced disease and poor outcomes [86], which artificial intelligence could help to track more closely during follow-up. Combining several data sources may prove more useful still, allowing early worsening to be detected before standard biomarkers change [87], and multimodal frameworks that integrate imaging, electrical, and laboratory data are being explored for exactly this purpose [88,89]. Important limitations remain, since many studies are retrospective or single-center and some rely on small datasets that can make results appear stronger than they are, so standardized methods, larger studies, and prospective testing are needed before routine use. Used together with biomarkers, artificial intelligence may nonetheless help refine prognosis and guide treatment at the right time, and so can improve outcomes

for patients with cardiac amyloidosis. Prognostic information from electrocardiographic and multimodal models should be distinguished from longitudinal treatment monitoring, for which no acoustic evidence exists.

7. Advantages, Limitations, and Equity Considerations

7.1. Scalability and Accessibility

Artificial intelligence for cardiac amyloidosis is now cleared for both the electrocardiogram and the echocardiogram, yet each still depends on a test that must first be acquired and interpreted, and echocardiography, scintigraphy, and cardiac magnetic resonance remain infrastructure-heavy [90]. Screening at the very first encounter, before any test has been recorded, therefore remains unaddressed. A heart sound classifier could fill that gap, since the signal is captured with a stethoscope rather than a scanner, although this depends on validated, artificial intelligence-compatible acquisition becoming available. Point-of-care artificial-intelligence stethoscopes have demonstrated the principle in valvular disease and heart failure, if not yet in amyloidosis [91,92], and because machine learning can flag amyloid-associated patterns on routinely acquired investigations, it may raise suspicion and support earlier diagnosis of a disease that is otherwise frequently missed [60]. The comparative characteristics of the three main cardiac signals as candidates for artificial intelligence screening are summarized in Table 2.

Table 2. Comparison of the electrocardiogram, echocardiogram, and heart sound as candidates for artificial-intelligence-based screening for cardiac amyloidosis.

Attribute	Electrocardiogram	Echocardiography	Heart Sound (Phonocardiogram)
Availability of the clinical test at first contact	High	Low	High
Availability of validated, AI-compatible acquisition and software for amyloidosis	Yes, cleared as a triage aid (2026)	Yes, cleared as a screening aid (2024)	None to date
Equipment cost	Low to moderate	High	Low to moderate (digital stethoscope)
Operator skill for acquisition	Low	High	Low for acquisition, but signal quality is operator-sensitive (position, contact pressure, movement, noise)
Training data for amyloidosis	Large, multi-center	Growing, multi-cohort	None specific to amyloidosis
External validation for amyloidosis models	Yes	Yes	Not applicable
Suitability for repeated or ambient sampling	Moderate	Low	High
Interpretability of AI outputs	Moderate	Moderate to high	Low to moderate
Direct AI evidence in cardiac amyloidosis	Yes	Yes	None to date

Heart sound entries refer to standardized digital phonocardiography suitable for AI analysis, not to conventional auscultation.

7.2. Limitations

Heart sound recordings are susceptible to a range of acoustic confounders, including ambient noise, respiratory interference, stethoscope motion artifacts, and variability in recording hardware, all of which can degrade signal quality, complicate segmentation, and reduce the consistency of automated interpretation across clinical environments [93–95].

Body habitus adds a further source of variability, because increased body mass index and chest wall thickness weaken cardiac sound transmission and reduce auscultatory sensitivity. Other determinants include atrial fibrillation, pacing, heart rate, blood pressure, pulmonary congestion, concomitant aortic stenosis or mitral and tricuspid regurgitation, chronic lung disease, patient position, auscultation site, contact pressure, and operator technique. Because the information of interest lies at low frequencies, device-specific filtering and microphone frequency response are a particular concern, since they may attenuate precisely the 20 to 70 Hz band that the model is meant to learn. Computational hemoacoustic modeling and clinical studies have shown that obesity and thoracic anatomical variation alter sound propagation in ways that may affect the reliability and generalizability of acoustic models [96,97], which is especially relevant given the older and often comorbid population in which amyloidosis occurs.

7.3. Algorithmic Bias and Equity

Algorithmic bias and equity are central concerns in the development of acoustic artificial intelligence tools. Bias may originate both in the training data and in the structure of the algorithms themselves, and although machine learning depends on datasets that reflect the diversity of real-world populations, vulnerable demographic groups are frequently underrepresented in healthcare data [98]. Recurring problems of class imbalance, limited demographic reporting, and reliance on internal validation constrain external validity and generalizability [99], and similar issues have been reported in phonocardiographic research, where imbalanced datasets may compromise robustness across patient populations, though data-augmentation strategies offer partial mitigation [100]. These concerns are particularly acute in amyloidosis, a rare and frequently underdiagnosed disease for which machine learning datasets remain small, heterogeneous, and limited in diversity, a scarcity that has prompted interest in synthetic data generation to augment training sets [101]. They are compounded in resource-limited clinics that face background noise, fewer trained staff, and restricted testing options, all of which may affect how well these tools perform. Heart sound abnormalities in amyloidosis have been identified using digital phonocardiography and may carry diagnostic and prognostic significance [32], yet studies applying acoustic artificial intelligence specifically to the disease remain absent, and closing that gap will require datasets and validation across diverse populations and settings before widespread use.

7.4. Interpretability and Regulatory Considerations

Interpretability remains a major obstacle to clinical implementation. Deep learning models often function as black boxes whose decision-making is not transparent, and although they may achieve high diagnostic performance, limited explainability can reduce clinician trust, hinder adoption, and raise concerns about reliability and bias [102]. Existing explainability approaches in heart sound analysis frequently rely on post hoc techniques whose outputs may lack clear clinical meaning [103], and a further risk is that a model learns background noise, recording artifacts, or equipment-related frequency variation rather than genuine pathological features, which would limit robustness in real-world use. These considerations sit within a broader effort to define how artificial intelligence tools for cardiac amyloidosis should be validated and deployed [104], and together with emerging multidisciplinary consensus on the diagnosis and management of the disease [105], they make a strong case for explainable models and standardized validation before wider deployment.

8. Future Directions

The clearest near-term opportunity lies in multimodal integration. The electrocardiogram, the echocardiogram, and the heart sound each capture a different facet of the same infiltrated ventricle, and models that draw on more than one signal have already outperformed those relying on any single source. Goto and colleagues showed that pairing electrocardiographic pre-screening with echocardiography sharply raised the positive predictive value of the imaging step [55], and subsequent work combined electrocardiographic and echocardiographic artificial intelligence to track disease before clinical diagnosis [61]. A heart sound classifier would slot naturally into such a pipeline, adding a mechanical readout of ventricular compliance that neither the electrocardiogram nor the echocardiogram provides directly, and at negligible cost. The most valuable models are likely to be those that treat the heart sound as an inexpensive first filter and a complementary source of physiological information rather than a rival to imaging.

Figure 3 shows a conceptual framework for artificial intelligence (AI)-enabled heart sound analysis across the disease course. A digital stethoscope or wearable device acquires the phonocardiogram (PCG), either alone or synchronized with the electrocardiogram (ECG). Following signal denoising, cardiac phase segmentation, and extraction of representative acoustic features, including Mel-frequency cepstral coefficients (MFCCs), log-Mel spectrograms, and low-frequency diastolic energy, machine learning and deep learning models integrate heart sound information with complementary data sources such as ECG, circulating biomarkers, and cardiac imaging. The resulting multimodal framework supports potential applications in screening and triage, diagnostic support, prognostic assessment, and longitudinal monitoring. None of these applications has yet been tested in cardiac amyloidosis, and each represents a priority direction for future investigation.

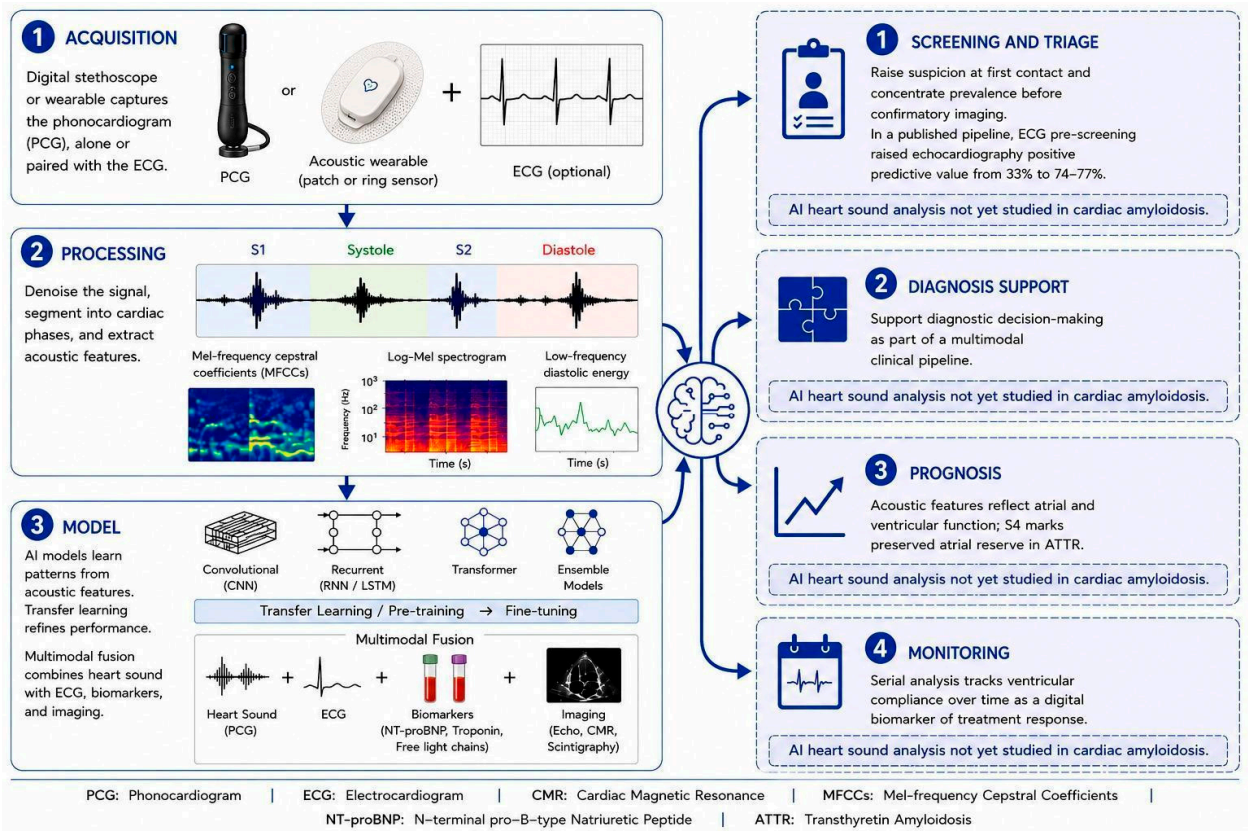

Figure 3. Conceptual framework for artificial intelligence (AI)-enabled heart sound analysis across the disease course.

A second direction is screening in at-risk populations using wearable acoustic sensors. Cardiac amyloidosis concentrates in identifiable groups, appearing in 7 to 12% of patients across cohorts with heart failure with preserved ejection fraction, severe aortic stenosis, and carpal tunnel syndrome [11], and these enriched populations are the natural place to screen. Wearable and miniaturized acoustic devices, such as the finger-ring stethoscope that captures phonocardiographic and photoplethysmographic signals together [69], raise the possibility of repeated or ambient heart sound captured outside the clinic, and applied to these enriched populations such sensors could flag the patients most likely to benefit from confirmatory testing. Realizing this will require heart sound datasets drawn from at-risk groups rather than the valvular cohorts on which current models were trained [38].

The most novel prospect may be serial heart sound analysis to monitor disease and treatment response. Transthyretin stabilizers and gene silencers hold amyloid deposition in check without undoing the damage already present [5,9], so the ability to detect subtle changes in ventricular compliance over time would be clinically valuable, and the heart sound is well suited to frequent, low-cost, non-invasive sampling. Acoustic features already carry prognostic information, with the fourth heart sound reflecting preserved atrial function in ATTRwt-CM [32]. Whether serial acoustic changes track amyloid burden or treatment response, independently of rhythm, loading conditions, and valve disease, is an open research question that would require prospective longitudinal validation. This remains hypothetical until prospective studies test it.

A first disease-specific study would need careful design, because the acoustic findings under investigation are not specific to amyloidosis. Table 3 summarizes the minimum requirements we propose. The study population should include patients with confirmed AL cardiac amyloidosis, ATTRwt-CM, and ATTRv-CM, analyzed separately, since these groups differ in age, disease tempo, wall thickness, atrial fibrillation, and conduction disease, and may differ in the mechanical substrate that produces S3 and S4. Pooling them without prespecified subgroup analyses risks a classifier that learns demographic or stage differences. The choice of controls matters even more. A model trained against healthy volunteers could learn age, heart failure, ventricular hypertrophy, valve disease, or congestion rather than amyloid, so the comparators should be patients with HFpEF, hypertensive left ventricular hypertrophy, hypertrophic cardiomyopathy, severe aortic stenosis, and chronic kidney disease, with amyloid status adjudicated against the reference standard. Recordings should come from standardized digital acquisition with a reported sampling rate, bandwidth, and microphone response adequate for the 20 to 70 Hz band, and with prespecified signal quality criteria. Development, tuning, and testing sets should be strictly patient-independent, and performance should be confirmed in an independent external cohort, reporting discrimination with confidence intervals, calibration, prevalence, and predictive values at a clinically meaningful triage threshold. These requirements are offered as recommendations for the field, not as a protocol.

Table 3. Minimum design requirements for a first disease-specific heart sound study in cardiac amyloidosis.

Element	Requirement
Target population	Adults with suspected or confirmed cardiac amyloidosis and clinically relevant comparators
Reference standard	ATTR by grade 2/3 scintigraphy with compatible phenotype and excluded monoclonal protein; AL by tissue biopsy with amyloid typing
Subtype reporting	AL, ATTRwt, and ATTRv analyzed separately with prespecified subgroup analyses
Control groups	Clinically relevant phenocopies: HFpEF, hypertensive LVH, HCM, severe aortic stenosis, CKD, common valvular disease, with adjudicated amyloid status

Table 3. *Cont.*

Element	Requirement
Acquisition	Standardized digital phonocardiography; defined auscultation sites and recording duration; reported device and vendor
Signal specification	Sampling rate and raw bandwidth sufficient to capture 20 to 70 Hz; reported microphone frequency response and filtering
Signal-quality criteria	Prespecified quality thresholds and handling of noise and artifact
Data partitioning	Strictly patient-independent development, tuning, and test sets
Validation	Independent external validation, separate from internal or temporal testing
Reporting	Discrimination with confidence intervals, calibration, disease prevalence, PPV and NPV, and a clinically meaningful triage threshold

9. Conclusions

Cardiac amyloidosis has moved within little more than a decade from an untreatable curiosity to a treatable and increasingly recognized disease, and the value of finding it early has risen with it. Artificial intelligence has begun to meet that need on the electrocardiogram and the echocardiogram, yet the heart sound, the cheapest and most widely available cardiac signal of all, remains almost untouched. The physiological case for acoustic analysis is strong, the enabling methods are mature, and the adjacent evidence in valvular and structural disease is encouraging, but not a single study has yet applied these tools to cardiac amyloidosis directly. Closing that gap will require dedicated acoustic datasets assembled from patients with confirmed disease and, in time, prospective trials that test whether heart sound analysis can shorten the path to diagnosis. The convergence of an important clinical need and increasingly sophisticated AI methods provides a compelling rationale for future research evaluating heart sound analysis as a tool for the early detection of cardiac amyloidosis.

Author Contributions: T.J. and S.P.A. defined the review scope, context, and purpose of this study. T.J., J.G., V.C., P.J., A.A., A.R., S.K.B., A.K., F.F., K.S., D.S.B.S., J.L., M.N.S., G.Y., T.N., J.J., P.E., S.M.J.W. and S.S.K. conducted the literature review and drafted the manuscript. T.J. and S.P.A. conceived and crafted illustrative figures. D.S., L.S.P., R.B., S.S. and S.A.H. provided clinical perspectives and expertise for this study. All authors read and performed a critical review of the manuscript. T.J., K.S., S.S.K. and S.P.A. performed the cleaning and organization of the manuscript. S.P.A. provided conceptualization, supervision, and project administration. All authors have read and agreed to the published version of the manuscript.

Funding: This research received no external funding.

Institutional Review Board Statement: Not applicable.

Informed Consent Statement: Not applicable.

Data Availability Statement: No new data were created or analyzed in this study. Data sharing is not applicable to this article.

Acknowledgments: This work was supported by the resources within the Digital Engineering & Artificial Intelligence Laboratory (DEAL), Department of Medicine, Mayo Clinic, Jacksonville, FL, USA. During the preparation of this manuscript, the authors used artificial-intelligence-based language tools to assist with drafting and language editing.

Conflicts of Interest: The authors declare no conflicts of interest.

References

1. Falk, R.H.; Alexander, K.M.; Liao, R.; Dorbala, S. AL (light-chain) cardiac amyloidosis: A review of diagnosis and therapy. *J. Am. Coll. Cardiol.* **2016**, *68*, 1323–1341. [PubMed]
2. Kittleson, M.M.; Maurer, M.S.; Ambardekar, A.V.; Bullock-Palmer, R.P.; Chang, P.P.; Eisen, H.J.; Nair, A.P.; Nativi-Nicolau, J.; Ruberg, F.L.; On behalf of the American Heart Association Heart Failure; et al. Cardiac amyloidosis: Evolving diagnosis and management: A scientific statement from the American Heart Association. *Circulation* **2020**, *142*, e7–e22, Correction in *Circulation* **2021**, *144*, 1. [CrossRef] [PubMed]
3. Gertz, M.A.; Dispenzieri, A. Systemic amyloidosis recognition, prognosis, and therapy: A systematic review. *JAMA* **2020**, *324*, 79–89. [CrossRef] [PubMed]
4. Merlini, G.; Bellotti, V. Molecular mechanisms of amyloidosis. *N. Engl. J. Med.* **2003**, *349*, 583–596. [CrossRef] [PubMed]
5. Maurer, M.S.; Schwartz, J.H.; Gundapaneni, B.; Elliott, P.M.; Merlini, G.; Waddington-Cruz, M.; Kristen, A.V.; Grogan, M.; Witteles, R.; Damy, T.; et al. Tafamidis treatment for patients with transthyretin amyloid cardiomyopathy. *N. Engl. J. Med.* **2018**, *379*, 1007–1016. [CrossRef] [PubMed]
6. Gillmore, J.D.; Judge, D.P.; Cappelli, F.; Fontana, M.; Garcia-Pavia, P.; Gibbs, S.; Grogan, M.; Hanna, M.; Hoffman, J.; Masri, A.; et al. Efficacy and safety of acoramidis in transthyretin amyloid cardiomyopathy. *N. Engl. J. Med.* **2024**, *390*, 132–142. [CrossRef] [PubMed]
7. Adams, D.; Gonzalez-Duarte, A.; O'Riordan, W.D.; Yang, C.C.; Ueda, M.; Kristen, A.V.; Tournev, I.; Schmidt, H.H.; Coelho, T.; Berk, J.L.; et al. Patisiran, an RNAi therapeutic, for hereditary transthyretin amyloidosis. *N. Engl. J. Med.* **2018**, *379*, 11–21. [CrossRef] [PubMed]
8. Benson, M.D.; Waddington-Cruz, M.; Berk, J.L.; Polydefkis, M.; Dyck, P.J.; Wang, A.K.; Planté-Bordeneuve, V.; Barroso, F.A.; Merlini, G.; Obici, L.; et al. Inotersen treatment for patients with hereditary transthyretin amyloidosis. *N. Engl. J. Med.* **2018**, *379*, 22–31. [CrossRef] [PubMed]
9. Fontana, M.; Berk, J.L.; Gillmore, J.D.; Witteles, R.M.; Grogan, M.; Drachman, B.; Damy, T.; Garcia-Pavia, P.; Taubel, J.; Solomon, S.D.; et al. HELIOS-B Trial Investigators. Vutrisiran in patients with transthyretin amyloidosis with cardiomyopathy. *N. Engl. J. Med.* **2025**, *392*, 33–44. [PubMed]
10. Kastritis, E.; Palladini, G.; Minnema, M.C.; Wechalekar, A.D.; Jaccard, A.; Lee, H.C.; Sanchorawala, V.; Gibbs, S.; Mollee, P.; Venner, C.P.; et al. Daratumumab-based treatment for immunoglobulin light-chain amyloidosis. *N. Engl. J. Med.* **2021**, *385*, 46–58. [CrossRef] [PubMed]
11. Aimo, A.; Merlo, M.; Porcari, A.; Georgiopoulos, G.; Pagura, L.; Vergaro, G.; Sinagra, G.; Emdin, M.; Rapezzi, C. Redefining the epidemiology of cardiac amyloidosis. A systematic review and meta-analysis of screening studies. *Eur. J. Heart Fail.* **2022**, *24*, 2342–2351. [CrossRef] [PubMed]
12. Mohammed, S.F.; Mirzoyev, S.A.; Edwards, W.D.; Dogan, A.; Grogan, D.R.; Dunlay, S.M.; Roger, V.L.; Gertz, M.A.; Dispenzieri, A.; Zeldenrust, S.R.; et al. Left ventricular amyloid deposition in patients with heart failure and preserved ejection fraction. *JACC Heart Fail.* **2014**, *2*, 113–122. [CrossRef] [PubMed]
13. Cianci, V.; Cianci, A.; Sapienza, D.; Cracò, A.; Germanà, A.; Ieni, A.; Gualniera, P.; Asmundo, A.; Mondello, C. Epidemiological changes in transthyretin cardiac amyloidosis: Evidence from in vivo data and autoptic series. *J. Clin. Med.* **2024**, *13*, 5140. [CrossRef] [PubMed]
14. Garcia-Pavia, P.; Rapezzi, C.; Adler, Y.; Arad, M.; Basso, C.; Brucato, A.; Burazor, I.; Caforio, A.L.P.; Damy, T.; Eriksson, U.; et al. Diagnosis and treatment of cardiac amyloidosis: A position statement of the ESC Working Group on Myocardial and Pericardial Diseases. *Eur. Heart J.* **2021**, *42*, 1554–1568. [CrossRef] [PubMed]
15. Gillmore, J.D.; Maurer, M.S.; Falk, R.H.; Merlini, G.; Damy, T.; Dispenzieri, A.; Wechalekar, A.D.; Berk, J.L.; Quarta, C.C.; Grogan, M.; et al. Nonbiopsy diagnosis of cardiac transthyretin amyloidosis. *Circulation* **2016**, *133*, 2404–2412. [CrossRef] [PubMed]
16. Perugini, E.; Guidalotti, P.L.; Salvi, F.; Cooke, R.M.; Pettinato, C.; Riva, L.; Leone, O.; Farsad, M.; Ciliberti, P.; Bacchi-Reggiani, L.; et al. Noninvasive etiologic diagnosis of cardiac amyloidosis using 99mTc-3,3-diphosphono-1,2-propanodicarboxylic acid scintigraphy. *J. Am. Coll. Cardiol.* **2005**, *46*, 1076–1084. [CrossRef] [PubMed]
17. Dorbala, S.; Ando, Y.; Bokhari, S.; Dispenzieri, A.; Falk, R.H.; Ferrari, V.A.; Fontana, M.; Gheysens, O.; Gillmore, J.D.; Glaudemans, A.W.J.M.; et al. ASNC/AHA/ASE/EANM/HFSA/ISA/SCMR/SNMMI expert consensus recommendations for multimodality imaging in cardiac amyloidosis: Part 1 of 2—Evidence base and standardized methods of imaging. *J. Nucl. Cardiol.* **2019**, *26*, 2065–2123, Correction in *J. Nucl. Cardiol.* **2021**, *28*, 1761–1762. [CrossRef] [PubMed]
18. Grogan, M.; Lopez-Jimenez, F.; Cohen-Shelly, M.; Dispenzieri, A.; Attia, Z.I.; Abou Ezzedine, O.F.; Lin, G.; Kapa, S.; Borgeson, D.D.; Friedman, P.A.; et al. Artificial intelligence-enhanced electrocardiogram for the early detection of cardiac amyloidosis. *Mayo Clin. Proc.* **2021**, *96*, 2768–2778, Erratum in *Mayo Clin. Proc.* **2023**, *98*, 211. [CrossRef] [PubMed]
19. U.S. Food and Drug Administration. *510(k) Premarket Notification: ECG-AI Cardiac Amyloidosis 12-Lead Algorithm (K253801)*; FDA: Silver Spring, MD, USA, 2026.

20. U.S. Food and Drug Administration. *510(k) Premarket Notification: EchoGo Amyloidosis (K240860)*; FDA: Silver Spring, MD, USA, 2024.
21. Pepys, M.B. Amyloidosis. *Annu. Rev. Med.* **2006**, *57*, 223–241. [CrossRef] [PubMed]
22. Falk, R.H. Diagnosis and management of the cardiac amyloidoses. *Circulation* **2005**, *112*, 2047–2060. [CrossRef] [PubMed]
23. Ruberg, F.L.; Berk, J.L. Transthyretin (TTR) cardiac amyloidosis. *Circulation* **2012**, *126*, 1286–1300. [CrossRef] [PubMed]
24. Ruberg, F.L.; Grogan, M.; Hanna, M.; Kelly, J.W.; Maurer, M.S. Transthyretin amyloid cardiomyopathy: JACC state-of-the-art review. *J. Am. Coll. Cardiol.* **2019**, *73*, 2872–2891. [PubMed]
25. Banypersad, S.M.; Moon, J.C.; Whelan, C.; Hawkins, P.N.; Wechalekar, A.D. Updates in cardiac amyloidosis: A review. *J. Am. Heart Assoc.* **2012**, *1*, e000364. [CrossRef] [PubMed]
26. Sekijima, Y.; Kelly, J.W.; Ikeda, S. Pathogenesis of and therapeutic strategies to ameliorate the transthyretin amyloidoses. *Curr. Pharm. Des.* **2008**, *14*, 3219–3230. [CrossRef] [PubMed]
27. Phelan, D.; Collier, P.; Thavendiranathan, P.; Popovic, Z.B.; Hanna, M.; Plana, J.C.; Marwick, T.H.; Thomas, J.D. Relative apical sparing of longitudinal strain using two-dimensional speckle-tracking echocardiography is both sensitive and specific for the diagnosis of cardiac amyloidosis. *Heart* **2012**, *98*, 1442–1448. [CrossRef] [PubMed]
28. Sato, Y.; Kawasaki, T.; Honda, S.; Harimoto, K.; Miki, S.; Kamitani, T.; Shiraishi, H.; Matoba, S. Third and fourth heart sounds and myocardial fibrosis in hypertrophic cardiomyopathy. *Circ. J.* **2018**, *82*, 509–516. [CrossRef] [PubMed]
29. Reddy, P.S.; Meno, F.; Curtiss, E.I.; O'Toole, J.D. The genesis of gallop sounds: Investigation by quantitative phono- and apexcardiography. *Circulation* **1981**, *63*, 922–933. [CrossRef] [PubMed]
30. Van de Werf, F.; Geboers, J.; Kesteloot, H.; De Geest, H.; Barrios, L. The mechanism of disappearance of the physiologic third heart sound with age. *Circulation* **1986**, *73*, 877–884. [CrossRef] [PubMed]
31. Muchtar, E.; Blauwet, L.A.; Gertz, M.A. Restrictive cardiomyopathy: Genetics, pathogenesis, clinical manifestations, diagnosis, and therapy. *Circ. Res.* **2017**, *121*, 819–837. [PubMed]
32. Ochi, Y.; Yamasaki, N.; Kubo, T.; Baba, Y.; Miyagawa, K.; Noguchi, T.; Hirota, T.; Hamada, T.; Kitaoka, H. Importance of fourth heart sound and preserved left atrial function in wild-type transthyretin amyloidosis. *ESC Heart Fail.* **2024**, *11*, 4000–4008. [CrossRef] [PubMed]
33. Dungu, J.N.; Valencia, O.; Pinney, J.H.; Gibbs, S.D.; Rowczenio, D.; Gilbertson, J.A.; Lachmann, H.J.; Wechalekar, A.; Gillmore, J.D.; Whelan, C.J.; et al. CMR-based differentiation of AL and ATTR cardiac amyloidosis. *JACC Cardiovasc. Imaging* **2014**, *7*, 133–142. [CrossRef] [PubMed]
34. Abbas, A.K.; Bassam, R. Phonocardiography signal processing. *Synth. Lect. Biomed. Eng.* **2009**, *4*, 1–194. [CrossRef]
35. Arjoune, Y.; Nguyen, T.N.; Doroshow, R.W.; Shekhar, R. A noise-robust heart sound segmentation algorithm based on Shannon energy. *IEEE Access* **2024**, *12*, 7747–7761. [CrossRef] [PubMed]
36. U.S. Food and Drug Administration. *510(k) Premarket Notification: CORE 500 Digital Stethoscope (K233609)*; FDA: Silver Spring, MD, USA, 2024.
37. Clifford, G.; Liu, C.; Springer, D.; Moody, B.; Li, Q.; Abad, R.; Millet, J.; Silva, I.; Johnson, A.; Mark, R. Classification of normal/abnormal heart sound recordings: The PhysioNet/Computing in Cardiology Challenge 2016. *Comput. Cardiol.* **2016**, *43*, 609–612. [CrossRef]
38. Reyna, M.A.; Kiarashi, Y.; Elola, A.; Oliveira, J.; Renna, F.; Gu, A.; Alday, E.A.P.; Sadr, N.; Sharma, A.; Kpodonu, J.; et al. Heart murmur detection from phonocardiogram recordings: The George B. Moody PhysioNet Challenge 2022. *PLoS Digit. Health* **2023**, *2*, e0000324. [CrossRef] [PubMed]
39. McDonald, A.; Gales, M.J.F.; Agarwal, A. A recurrent neural network and parallel hidden Markov model algorithm to segment and detect heart murmurs in phonocardiograms. *PLoS Digit. Health* **2024**, *3*, e0000436. [CrossRef] [PubMed]
40. Shariat Panah, D.; Hines, A.; McKeever, S. Exploring the impact of noise and degradations on heart sound classification models. *arXiv* **2022**, arXiv:2211.07445.
41. Grooby, E.; Sitaula, C.; Fattahi, D.; Sameni, R.; Tan, K.; Zhou, L.; King, A.; Ramanathan, A.; Malhotra, A.; Dumont, G.; et al. Noisy neonatal chest sound separation for high-quality heart and lung sounds. *arXiv* **2022**, arXiv:2201.03211.
42. Springer, D.B.; Tarassenko, L.; Clifford, G.D. Logistic regression-HSMM-based heart sound segmentation. *IEEE Trans. Biomed. Eng.* **2016**, *63*, 822–832. [CrossRef] [PubMed]
43. Satya Karthikeya, P.P.; Rohith, P.; Karthikeya, B.; Karthik Reddy, M.; Akhil, V.M.; Tigrini, A.; Burattini, L. Heart sound classification for early detection of cardiovascular diseases using XGBoost and engineered acoustic features. *Sensors* **2026**, *26*, 630. [CrossRef] [PubMed]
44. Deng, M.; Meng, T.; Cao, J.; Wang, S.; Zhang, J.; Fan, H. Heart sound classification based on improved MFCC features and convolutional recurrent neural networks. *Neural Netw.* **2020**, *130*, 22–32. [CrossRef] [PubMed]
45. Chen, W.; Zhou, Z.; Bao, J.; Wang, C.; Chen, H.; Xu, C.; Xie, G.; Shen, H.; Wu, H. Classifying heart-sound signals based on CNN trained on MelSpectrum and Log-MelSpectrum features. *Bioengineering* **2023**, *10*, 645. [CrossRef] [PubMed]

46. Liu, Z.; Jiang, H.; Zhang, F.; Ouyang, W.; Li, X.; Pan, X. Heart sound classification based on bispectrum features and Vision Transformer model. *Alex. Eng. J.* **2023**, *85*, 49–59. [CrossRef]
47. Zhao, Q.; Geng, S.; Wang, B.; Sun, Y.; Nie, W.; Bai, B.; Yu, C.; Zhang, F.; Tang, G.; Zhang, D.; et al. Deep learning in heart sound analysis: From techniques to clinical applications. *Health Data Sci.* **2024**, *4*, 0182. [CrossRef] [PubMed]
48. Ren, Z.; Chang, Y.; Nguyen, T.T.; Tan, Y.; Qian, K.; Schuller, B.W. A comprehensive survey on heart sound analysis in the deep learning era. *arXiv* **2023**, arXiv:2301.09362.
49. Nguyen, M.T.; Lin, W.W.; Huang, J.H. Heart sound classification using deep learning techniques based on log-mel spectrogram. *Circuits Syst. Signal Process.* **2023**, *42*, 344–360. [CrossRef]
50. Gong, Y.; Chung, Y.A.; Glass, J. AST: Audio Spectrogram Transformer. In Proceedings of the Interspeech 2021, Brno, Czech Republic, 30 August–3 September 2021; pp. 571–575.
51. Siddiqui, M.S.B.; Saha, U. AudioFuse: Unified spectral-temporal learning via a hybrid ViT-1D CNN architecture for robust phonocardiogram classification. *arXiv* **2025**, arXiv:2509.23454.
52. Khan, S.I.; Qaisar, S.M.; Pachori, R.B. Automated classification of valvular heart diseases using FBSE-EWT and PSR based geometrical features. *Biomed. Signal Process. Control* **2022**, *73*, 103445. [CrossRef]
53. Sarker, S.; Preotee, F.F.; Muhammad, T.; Akhter, S. An innovative framework for heart sound classification integrating adaptive fuzzy rank-based ensemble of transfer learning models with multi-dimensional features. *bioRxiv* **2025**, bioRxiv:2025.09.07.674773. [CrossRef]
54. Despotovic, V.; Pocta, P.; Zgank, A. CardioPHON: Quality assessment and self-supervised pretraining for screening of cardiac function based on phonocardiogram recordings. *Biomed. Signal Process. Control* **2026**, *113*, 109047. [CrossRef]
55. Goto, S.; Mahara, K.; Beussink-Nelson, L.; Ikura, H.; Katsumata, Y.; Endo, J.; Gaggin, H.K.; Shah, S.J.; Itabashi, Y.; MacRae, C.A.; et al. Artificial intelligence-enabled fully automated detection of cardiac amyloidosis using electrocardiograms and echocardiograms. *Nat. Commun.* **2021**, *12*, 2726. [CrossRef] [PubMed]
56. Harmon, D.M.; Mangold, K.; Baez Suarez, A.; Scott, C.G.; Murphree, D.H.; Malik, A.; Attia, Z.I.; Lopez-Jimenez, F.; Friedman, P.A.; Dispenzieri, A.; et al. Postdevelopment performance and validation of the artificial intelligence-enhanced electrocardiogram for detection of cardiac amyloidosis. *JACC Adv.* **2023**, *2*, 100612. [CrossRef] [PubMed]
57. Croon, P.M.; Dhingra, L.S.; Batinica, B.; Choi, R.B.; Oikonomou, E.K.; Shankar, S.V.; Sangha, V.; van der Boon, R.M.; Michels, M.; van Ettinger, M.; et al. Electrocardiogram-based deep learning enables scalable screening of transthyretin amyloid cardiomyopathy. *medRxiv* **2026**. medRxiv:2024.09.30.24314651.
58. Duffy, G.; Oikonomou, E.K.; Hourmozdi, J.; Usuku, H.; Patel, J.; Katsumata, Y.; Yamasawa, D.; Stern, L.; Goto, S.; Tsujita, K.; et al. International validation of echocardiographic artificial intelligence amyloid detection algorithm. *JACC Adv.* **2025**, *4*, 102067. [CrossRef] [PubMed]
59. Slivnick, J.A.; Hawkes, W.; Oliveira, J.; Woodward, G.; Akerman, A.; Gomez, A.; Hamza, I.; Desai, V.K.; Barrett-O'kEefe, Z.; Grogan, M.; et al. Cardiac amyloidosis detection from a single echocardiographic video clip: A novel artificial intelligence-based screening tool. *Eur. Heart J.* **2025**, *46*, 4090–4101. [CrossRef] [PubMed]
60. Chang, R.S.; Chiu, I.M.; Tacon, P.; Abiragi, M.; Cao, L.; Hong, G.; Le, J.; Zou, J.; Daluwatte, C.; Ricchiuto, P.; et al. Detection of cardiac amyloidosis using machine learning on routine echocardiographic measurements. *Open Heart* **2024**, *11*, e002884. [CrossRef] [PubMed]
61. Oikonomou, E.K.; Sangha, V.; Shankar, S.V.; Coppi, A.; Krumholz, H.M.; Nasir, K.; Miller, E.J.; Kattan, C.G.; Al-Mallah, M.H.; Al-Kindi, S.; et al. Artificial intelligence-enabled electrocardiography and echocardiography to track preclinical progression of transthyretin amyloid cardiomyopathy. *Eur. Heart J.* **2025**, *46*, 3651–3662. [CrossRef] [PubMed]
62. Chorba, J.S.; Shapiro, A.M.; Le, L.; Maidens, J.; Prince, J.; Pham, S.; Kanzawa, M.M.; Barbosa, D.N.; Currie, C.; Brooks, C.; et al. Deep learning algorithm for automated cardiac murmur detection via a digital stethoscope platform. *J. Am. Heart Assoc.* **2021**, *10*, e019905. [CrossRef] [PubMed]
63. Ghanayim, T.; Lupu, L.; Naveh, S.; Bachner-Hinenzon, N.; Adler, D.; Adawi, S.; Banai, S.; Shiran, A. Artificial intelligence-based stethoscope for the diagnosis of aortic stenosis. *Am. J. Med.* **2022**, *135*, 1124–1133. [CrossRef] [PubMed]
64. Castano, A.; Narotsky, D.L.; Hamid, N.; Khalique, O.K.; Morgenstern, R.; DeLuca, A.; Rubin, J.; Chiuzan, C.; Nazif, T.; Vahl, T.; et al. Unveiling transthyretin cardiac amyloidosis and its predictors among elderly patients with severe aortic stenosis undergoing transcatheter aortic valve replacement. *Eur. Heart J.* **2017**, *38*, 2879–2887. [CrossRef] [PubMed]
65. Ogawa, S.; Ishii, M.; Saito, S.; Seki, H.; Ikeda, K.; Yasui, Y.; Komatsu, T.; Sato, G.; Tabata, N.; Ohishi, M.; et al. Deep learning for cardiac overload estimation: Predicting B-type natriuretic peptide levels from heart sounds and electrocardiogram. *Circ. J.* **2025**, *89*, 1684–1692. [CrossRef] [PubMed]
66. Ogawa, S.; Namino, F.; Mori, T.; Sato, G.; Yamakawa, T.; Saito, S. AI diagnosis of heart sounds differentiated with super StethoScope. *J. Cardiol.* **2024**, *83*, 265–271. [CrossRef] [PubMed]
67. Partovi, E.; Babic, A.; Gharehbaghi, A. A review on deep learning methods for heart sound signal analysis. *Front. Artif. Intell.* **2024**, *7*, 1434022. [CrossRef] [PubMed]

68. Roy, T.S.; Roy, J.K.; Mandal, N. Design of ear-contactless stethoscope and improvement in the performance of deep learning based on CNN to classify the heart sound. *Med. Biol. Eng. Comput.* **2023**, *61*, 2417–2439. [CrossRef] [PubMed]
69. Lee, S.; Wei, Q.; Park, H.; Na, Y.; Jeong, D.; Lim, H. Development of a finger-ring-shaped hybrid smart stethoscope for automatic S1 and S2 heart sound identification. *Sensors* **2021**, *21*, 6294. [CrossRef] [PubMed]
70. Xu, W.; Yu, K.; Xu, J.; Ye, J.; Li, H.; Shu, Q. Artificial intelligence technology in cardiac auscultation screening for congenital heart disease: Present and future. *Zhejiang Da Xue Xue Bao Yi Xue Ban.* **2020**, *49*, 548–555. [PubMed]
71. Ainiwaer, A.; Kadier, K.; Qin, L.; Rehemuding, R.; Ma, X.; Ma, Y.T. Audiological diagnosis of valvular and congenital heart diseases in the era of artificial intelligence. *Rev. Cardiovasc. Med.* **2023**, *24*, 175. [CrossRef] [PubMed]
72. Nahar, J.K.; Lopez-Jimenez, F. Utilizing conversational artificial intelligence, voice, and phonocardiography analytics in heart failure care. *Heart Fail. Clin.* **2022**, *18*, 311–323. [CrossRef] [PubMed]
73. Sakamoto, A.; Nakamura, Y.; Sato, E.; Kagiyama, N. Artificial intelligence in clinics: Enhancing cardiology practice. *JMA J.* **2025**, *8*, 131–140. [CrossRef] [PubMed]
74. De Michieli, L.; Sinigiani, G.; De Gaspari, M.; Branca, A.; Rizzo, S.; Basso, C.; Trentin, L.; Iliceto, S.; Marra, M.P.; Cipriani, A.; et al. Light-chain cardiac amyloidosis for the non-expert: Pearls and pitfalls. *Intern. Emerg. Med.* **2023**, *18*, 1879–1886. [CrossRef] [PubMed]
75. Rozenbaum, M.H.; Large, S.; Bhambri, R.; Stewart, M.; Whelan, J.; van Doornewaard, A.; Dasgupta, N.; Masri, A.; Nativi-Nicolau, J. Impact of delayed diagnosis and misdiagnosis for patients with transthyretin amyloid cardiomyopathy (ATTR-CM): A targeted literature review. *Cardiol. Ther.* **2021**, *10*, 141–159. [CrossRef] [PubMed]
76. Gertz, M.; Adams, D.; Ando, Y.; Beirão, J.M.; Bokhari, S.; Coelho, T.; Comenzo, R.L.; Damy, T.; Dorbala, S.; Drachman, B.M.; et al. Avoiding misdiagnosis: Expert consensus recommendations for the suspicion and diagnosis of transthyretin amyloidosis for the general practitioner. *BMC Fam. Pract.* **2020**, *21*, 198. [CrossRef] [PubMed]
77. Gill, S.S.; Fellin, E.; Stampke, L.; Zhao, Y.; Masri, A. Clinical clues and diagnostic workup of cardiac amyloidosis. *Methodist Debakey Cardiovasc. J.* **2022**, *18*, 36–46. [CrossRef] [PubMed]
78. Sperry, B.W.; Reyes, B.A.; Ikram, A.; Donnelly, J.P.; Phelan, D.; Jaber, W.A.; Shapiro, D.; Evans, P.J.; Maschke, S.; Kilpatrick, S.E.; et al. Tenosynovial and cardiac amyloidosis in patients undergoing carpal tunnel release. *J. Am. Coll. Cardiol.* **2018**, *72*, 2040–2050. [CrossRef] [PubMed]
79. Caponetti, A.G.; Accietto, A.; Saturi, G.; Ponziani, A.; Sguazzotti, M.; Massa, P.; Giovannetti, A.; Ditaranto, R.; Parisi, V.; Leone, O.; et al. Screening approaches to cardiac amyloidosis in different clinical settings: Current practice and future perspectives. *Front. Cardiovasc. Med.* **2023**, *10*, 1146725. [CrossRef] [PubMed]
80. Nativi-Nicolau, J.; Karam, C.; Khella, S.; Maurer, M.S. Screening for ATTR amyloidosis in the clinic: Overlapping disorders, misdiagnosis, and multiorgan awareness. *Heart Fail. Rev.* **2022**, *27*, 785–793. [CrossRef] [PubMed]
81. Fontana, M.; Ioannou, A.; Cuddy, S.; Dorbala, S.; Masri, A.; Moon, J.C.; Singh, V.; Clerc, O.; Hanna, M.; Ruberg, F.; et al. The last decade in cardiac amyloidosis: Advances in understanding pathophysiology, diagnosis and quantification, prognosis, treatment strategies, and monitoring response. *JACC Cardiovasc. Imaging* **2025**, *18*, 478–499. [PubMed]
82. Palladini, G.; Dispenzieri, A.; Gertz, M.A.; Kumar, S.; Wechalekar, A.; Hawkins, P.N.; Schönland, S.; Hegenbart, U.; Comenzo, R.; Kastritis, E.; et al. New criteria for response to treatment in immunoglobulin light chain amyloidosis based on free light chain measurement and cardiac biomarkers: Impact on survival outcomes. *J. Clin. Oncol.* **2012**, *30*, 4541–4549. [CrossRef] [PubMed]
83. Perfetto, F.; Zampieri, M.; Fumagalli, C.; Allinovi, M.; Cappelli, F. Circulating biomarkers in diagnosis and management of cardiac amyloidosis: A review for internist. *Intern. Emerg. Med.* **2022**, *17*, 957–969. [CrossRef] [PubMed]
84. Allegra, A.; Mirabile, G.; Tonacci, A.; Genovese, S.; Pioggia, G.; Gangemi, S. Machine learning approaches in diagnosis, prognosis and treatment selection of cardiac amyloidosis. *Int. J. Mol. Sci.* **2023**, *24*, 5680. [CrossRef] [PubMed]
85. Amadio, J.M.; Grogan, M.; Muchtar, E.; Lopez-Jimenez, F.; Attia, Z.I.; AbouEzzeddine, O.; Lin, G.; Dasari, S.; Kapa, S.; Borgeson, D.D.; et al. Predictors of mortality by an artificial intelligence enhanced electrocardiogram model for cardiac amyloidosis. *ESC Heart Fail.* **2025**, *12*, 677–682. [CrossRef] [PubMed]
86. Argirò, A.; Zampieri, M.; Mazzoni, C.; Fumagalli, C.; Baccini, M.; Mattei, A.; Cipriani, A.; De Michieli, L.; Porcari, A.; Sinagra, G.; et al. Progression and prognostic significance of electrocardiographic findings in patients with cardiac amyloidosis. *ESC Heart Fail.* **2025**, *12*, 809–818. [CrossRef] [PubMed]
87. Adrejiya, P.; Alkhatib, D.A.; Aljaroudi, W. Multimodal artificial intelligence for early detection and precision management of inflammatory and infiltrative cardiomyopathies. *Curr. Probl. Cardiol.* **2026**, *51*, 103371. [CrossRef] [PubMed]
88. Tersalvi, G.; James, J.K.; Attia, Z.I.; Chang, I.C.; Grazzini Frantz, J.; Adigun, R.O.; Dispenzieri, A.; Alkhouli, M.; Lopez-Jimenez, F.; Pellikka, P.A.; et al. Artificial intelligence application and future directions in infiltrative and inflammatory cardiomyopathies: A state-of-the-art review. *J. Card. Fail.* **2026**, *32*, 888–901. [CrossRef] [PubMed]
89. Kong, D.; Capustin, M.; Ho, M.; Choi, J.; Stern, D.L.; Hadley, M.; Finkielstein, D. Artificial intelligence as a prognostic tool in cardiac amyloidosis: A review. *Am. J. Cardiol.* **2026**, *262*, 75–82. [CrossRef] [PubMed]

90. Wardak, R.; Snipelisky, D. The role of artificial intelligence in cardiac amyloidosis: A focus on diagnosis and clinical application. *J. Cardiovasc. Dev. Dis.* **2025**, *12*, 221. [CrossRef] [PubMed]
91. Rancier, M.; Israel, I.; Monickam, V.; Currie, C.; Verschoore, B.; Lastowski, E.; Van Pelt, D.W.; Prince, J.; McDonough, R.V. Artificial-intelligence-enabled digital stethoscope improves point-of-care screening for moderate-to-severe valvular heart disease. *Eur. Heart J. Digit. Health* **2026**, *7*, ztag003. [CrossRef] [PubMed]
92. Bachtiger, P.; Petri, C.F.; Scott, F.E.; Ri Park, S.; Kelshiker, M.A.; Sahemey, H.K.; Dumea, B.; Alquero, R.; Padam, P.S.; Hatrick, I.R.; et al. Point-of-care screening for heart failure with reduced ejection fraction using artificial intelligence during ECG-enabled stethoscope examination in London, UK: A prospective, observational, multicentre study. *Lancet Digit. Health* **2022**, *4*, e117–e125. [CrossRef] [PubMed]
93. Salleh, S.H.; Hussain, H.S.; Swee, T.T.; Ting, C.M.; Noor, A.M.; Pipatsart, S.; Ali, J.; Yupapin, P.P. Acoustic cardiac signals analysis: A Kalman filter-based approach. *Int. J. Nanomed.* **2012**, *7*, 2873–2881. [CrossRef] [PubMed]
94. Nowak, L.J.; Nowak, K.M. Sound differences between electronic and acoustic stethoscopes. *Biomed. Eng. Online* **2018**, *17*, 104. [CrossRef] [PubMed]
95. Tang, H.; Wang, M.; Hu, Y.; Guo, B.; Li, T. Automated signal quality assessment for heart sound signal by novel features and evaluation in open public datasets. *Biomed. Res. Int.* **2021**, *2021*, 7565398. [CrossRef] [PubMed]
96. Lee, D.H.; Seo, J.H.; Mittal, R. Quantifying the effect of body habitus on cardiac auscultation via computational hemoacoustics. *J. Biomech. Eng.* **2023**, *145*, 024503. [CrossRef] [PubMed]
97. Kalinauskiene, E.; Razvadauskas, H.; Morse, D.J.; Maxey, G.E.; Naudziunas, A. A comparison of electronic and traditional stethoscopes in the heart auscultation of obese patients. *Medicina* **2019**, *55*, 94. [CrossRef] [PubMed]
98. Sufian, M.A.; Alsadder, L.; Hamzi, W.; Zaman, S.; Sagar, A.S.M.S.; Hamzi, B. Mitigating algorithmic bias in AI-driven cardiovascular imaging for fairer diagnostics. *Diagnostics* **2024**, *14*, 2675. [CrossRef] [PubMed]
99. Houssein, E.H.; Mostafa, H.; Ali, A.A.; Emam, M.M.; Hassan, M.R. Advances in artificial intelligence techniques for diagnosis of cardiac diseases. *Discov. Artif. Intell.* **2026**, *6*, 424. [CrossRef]
100. Valaee, M.; Shirani, S. Heart murmur detection in phonocardiogram data leveraging data augmentation and artificial intelligence. *Diagnostics* **2025**, *15*, 2471. [CrossRef] [PubMed]
101. Speziale, F.; Lomoio, U.; Boccuto, F.; Veltri, P.; Guzzi, P.H. A usable GAN-based tool for synthetic ECG generation in cardiac amyloidosis research. *arXiv* **2026**, arXiv:2601.08260.
102. Marey, A.; Arjmand, P.; Alerab, A.D.S.; Eslami, M.J.; Saad, A.M.; Sanchez, N.; Umair, M. Explainability, transparency and black box challenges of AI in radiology: Impact on patient care in cardiovascular radiology. *Egypt. J. Radiol. Nucl. Med.* **2024**, *55*, 183. [CrossRef]
103. Sun, Q.; Li, Y.; Javadov, A.; Wu, X.; Schuller, B.W. Prior-aligned frequency-domain explanations for heart sound classification: A scale-consistent attribution approach. *Front. Artif. Intell.* **2026**, *9*, 1780496. [CrossRef] [PubMed]
104. Kamel, M.A.; Abbas, M.T.; Kanaan, C.N.; Awad, K.A.; Baba Ali, N.; Scalia, I.G.; Farina, J.M.; Pereyra, M.; Mahmoud, A.K.; Steidley, D.E.; et al. How artificial intelligence can enhance the diagnosis of cardiac amyloidosis: A review of recent advances and challenges. *J. Cardiovasc. Dev. Dis.* **2024**, *11*, 118. [CrossRef] [PubMed]
105. Kittleson, M.M.; Ruberg, F.L.; Ambardekar, A.V.; Brannagan, T.H.; Cheng, R.K.; Clarke, J.O.; Dember, L.M.; Frantz, J.G.; Hershberger, R.E.; Maurer, M.S.; et al. 2023 ACC expert consensus decision pathway on comprehensive multidisciplinary care for the patient with cardiac amyloidosis: A report of the American College of Cardiology Solution Set Oversight Committee. *J. Am. Coll. Cardiol.* **2023**, *81*, 1076–1126. [PubMed]

Disclaimer/Publisher's Note: The statements, opinions and data contained in all publications are solely those of the individual author(s) and contributor(s) and not of MDPI and/or the editor(s). MDPI and/or the editor(s) disclaim responsibility for any injury to people or property resulting from any ideas, methods, instructions or products referred to in the content.