

Supplementary Material

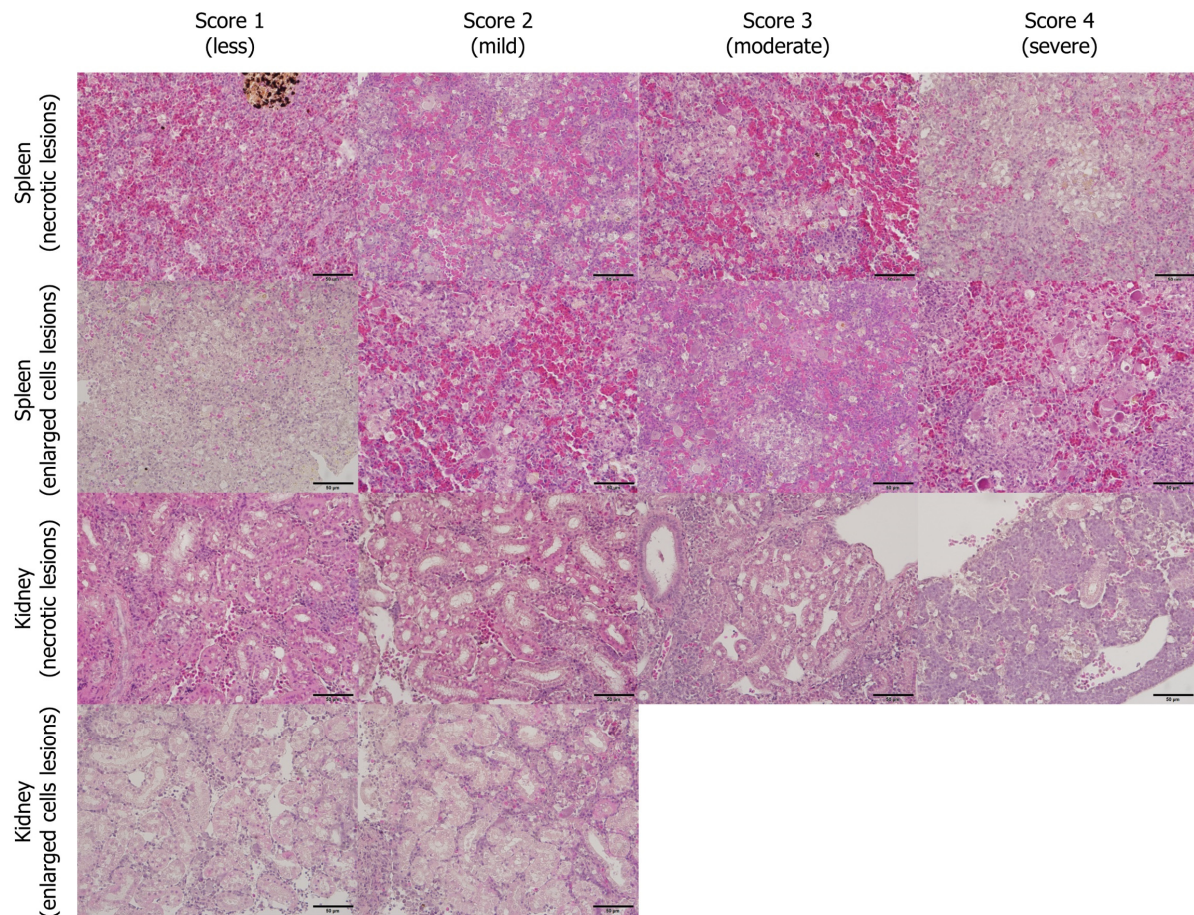


Figure S1. Scoring of lesions: Histopathological scoring of the lesions of red sea bream iri-dovirus-induced necrotizing lesions and enlarged cells lesions in the flathead grey mullet (*Mugil cephalus*) spleen and kidney tissues (haematoxylin and eosin stain, bar = 50 µm).