

Case Report

Sedline[®] Miscalculation of Depth of Anaesthesia Variables in Two Pigs Due to Electrocardiographic Signal Contamination

Alessandro Mirra ^{1,*}, Darren Hight ², Alan Kovacevic ³ and Olivier Louis Levionnois ¹

¹ Section of Anaesthesiology and Pain Therapy, Department of Clinical Veterinary Medicine, Vetsuisse Faculty, University of Bern, 3012 Bern, Switzerland; olivier.levionnois@unibe.ch

² Department of Anaesthesiology and Pain Medicine, Inselspital Bern University Hospital, University of Bern, 3010 Bern, Switzerland; darren.hight@insel.ch

³ Small Animal Internal Medicine, Vetsuisse Faculty, University of Bern, 3012 Bern, Switzerland; alan.kovacevic@unibe.ch

* Correspondence: alessandro.mirra@unibe.ch

Simple Summary: The assessment of the depth of anaesthesia remains challenging. In experimental pigs, the use of electroencephalography-based monitors has spread to characterizing brain activity depression as a surrogate of anaesthetics' hypnotic effect. However, these devices have been validated for humans and, most of the time, a mere application has been performed in animal species including pigs with little effort made to assess their actual usability. Moreover, while artefacts within the electroencephalographic signal originating from other sources than the brain (e.g., electromyographic activity) have been extensively reported in humans, such interferences have not been characterized in this species yet. We report the contamination of the electroencephalographic signal by the electrocardiographic activity in two pigs undergoing general anaesthesia, leading to miscalculation of the variables displayed by the depth of the anaesthesia monitor Sedline. Visual interpretation of the raw electroencephalogram remains necessary to avoid making wrong clinical decisions based on such electroencephalography-derived variables.



Citation: Mirra, A.; Hight, D.; Kovacevic, A.; Levionnois, O.L. Sedline[®] Miscalculation of Depth of Anaesthesia Variables in Two Pigs Due to Electrocardiographic Signal Contamination. *Animals* **2023**, *13*, 2699. <https://doi.org/10.3390/ani13172699>

Academic Editor: Pablo Sánchez Quinteiro

Received: 29 June 2023

Revised: 10 August 2023

Accepted: 22 August 2023

Published: 23 August 2023



Copyright: © 2023 by the authors. Licensee MDPI, Basel, Switzerland. This article is an open access article distributed under the terms and conditions of the Creative Commons Attribution (CC BY) license (<https://creativecommons.org/licenses/by/4.0/>).

Abstract: Two young (11-week-old) pigs underwent sole propofol anaesthesia as part of an experimental study. The depth of anaesthesia was evaluated both clinically and using the electroencephalography (EEG)-based monitor Sedline; in particular, the patient state index, suppression ratio, raw EEG traces, and its spectrogram were assessed. Physiological parameters and electrocardiographic activity were continuously monitored. In one pig (Case 1), during the administration of high doses of propofol, the Sedline-generated variables suddenly indicated an increased EEG activity while this was not confirmed by observation of either the raw EEG or its spectrogram. In the second pig (Case 2), a similar event was recorded during euthanasia with systemic pentobarbital. Both events happened while the EEG activity was isoelectric except for signal interferences and synchronous in rhythm and shape with the electrocardiographic activity. The suggestion of increased brain activity based on the interpretation of the Sedline variables was suspected wrong; most probably due to electrocardiographic interferences. In pigs, the patient state index and suppression ratio, as calculated by the Sedline monitor, could be influenced by the electrocardiographic activity contaminating the EEG trace, especially during otherwise isoelectric periods (strong EEG depression). Visual interpretation of the raw EEG and of the spectrogram remains necessary to identify such artefacts.

Keywords: Sedline; patient state index; suppression ratio; electroencephalogram; electrocardiogram; depth of anaesthesia; signal contamination; interference; pig

1. Introduction

The accurate assessment of the depth of anaesthesia (DoA) remains a significant challenge which is of major significance in pigs undergoing surgical experimental procedures. Indeed, DoA is still mainly monitored by assessing cardio-respiratory variables,

trigeminal reflexes (e.g., palpebral reflex), and more complex responses (e.g., movement following a painful stimulus) [1–3]. To date, no gold standard methodology has been established. Over the last 20 years, some research groups attempted to improve DoA assessment in pigs by characterizing the extent of brain activity depression [4–6]. Different electroencephalographic (EEG)-based monitors have been used. However, being developed on human data and using proprietary algorithms, their inter-species translation could lead to signal miscalculation and misinterpretation. This methodology also presents limitations. For instance, non-GABAergic drugs (e.g., ketamine) have been shown to lead to erroneous increases in index values in humans [7,8] and little information is present concerning pigs. Furthermore, artefacts within the EEG originating from other sources than the brain (e.g., electrocardiographic (ECG) activity and eye movements) have been extensively reported in humans [9–11] and may differ in pigs. Despite this, few efforts have been made to characterize and remove interferences during application of these devices in animal species. The purpose of this case report in two pigs undergoing general anaesthesia is to describe interferences within the EEG, very likely due to the ECG signal, leading to miscalculation of the variables displayed by the Sedline monitor.

2. Case Presentation

2.1. Case 1

An 11-week-old, 27.1 kg, male castrated pig (phenotypic Edelschwein) underwent a sole propofol anaesthesia as part of an approved experimental study (protocol number from Canton Bern: BE116/19).

After acclimatization, the pig was placed in a sling and instrumented. Following application of a local anaesthetic cream (EMLA 5%, Anesderm, Pierre Fabre, Switzerland), an ear venous and arterial catheter were placed. A six lead wireless device (Televet 100, Engel Engineering Services GmbH, Heusenstamm, Germany) was used to continuously assess the ECG activity. A Sedline monitor (Masimo Corp., Irvine, CA, USA) was used to continuously assess the EEG activity and record the patient state index (PSI, no unit), suppression ratio (SR, in %), left and right spectral edge frequencies 95% (SEF L and SEF R, in Hz), as well as electromyographic activity (EMG, in %), and non-brain related artefacts (ARTE, in %) every two seconds. A paediatric RD Sedline-sensor was placed over the frontal bone of the animal as previously reported [12] (Figure 1). The EEG data were exported (sampling rate: 178 Hz, left pre-frontal (Fp1) electrode) and spectrograms were created using two second moving windows (overlap 1-s; Figure 2).

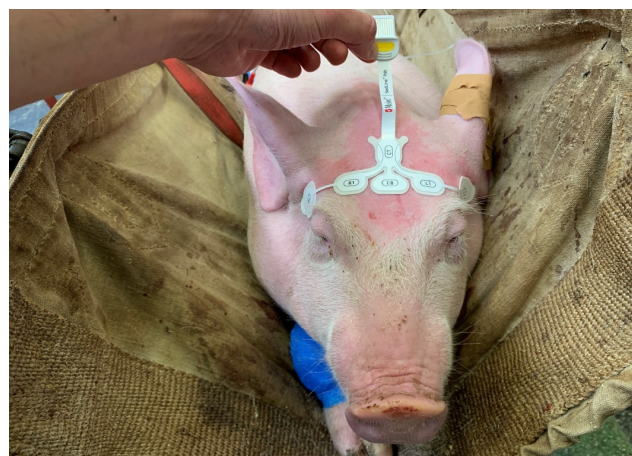

Figure 1. Positioning of the paediatric SedLine electrodes in a pig. The electrode line (L2, L1, R1, R2, from left to right) was placed over the frontal bone, keeping the rostral border of the electrodes on an imaginary line running between the lateral canthi of the eyes. The central GB (ground) and the caudal CT (reference) electrodes were placed on the mid-sagittal line.

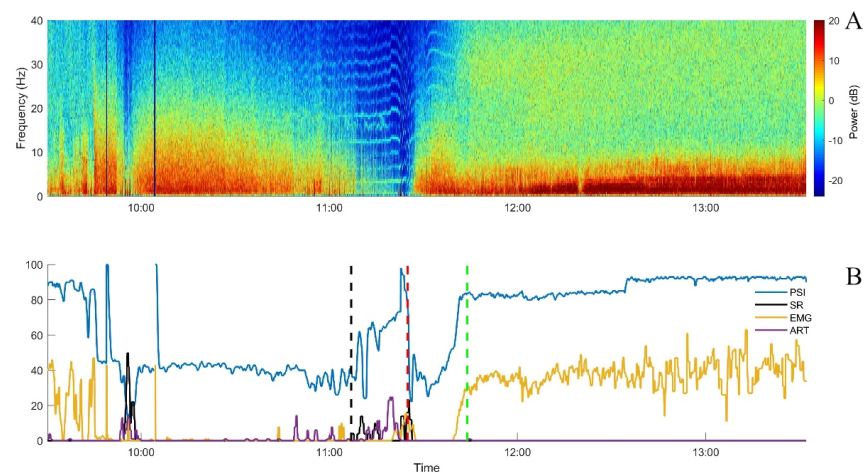


Figure 2. Spectrogram (A) and Sedline parameters graphically represented (B) from Case 1 over time. All Sedline values are smoothed using a 10 s median filter. Endotracheal intubation attempts occurred immediately prior to 10:00. Black dashed vertical line: sixth bolus of propofol; red dashed vertical line: propofol stop; green dashed vertical line: extubation; PSI: patient state index (blue, no unit); EMG: electromyographic activity (yellow, in %); SR: suppression ratio (black, in %); ART: artefact (purple, in %).

The heart rate (HR), respiratory rate, arterial blood pressure, palpebral reflex, jaw tone, peripheral oxygen saturation (SpO₂), and hind-limb nociceptive withdrawal reflex threshold (NWR; PainTracker; Dolosys GmbH, Berlin, Germany) were also assessed.

According to the experimental protocol, endotracheal intubation (ETI) was achieved with intravenous propofol to effect (approximately 5 mg/kg, administered at around 09:50). Simultaneously, a propofol infusion (20 mg/kg/h) was started and then incremented (6 mg/kg/h, associated with a bolus of 0.5 mg/kg, every 10 min) until reaching a target SR between 10 and 30%, as displayed on the Sedline. After each of the first five increments, a decrease in the PSI occurred, as expected. After the sixth one, the PSI increased markedly while the EEG appeared clearly suppressed on all four channels (soon after 11:00). No clinical signs of anaesthesia lightening were present: no gross movement, no palpebral reflex, absence of jaw tone, and stable cardiovascular and respiratory parameters. Moreover, the NWR threshold continued to increase. In parallel, the value for artefact recognition increased (max value 31%; Figure 3).

The heart rhythm was always sinus, with a rate ranging between 180 and 200 beats per minute (bpm). The raw EEG displayed a nearly isoelectric line (<10 μ V) in addition to monomorphic peaks at very regular intervals with a rate similar to the heart rhythm (Figure 3).

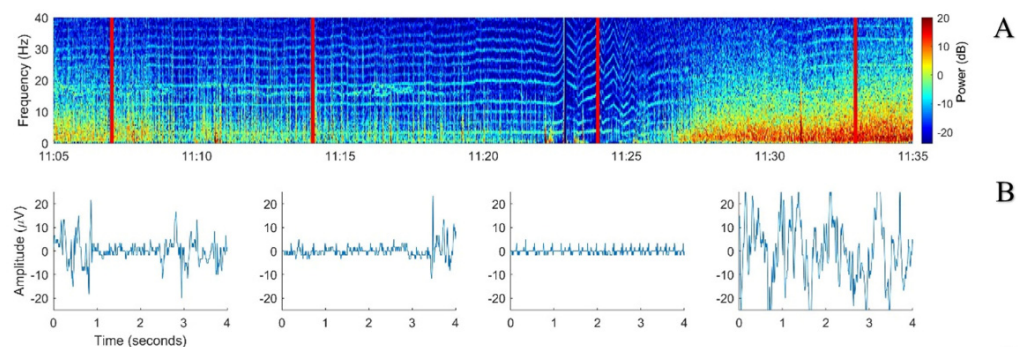


Figure 3. Cont.

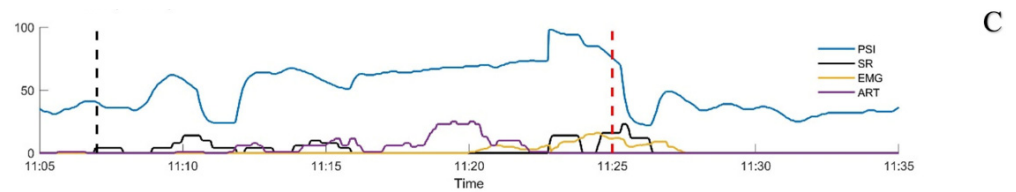


Figure 3. Period of suspected Sedline miscalculation from Case 1. (A) Spectrogram from the sixth propofol bolus (black dashed vertical line in 3C) until propofol was discontinued (red dashed vertical line in 3C). (B) Examples of 4-s EEG signals taken from the timepoints shown by the red full lines on the spectrogram. (C) Sedline parameters smoothed with a 10 s median filter. PSI: patient state index (blue, no unit); EMG: electromyographic activity (yellow, in %); SR: suppression ratio (black, in %); ART: artefact (purple, in %).

During the following 15 min, the SR showed some increases but did not reach the target to stop propofol administration (10–30%; Figure 3). However, DoA was considered clinically as deep and the EEG was judged as isoelectric. The displayed PSI and SR values were both considered aberrant, most probably due to the ECG signal appearing in the EEG. Therefore, propofol administration was stopped. A few minutes later, the PSI returned to values similar to those immediately before the sixth bolus of propofol and then increased progressively as the pig recovered from general anaesthesia (Figure 2). The recovery was uneventful and no other incongruences between clinical DoA assessment and Sedline-generated variables were noticed.

2.2. Case 2

An 11.5-week-old, 32.8 kg, female pig (phenotypic Edelschwein) underwent a similar experimental study as described above until recovery from general anaesthesia followed by final euthanasia while the pig was still instrumented. By the end of recovery, the pig started to show marked excitation and accidentally displaced its ear venous catheter. It was decided to proceed to euthanasia. As planned, pentobarbital (150 mg/kg) was administered but into the coccygeal arterial catheter which was still available. Injection was performed over 10 seconds (at 13:57). Immediately after drug administration, EEG and invasive blood pressure curves became isoelectric, the animal stopped breathing, and neither movements nor reflexes were present. However, the ECG activity continued to be present, showing different subsequent patterns:

- 13:59: third degree atrio-ventricular block (HR 120 bpm);
- 14:02: narrow QRS rescue rhythm (HR 96–108 bpm);
- 14:05: wide QRS rescue rhythm (HR 96–108 bpm) including a change in polarity associated with non-conducted P waves;
- 14:08: further change in polarity;
- 14:10–14:22: short periods of ventricular standstill and QRS waves with different polarity while atrial activity was still present.

In the meantime, the ECG patterns were recognizable on the raw EEG traces and the PSI and SR values increased and decreased over time (Figure 4).

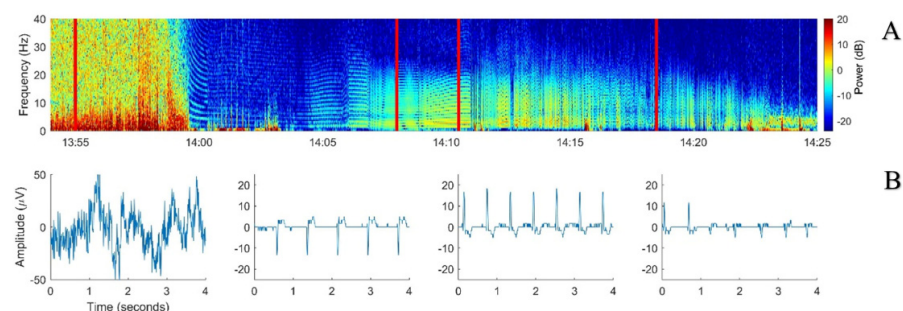


Figure 4. Cont.

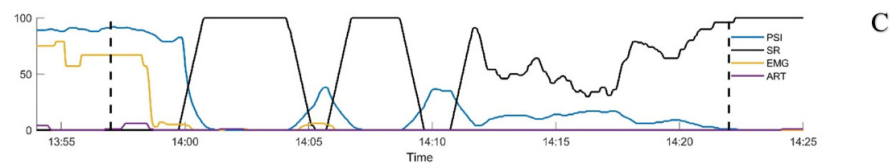


Figure 4. Spectrogram: example EEG sections and Sedline parameters over time from Case 2. (A) spectrogram of the EEG collected during euthanasia with intravenous pentobarbital (13:57). (B) Examples of 4-s EEG signals taken from the left pre-frontal electrode (Fp1) at four different timepoints corresponding to the vertical red bold lines on the spectrogram. (C) Sedline parameters smoothed with a 10 s median filter. First black dashed vertical line: first pentobarbital bolus for euthanasia. Second black vertical dashed line: intracardiac pentobarbital bolus. PSI: Patient State Index (blue, no unit); SR: suppression ratio (black, in %); EMG: electromyographic activity (yellow, in %); ART: artifact (purple, in %).

Due to the persistent ECG activity, 25 minutes after the induction of euthanasia (14:22), pentobarbital (150 mg/kg) was repeated intracardially. The ECG electrical activity ceased immediately, no further interferences on the EEG trace were noticed (flat isoelectric line), PSI decreased to 0, and SR increased to 100%.

3. Discussion and Conclusions

In this case report, we have shown that electrical activity generated from another source than the brain can lead to PSI and SR miscalculation by the Sedline monitor in pigs. The ECG signal contaminating the EEG was interpreted by the Sedline as an increased brain activity raising and decreasing the PSI and SR values, respectively. This miscalculation could lead to inadequate interpretation and clinical decision from the anaesthetist if the mere EEG-derived parameters are used without interpreting the raw EEG.

Many signals have been reported to interfere with the EEG, including electromyographic [9] and epileptiform activity [13], cerebral spinal fluid pulsation [14], and ECGs [15]. Of these, the latter has been the focus of many studies trying to reduce its interference with the EEG signal [16–18]. However, no gold standard methodology has been found yet. Moreover, even though most commercial EEG monitors claim to be able to reduce interferences from external noises, their algorithms remain proprietary; thus, it is difficult to judge their efficacy while attempting to estimate hypnotic depth in pigs. It is also important to mention that these devices have all been developed on and for humans and have never been validated in pigs [19]. Thus, their use in non-human species can result in inappropriate output and wrong clinical decisions.

The species-specific anatomical differences, as for example the proximity between brain and heart and the length of the neck, may enhance the risk of ECG signal contamination in the EEG dataset. This topic, as well as appropriate solutions, requires further investigations.

A previous study reported external signal interference involving artery pulsation while using the Sedline monitor [10]. In our animals, the interference appeared to be related to the ECG activity. In the first case, an increase in the PSI was noticed while propofol was administered at high dose. This increase would be expected to correlate with a lighter anaesthetic level but this did not mirror the dosage administered and the other clinical and neurophysiological (NWR threshold) parameters that reflected a deep anaesthetic plane. Visual inspection of the raw EEG signal revealed ECG interferences also present at many other time points from the beginning of the recording on. However, they seemed not to influence the Sedline calculations, probably due to their lower relative amplitude compared to the EEG signal. When brain activity became suppressed, the ECG became dominant in the EEG trace and was interpreted by the Sedline as an increase in its activity (Figure 3). A similar situation was found in the second case where the ECG was the sole electrical signal present after euthanasia. Also in this case, some ECG artefacts could be noticed in

the spectrogram but they seemed not to influence the Sedline calculation until euthanasia was performed.

It is worth noting that the light blue or green horizontal stripes in the spectrogram, clearly visible when the EEG power is low, are most probably artefacts resulting from the inability of the Fast Fourier Transform (FFT) to model the low-frequency, sharp, and high-amplitude waves that the ECG signal produces [20].

In pigs, Sedline PSI and SR could be influenced by both the amplitude and polarity of the ECG trace contaminating the EEG, especially during isoelectric periods. Visual interpretation of the raw EEG and of the spectrogram remains necessary to identify such artefact interactions.

Author Contributions: Conceptualization, A.M., D.H. and O.L.L.; methodology, A.M., D.H. and O.L.L.; formal analysis, A.M., D.H., A.K. and O.L.L.; investigation, A.M., D.H., A.K. and O.L.L.; data curation, A.M., D.H., A.K. and O.L.L.; writing—original draft preparation, A.M.; writing—review and editing, D.H., A.K. and O.L.L. All authors have read and agreed to the published version of the manuscript.

Funding: This research was funded by the Swiss National Science Foundation (Spark) [Grant number CRSK-3_190926/1] and by the Berne University Research Foundation and BEKB Förderfonds. The funder had no role in study design, data collection and analysis, decision to publish, or preparation of the manuscript.

Institutional Review Board Statement: The animal study protocol was approved by the Committee for Animal Experiments of the Canton of Bern, Switzerland (Protocol Number: 32015).

Informed Consent Statement: Not applicable.

Data Availability Statement: The data presented in this study are openly available in Boris Portal at <https://doi.org/10.48620/114>.

Conflicts of Interest: The authors declare no conflict of interest.

References

1. Ryden, A.; Fisichella, S.; Perchiazzi, G.; Nyman, G. Comparison of two injectable anaesthetic techniques on induction and subsequent anaesthesia in pigs. *Lab. Anim.* **2021**, *55*, 540–550. [[CrossRef](#)] [[PubMed](#)]
2. Lervik, A.; Raszplewicz, J.; Ranheim, B.; Solbak, S.; Toverud, S.F.; Haga, H.A. Dexmedetomidine or fentanyl? Cardiovascular stability and analgesia during propofol-ketamine total intravenous anaesthesia in experimental pigs. *Vet. Anaesth. Analg.* **2018**, *45*, 295–308. [[CrossRef](#)] [[PubMed](#)]
3. De Monte, V.; Staffieri, F.; di Meo, A.; Vannucci, J.; Bufalari, A. Comparison of ketamine-dexmedetomidine-methadone and tiletamine-zolazepam-methadone combinations for short-term anaesthesia in domestic pigs. *Vet. J.* **2015**, *205*, 364–368. [[CrossRef](#)] [[PubMed](#)]
4. Jaber, S.M.; Sullivan, S.; Hankenson, F.C.; Kilbaugh, T.J.; Margulies, S.S. Comparison of Heart Rate and Blood Pressure with Toe Pinch and Bispectral Index for Monitoring the Depth of Anesthesia in Piglets. *J. Am. Assoc. Lab. Anim. Sci.* **2015**, *54*, 536–544. [[PubMed](#)]
5. Llonch, P.; Andaluz, A.; Rodríguez, P.; Dalmau, A.; Jensen, E.W.; Manteca, X.; Velarde, A.; Dvm, M.P.R. Assessment of consciousness during propofol anaesthesia in pigs. *Vet. Rec.* **2011**, *169*, 496. [[CrossRef](#)] [[PubMed](#)]
6. Martín-Cancho, M.F.; Lima, J.R.; Luis, L.; Crisóstomo, V.; López, M.A.; Ezquerro, L.J.; Carrasco-Jiménez, M.S.; Usón-Gargallo, J. Bispectral index, spectral edge frequency 95% and median frequency recorded at varying desflurane concentrations in pigs. *Res. Vet. Sci.* **2006**, *81*, 373–381. [[CrossRef](#)] [[PubMed](#)]
7. Schüller, S.S.; Petersen, C.L.; West, N.C.; Ansermino, J.M.; Merchant, R.N.; Görges, M. The effect of ketamine on depth of hypnosis indices during total intravenous anesthesia—A comparative study using a novel electroencephalography case replay system. *J. Clin. Monit. Comput.* **2021**, *35*, 1027–1036. [[CrossRef](#)] [[PubMed](#)]
8. Purdon, P.L.; Sampson, A.; Pavone, K.J.; Brown, E.N. Clinical Electroencephalography for Anesthesiologists: Part I: Background and Basic Signatures. *Anesthesiology* **2015**, *123*, 937–960. [[CrossRef](#)] [[PubMed](#)]
9. Goncharova, I.; McFarland, D.; Vaughan, T.; Wolpaw, J. EMG contamination of EEG: Spectral and topographical characteristics. *Clin. Neurophysiol.* **2003**, *114*, 1580–1593. [[CrossRef](#)] [[PubMed](#)]
10. Kamata, K.; Lipping, T.; Yli-Hankala, A.; Jäntti, V.; Yamauchi, M. Spurious electroencephalographic activity due to pulsation artifact in the depth of anesthesia monitor. *JA Clin. Rep.* **2021**, *7*, 35. [[CrossRef](#)] [[PubMed](#)]

11. Guerrero-Mosquera, C.; Vazquez, A.N. Automatic removal of ocular artifacts from EEG data using adaptive filtering and independent component analysis. In Proceedings of the 17th European Signal Processing Conference, Glasgow, UK, 24–28 August 2009; pp. 2317–2321.
12. Mirra, A.; Casoni, D.; Barge, P.; Hight, D.; Levionnois, O.; Spadavecchia, C. Usability of the SedLine® electroencephalographic monitor of depth of anaesthesia in pigs: A pilot study. *J. Clin. Monit. Comput.* **2022**, *36*, 1635–1646. [[CrossRef](#)] [[PubMed](#)]
13. Särkelä, M.O.K.; Ermes, M.J.; van Gils, M.J.; Yli-Hankala, A.M.; Jäntti, V.H.; Vakkuri, A.P. Quantification of Epileptiform Electroencephalographic Activity during Sevoflurane Mask Induction. *Anesthesiology* **2007**, *107*, 928–938. [[CrossRef](#)] [[PubMed](#)]
14. Wallace, A.; Shin, C.; Wirrell, E.C.; Burkholder, D.B. False ictal-appearing EEG from a frontal sinus pseudomeningocele. *Neurology* **2016**, *87*, 2600–2601. [[CrossRef](#)] [[PubMed](#)]
15. Chakrabarti, D.; Bansal, S. ECG contamination of EEG signals: Effect on entropy. *J. Clin. Monit. Comput.* **2016**, *30*, 119–122. [[CrossRef](#)] [[PubMed](#)]
16. Tong, S.; Bezerianos, A.; Paul, J.; Zhu, Y.; Thakor, N. Removal of ECG interference from the EEG recordings in small animals using independent component analysis. *J. Neurosci. Methods* **2001**, *108*, 11–17. [[CrossRef](#)] [[PubMed](#)]
17. Mateo, J.; Sánchez-Morla, E.; Santos, J. A new method for removal of powerline interference in ECG and EEG recordings. *Comput. Electr. Eng.* **2015**, *45*, 235–248. [[CrossRef](#)]
18. Devuyst, S.; Dutoit, T.; Stenuit, P.; Kerkhofs, M.; Stanus, E. Removal of ECG artifacts from EEG using a modified independent component analysis approach. In Proceedings of the 30th Annual International Conference of the IEEE Engineering in Medicine and Biology Society EMBS'08—Personalized Healthcare through Technology, Vancouver, BC, Canada, 20–25 August 2008; pp. 5204–5207. [[CrossRef](#)]
19. Mirra, A.; Maidanskaia, E.G.; Carmo, L.P.; Levionnois, O.; Spadavecchia, C. How is depth of anaesthesia assessed in experimental pigs? A scoping review. *PLoS ONE* **2023**, *18*, e0283511. [[CrossRef](#)] [[PubMed](#)]
20. Pullon, R.M.; McCabe, S.; Gaskell, A.; Sleight, J.W. Non-sinusoidal waves in the EEG and their simulated effect on anaesthetic quantitative EEG monitors. *J. Clin. Monit. Comput.* **2019**, *33*, 1089–1096. [[CrossRef](#)] [[PubMed](#)]

Disclaimer/Publisher's Note: The statements, opinions and data contained in all publications are solely those of the individual author(s) and contributor(s) and not of MDPI and/or the editor(s). MDPI and/or the editor(s) disclaim responsibility for any injury to people or property resulting from any ideas, methods, instructions or products referred to in the content.