

Supplementary Materials

Figure S1. Macroscopic observation of lung lesions.

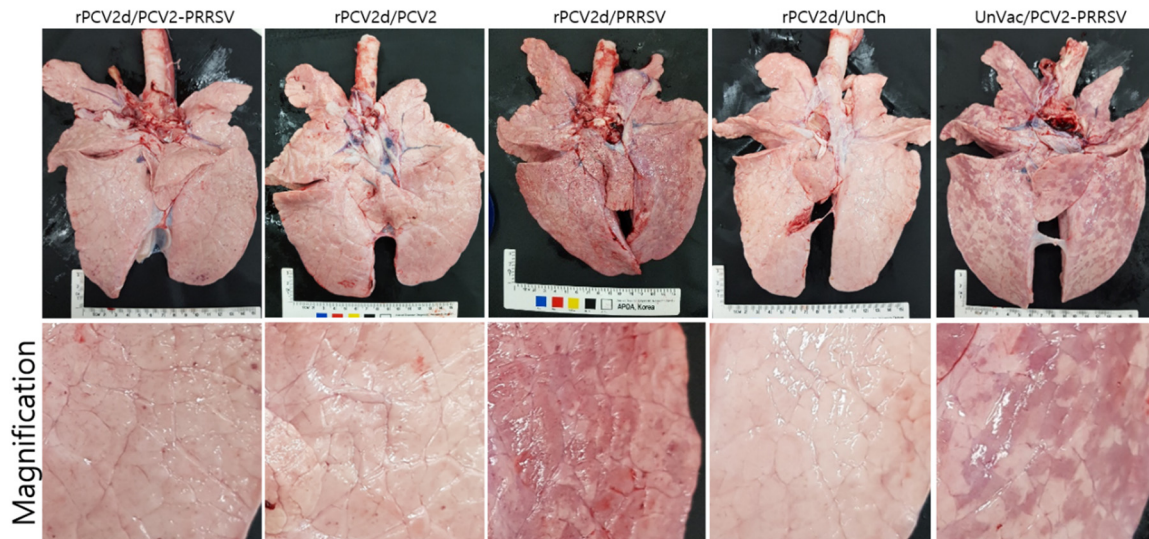


Figure S2. Microscopic observation of lesions in lung, tonsil, mesenteric and inguinal LN.

