Journal of
Personalized Medicine

MDPI

Article

SEquential Utilization of MIcrospheres and GLUE ("SEMIGLUE" Approach) for Prostatic Artery Embolization Initial Experience

Hippocrates Moschouris [1,2,*], Elena Hadjichristou [1], Apostolos Mouroukis [1], Maria-Theodora Moschouri [2], Konstantinos Stamatiou [3], Marios Ioannou [3], Dimitrios Kourdakis [4] and Adam Hatzidakis [4]

[1] Radiology Department, University Hospital of Alexandroupolis, 68100 Alexandroupolis, Greece; elech@med.uoa.gr (E.H.); aposmour@med.duth.gr (A.M.)
[2] Department of Medicine, School of Heath Sciences, Democritus University of Thrace, 68100 Alexandroupolis, Greece; marimosc9@med.duth.gr
[3] Urology Department, General Hospital "Tzanio", 18536 Piraeus, Greece; ourologikitzaneio@gov.gr (K.S.); ioannmarios472@gmail.com (M.I.)
[4] Department of Radiology, AHEPA University Hospital of Thessaloniki, Aristotle University of Thessaloniki, 54636 Thessaloniki, Greece; dkourdakis@ahepahosp.gr (D.K.); adamhatz@auth.gr (A.H.)
* Correspondence: hipmosch@gmail.com

Abstract

Background/Objectives: Prostatic artery embolization (PAE) with an n-butyl cyanoacrylate (NBCA) glue–lipiodol mixture offers potential advantages over PAE with microspheres for the treatment of symptomatic benign prostatic hyperplasia (BPH). However, the distal penetration of glue–lipiodol in intraprostatic vasculature is often not possible, and proximal-only prostatic artery (PA) occlusion with glue may fail to induce significant prostatic infarction. To mitigate this limitation, the authors applied and evaluated SEquential utilization of MIcrospheres and GLUE for PAE (SEMIGLUE-PAE). **Methods**: For SEMIGLUE-PAE, embolization began with microspheres (100–300 μm) with the microcatheter tip at the distal extraprostatic part of the PA; intraprostatic advancement of the microcatheter and injection of additional microspheres were then attempted. When flow stasis in intraprostatic branches was observed, embolization continued with small aliquots (0.1 mL) of the glue–lipiodol mixture (1:8) with the same initial position of the microcatheter tip, until the distal one-half (to two-thirds) of the extraprostatic PA was filled with the mixture. Twenty-three consecutive patients with symptomatic BPH were treated with SEMIGLUE-PAE in a single tertiary center. After the exclusion of three patients who were lost to follow-up, 20 patients were included in the final analysis of this retrospective study. Short-term improvements in imaging and clinical parameters and safety were evaluated. **Results**: Clinical success rates were 95%, 90%, and 83.6% at 3, 6, and 12 months post SEMIGLUE-PAE, respectively. Three months post-SEMIGLUE-PAE, the mean reduction in prostate volume was 32.4% ($p < 0.01$) and the mean improvement in the international prostate symptom score was 61.2% ($p < 0.01$). The mean percentage of prostatic infarction (measured within 24 h post-PAE and compared to baseline PV) was 45.7%. Minor (only) complications were encountered in 4/20 patients. **Conclusions**: SEMIGLUE-PAE seems to be safe, effective, and feasible; it merits further clinical application and long-term evaluation and could contribute to the personalized interventional management of symptomatic BPH.

Keywords: N-butyl cyanoacrylate glue; lipiodol; microspheres; prostatic artery embolization; infarction

Check for updates

Academic Editor: Liang Cheng

Received: 30 September 2026
Revised: 14 November 2026
Accepted: 21 November 2026
Published: 25 November 2026

Copyright: © 2026 by the authors. Licensee MDPI, Basel, Switzerland. This article is an open access article distributed under the terms and conditions of the Creative Commons Attribution (CC BY) license.

1. Introduction

During the last few years, an n-butyl cyanoacrylate (NBCA) glue–lipiodol mixture has emerged as a promising embolic alternative to microparticles for prostatic artery embolization (PAE) [1]. Attractive features of glue–lipiodol as an embolic material for PAE (glue–PAE) include its potential for rapid and possibly durable vascular occlusion and its radiopacity, which enhances radiologic visualization of the embolic mixture during and after the procedure [1,2]. Radiation exposure appears to be lower with glue-PAE compared to the "standard" PAE technique with microspheres, and the two approaches have demonstrated comparable clinical efficacy and safety [3].

However, glue–PAE is even more technically demanding than the standard PAE procedure and requires significant operator expertise [4]; in addition to the usual limitations associated with glue as an embolic material (microcatheter occlusion or microcatheter adhesion to arterial wall, glue reflux and irreversible occlusion of non-target arteries, etc.), distal penetration of glue into the prostate and adequate coverage of small, tortuous intraprostatic branches with slow flow may be extremely difficult and may require significant experience and the application of special techniques [4,5]. The association of the level (proximal versus distal) of PA embolization with the extent of prostatic ischemia has not been studied in detail. In one illustrative case, proximal-only PA occlusion with glue failed to induce any prostatic infarction [6]. Evidence from other vascular territories also indicates that proximal artery occlusion with glue can activate collateral circulation to the target [7]; proximal artery occlusion will also permanently block subsequent attempts to reach smaller, distal branches with the microcatheter.

The authors hypothesized that these challenges surrounding glue–PAE, which may be more pronounced for operators with limited experience in glue embolization, could be addressed with the "SEquential utilization of MIcrospheres and GLUE" ("SEMIGLUE") approach. The primary objective of this study was to describe SEMIGLUE-PAE and to investigate its early clinical outcomes and safety. The secondary objective was to describe imaging findings relevant to this approach and to present its potential contribution in the personalized interventional management of symptomatic benign prostatic hyperplasia (BPH).

2. Materials and Methods

2.1. Study Design and Inclusion and Exclusion Criteria

A retrospective review was conducted of the first patients who received SEMIGLUE-PAE for symptomatic BPH at a tertiary center (from March 2025 to November 2025). The inclusion criteria were as follows [8]: moderate or severe lower urinary tract symptoms (International Prostate Symptom Score, IPSS $\geq$ 8); quality of life (QoL) $\geq$ 3; failure of medical treatment; and prostate volume PV > 40 mL. Patients with chronic urinary retention caused by BPH and managed with indwelling bladder catheter were also candidates for SEMIGLUE-PAE. Exclusion criteria were urinary tract infection; prostate or bladder cancer; neurogenic bladder; large (>2.5 cm) bladder diverticula or bladder stones; contraindications to angiographic procedures; and clinical and imaging follow-up of less than 3 months.

All patients had been informed of the procedure, the imaging follow-up protocol and the associated risks in detail and had provided written informed consent. The study was approved by the institutional review board.

2.2. Pre-Interventional Evaluation

All patients were clinically evaluated prior to treatment. QoL scores were recorded for all patients; IPSS scores were recorded for the patients who were not catheter-dependent. Contrast-enhanced pelvic computed tomography (CT) and CT angiography (CTA) were

performed a few days prior to intervention, to evaluate prostate size and morphology, detect any coexistent pathology and enable vascular planning. A 64-row scanner (Optima CT 660, GE Healthcare, Japan Corporation, Hino, Tokyo, Japan) was used for the CT studies for all patients. Power settings were 120 kV, auto milliamperage, matrix of 512 × 512 pixels, slice thickness 0.625 mm, and pitch 0.984:1. Iodinated contrast agent injection (100–120 mL, 350 mg I/mL, rate 4.5–5 mL/s) was performed with bolus triggering, with a region of interest (ROI) placed in the lower abdominal aorta. Scanning was initiated when the ROI reached a threshold of 300 Hounsfield units. Sagittal oblique maximum intensity projections (MIPs) were produced from axial arterial phase images to demonstrate the origin of the PAs. CTA was not systematically utilized to identify potentially hazardous arterial anastomoses; the authors preferred to evaluate such anastomoses during the intervention with superselective injections and digital subtraction angiography. Prostate volume was calculated with Artificial Intelligence-assisted segmentation and volumetry on axial CT images with dedicated software ("3D Slicer" with "nnInteractive" AI Segmentation addon) [9–11]. Post-void residual (PVR) was measured with trans-abdominal ultrasound. Uroflowmetry was performed at the discretion of the referring urologist, but the respective data (as well as those regarding erectile function) were not collected in the context of the study. Prostatic specific antigen (PSA) measurements were available for all patients at baseline; however, post-interventional PSA changes were not recorded.

2.3. PAE Technique

Vascular access was obtained via the common femoral artery and catheterization of the PA was performed in the usual manner. A 1.9 Fr or 1.98 Fr microcatheter (Tellus or Parkway Soft, Asahi Intecc Co., Seto, Aichi, Japan) and a double-angle microguidewire (0.016'' Meister, Asahi, Japan) were the standard combination of devices for PA catheterization. When this combination failed, the standard microcatheter was replaced with a 2.4 Fr steerable microcatheter (Swiftninja, Merit Medical, South Jordan, UT, USA). If possible, the microcatheter was advanced into the distal extraprostatic part of the PA, just proximal to the prostatic capsule. Embolization began from that point, using hydrophilic polymer (Polifit 70®) microspheres with a diameter of 100–300 µm (Embosoft, Scitech Medical, Goiás, Brazil). Distal advancement of the microcatheter in intraprostatic branches and additional injection of microspheres was then applied, if vascular anatomy was favorable. Embolization with microspheres stopped when complete flow stasis in the intraprostatic vascular bed was achieved. Flow stasis was defined as a complete absence of opacification of intraprostatic branches during contrast injection at the distal extraprostatic part of the PA. Thereafter, glue embolization also began with the tip of the microcatheter at the distal extraprostatic part of the PA. In line with many glue–PAE studies [1], an 1:8 glue/lipiodol mixture (Glubran2, GEM, Viareggio (Lucca) Italy/Lipiodol Ultra Fluid, Guerbet, Villepinte, France) was routinely utilized and small aliquots (0.1 mL) were injected through the microcatheter with a 1 mL syringe with luer-lock. With smaller PAs in particular, a "blocked flow" technique (with the microcatheter "wedged" in the distal extraprostatic part of the PA) was occasionally attempted, although this was not aggressively pursued. The microcatheter was then slowly withdrawn while injecting the rest of the glue aliquot (using the "free-flow" technique). The microcatheter was flushed with 5 mL of nonheparinized 5% dextrose solution before and after each glue injection ("sandwich" technique). Additional 0.1 mL aliquots of glue/lipiodol were administered if required (especially in cases of PAs with a large diameter and a long trajectory). Injection of the glue–lipiodol mixture stopped when the distal half (up to two thirds) of the PA was filled with glue. When the distal extraprostatic part of the PA could not be approached (due to unfavorable anatomy or poor support from the base catheter), or when microcatheter "wedging" was considered

potentially traumatic for the arterial wall, embolization was performed with the "free-flow" technique only, with the microcatheter in a more proximal part of the PA, first with microspheres and then with glue–lipiodol, with the same respective endpoints as previously described. Complete flow stasis in the proximal part of the PA was considered as the final angiographic endpoint. The rationale for glue injection after achieving complete distal stasis with microsphere was to permanently block inflow and reduce the risk for recanalization of the arteries which had been occluded by the microspheres.

Almost immediately after the procedure (15–20 min after arterial closure), an unenhanced CT scan (same equipment with the pre-interventional CT) was applied to show the distribution of the embolic materials within and around the prostate. Radiation parameters (fluoroscopy time-FT and dose-area product-DAP) were recorded after each procedure. SEMIGLUE-PAE was performed by 2 interventional radiologists with approximately 10 years of experience in PAE with microspheres but with no previous experience in glue–PAE and with limited experience in the glue embolization of other organs.

2.4. Clinical Evaluation Post PAE

For patients with LUTS, the diagnosis of clinical success with SEMIGLUE-PAE was based on a reduction in IPSS (<18 with a decrease of at least 25% from baseline) and QoL (≤3, with at least a 1-point decrease compared to baseline). Clinical failure was defined as the persistence of severe symptoms (IPSS decrease ≤ 25%, IPSS score ≥ 18, QoL score decrease ≤ 1, and a QoL score ≥ 4) [8]. For catheter-dependent patients, diagnosis of clinical success was based on the successful removal of the indwelling bladder catheter and with PVR < 200 mL. Clinical failure in these patients was defined as consecutive failed attempts for bladder catheter removal every 2 weeks, for 2 months post PAE. The need for bladder catheter reinsertion after a period of freedom from catheter was also considered clinical failure [8,12]. Patients were clinically re-evaluated during the first 3–4 days post SEMIGLUE-PAE, one and three months later and then every three months. Complications were recorded and graded using the modified (for PAE) Clavien–Dindo system [13].

2.5. Imaging Evaluation Post PAE

Prostate infarction was calculated within 24 h post PAE, with transabdominal contrast-enhanced ultrasound (CEUS) after bolus intravenous injection of echo-enhancer (SonoVue, Bracco, Milan, Italy). The volume of each prostatic infarct was calculated using the ellipsoid formula; the volumes of all prostatic infarcts were summed and divided by PV, thus calculating the percentage of Prostatic Infarction (pPI) in line with previous work [14]. Three months post-SEMIGLUE-PAE, PV was measured again using CT and the aforementioned dedicated software, and prostate shrinkage was evaluated by comparing PV measurements at baseline and 3 months post-procedure. Post-void residual (PVR) was also measured 3 months post-procedure with transabdominal ultrasound and compared to baseline measurement. Angiographic evaluation with CTA 3 months post procedure (at the same session with the standard CT) and other imaging studies performed after 3 months were optional.

2.6. Statistics

Descriptive statistics were applied for the basic quantitative and qualitative parameters. The Wilcoxon Signed-Rank Test was used to evaluate the significance of the change in the outcome parameters before and after treatment. The Kaplan–Meier method was used to calculate the clinical success rates of SEMIGLUE PAE over time. Additionally, 95% confidence intervals (CIs) for these rates were calculated with the log-log transformation. Statistical significance was defined as a p value of <0.05. Statistical Package for Social Sciences (Version 26.0, SPSS Inc., Chicago, IL, USA) was used for the statistical analysis.

3. Results

3.1. Basic Population Features and Technical Outcomes

The "SEMIGLUE" approach was applied in 23 consecutive patients. Three of them were dismissed 14–18 h post procedure, before the early CEUS study, and did not return for the 3-month or for any other evaluation. These three patients had undergone bilateral SEMIGLUE-PAE and were also evaluated for (very early) complications; however, they were excluded from the main part of the study. Therefore, 20 patients were eventually studied and underwent full analysis (Figure 1, Table 1). Sixty percent of the studied patients ($n = 12$) suffered from moderate or severe LUTS and all of them had received medication for at least 6 months prior to intervention, with negligible effect on their symptoms. The rest of the studied patients ($n = 8$) were catheter-dependent for 2–5 months prior to intervention.

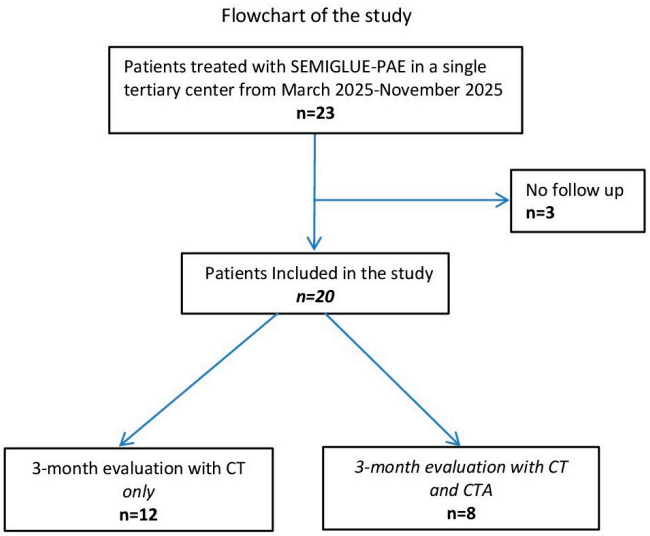

Figure 1. Flowchart of the patients in this study.

Table 1. Demographic and clinical features of the first 20 patients treated with "SEMIGLUE" PAE.

Variable	Value (Mean ± SD)
Age (years)	72.0 ± 8.7
PV (mL)	91.9 ± 34.4
PVR * (mL)	201 ± 91
IPSS *	24.0 ± 2.6
QoL	4.6 ± 0.5
Indication for PAE	Proportion of patients
- Moderate LUTS	3/20
- Severe LUTS	9/20
- IBC	8/20

PAE: Prostatic artery embolization; SD: standard deviation; PV: prostate volume; PVR: post void residual; IPSS: international prostate symptom score; QoL: quality of life; LUTS: lower urinary tract symptoms; IBC: indwelling bladder catheter. * IPSS and PVR were calculated only for patients with moderate or severe LUTS, and not for patients with IBC.

Bilateral PAE was performed in 18/20 patients and unilateral PAE in 2 patients (in total, 38 embolized hemiprostates). From a total of 46 PAs (2.3 PAs per patient), 42 were embolized with the aforementioned technique. The remaining four PAs were neither catheterized nor embolized. For two of those four PAs, several attempts at cannulation were made, but proved unsuccessful due to unfavorable anatomy. The last two PAs were considered too difficult to access and no catheterization attempts were made. Regarding procedural radiation

parameters, mean FT was 41.8 ± 13.0 min and mean DAP was 229.9 ± 119.1 Gy·cm^2. Total procedure time (measured from the moment of arterial puncture until the beginning of arterial manual compression) was 96.3 ± 23.4 min.

3.2. Clinical Outcomes

Follow-up times ranged from 3 to 13 months (mean: 9.45 months, median: 10 months). The clinical success rates were 95% (95% CI: 69.5–99.3%), 90% (95% CI: 65.6–97.4%) and 83.6% (95% CI: 56.8–94.5%) at 3, 6 and 12 months post SEMIGLUE-PAE, respectively (Figure 2). Three clinical failures were noted, and two of them occurred in patients with moderate or severe LUTS. Both patients experienced full symptomatic recurrence after a brief period (4 and 9 months post PAE, respectively) of improvement (40% reduction in IPSS for each of them). One of these patients was scheduled for Holmium-Laser enucleation of the prostate. Interestingly, the other patient reported great symptomatic improvement with tamsulosin, after failed (pre-PAE) medication with dutasteride. There was also one catheter-dependent patient who had undergone five failed attempts at catheter removal during the first two months post PAE. He was registered as undergoing clinical failure at month 2 post PAE and was successfully managed (and relieved from the bladder catheter) with transurethral resection of the prostate at month 4 post PAE. All other catheter-dependent patients were relieved of their Foley catheters 2–4 weeks post intervention and were able to urinate spontaneously with a PVR ranging from 49 to 156 mL. None of the patients with clinically successful procedures received medication for BPH post SEMIGLUE-PAE.

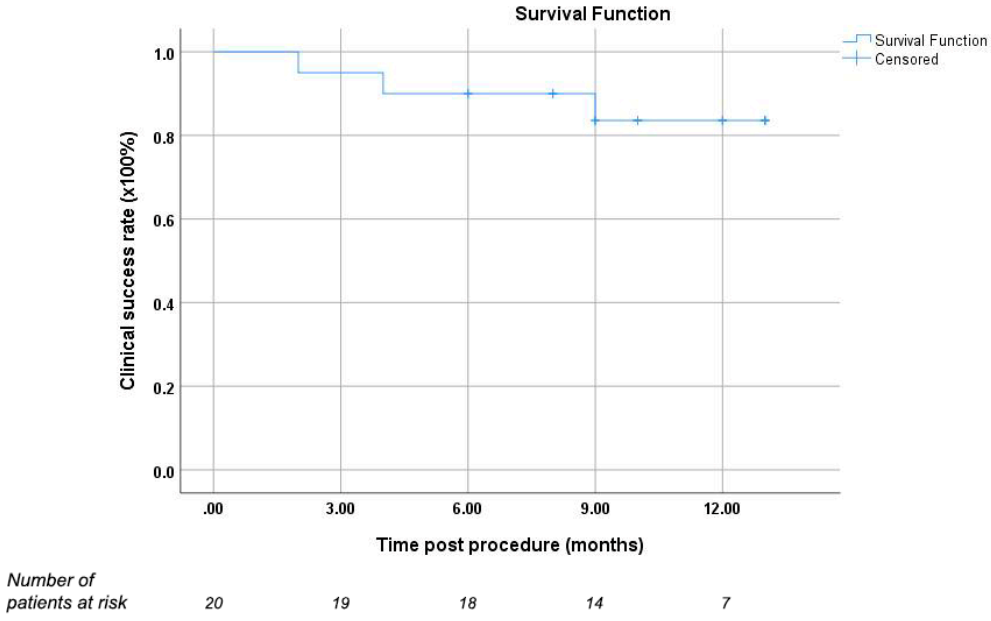

Figure 2. Kaplan–Meier curve showing short-term clinical success rates of SEMIGLUE-PAE.

Short-term improvement in imaging and clinical parameters was statistically significant, with a 32.4% mean reduction in PV and 61.2% mean improvement in IPSS (Table 2).

The majority of the patients (17/20 patients, 85%) experienced post-embolization syndrome (PES), which included dysuria, urgency, frequent urination, fever (up to 38 °C, with no other evidence of sepsis), pelvic/perineal pain, or a combination of these symptoms, during the first 3–8 days following SEMIGLUE-PAE. All PES cases resolved completely with the standard oral antibiotic and analgesic treatment (ciprofloxacin and ibuprofen) that was routinely prescribed for one week post SEMIGLUE-PAE. PES events were registered separately from the other complications. Four out of 20 patients (20%) experienced minor

complications: There were two grade I complications (urinary incontinence for 1.5–2 weeks, $n = 2$) and two grade II complications (acute urinary retention managed with bladder catheter for 5–7 days, $n = 2$). No major complications were encountered. No (intraprocedural or very early post-procedural) complications were detected in the three excluded patients during their short hospital stay.

Table 2. Values of imaging and clinical parameters at short-term follow up after "SEMIGLUE" PAE and relevant improvement.

Variable	Value (Mean ± SD)	Improvement	95% Confidence Interval [b]	*p*-Value [c]
pPI [a] (%)	45.7 ± 16.5		-	
PV (ml)	62.1 ± 30.3	32.4%	22.5–37.5	<0.01
PVR * (ml)	77 ± 44	61.7%	62–177	0.01
IPSS *	9.3 ± 4.4	61.2%	11.3–18.1	<0.01
QoL	2 ± 1.1	56.5%	2–3.2	<0.01

pPI: Percentage of prostatic infarction = volume of infarcts/total volume of prostate (infarcts were evaluated with contrast-enhanced ultrasound); SD: standard deviation; PV: prostate volume; PVR: post void residual; IPSS: international prostate symptom score; QoL: quality of life. [a]: pPI was calculated on the first day post PAE; all other variables were calculated approximately 3 months post PAE and compared with respective baseline measurements. [b]: The confidence intervals refer to absolute changes (not percentages) of the respective variables. [c]: Statistical significance was evaluated after comparison with baseline measurements. Wilcoxon Signed-Rank Test was used for the comparisons. * The values of IPSS and PVR refer only to patients with moderate or severe LUTS ($n = 12$), not to patients with IBC ($n = 8$). The values of the other variables refer to the entire cohort ($n = 20$).

3.3. Imaging Outcomes

Non-enhanced CT (performed immediately post PAE in all 20 patients) showed hyperdensities of varying extents in both prostatic lobes in 18/20 patients (36/38 embolized hemiprostates), indicating intraprostatic retention of the contrast-microspheres mixture. Hyperdensities in only one prostatic lobe were noted in the two patients with unilateral embolization. Areas of dense intraprostatic retention corresponded to ischemic infarcts, as demonstrated by contrast-enhanced ultrasonography (CEUS), which was performed within 24 h post PAE (Figure 3).

The mean percentage of prostatic infarction was 45.7%. In two cases, intraprostatic contrast retention took the form of dense contrast "pooling" in the treated lobe and this finding was associated with persistent enhancement defects on CEUS studies performed in these two patients, at 5 and 7 months post SEMIGLUE-PAE, respectively (Figure 4).

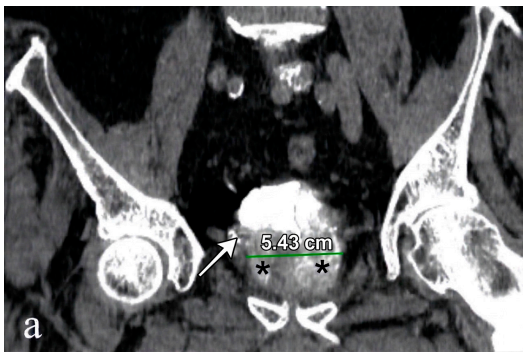

Figure 3. *Cont.*

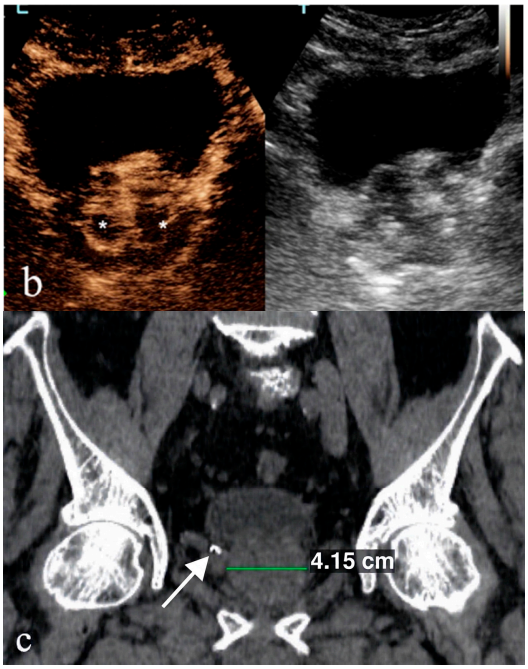

Figure 3. Representative images post SEMIGLUE PAE. Coronal reformatted image from unenhanced CT immediately post procedure (**a**), showing parenchymal hyperdense appearance of both prostatic lobes (*). Filling of the distal extraprostatic part of the right PA with gluelipiodol mixture can also be seen (arrow). Axial dual sonographic image acquired 18 h post PAE (**b**), with reference, gray-scale image on the right and corresponding CEUS image on the left, showing non-enhancing infarcts of both prostatic lobes (*). Coronal reformatted image (**c**) from unenhanced CT performed 3 months post PAE showing prostate shrinkage and resolution of the parenchymal hyperdensities that were noted on CT immediately post PAE. Filling of the distal extraprostatic part of the right PA can still be seen (arrow).

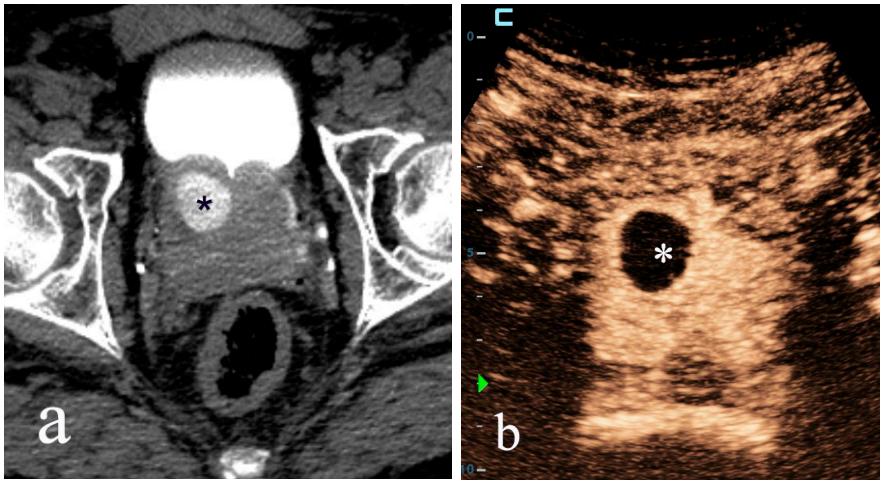

Figure 4. Representative images from a case of SEMIGLUE PAE with persistent infarction. Unenhanced CT image immediately post PAE (**a**), showing dense contrast pooling (*) in the right hemiprostate. Corresponding contrast-enhanced US image, 5 months post PAE (**b**), showing a persistent enhancement defect at the same area (*).

Non-enhanced CT immediately post PAE also confirmed opacification (with the glue–lipiodol mixture) of the distal extraprostatic part of the embolized PAs in all cases. A limited distribution of glue in few intraprostatic branches was additionally noted in 28/38 embolized hemiprostates. This finding appeared as small linear or branching opacities, almost always at

the periphery of the prostate, as opposed to the more central and amorphous hyperdensities of the contrast-microspheres mixture.

Notably, in two cases of duplicate PA in the same pelvic side, glue injection in the first PA was rapidly followed by a reflux of glue in the second ipsilateral PA. In this way, both PAs of the same side were embolized (the first PA antegradely and the second PA retrogradely) with only one catheterization (Figure 5). Reflux from one PA to the other in these two cases was first identified before embolization, with test contrast injections through the microcatheter; subsequent glue injection was made slowly, under fluoroscopic control and magnification, carefully observing the flow of the liquid embolic. Injection stopped when the distal half of the second PA was retrogradely filled. Table 3 provides additional data regarding the glue–lipiodol embolization of the extraprostatic part of the PAs.

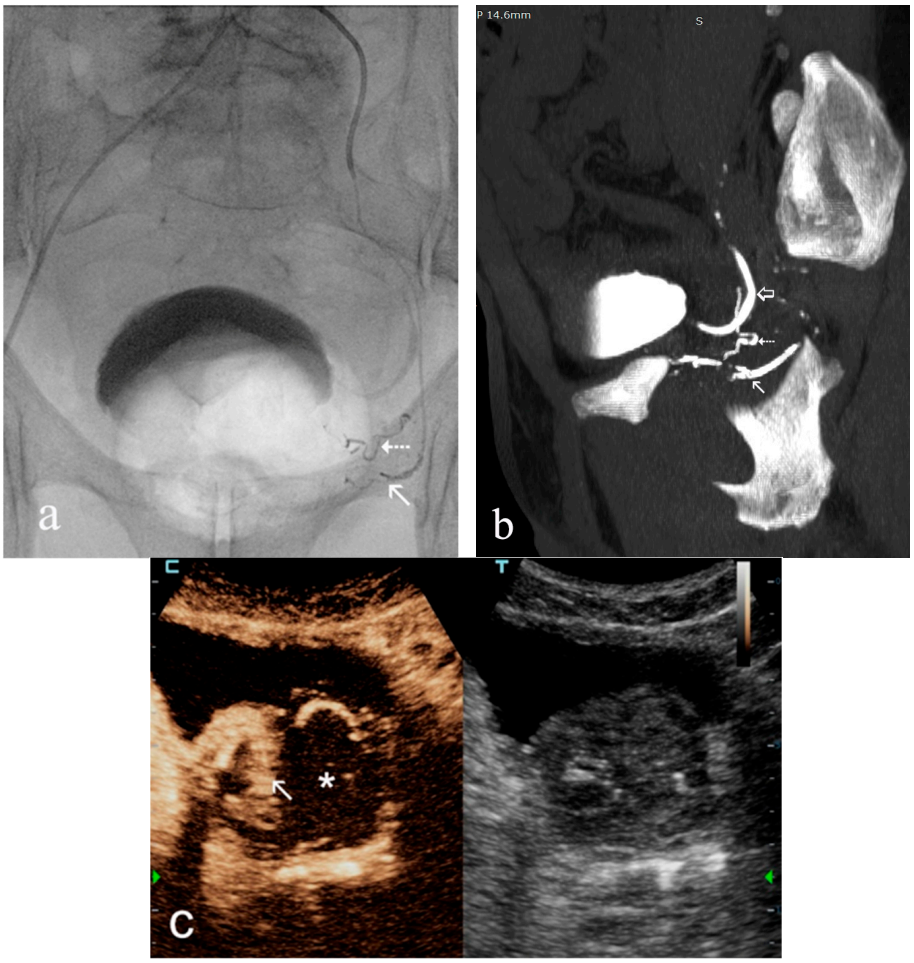

Figure 5. Representative images from a case of SEMIGLUE PAE in duplicate left PA. Fluoroscopic anteroposterior image (**a**) during injection of glue–lipiodol with the microcatheter tip in the distal extraprostatic part of the lower PA (arrow), showing reflux of liquid embolic in the upper PA (dotted arrow) and retrograde filling of this artery. Sagittal oblique reformatted maximum intensity projection image from unenhanced CT immediately post PAE (**b**), showing filling of the large extraprostatic part of both the lower (arrow) and the upper (dotted arrow) left PA with the glue–lipiodol mixture. The opacified left ureter is also shown (open arrow). Axial dual sonographic image acquired 6 h post PAE (**c**), with reference, gray-scale image on the right and corresponding CEUS image on the left, showing almost complete devascularization of the left prostatic lobe (*). Residual enhancement (arrow) of the right prostatic lobe.

Table 3. Technical details relevant to glue–lipiodol embolization of the extraprostatic part of the prostatic arteries (PAs) of this study.

PAs of the Patients of the Study (*n*)	**46**
PAs embolized with glue–lipiodol mixture	42
PAs embolized *ante*gradely	40
PAs embolized *retro*gradely	2
PAs not embolized	4
PAs embolized with blocked-flow technique	5
PAs embolized with free-flow technique (only)	37
PAs embolized with 1–1.5 mL glue–lipiodol mixture	19
PAs embolized with 2–2.5 mL glue–lipiodol mixture	21
PAs embolized with 3–3.5 mL glue–lipiodol mixture	2

Three months post-SEMIGLUE-PAE, all 20 patients underwent follow-up with CT (with additional CTA in 8 patients). CT confirmed the presence of retained glue–lipiodol mixture in all embolized PAs. CTA confirmed occlusion of the distal extraprostatic part of all the studied PAs. Absence of significant enhancement was also observed in the proximal extraprostatic part in the majority of the studied PAs (Table 4, Figure 6).

Table 4. Follow-up imaging findings relevant to glue–lipiodol embolization of the PAs (extraprostatic part) of this study.

Embolized PAs of the Patients in the Study (*n*)	**42**
PAs studied with CT 3 months post PAE	42
PAs with retained glue–lipiodol	42
PAs studied with CTA 3 months post PAE	19
PAs with occlusion of their *distal* part	19
PAs with minimal or no enhancement of their *proximal* part	13
PAs with residual enhancement of their *proximal* part	6

PAs: Prostatic arteries; PAE: prostatic artery embolization; CT: computed tomography; CTA: computed tomography–angiography.

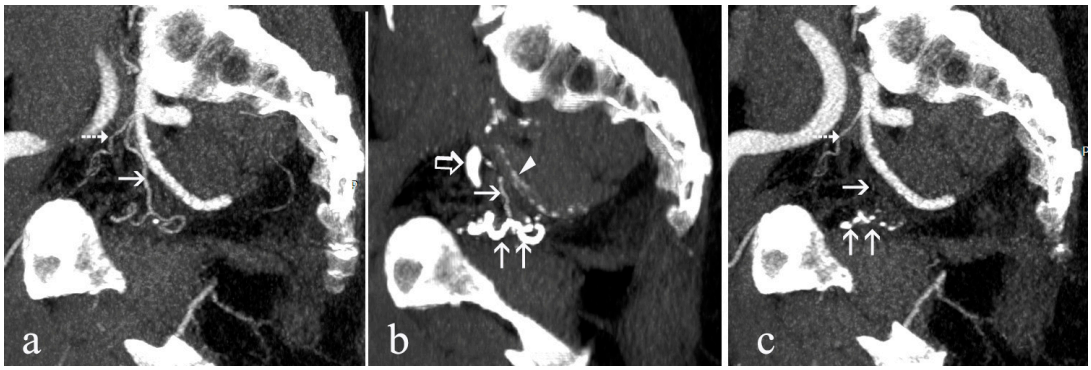

Figure 6. Short-term follow-up of the extraprostatic left PA after SEMIGLUE-PAE. All images are sagittal oblique reformatted maximum intensity projections. CTA prior to intervention (**a**), showing a common origin of superior vesical artery (dotted arrow) and PA (arrow). Unenhanced CT immediately post SEMIGLUE-PAE (**b**), showing filling of the PA (arrow: proximal PA, double arrow: distal PA) with the glue–lipiodol mixture. The opacified ureter (open arrow) and atheromatous calcifications of inferior gluteal artery (arrowhead) are also shown. CTA 3 months post-intervention (**c**), shows persistent filling of the distal PA (double arrow) with glue–lipiodol mixture and absence of enhancement. There is an impression of minimal enhancement in a small proximal segment of the PA (arrow). Normal enhancement of the superior vesical artery (dotted arrow).

4. Discussion

Most researchers agree that the therapeutic mechanisms of PAE are multiple and complex and not limited to ischemic necrosis and prostate debulking [15]. For example, substantial symptomatic relief has been observed post PAE, even in the absence of detectable prostatic infarction on contrast-enhanced MR [16]. Greater infarction volume does not necessarily translate into greater clinical improvement. In fact, very small microspheres (40–120 μm) have been associated with impressive prostatic infarction, but with similar clinical improvement and with more severe ischemic complications, compared to 100–300 μm microspheres [17]. However, despite these concerns, prostatic ischemia is still considered a major part of the therapeutic action of PAE. Several studies indicate that ischemic infarcts, which are demonstrated on contrast-enhanced studies shortly post-PAE can, at least to some extent, predict clinical success and prostate shrinkage [18,19]. The potential of the smaller microspheres (≤300 μm) for deep penetration in the intraprostatic prostatic branches and for induction of extensive ischemia has been repeatedly demonstrated, both with imaging and histologically; there is also relevant clinical evidence [17]. Regarding glue–PAE, the clinical benefits of distal, intraprostatic distribution of glue are less clear [20]. Of course, adequate delivery of a glue–lipiodol mixture in distal parenchymal arteries can be achieved, but most researchers agree that it requires a high level of expertise and/or advanced embolization techniques [2,4]. Moreover, the ischemic effects of glue–PAE on the prostate have not been thoroughly evaluated, although there is evidence that proximal-only glue PAE cannot induce significant prostatic infarction [6].

The extent of prostatic infarction post-SEMIGLUE-PAE (pPI: 45.7% in the present study) appears to be higher compared to PAE with microspheres of the same size (pPI: 30.3%), almost reaching the ischemic effect of smaller (40–120 μm) microspheres (pPI: 48.3%) [17]. Prostate shrinkage 3 months post-SEMIGLUE-PAE was also satisfactory, reaching 32.4%, versus only 11–21% for glue-PAE alone [1] and 28.4% for PAE with microspheres of comparable size [17].

Imaging follow-up in this work relied heavily on CT, thus increasing the patients' cumulative radiation exposure. Thankfully, the Lifetime Attributable Risk for cancer related to abdominopelvic CT is approximately 50% lower for older patients (like PAE candidates) compared to younger ones [21]. CT was performed immediately post PAE for a more detailed study of the distribution of the embolic materials (compared to fluoroscopy). The detection of extraprostatic deposition of the glue–lipiodol mixture, in particular, could facilitate the early diagnosis of ischemic complications related to non-target embolization. An original feature of the present study was the re-evaluation of PA patency 3 months post-SEMIGLUE-PAE in a small subgroup (n = 8) of the treated patients: it was confirmed that occlusion persisted in the distal extraprostatic part in all treated PAs and in the proximal part of most of them. This could be an indication of the efficacy of extraprostatic PA occlusion with glue and probably deserves long-term evaluation in larger patient cohorts.

Clinical outcomes of SEMIGLUE-PAE (with short term improvements in IPSS, QoL and PVR exceeding 55%) are also satisfactory and appear to be comparable to PAE with either glue or microspheres. Notably, in the present study, IPSS reduction reached 14.7 units at 3 months post SEMIGLUE-PAE; corresponding short-term reductions in IPSS post glue–PAE (from experienced operators) and post-microsphere-PAE (with 100–300 μm microspheres) were 10.6–11.3 units and 13.8 units, respectively [1,2,17]. These comparisons, however (as well as those regarding imaging outcomes), should be interpreted with caution, taking into account not only the small sample size of this study, but also differences in patient populations, embolization protocols and imaging methods between different studies.

The approach presented herein requires no advanced maneuvers for distal penetration of the glue; therefore, we hypothesize that it could be suitable for some operators who

have recently incorporated this liquid agent in their PAE practice and are not familiar with such maneuvers. Moreover, after injection of the microspheres, glue may still be capable of reaching some distal branches and anastomoses that have escaped occlusion with microspheres. This is supported by the cases of simultaneous embolization of duplicated ipsilateral PAs after glue injection in only one of them.

In the small group of patients treated with SEMIGLUE-PAE, no major complications were encountered. The authors speculate that the absence of non-target embolization events (caused by reflux of the embolic in non-prostatic branches) could be attributed to (i) the delivery of microspheres mainly in intraprostatic branches and (ii) the administration of small aliquots of glue–lipiodol far from the PA origin. Nevertheless, the small sample size warrants cautious interpretation of these encouraging safety outcomes.

Previous experience with a combination of liquid embolic and microspheres for PAE is very limited. In a study on repeat PAE, ethylene-vinyl alcohol copolymer (EVOH) was injected after 300–500 μm microspheres, and resulted in significant short-term clinical improvement, moderate (11.3%) reduction in PV and one major complication (3.3%) [22]. The comparatively larger size of the microspheres in this study (300–500 μm vs. 100–300 μm in the current study) could have been the cause of the moderate prostate shrinkage. Microspheres and glue were also combined in a small subgroup of patients (n = 9) of a multicenter study, which highlighted the role of PAE in the management of catheter-dependent patients with BPH [23]; however, relevant technical details are not available. In a case report describing PAE in the context of a rare PA variant, NBCA-glue was successfully combined with hydrogel microspheres (250 μm); significant prostate shrinkage (31.4%) and prostatic infarction were evident on magnetic resonance one month post-PAE. Further technical details regarding the combined utilization of the embolic materials from this case are not available either [24]. There is also sparse evidence on the utilization of the "Embosoft" microsphere for PAE. In an earlier comparative study [25], PAE with "Embosoft 300–500" provided significant symptomatic improvement, although it was inferior to open simple prostatectomy in relieving bladder outlet obstruction. Notably, short-term PV reduction (20.9%) in this study was inferior to the result reported herein. Finally, the utilization of Embosoft 100–300 has previously been reported in a salvage case of transradial PAE with rapid control of hematuria of prostatic origin [26].

At least two disadvantages of SEMIGLUE-PAE should be taken into account: First, since it combines two embolic agents, it is associated with higher cost than PAE with either glue, or microspheres. The high cost could hinder the widespread adoption of SEMIGLUE-PAE and cause reimbursement problems. Second, the injection of the embolics requires more time compared to glue–PAE, resulting in increased FT and radiation exposure. FT (41.8 min) in the current series was longer compared to glue–PAE studies (24.9–32.6 min) [1]; the radiation dose of SEMIGLUE-PAE was also higher than previously reported values for glue–PAE [1]. In fact, the herein reported mean DAP (229.9 Gy·cm^2) appears to be exceptionally high, even when compared with some of the highest reported DAP values for glue–PAE (32.5 Gy·cm^2) [27]. The relatively low radiation dose associated with glue–PAE is a significant advantage, especially when younger patients are treated. The mean total procedure time reported herein (96.3 min) is also longer compared to respective values for glue–PAE (80.7–95 min), although the differences are less pronounced compared to the differences in FT.

A major limitation of the present work is that it is a small, single-center study, with only short-term results. Another significant methodological limitation is the absence of a control group, which prevents an objective comparison between SEMIGLUE-PAE and PAE with either NBCA or microspheres. There was also a potential selection bias associated with the inclusion of two groups of SEMIGLUE-PAE candidates (the group with LUTS and the

group with catheter-dependent patients). Some technical aspects (for example, utilization of both blocked-flow and free-flow techniques for glue injection) increased procedural heterogeneity. Some potentially important outcomes were not included in the study; for example, uroflowmetry measurements were not systematically performed, and neither was erectile function evaluated. Finally, there are limitations associated with imaging follow-up: CTA evaluation of the potency of the PA was available for only a small subgroup of patient and limited to only a few months post-PAE. Measurement of prostatic infarction with CEUS could have been inaccurate in cases of multiple irregular necrotic areas, and the reproducibility of the CEUS measurements was not assessed in this study. There is, however, evidence from another study that semiquantitative CEUS measurements of unenhanced areas of the prostate of PAE are highly reproducible [28].

Despite the aforementioned limitations, this study could contribute to personalized medicine (and personalized interventional radiology in particular) by presenting a tailored, sequential embolic protocol that adapts to individual vascular anatomy and operator expertise. By incorporating AI-assisted 3D CT segmentation and early CEUS imaging of prostatic infarction, this work also demonstrates how precision imaging can be used for a more comprehensive evaluation of dedicated interventional techniques.

5. Conclusions

It is recognized that the "SEMIGLUE" approach is not a novel approach, but rather a combination of two established techniques. Initial evidence from this small, uncontrolled study supports the feasibility and satisfactory short-term outcomes of "SEMIGLUE" PAE. The safety and long-term efficacy of this technique, as well as its potential advantages over glue–PAE or microsphere–PAE, deserve further evaluation.

Author Contributions: Conceptualization, H.M. and E.H.; methodology, H.M. and E.H.; software H.M. and E.H.; validation A.H.; Formal analysis, A.M., E.H. and H.M.; investigation, H.M. and E.H.; resources, K.S. and M.I.; data curation, E.H. and M.-T.M.; writing—original draft preparation, H.M.; writing—review and editing, H.M. and E.H.; supervision, H.M.; visualization, E.H., D.K. and M.-T.M.; Supervision, H.M.; project administration, H.M.; graphical abstract, E.H. and M.-T.M.; funding acquisition. All authors have read and agreed to the published version of the manuscript.

Funding: This research received no external funding.

Institutional Review Board Statement: This study was conducted in accordance with the Declaration of Helsinki and approved by the Institutional Review Board of G.H.P.T. (General Hospital of Piraeus, "Tzanio"), protocol code NO. 5, approved on 24 February 2026.

Informed Consent Statement: Informed consent was obtained from all subjects involved in this study. Written informed consent has been obtained from the patients to publish this paper.

Data Availability Statement: The data presented in this study are available from the corresponding author on request.

Acknowledgments: The authors are grateful to Konstantinos Chouchos for his assistance in the preparation of the manuscript: Konstantinos Chouchos, Electronics Engineering with Medical Electronics, Department of Diagnostic, Interventional Radiology, School of Medicine, Democritus University of Thrace. During the preparation of this manuscript, the authors used OpenAI ChatGPT-6 to assist with the visual presentation and layout of the graphical abstract. The Step 1 and Step 2 illustrations were drawn by the authors. All scientific content and data were provided and verified by the authors. The authors reviewed and edited the output and take full responsibility for the content of this publication.

Conflicts of Interest: The authors declare no conflicts of interest.

Abbreviations

The following abbreviations are used in this manuscript:

PAE	Prostatic Artery Embolization
PA	Prostatic Artery
NBCA	n-Butyl Cyanoacrylate
BPH	Benign Prostatic Hyperplasia
SEMIGLUE—PAE	SEquential utilization of MIcrospheres and GLUE for PAE
QoL	Quality of Life
IPSS	International Prostate Symptom Score
PV	Prostate Volume
CT	Computed Tomography
CTA	CT angiography
CEUS	Contrast-Enhanced Ultrasound
pPI	Prostatic Infarction
PVR	Post-Void residual

References

1. Mohamed, N.S.A.; El Khatib, E.; Justaniah, A.I.; Fouad, M.E.M.; Loffroy, R. N-Butyl Cyanoacrylate Glue Application in Prostate Artery Embolization for Benign Prostatic Hyperplasia: A Systematic Review of Safety and Efficacy. *CVIR Endovasc.* **2025**, *8*, 98. [CrossRef]
2. Loffroy, R.; Quirantes, A.; Tomassoni, M.T.; Fouad, M.; Comby, P.-O.; Aho-Glélé, L.S.; Chevallier, O. One-Year Outcomes of Glue Prostate-Artery-Embolization for Symptomatic Benign Prostatic Hyperplasia: A Single-Center Retrospective Cohort Study. *Eur. Radiol.* **2025**, *36*, 2317–2328. [CrossRef]
3. Salet, E.; Crombé, A.; Grenier, N.; Marcelin, C.; Lebras, Y.; Jambon, E.; Coussy, A.; Cornelis, F.H.; Petitpierre, F. Prostatic Artery Embolization for Benign Prostatic Obstruction: Single-Centre Retrospective Study Comparing Microspheres Versus n-Butyl Cyanoacrylate. *Cardiovasc. Interv. Radiol.* **2022**, *45*, 814–823. [CrossRef]
4. Vizzuso, A.; Spina, A.; Bazzocchi, M.V.; Giampalma, E.; Renzulli, M. Safe Prostatic Artery Embolization with Cyanoacrylate: Representative Cases Demonstrating Non-Target Artery Preservation. *Diagnostics* **2026**, *16*, 1785. [CrossRef]
5. Comby, P.O.; Guillen, K.; Chevallier, O.; Lenfant, M.; Pellegrinelli, J.; Falvo, N.; Midulla, M.; Loffroy, R. Endovascular Use of Cyanoacrylate-Lipiodol Mixture for Peripheral Embolization: Properties, Techniques, Pitfalls, and Applications. *J. Clin. Med.* **2021**, *10*, 4320. [CrossRef]
6. Moschouris, H.; Şentürk, Ç.; Stamatiou, K. Commentary on "Glue Penetration Index Score for Use During Glue Prostate Artery Embolization". *Cardiovasc. Interv. Radiol.* **2025**, *49*, 458–459. [CrossRef]
7. Kim, H.C.; Miyayama, S.; Choi, J.W.; Kim, D.H.; Lee, M.; Hur, S.; Jae, H.J.; Chung, J.W. Embolization with N-Butyl Cyanoacrylate: Properties, Techniques, Applications, and Pitfalls. *Radiographics* **2026**, *46*, e250122. [CrossRef]
8. Cornelis, F.H.; Bilhim, T.; Hacking, N.; Sapoval, M.; Tapping, C.R.; Carnevale, F.C. CIRSE Standards of Practice on Prostatic Artery Embolisation. *Cardiovasc. Interv. Radiol.* **2020**, *43*, 176–185. [CrossRef]
9. Fedorov, A.; Beichel, R.; Kalpathy-Cramer, J.; Finet, J.; Fillion-Robin, J.-C.; Pujol, S.; Bauer, C.; Jennings, D.; Fennessy, F.; Sonka, M.; et al. 3D Slicer as an Image Computing Platform for the Quantitative Imaging Network. *Magn. Reson. Imaging* **2012**, *30*, 1323–1341. [CrossRef]
10. Isensee, F.; Rokuss, M.; Krämer, L.; Dinkelacker, S.; Ravindran, A.; Stritzke, F.; Hamm, B.; Wald, T.; Langenberg, M.; Ulrich, C.; et al. nnInteractive: Redefining 3D Promptable Segmentation. *arXiv* **2025**, arXiv:2503.08373.
11. de Vente, C.; Venkadesh, K.V.; van Ginneken, B.; Sánchez, C.I. SlicerNNInteractive: A 3D Slicer Extension for nnInteractive. *arXiv* **2025**, arXiv:2504.07991.
12. Majbar, E.; Swanberg, J.; Alamdari, F.; Peeker, R.; Chabok, A. Early experience of prostate artery embolization: A retrospective single-centre study. *Scand. J. Urol.* **2025**, *60*, 1–7. [CrossRef]
13. Moreira, A.M.; De Assis, A.M.; Carnevale, F.C.; Antunes, A.A.; Srougi, M.; Cerri, G.G. A Review of Adverse Events Related to Prostatic Artery Embolization for Treatment of Bladder Outlet Obstruction Due to BPH. *Cardiovasc. Interv. Radiol.* **2017**, *40*, 1490–1500. [CrossRef]
14. Moschouris, H.; Stamatiou, K.; Malagari, K.; Marmaridou, K.; Kladis-Kalentzis, K.; Kiltenis, M.; Papadogeorgopoulos, N.; Tsavari, A.; Manoloudaki, K. The Value of Contrast-Enhanced Ultrasonography in Detection of Prostatic Infarction after Prostatic Artery Embolization for the Treatment of Symptomatic Benign Prostatic Hyperplasia. *Diagn. Interv. Radiol.* **2019**, *25*, 134–143. [CrossRef]
15. Sun, F.; Crisóstomo, V.; Báez-Díaz, C.; Sánchez, F.M. Prostatic Artery Embolization (PAE) for Symptomatic Benign Prostatic Hyperplasia (BPH): Part 2, Insights into the Technical Rationale. *Cardiovasc. Interv. Radiol.* **2016**, *39*, 161–169. [CrossRef]

16. Frenk, N.E.; Baroni, R.H.; Carnevale, F.C.; Gonçalves, O.M.; Antunes, A.A.; Srougi, M.; Cerri, G.G. MRI findings after prostatic artery embolization for treatment of benign hyperplasia. *AJR Am. J. Roentgenol.* **2014**, *203*, 813–821. [CrossRef]
17. Moschouris, H.; Şentürk, Ç.; Stamatiou, K.; Mouroukis, A.; Stylianou, C.; Kontothanasis, D. Single-Center Retrospective Comparative Study of 40–120 Mm versus 100–300 Mm Trisacryl Gelatin Microspheres as the Main Embolic Agents for Prostatic Artery Embolization. *Diagn. Interv. Radiol.* **2026**, *32*, 700–708. [CrossRef]
18. von Stempel, C.; Tzelves, L.; Khangura, S.; Kilic, Y.; Walkden, M.; Al-Nowfal, A.; Munneke, G.; Hines, J.; Mazzon, G.; Tandoğdu, Z. Three-Month Magnetic Resonance Imaging Post-Prostate Artery Embolization Predicts 1-Year Clinical Outcomes. *Cardiovasc. Interv. Radiol.* **2026**, *49*, 370–379. [CrossRef]
19. Sun, F.; Lucas-Cava, V.; Sánchez-Margallo, F.M. Clinical Predictive Factors in Prostatic Artery Embolization for Symptomatic Benign Prostatic Hyperplasia: A Comprehensive Review. *Transl. Androl. Urol.* **2020**, *9*, 1754–1768. [CrossRef]
20. Von Stempel, C.; Vigneswaran, G.; Little, M.; Quirantes, A.; Al-Nowfal, A.; Patel, S.; Beckett, D.; Loffroy, R.; Bent, C. Glue Penetration Index Score for Use during Glue Prostate Artery Embolization. *Cardiovasc. Interv. Radiol.* **2025**, *48*, 1355–1360. [CrossRef]
21. Smith-Bindman, R.; Lipson, J.; Marcus, R.; Kim, K.P.; Mahesh, M.; Gould, R.; Berrington de González, A.; Miglioretti, D.L. Radiation Dose Associated with Common Computed Tomography Examinations and the Associated Lifetime Attributable Risk of Cancer. *Arch. Intern. Med.* **2009**, *169*, 2078–2086. [CrossRef]
22. Guerra, X.; Sapoval, M.; Querub, C.; Al Ahmar, M.; Di Gaeta, A.; Dean, C.; Pellerin, O.; Boeken, T. Repeat Prostatic Artery Embolization with the Addition of a Liquid Embolic Agent: Short-Term Results. *Acad. Radiol.* **2024**, *31*, 1959–1967. [CrossRef]
23. Pouchot, J.; Crombé, A.; Burlet, L.; Farah, F.; Baseilhac, P.; David, A.; Petitpierre, F.; Maaloum, R.; Le Bras, Y.; Pagnoux, G.; et al. Safety and Clinical Efficacy of Prostatic Artery Embolization in Patients with Indwelling Urinary Catheter for Benign Hyperplasia—A Multicenter Study. *Diagnostics* **2024**, *14*, 2864. [CrossRef]
24. Tran, D.K.; Nguyen, T.A.; Tran, T.T.T.; Le, H.D.; Le, T.D.; Than, V.S. Prostatic Artery Embolization in a Rare Anatomical Variant Arising from the Superior Rectal Artery: Case Report. *J. Korean Soc. Radiol.* **2026**, *87*, 152. [CrossRef]
25. Lebani, B.R.; Porto, D.D.D.S.; Silva, A.B.D.; Girotti, M.E.; Pinto, E.R.; Skaff, M.; Szejnfeld, D.; Almeida, F.G.D. Randomized Controlled Trial Comparing Open Simple Prostatectomy or Prostate Artery Embolization in Large Prostates: Clinical and Urodynamic Assessment—PoPAE Study. *Urology* **2024**, *189*, 94–100. [CrossRef]
26. Moschouris, H.; Tsetsou, I.; Kaniaris, A.; Stamatiou, K. Transradial Prostatic Artery Embolization as a Salvage Procedure in a Patient With Severe Deformities and Refractory Hematuria of Prostatic Origin. *Cureus* **2024**, *16*, e59894. [CrossRef]
27. Loffroy, R.; Quirantes, A.; Guillen, K.; Mazit, A.; Comby, P.O.; Aho-Glélé, L.S.; Chevallier, O. Prostate Artery Embolization using n-Butyl Cyanoacrylate Glue for Symptomatic Benign Prostatic Hyperplasia: A Six-Month Outcome Analysis in 103 Patients. *Diagn. Interv. Imaging* **2024**, *105*, 129–136. [CrossRef]
28. Barat, M.; Boeken, T.; Moussa, N.; Di Gaeta, A.; Déan, C.; Thioun, N.; Del Giudice, C.; Pellerin, O.; Sapoval, M. Contrast-Enhanced Ultrasonography for the Early Evaluation of Prostate Artery Embolization. *Cardiovasc. Interv. Radiol.* **2020**, *43*, 1498–1504. [CrossRef]

Disclaimer/Publisher's Note: The statements, opinions and data contained in all publications are solely those of the individual author(s) and contributor(s) and not of MDPI and/or the editor(s). MDPI and/or the editor(s) disclaim responsibility for any injury to people or property resulting from any ideas, methods, instructions or products referred to in the content.