diagnostics

Correction

Correction: Edris et al. Temporal Bone Fractures on High-Resolution CT: Bridging Radiologic Detail with Otologic Anatomy and Surgical Implications. *Diagnostics* 2026, *16*, 718

Osama M. K. Edris [1], Abdulgaffar Bashir Adam [2], Emad Ali Albadawi [3], Ahmad Mahroos ALGhabban [4], Razan Saad M. Alqarni [3], Wejdan Hussain Owaydhah [3], Omar A. Alharthi [4], Eyad Khattab [5], Fahd Alharbi [6] and Yasir Hassan Elhassan [3,*]

1 Department of Otolaryngology, Faculty of Medicine, University of Khartoum, Khartoum 11115, Sudan; osamamk@yahoo.com
2 Khartoum ENT Teaching Hospital, Khartoum 11112, Sudan
3 Department of Basic Medical Sciences, College of Medicine, Taibah University, Madinah 42353, Saudi Arabia
4 Department of Internal Medicine, College of Medicine, Taibah University, Madinah 42353, Saudi Arabia
5 Department of Emergency Medicine, King Saud University Medical City, Riyadh 42353, Saudi Arabia
6 Department of General and Specialized Surgery, College of Medicine, Taibah University, Madinah 42353, Saudi Arabia
* Correspondence: yasiranatomy2@hotmail.com

In the original publication [1], there is an error in Figure 1. Figure 1 had an incorrect temporal bone with a mislabeled "Tympanic part" and wrong coloring. The corrected Figure 1 appears below. The authors state that the scientific conclusions are unaffected. This correction was approved by the Academic Editor. The original publication has also been updated.

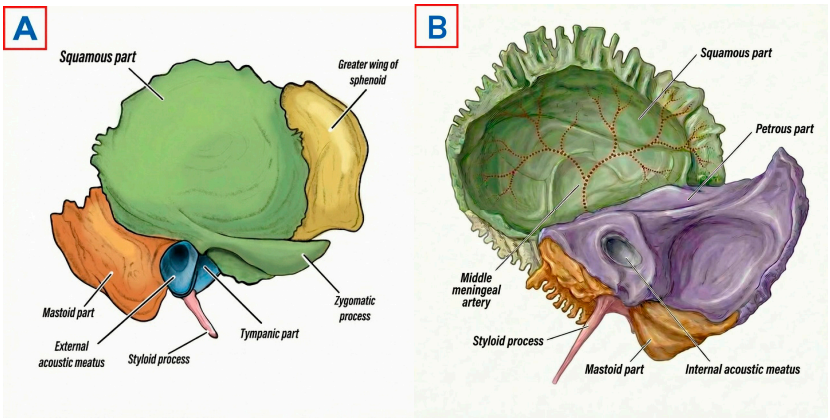

Figure 1. Anatomy of the right temporal bone. (**A**) Lateral external (otologic) surface. (**B**) Medial intracranial surface.

Reference

1. Edris, O.M.K.; Adam, A.B.; Albadawi, E.A.; ALGhabban, A.M.; Alqarni, R.S.M.; Owaydhah, W.H.; Alharthi, O.A.; Khattab, E.; Alharbi, F.; Elhassan, Y.H. Temporal Bone Fractures on High-Resolution CT: Bridging Radiologic Detail with Otologic Anatomy and Surgical Implications. *Diagnostics* **2026**, *16*, 718. [CrossRef] [PubMed]

Check for updates

Received: 21 April 2026
Accepted: 23 April 2026
Published: 6 May 2026

Copyright: © 2026 by the authors. Licensee MDPI, Basel, Switzerland. This article is an open access article distributed under the terms and conditions of the Creative Commons Attribution (CC BY) license.

Disclaimer/Publisher's Note: The statements, opinions and data contained in all publications are solely those of the individual author(s) and contributor(s) and not of MDPI and/or the editor(s). MDPI and/or the editor(s) disclaim responsibility for any injury to people or property resulting from any ideas, methods, instructions or products referred to in the content.