symmetry

MDPI

*Article*

# Evaluation of Mandibular Growth and Symmetry in Child with Congenital Zygomatic-Coronoid Ankylosis

**Anna Lipowicz [1], Wojciech Wolański [2,*], Edyta Kawlewska [2], Patrycja Zwolska [3], Małgorzata Kulesa-Mrowiecka [4], Krzysztof Dowgierd [5], Paweł Linek [6] and Andrzej Myśliwiec [6,7]**

1 Department of Anthropology, Institute of Environmental Biology, Wroclaw University of Environmental and Life Sciences, 50-375 Wroclaw, Poland; anna.lipowicz@upwr.edu.pl
2 Department of Biomechatronics, Faculty of Biomedical Engineering, Silesian University of Technology, 41-800 Zabrze, Poland; edyta.kawlewska@polsl.pl
3 Aesthetical Dentistry Center "Studio Dentico", 44-237 Stanowice, Poland; stomatolog@studiodentico.pl
4 Department of Physiotherapy, Institute of Physiotherapy, Faculty of Health Sciences, Jagiellonian University Medical College, 31-008 Cracow, Poland; m.kulesa-mrowiecka@uj.edu.pl
5 Head and Neck Surgery Clinic for Children and Young Adults, Department of Clinical Pediatrics, University of Warmia and Mazury, 10-561 Olsztyn, Poland; krzysztofdowgierd@wssd.olsztyn.pl
6 Institute of Physiotherapy and Health Sciences, Academy of Physical Education, 40-065 Katowice, Poland; linek.fizjoterapia@vp.pl (P.L.); a.mysliwiec@awf.katowice.pl (A.M.)
7 Specialized Physiotherapy Center, 44-270 Rybnik, Poland
* Correspondence: wojciech.wolanski@polsl.pl

**Abstract:** Ankyloses in the area of the temporomandibular joint (TMJ) are mentioned as a potential etiological factor of mandibular growth disorders and facial asymmetry. The aim of this case study was to evaluate the changes in the mandible of a child with zygomatic-coronoid ankylosis during the first five years of life, in which two adhesion release procedures were performed. The adopted symmetrical approach is based on the assumption of symmetry of the structure of the stomatognathic system in relation to the sagittal median plane. However, the assessment of pathological changes in the structure of the skeletal system was performed using an asymmetrical approach. Computed tomography techniques and a system of computer-aided diagnosis (CAD) were used in the case study. During the child's growth, linear and angular measurements were made thrice (at the age of 16, 25 and 54 months). The degree of asymmetry was estimated in the measurements made on the right and left sides of the three-dimensional mandible. Unilateral congenital hypoplasia of the articular process and zygomatic-coronoid adhesion caused asymmetrical growth of the mandible in the child along with shortening of the mandibular branch and body on the damaged side and a visible difference in the size of the mandibular angles. Removal of the adhesions during surgical procedures made it possible to reduce the asymmetry of the mandible and catch-up growth, although at the age of five, the mandible was still smaller than the mandible in healthy peers. It was shown that the early adhesion release procedures supported by the CAD analysis enabled the restoration of mandibular symmetry.

**Keywords:** anthropometry; human growth; temporomandibular joint; cranio-maxillofacial surgery; physiotherapy; computer-aided diagnosis; asymmetry

check for updates

**Citation:** Lipowicz, A.; Wolański, W.; Kawlewska, E.; Zwolska, P.; Kulesa-Mrowiecka, M.; Dowgierd, K.; Linek, P.; Myśliwiec, A. Evaluation of Mandibular Growth and Symmetry in Child with Congenital Zygomatic-Coronoid Ankylosis. *Symmetry* **2021**, *13*, 1634. https://doi.org/10.3390/sym13091634

Academic Editor: Chiarella Sforza

Received: 16 July 2021
Accepted: 2 September 2021
Published: 5 September 2021

**Publisher's Note:** MDPI stays neutral with regard to jurisdictional claims in published maps and institutional affiliations.

**Copyright:** © 2021 by the authors. Licensee MDPI, Basel, Switzerland. This article is an open access article distributed under the terms and conditions of the Creative Commons Attribution (CC BY) license (https://creativecommons.org/licenses/by/4.0/).

## 1. Introduction

Bilateral symmetry never occurs in people's faces, despite the fact that the right and left hemifaces are built from the same structures and aim to achieve symmetry in their development. Widespread slight asymmetry of the face (the so-called relative symmetry, subclinical asymmetry or normal asymmetry) is most often imperceptible to the surrounding people; it does not hinder functioning, nor does it pose an aesthetic problem [1].Only differences of at least two millimeters in the dimensions between the right and left side of the facial skeleton are of clinical significance [2,3].

However, various aspects, such as pathological, traumatic, functional or developmental factors, may disturb the growth process of the facial skeleton, causing greater asymmetries [4]. Among many reasons for the facial asymmetry, scientists also name the uneven development of the mandible during human ontogenesis [1,5]. Disturbed development of the child's mandible often results in growth compensation in contralateral sides, thus increasing differences in the measurements between the sides. The mandible's asymmetry may manifest itself in all three dimensions and angles. It may include the mandibular body (curved and horizontally placed part), two rami which project perpendicularly upwards from the angle of the mandible) and two condyles (that articulate with the skull) (Figure 1a). Most studies of the asymmetry of the skull and face highlight greater values of the bone measurements on the right hemiface than those on the left [6,7]. This fact is explained, among other things, by a dominant growth potential of the skull and brain on the right side of the face or a greater expression of emotions on the left side of the face [8]. It has been also speculated that neural crest cell migration during fetal growth happens earlier on the right side and tends to be delayed on the left side [9,10].

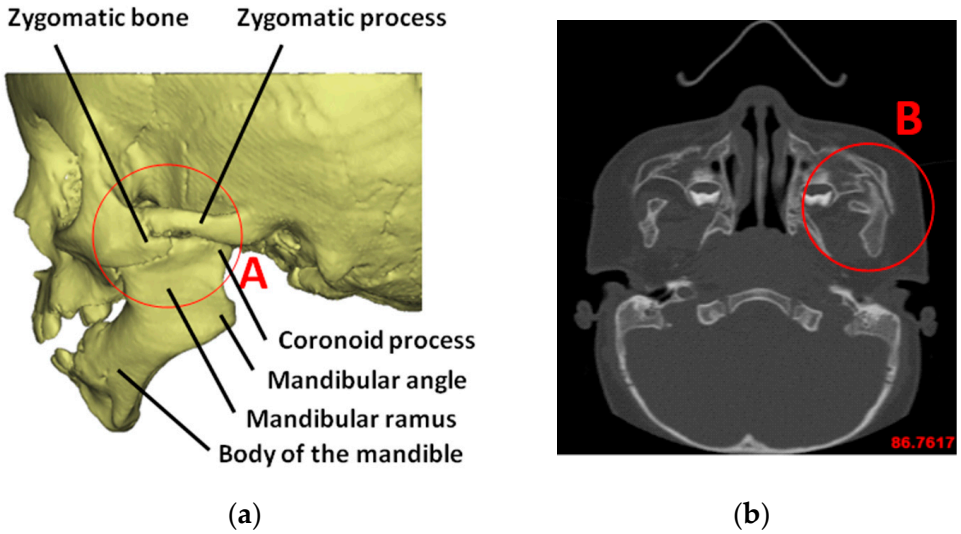


**Figure 1.** The images of the childat 16 months: (**a**) 3D reconstructions of the maxillofacial region with marked syngnathia—A; (**b**) maxillofacial CT scan with marked syngnathia—B.

Despite the dominance of genetic factors, the mandible's development is sensitive to the influence of modifying environmental factors [11,12], such as diet, functioning/loads exerted on the stomatognathic system, size and type of occlusion, work of muscles and muscular tone (including masseter muscles, suprahyoid and infrahyoid muscles, temporal and pterygoid muscles). The most significant factors modifying the development of the stomatognathic system are pathological conditions and dysfunctions of the masticatory organ. These refer to clinical multi-cause disorders in the morphological and functional system, including tissues and organs within the oral cavity and the facial skeleton (bones and soft tissues, cartilaginous joints). Therefore, the disorders in the area of the temporomandibular joint (TMJ), ankyloses of various origin, occlusion disorders, hyperplasia or hypoplasia of condylar processes of the mandible, cysts and tumors may change the course of the mandible's development [5,13,14]. In addition, the proper growth in the posterior direction [15] and the resistance to compressive forces [16] may be disturbed by some disorders.

Ankylosis of the TMJ is a fibrous adhesion or bony fusion resulting either in the limitation of the mobility or full immobility of the mandible joint. In most cases, TMJ ankylosis is a complication resulting from trauma of various origins, sustained at different ages. Ankylosis may affect a joint (the so-called true ankylosis—intra-articular ankylosis), be located outside the joint (apparent ankylosis) or adopt a mixed form. It may also be complete or incomplete. An example of apparent ankylosis located outside the TMJ is

a bony or fibrous fusion between the coronoid process and zygomatic bone (zygomatic-coronoid ankylosis) usually resulting from the trauma (fractures) of the maxillofacial part, hyperplasia of the coronoid process, inflammatory conditions or complications after surgical procedures. In very rare cases, it can be congenital, i.e., present from birth [17,18]. The etiology of true congenital ankylosis TMJ is controversial, as some authors [19] link it to obstetric trauma causing an inflammatory focus with bleeding into the joint cavity or abnormal prenatal development [20]. The exact pathogenesis of congenital ankylosis is unknown. Various hypotheses proposed include anomalies of the embryonic mesenchyme junction in early development during embryogenesis, abnormalities of the fetal stapedial artery, hypervitaminosis A and early loss of neural crest cells. Furthermore, ankylosis of the TMJ has been reported to co-occur in some congenital malformations associated with abnormalities in the differentiation of the first and second branchial arches in early fetal development, such as Treacher Collins syndrome and Nager syndrome [21].

By comparison with adults, TMJ ankylosis in children leads to more acute disorders of the mandible's development [22]. In unilateral TMJ ankylosis, there is a clear asymmetry of the face and deformations in the facial area [23]. Release of the adhesion makes it possible to start the rebuilding of the mandible [24]. In the treatment of patients with TMJ ankylosis, special attention is paid to the adhesion region (condylar and coronoid processes, joints surfaces) as well as the restoration of functions connected toingesting and grinding of food as well as breathing and speaking. There are very few studies presenting changes that occur in the mandibles of children with congenital defects of the TMJs [25–27].

The above-mentioned studies encompass mainly the assessment of the effects after surgical procedures and physiotherapy (improvement and maintaining of the maximal incisal opening). However, these works do not include the description of or the changes in the mandible's development. It seems that in the case of congenital ankyloses, it is important to observe the changes in the measurements, proportions and asymmetry degree of the mandible, because the above-mentioned factors may influence the choice of treatment or the modification of therapeutic methods, for instance, by taking into consideration orthodontic treatment. Therefore, the main aim of this case study was to present the description of the changes in size and proportions of the female patient's mandible, occurring over a period of several years, during which two surgical procedures of the removal of zygomatic-coronoid ankylosis were performed [28]. Additionally, the comparison of the obtained measurements with the reference data available in the literature and the analysis of the asymmetry within the mandible were done.

## 2. Materials and Methods

### *2.1. Case Study: Patient Information*

The report presents observations of the changes in size and proportions of the patient's mandible over several years, during which two surgical procedures of the removal of zygomatic-coronoid ankylosis were performed. It involves a child of the female gender who was born in 2015 at a Silesian hospital in Poland. The child was born from a second pregnancy. Delivery was at term, uncomplicated. There were no confirmed developmental bone defects or masticatory organ dysfunctions in the child's family in the past. At birth, congenital ankylosis of the TMJ area was diagnosed on the left side [28]. Genetic mapping was not performed for the considered clinical case to rule out a concomitant first-second branchial arch syndrome. Integrated medical care by specialists in different fields was recommended. The first orthodontic consultation confirmed limited lowering of the child's mandible and a larger oral fissure on the right side than that on the left. The child had an active sucking reflex, however, there was a lack of the tongue extrusion between the upper and lower alveolar ridge. The lower part of the left auricle was smaller than that on the right side. That image was initially described as partial underdevelopment of the face. As a result of further examinations using computed tomography (CT), the defect was defined as congenital zygomatic-coronoid ankylosis, consisting in the adhesion of the coronoid process and zygomatic arch on the left side of the face (Figure 1b).

Two osteotomies were performed to remove the bone fusion between the zygomatic bone shaft and the coronoid process of the mandible [28]. A detailed scheme of the procedure steps is presented in Figure 2. On the 21st day after the first surgical procedure (at 18 months), therapeutic procedures began, however, they did not bring the expected result— a late start of physiotherapy did not prevent the re-ankylosis which impaired mandibular movements. The abduction of the mandible up to 4 mm was achieved, but no protrusion and laterotrusion movement was found. The second surgical procedure removed the re-ankylotic adhesion (at 37 months), and therapeutic exercises began on the second day after the operation (Figure 2). The immediate physiotherapeutic activity made it possible to maintain the opening of the jaws at a level of 16 mm in the 12th month after the second surgical procedure. A detailed description of the treatment is placed elsewhere [28]. At the age of 5 years and 2 months, the patient had her biological age evaluated using the method of dental age estimation according to [29]. On the basis of an X-ray image, it was ascertained that the child had no permanent teeth buds of the second premolars. The obtained result of 44.8 points made it possible to estimate the child's age as 6.5 years old, therefore, the patient's biological age was higher than the metrical age by approximately 1 year and 3 months.

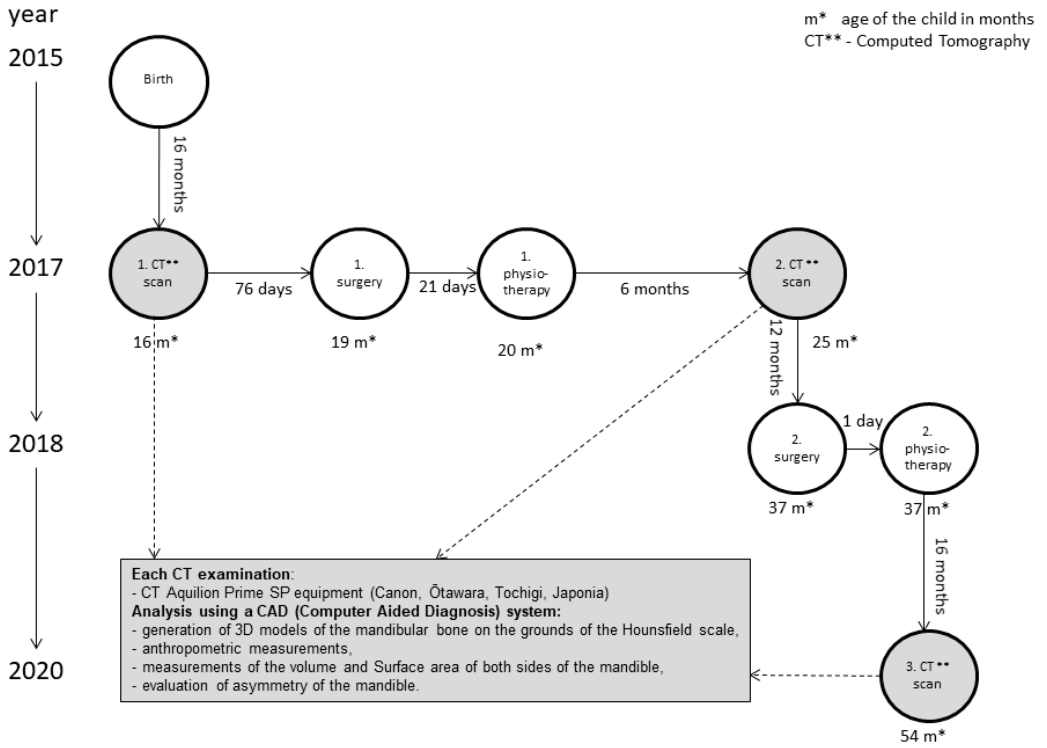


**Figure 2.** A detailed scheme of the treatment during the first 5 years of life (description is given in the text).

### *2.2. Computed Tomography*

Three computed tomography (CT) examinations of the facial skeleton were performed for the analyzed case (Figure 3). All diagnostic CT examinations were conducted in the same Children's Hospital in Poland, using the same equipment, namely CT Aquilion Prime SP (Canon, Ōtawara, Tochigi, Japan), and with the same technician performing the examination. This enabled the obtainment of 2D images of particular sections of the patient's body. The technician performing the tests was not aware of the purpose of this case study.

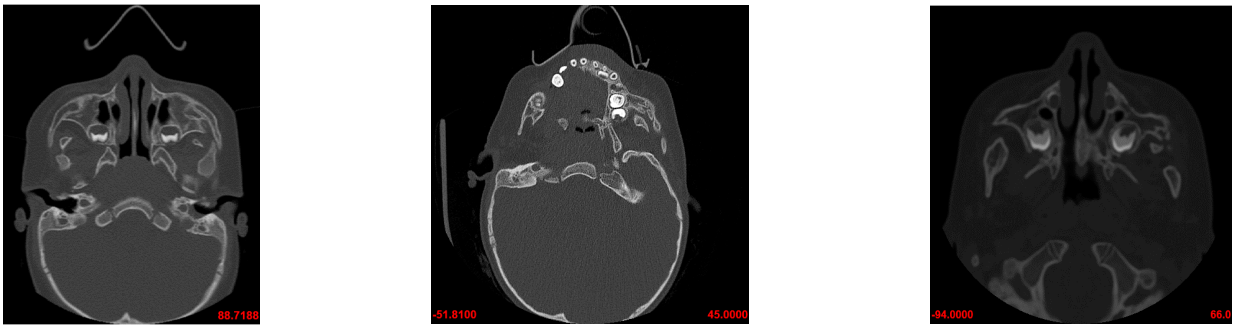

(**a**) (**b**) (**c**)

**Figure 3.** The CT scans of the maxillofacial region at (**a**) 16 months, (**b**) 25 months and (**c**) 54 months.

The first examination (prior to the first surgical procedure) was conducted for diagnostic purposes in 2017, when the child was 16 months old (Figure 3a). Scanning was performed at a resolution of 512 × 512 px, pixel size of 0.326 mm, slide thickness of 1.0 mm. The second CT examination was also performed in 2017 (25th month of life) and was a control examination taking place six months after the first surgical procedure (Figure 3b).The scanning parameters were as follows: resolution: 512 × 512 px, pixel size: 0.377 mm, slide thickness: 0.625 mm. After the second surgical procedure, the third control CT examination was performed in 2020 (at 4 years and 6 months—54 months; Figure 3c).The scanning parameters were as follows: resolution: 512 × 512 px, pixel size: 0.263 mm, slide thickness: 0.5 mm. The obtained data were saved in the DICOM format (Digital Imaging and Communications in Medicine). On the basis of the Hounsfield scale, it was possible to select individual tissues/structures (e.g., bones) and generate 3D models (Figure 4). Taking into account all CT examinations, the researchers performed segmentation of the mandibular bone. Next, anthropometric measurements were carried out. A long-term assessment of the asymmetry of the mandible was conducted using a computer-aided diagnosis system [30]. All analyses of the changes within the mandible were conducted using the symmetrical approach devised by one person. The above-mentioned method is based on the assumption of the symmetry of the skull's build in relation to the median sagittal plane [31]. Mimics v16software was used (Materialise, Leuven, Belgium). The applied approach enabled the determination of linear and angular measurements of three-dimensional objects, such as vertical, median-lateral and anterior-posterior, as well as surface asymmetry index (AI) and volume index. The above-mentioned approach also enabled the comparison of the results obtained in the analyses performed at long intervals. Measurement errors are within the limits of the CT images resolution, whereas the voxel resolution amounts to ±0.5 mm [32].

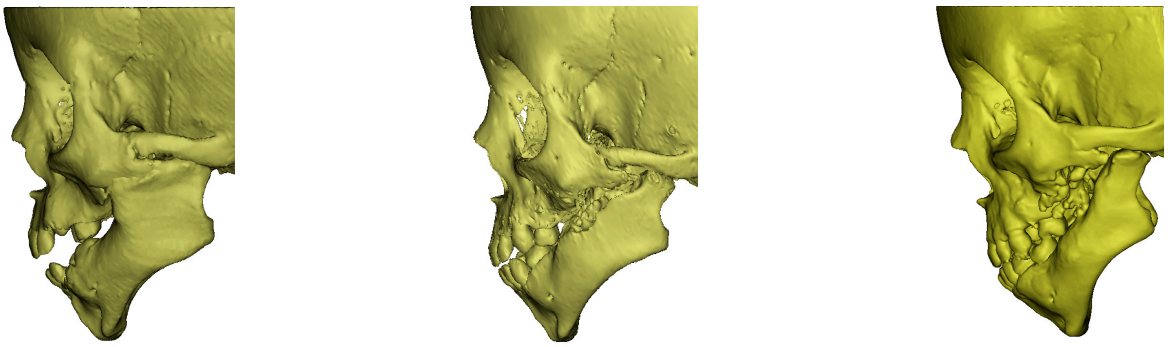

(**a**) (**b**) (**c**)

**Figure 4.** Three-dimensionalreconstructions of the maxillofacial region at (**a**) 16 months, (**b**) 25 months and (**c**) 54 months.

### 2.3. Analysis of 3D Models

Standard anthropometric points in the obtained 3D models of the mandible were designated in accordance with Martin and Saller's methodology [33]. On the basis of the above-mentioned points (Figure 5), the following even and odd measurements were carried out:

- gonionleft–gonion right (go.l–go.r)—bigonial breadth (distance between the right and left gonion points on mandibular angles).
- kondylion laterale left–kondylion laterale right (kdl.l–kdl.r)—bicondylar breadth external (distance between the most right and left lateral points on the condylar processes).
- kondylion mediale left–kondylion mediale right(kdm.l–kdm.r)—bicondylar breadth internal (distance between the right and left medial points on the condylar processes).
- gnathion–gonion (gn–go)—mandibular body length (distance between the most inferior point of the mandible in the midline and the point on the mandibular angle).
- gnathion–kondylion laterale (gn–kdl)—total mandibular length (distance between the most inferior point of the mandible in the midline and the lateral point on the condylar process).
- infradentale–gnathion (gn–id)—height of the mandibular symphysion (distance between the most inferior point of the mandible in the midline and the point of alveolar contact with the lower central incisors).
- gonion–kondylion laterale (go–kdl)—height of ramus (distance between the point on the mandibular angle and the lateral point on the condylar process).
- height of the mandibular body at molar 2 (distance between the lower and upper edges of the mandible perpendicularly passing by M2).
- height of mandibular body at foramen mentale (distance between the lower and upper edges of the mandible perpendicularly passing by the mental foramen).

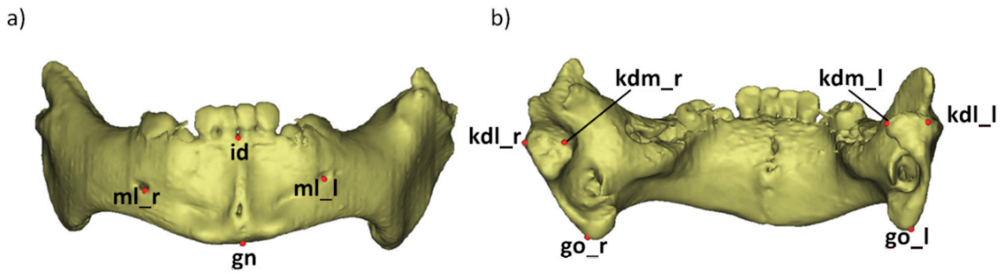


**Figure 5.** Anthropometric points of the mandible: (**a**) anterior view, (**b**) posterior view.

In addition, four angles were measured (Figure 6):

- gonion–gnathion–gonion (go–gn–go), the angle of the mandible,
- gonial angle (alpha),
- mental angle (beta),
- upper mandibular symphysis angle (gamma).

All measurements were conducted on the basis of 3D models of the mandibular bone, which were segmented using the Mimics software. The measurements served the purpose of the determination of indices defining proportions. Moreover, the measurements of the volume and surface area of both (left and right) sides of the mandible were conducted and compared. Each linear dimension obtained for the right and left side had its asymmetry index (AI) assessed by means of the formula proposed by [34]:

$$\mathrm{AI} = \frac{\text{right measurement} - \text{left measurement}}{\text{right measurement} + \text{left measurement}} \times 100$$

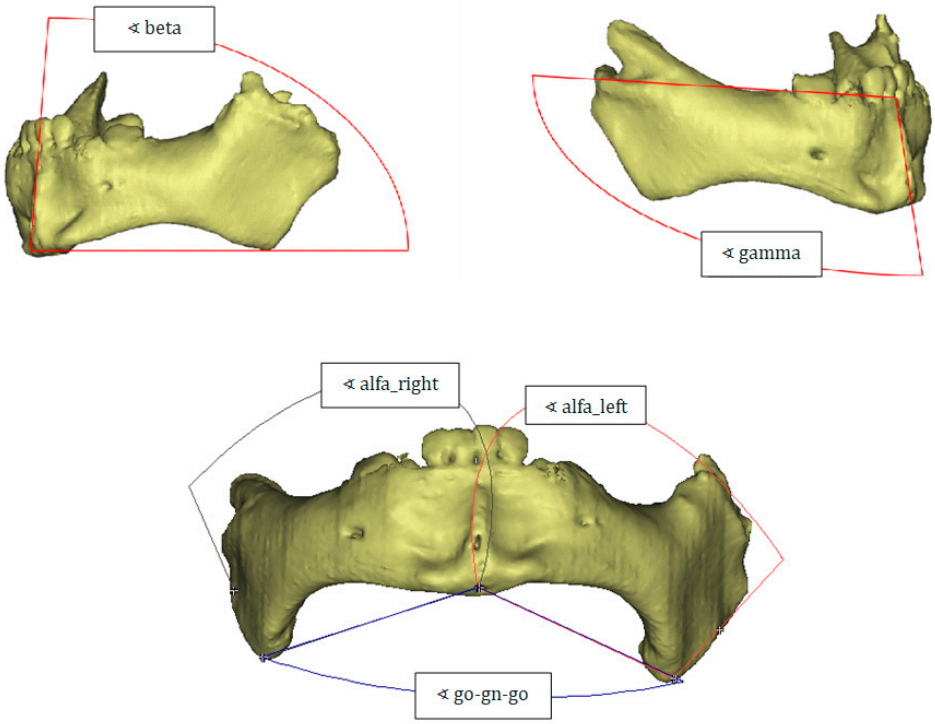


**Figure 6.** Anthropometric angles of the mandible: go.l–gn–go.r—the angle of mandible, alpha—gonial angle, beta—mental angle, gamma—superior mandibular symphysis angle.

The results were obtained as a percentage, where AI equal to 0 indicated that both sides of the mandible were symmetrical, a negative value indicated that the left side was larger than the right, a positive value indicated that the right side was larger than the left. To assess the degree of asymmetry, the following classification was applied: no significant (NS) asymmetry, when AI was between 0 and 2.99 percent; light (L), when AI was between 3 and 5 percent; moderate (M), when the index was greater than 5 percent but less than or equal to 10 percent; and severe (S), when AI was more than 10 percent [3]. Asymmetry in the gonial angle was evaluated by subtracting the value of the left angle from that of the right angle. The intensity of asymmetry was defined as no significant (NS), when the difference between the right and left angle was from 0 to 2.99 degrees; light (L), when the difference between both sides was from 3 to 5 degrees; moderate (M), when the difference was greater than 5 degrees but smaller or equal to 10 degrees; severe (S), when the difference was greater than 10 degrees [3]. To compare our own measurements and indices of the analyzed mandible with the data available in the subject literature, the Authors used the following measurements performed onskeletal remains [35,36] and cephalograms [37].

## 3. Results

The measurements were performed on the basis of three CT scans of the patient—at the first diagnosis (aged 16 months), after the first surgery and physiotherapy (at 25 months) and after the second surgery and physiotherapy (at 54 months). All measured distances and angles are presented in Tables 1 and 2. Calculated ratios indicating the proportions between the mandibular dimensions are shown in Table 3. Measurements, angles and indices are presented in comparison with data for peers of the same age groups [34–36,38]. Table 1 indicates that the dimensions of the described mandible were in most dimensions smaller than the mandibles of children in the corresponding age classes. Moreover, comparison of the values revealed that the mandible resembled in size the mandibles of children at least one year younger. For example, in children aged one, the mandibular body length was 50 mm, and in children aged two, it was 57.2 mm. The patient's mandibleat 16 months at the ankylotic side of the face was 48.6 mm. Table 2 shows that the patient's mandibular angles were also abnormal. Particularly noteworthy is the gonial angle (alpha), which

in the patient was 136–140 degrees on the side with ankylosis during the study period, while it was approximately 128 degrees in the healthy children studied by Liu et al. [39]. Additionally, the comparison of the angles on both sides of the patient's mandible indicated uneven development of both parts of the face (Table 2). In addition to the described direct measurements, the distorted proportions of the mandible with ankylosis were demonstrated by indices. In general, the patient's mandible was characterized by a shorter body, shorter rami and a higher mandibular symphysis (Table 3). As the patient grew, the mandibular surface area increased, as shown in Table 4. However, mandibular asymmetry fluctuated from light asymmetry (L) to moderate asymmetry (M), which was observed at three time points (Table 5).

**Table 1.** Linear measurements of the patient's mandible compared with other mandibles in children at the age of 1–5.

| **Year of Life**<br>**Age of Patient at the Time of CT** | **1st** | **2nd** | **3rd** | **4th** | **5th** | **Source of Measurements** |
|---|---|---|---|---|---|---|
| | **-** | **16 Months** | **25 Months** | **-** | **54 Months** | |
| | | | **Measured Distances [mm]** | | | |
| gnathion–gonion<br>(gn–go)<br>mandibular body length | -<br>50.0 | L 48.6<br>R 50.9<br>57.2 | L 50.5<br>R 54.3<br>57.8 | -<br>58.4 | L 57.1<br>R 55.6<br>61.9 | Patient<br>Malinowski [35] |
| gonion–gonion<br>(go.l–go.r)<br>bigonial breadth | -<br>66.3 | 65.1<br>71.1 | 69.7<br>72.3 | -<br>72.3 | 71.1<br>74.5 | Patient<br>Malinowski [35] |
| gonion–kondylion laterale<br>(go–kdl)<br>height of ramus | -<br>32.7 | L 24.6<br>R 25.0<br>36.1 | L 25.7<br>R 25.8<br>38.6 | -<br>40.5 | L 32.0<br>R 29.5<br>41.7 | Patient2<br>Malinowski [35] |
| infradentale–gnathion<br>(id–gn)<br>height of the mandibular symphysion | -<br>19.3 | 20.1<br>20.3 | 22.0<br>20.7 | -<br>21.7 | 26.9<br>23.1 | Patient<br>Malinowski [35] |
| kondylion laterale–kondylion laterale<br>(kdl.l–kdl.r)<br>bicondylar breadth external | -<br>79.7 | 81.66<br>84.6 | 84.54<br>88.8 | -<br>89.5 | 93.54<br>92.6 | Patient<br>Malinowski [35] |
| kondylion mediale–kondylion mediale<br>(kdm.l–kdm.r)<br>bicondylar breadth internal | -<br>- | 64.8<br>63.0 | 69.6<br>65.3 | -<br>65.4 | 73.1<br>65.5 | Patient<br>Malinowski [35] |
| gnathion–kondylion laterale<br>(gn–kdl)<br>total mandibular length | - | L 60.0<br>R 66.4 | L 69.0<br>R 69.2 | - | L 80.6<br>R 76.3 | Patient |
| mentale–mentale<br>(ml.l–ml.r)<br>bimental breadth) | - | 35.4 | 35.7 | - | 38.5 | Patient |
| height of mandibular body at molar 2 | - | L 17.2<br>R16.5 | L18.2<br>R 19.0 | - | L 18.1<br>R 20.4 | Patient |
| height of mandibular body at foramen mentale | - | L 17.4<br>R 16.5 | L 18.7<br>R 18.6 | - | L 24.7<br>R 24.2 | Patient |

Legend: R—right; L—left.

**Table 2.** Angular measurements of the patient's mandible compared with those of other mandibles in children at the age of 1–5.

| Year of Life<br>Age of Patient at the Time of CT | 1st | 2nd | 3rd | 4th | 5th | Source of Measurements |
|---|---|---|---|---|---|---|
| | - | 16 Months | 25 Months | - | 54 Months | |
| | Measured Angles [deg] | | | | | |
| mandibular angle (go.l–gn–go.r) | - | 81.9 | 83.0 | - | 80.1 | Patient |
| | - | - | 68.9–72.3 | - | - | Malinowski [35] |
| gonial angle (alpha) | - | L 136.0<br>R 127.9 | L 140.9<br>R 127.5 | - | L 140.2<br>R 128.4 | Patient |
| | - | - | 135.1 ± 7.6 | - | - | Kurnik [40] |
| | 139–140 | | - | - | | Kaur et al. [36] |
| | 128.8 | 128.5 | 128.7 | 128.0 | 126.8 | Liu et al. [39] |
| mental angle (beta) | - | 80.22 | 80.26 | - | 85.02 | Patient |
| | - | - | 74.1 ± 8.7 | - | - | Kurnik [40] |
| | 88.4 | | 73.2 | | 69.0 | Le Double in Malinowski [35] |
| upper mandibular symphysion angle (gamma) | - | 106.3 | 101.8 | - | 87.9 | Patient |
| | - | - | 98.8 ± 8.3 | - | - | Kurnik [41] |

**Table 3.** Indices values describing the shape and proportions of the mandible.

| Age of Patient at the Time of CT | 16 Months | 25 Months | 54 Months | Source of Measurements |
|---|---|---|---|---|
| Calculated Values of Indices | | | | |
| $i_1 = \frac{go.l-go.r}{kdl.l-kdl.r} \times 100$<br>The lower the value, the narrower the lower part of the mandible | 79.77 | 82.45 | 75.96 | Patient |
| | 84.0 | 81.4 | 80.4 | Malinowski [35] |
| $i_2 = \frac{go.l-go.r}{gn-kdl} \times 100$<br>The higher the value, the shorter the mandible | L: 98.7<br>R 98.1 | L 101.0<br>R 100.7 | L 88.1<br>R 93.1 | Patient |
| | 63.1 | 66.8 | 67.4 | Malinowski [35] |
| $i_3 = \frac{gn-go}{gn-kdl} \times 100$<br>The higher the value, the shorter the mandibular body | L 81.0<br>R 76.7 | L 73.1<br>R 78.4 | L 70.8<br>R 72.8 | Patient |
| | 56.2 | 53.6 | 55.4 | Malinowski [35] |
| $i_4 = \frac{gn-id}{gn-go} \times 100$<br>The higher the value, the higher the mandibular symphysis | L 41.4<br>R 39.5 | L 43.6<br>R 40.6 | L 47.1<br>R 48.3 | Patient |
| | 35.5 | 35.8 | 37.3 | Malinowski [35] |
| $i_5 = \frac{gn-kdl}{go-gn} \times 100$<br>The lower the value, the shorter the mandibular ramus | L 50.7<br>R 49.1 | L 50.8<br>R 47.6 | L 56.1<br>R 52.8 | Patient |
| | 67.6 | 65.1 | 66.8 | Malinowski [35] |

Legend: R—right; L—left.

**Table 4.** Surface area and volume of the patient's mandible at three time points.

| | Entire Mandible | Left Side–Incision Site | Right Side–Intact |
|---|---|---|---|
| | Mandible Volume [$mm^3$] | | |
| Prior to surgical procedure | 18,909 | 9985 | 8924 |
| After 1st surgical procedure | 16,138 | 8362 | 7776 |
| After 2nd surgical procedure | 13,796 | 6642 | 7154 |
| | Mandible Surface Area [$mm^2$] | | |
| Prior to surgical procedure | 14,203 | 7790 | 6871 |
| After 1st surgical procedure | 18,212 | 9635 | 8975 |
| After 2nd surgical procedure | 17,892 | 8609 | 9591 |

**Table 5.** Asymmetry index (AI) (percentage and degrees) of the patient's mandible at three time points.

| Age of Patient | 16 Months | | 25 Months | | 54 Months | |
|---|---|---|---|---|---|---|
| Type of Asymmetry Index | AI | Type of Asymmetry | AI | Type of Asymmetry | AI | Type of Asymmetry |
| Total length of mandible gn–kdl (%) | 5.05 | M | 0.12 | NS | −2.75 | NS |
| Body length gn–go (%) | 2.29 | NS | 3.63 | L | −1.33 | NS |
| Body height M2 (%) | −1.96 | NS | 2.26 | NS | 6.03 | M |
| Body height ml (%) | −2.47 | NS | −0.35 | NS | −1.15 | NS |
| Height of ramus go–kdl (%) | 0.69 | NS | 0.33 | NS | −3.89 | L |
| Volume (%) | −5.61 | M | −3.63 | L | 3.71 | L |
| Surface area (%) | −6.27 | M | −3.55 | L | 5.40 | M |
| Gonial angle alpha (degrees) | 8.07 | M | 13.4 | S | 11.88 | S |

Legend: (NS) no significant asymmetry; (L) light asymmetry; (M) moderate asymmetry; (S) severe asymmetry.

### *3.1. Prior to the Commencement of Treatment (Age—16 Months)*

In comparison with the mandibles of peers, the mandible of the examined child had the following characteristics:

- shorter body (gn–go) and shorter rami (go–kdl; Table 1). Moreover, the values of indices pointed out that the body of mandible was relatively shorter in relation to the rami (values of indices $i_2$, $i_3$ and $i_5$; Table 3);
- smaller breadth of the inferior mandible (bigonial breadth, go–go; Table 1);
- correct breadth of the superior mandible (kdl–kdl; kdm–kdm; intercondylar distance, internal and external), conditioned by the breadth of the location of articular fossae in the skull (Table 1);
- increased angle of mandible (go–gn–go; Table 2), caused by a short body (gn–go) and widely distanced condyles (kdl–kdl);
- correct height of the symphysis of the body (gn–id; Table 1);
- left side larger than the right side; both the surface area and the volume were asymmetrical toa moderate degree (Tables 4 and 5). Figure 4 shows the differences revealing asymmetrical structure of the mandibular bone in relation to the median sagittal plane. The greatest deviations from the symmetrical build exceeded 5 mm;
- asymmetry toa moderate degree, which revealed itself in the difference in the total length of the mandible (Table 5). Length gn–kdl on the left side (affected by ankylosis) was shorter than that on the right side (AI = 5.05%);
- moderately asymmetrical angles of the mandible; gonial angle (alpha) on the right side was larger by eightdegrees than the left angle (Table 5).

### *3.2. After the First Surgical Procedure and First Physiotherapy (Age—25 Months)*

In comparison with the mandibles of peers, the mandible of the examined child had the following characteristics:

- shorter mandibular body (gn–go) in spite of an increase in its length by 1.85 mm on the left side and by 3.37 mm on the right side (Table 1),
- shorter rami of the mandible (go–kdl) in spite of the elongation of the rami by 1.03 mm on the left side and by 0.86 mm on the right side (2.5 mmin the peer group [35]; Table 1),
- smaller breadth of the lower mandible (bigonial breadth, go–go) in spite of an abrupt increase in the dimension by 4.56 mm in comparison with that in the examination prior to the surgical procedure (Table 1),
- increased height of the body in the area of the mandible symphysis (gn–id; height at the site of mental foramen), which was confirmed in direct measurements (Table 1) and relative measurements in relation to the body length (value of index $i_4$; Table 3); this is an effect of the process of backward rotation;

- upheld larger angle of the mandible (go–gn–go; Table 2);
- correct breadth of the superior mandible (kdl–kdl; kdm–kdm; intercondylar distance, internal and external; Table 1),
- symmetrical length of the entire mandible (gn–kdl); a decrease in the degree of asymmetry by 4.93 degrees,
- asymmetrical volume and surface area toa light degree (Tables 4 and 5),
- asymmetrical length of the body toa light degree (Table 5),
- asymmetry of the angle of the mandible (gonial angle), which underwent transformation from moderate to severe asymmetry (increase by 5.33 degrees; Table 5).

### *3.3. After Second Surgical Procedure and Second Physiotherapy (Age—54 Months)*

In comparison with the mandibles of peers, the mandible in the examined child had the following characteristics:

- shorter body (gn–go) and shorter rami of the mandible (go–kdl) in spite of an increase in dimensions in relation to those from the previous examination (Table 1),
- smaller breadth (bigonial breadth, go–go) in spite of an increase in dimensions in relation to those from the previous examination (Table 1),
- further increase in the body height in the area of the mandible symphysis (gn–id)—an effect of progressing backward rotation (Table 1),
- upheld considerably larger angle of the mandible (go–gn–go; Table 2);
- correct breadth of the superior mandible (kdl–kdl; kdm–kdm; intercondylar distance, internal and external),
- light and moderate asymmetry of the volume and surface area (Tables 4 and 5),
- preserved symmetry of the length of both the entire mandible and the body (Table 5),
- moderate asymmetry of the body height at level M2 (Table 5);
- light asymmetry of the height of both rami (go–kdl), the right ramus was shorter than the left one (the operated one); an increase in growth on the operated side (Table 5),
- severe asymmetry of the gonial angles (alpha). The right-hand angle was larger than the left-hand angle by 11.88 degrees (Table 5).

Within the time period from the first CT, the mandibular body (gn–go) elongated by 8.43 mm on the left side (subjected twice to surgical procedures), whereas it elongated by 4.65 mm on the right side. During that time, the entire length of the mandible elongated (gn–kdl) by 20.6 mm on the left (operated) side and by 9.9 mm on the right side. Acceleration of mandibular growth, which was greater on the left side—the side showing smaller dimensions prior to the treatment—led to a decrease in the asymmetry of the mandible volume from a moderate to light degree as well as to the obtainment of symmetry in the length of the right and left part of the body and rami. The comparison of values of both mandibular gonial angles in three CT examinations showed an increase in the dimensions on the left side. This fact led to considerable asymmetry of the gonial angles (alpha).

## 4. Discussion

This work presents the evaluation of long-term changes occurring in the mandible of a child with congenital zygomatic-coronoid ankylosis, who underwent surgical procedures of the adhesion release at the age of two and four. A three-dimensional analysis of the first CT scan revealed that prior to surgical procedures (at the age of 16 months), in comparison with mandibles of children in the same age group, the child's mandible was characterized by smaller measurements of length, disturbed proportions and moderate asymmetry (left side of the body and the rami was smaller than the right side) [35–40]. The above-mentioned differences probably resulted from the zygomatic-coronoid adhesion and confirmed congenital defects in the area of the left TMJ. Prior to the first surgical procedure, the interincisal distance was not observed [28]. The first surgical procedure of the release of the mandible and the patient's rehabilitation process did not bring the expected functional results [28]. The second CT scan revealed re-ankylotic adhesion (at the age of 25 months), which allowed the upholding of the interincisal distance at a level of four millimeters [28].

The results of the second CT examination (seven months after the first surgery) revealed an increase in the mandible's measurements, first of all, the elongation of the body and of both rami of the mandible (despite the fact that the mandible still showed smaller dimensions in comparison with those of other children's mandibles [35]. In addition, the female patient's mandible was characterized by a large angle of the mandible (go–gn–go) resulting from the short body and correct intercondylar distance. One can also notice an initiated process of backward rotation (nonexistent seven months earlier). The above-mentioned process was accompanied by an increase in the body height in the area of the mandibular symphysis and an asymmetrical, left-sided increase in the gonial angle (alpha).

The second surgical procedure and early physiotherapy made it possible to obtain 16 mm of interincisal distance 12 months after the operation [28]. As a result, functions of the stomatognathic system (such as food ingestion, grinding, swallowing, breathing and sound articulation) had considerably improved [28]. A three-dimensional analysis of the third CT scan revealed that 16 months after the second surgical procedure, the mandible was still characterized by smaller measurements of the body length, excessive build of the body height in the area of the mandibular symphysis, backward rotation and a considerably large angle of the mandible (go–gn–go) in comparison with those of mandibles in other children [35–39,41]. At the age of 54 months, the patient showed catch-up growth, which was greater on the side subjected to the surgical procedure.

According to [41], the growth of bones occurs through the stimulation by soft tissues, mainly muscles, as a reaction to the performed physiological activities (biting, chewing and swallowing of food as well as speaking) [40,42].The observed patient's congenital limitation in mandibular mobility and related unsatisfactory mechanical stimulation of the entire stomatognathic apparatus as well as tongue mobility disorders had influence on the development of the mandibular structure, which affected both the functioning of the cartilaginous tissue of the condylar process and the rebuilding of the mandible on the basis of bone resorption and apposition. The patient's congenital hypoplasia in the TMJ area, which was connected with damage to the structure of the condylar cartilage, led to disorders in the ossification processes of the mandible, disturbed the growth of the condylar process and decreased its resistance to compressive forces [15]. As a result, the condyle could not grow in the superior direction and due to the ossification of the posterior edge of the condylar process, it compensated its growth in the posterior direction [16]. In consequence, apposition-growth of bones through the deposition of the lower edge of the gonial angle took place, which led to inferoposterior displacement of the mandible. In addition, despite the resistance exerted by the adhesion in the area of the hinge axis, the increased work of the mandibular–hyoid muscle was distancing the mandible from the maxilla, reinforcing thus the backward rotation of the mandible. As a result of these processes, the child's mandible with congenital unilateral ankylosis and disorders in the area of TMJs was characterized by smaller measurements of length of the body and rami, backward rotation and an asymmetrical increase in the gonial angles. The correlation between the stage of backward rotation and deep antegonial notch duration of history of ankylosis was confirmed by [43].

A repeat removal of the ankylotic adhesion and an increase in the mandibular mobility enabled the patient to make hinge movements of the mandible and undertake basic physiological functions. During the second physiotherapy period, the four-year-old girl learned new skills, such as pushing her tongue beyond the line of her teeth and eating chopped food (including meat and bread) on her own; she started to speak according to age as well as sing songs. Quality of sleep improved, and respiratory problems were gone [28]. The removal of the obstacle hampering the development of the mandible as well as the application of physiotherapeutic stimulation of muscles activated the catch-up growth process, in accordance with the "form follows function" paradigm [44,45]. The mandible's growth accelerated, particularly on the left side, thus decreasing retardation of the development of the operated side and reducing its developmental distance to other

mandibles in peers (from 8.57 mm before the first surgical operation to 4.84 mm 12 months after the second operation).

Another characteristic feature of the patient's mandible was its backward rotation and large gonial angles (alpha). They are typical of persons with a dolichofacial face pattern. This morphological type of face is related to weak mandibular muscles and additionally with relatively obliquely oriented jaw muscles. It has been observed that there is a relationship between the cross-sectional area of the mandibular muscles and facial morphology: masseter and medial pterygoid muscles have small cross sections in subjects with large anterior facial height and a large gonial angle. At the same time, dolichofacial subjects are characterized by weak bite forces, in contrast to those with strong bite forces, who tend to have brachyfacial patterns. Proffit and Fields [46] recognized it is possible that the lower bite force in dolichofacial people might allow backward rotation of the mandible, often seen in such subjects. Taking into consideration the above-described observations, it seems that severe asymmetry of the gonial angles in the patient resulted from considerable weakening of the muscle force on the operated side, in comparison with the intact side. It was caused, among other things, by the removal of the coronoid process along with the temporal muscle attachments (weak stimulation of the muscles). Such asymmetry was not random in the case of this patient, as the asymmetry of the gonial angles is the rarest asymmetry occurring in the mandibular area (only three cases in a group of 327 children aged 8–12 were observed; 0.92%; [3]). Although it is widely believed that patients with the dolichofacial form have relatively weak mandibular muscles in comparison with those of patients with the brachyfacial form, the assumption whether the force of mandibular muscles determines the skull morphology, or vice versa, has not yet been unquestionably confirmed. A larger gonial angle, which developed on the side with smaller musculature in the patient (operated on at the age of 19 months), may confirm the significance of mechanical impact exerted by muscular forces on the mandibular structure.

The disordered development, degree of asymmetry as well as shape and proportions of the mandible were affected by the patient's inability to perform movements in other directions than hinge movement, when the mandibular head performed only rotary movement in the joint acetabulum (the possibility of hinge movement was created thanks to two surgical procedures and undertaken physiotherapy). However, there was no sliding movement, which is responsible for the decrease in posterior distance between teeth [47].

The case report has some limitations. The first of them is the quality of comparative data. Due to the fact that the measurements of children's mandibles are very rare in the subject literature, the dimensions of the patient's mandible were compared with the measurements obtained from various comparative materials. The work used measurements carried out directly on dry mandibles [35] and cephalograms [39]. The variety of methods made it impossible to perform accurate comparisons. The next problem is connected to the wide age range of groups of children presented in the literature. In this case study, the measurements of a child at a particular age are presented. The fact that publications do not always include the values of standard deviations in the conducted measurements [35] posed an additional problem. It prevented the assessment of whether the dimensions of the patient's mandible were within the range of variability of a given feature in a certain age group. However, in the case of each metrical feature, the patient's mandible showed consequent abnormality in the same direction. Finally, the work presents the changes in the measurements and shape of the mandible in only one patient with zygomatico-coronoid ankylosis. It is difficult to generalize the results on the basis of case studies. It is necessary to subject the obtained results to verification in a larger number of patients. However, this objective is rather difficult to achieve for two reasons: firstly, the cases of congenital ankylosis occur very rarely [17], secondly, surgical procedures are rarely performed in children under the age of three [17].

## 5. Conclusions

In conclusion, the cartilaginous adhesion resulted in the necessity of performing surgical procedures in the area of the temporomandibular joint. It was imperative particularly in the case of congenital idiopathic ankylosis, which caused asymmetrical growth of the right and left sides of the child's mandible, together with the shortening of the body and rami of the mandible on the incision site. In consequence, all that led to the occurrence of severe asymmetry, which demonstrated itself particularly in the visible differences in the values of gonial angles and backward rotation of the mandible. The release of the adhesion as a result of surgical procedures and the applied physiotherapy enabled catch-up growth. This led to a decrease in the distance to the mandibles in children at a similar age. However, the measurements of the mandible were still smaller than those observed in healthy peers. The whole treatment contributed to a decrease in differences between the right and left side of the mandible.

From a clinical perspective, the observation of both development and asymmetry degree constitutes an important element of the treatment process. Catch-up growth, which should follow the removal of the impeding factor, and risk of asymmetry must be taken into consideration while choosing physiotherapeutic and orthodontic approaches in the following years of a child's life.

**Author Contributions:** Conceptualization: A.L. and A.M.; methodology: W.W., A.L., K.D. and P.Z.; software: W.W. and E.K.; validation: A.L. and A.M.; formal analysis: P.L., A.L. and A.M.; investigation: M.K.-M. and P.Z.; resources, K.D., A.M. and M.K.-M.; data: W.W., E.K. and A.L.; writing—original draft preparation, A.L. and A.M., writing—review and editing: W.W., A.L., A.M. and P.L.; visualization: W.W.; supervision, A.M.; All authors have read and agreed to the published version of the manuscript.

**Funding:** This case study received no external funding.

**Institutional Review Board Statement:** The case study was conducted according to the guidelines of the Declaration of Helsinki and approved by the Institutional Review Board of Head and Neck Surgery Clinic for Children and Young Adults (KB 430-15/17-02.03.2017).

**Informed Consent Statement:** Informed consent was obtained from all subjects involved in the case study.

**Data Availability Statement:** Data available within the article.

**Conflicts of Interest:** The authors declare no conflict of interests.

## References

1. Thiesen, G.; Gribel, B.F.; Freitas, M.P.M. Facial asymmetry: A current review. *Dent. Press J. Orthod.* **2015**, *20*, 110–125. [CrossRef] [PubMed]
2. Kula, K.A.; Esmailnejad, A.; Hass, A. Dental arch asymmetry in children with large overjets. *Angle Orthod.* **1998**, *68*, 45–52.
3. Ramirez-Yañez, G.O.; Stewart, A.; Franken, E.; Campos, K. Prevalence of mandibular asymmetries in growing patients. *Eur. J. Orthod.* **2011**, *33*, 236–242. [CrossRef]
4. Chia, M.S.; Naini, F.B.; Gill, D.S. The aetiology, diagnosis and management of mandibular asymmetry. *Orthod. Update* **2008**, *1*, 44–52. [CrossRef]
5. Cheong, Y.W.; Lo, L.J. Facial asymmetry: Etiology, evaluation, and management. *Chang Gung Med. J.* **2011**, *34*, 341–351.
6. Shah, S.M.; Joshi, M.R. An assessment of asymmetry in the normal craniofacial complex. *Angle Orthod.* **1978**, *48*, 141–148. [PubMed]
7. Haraguchi, S.; Iguchi, Y.; Takada, K. Asymmetry of the face in orthodontic patients. *Angle Orthod.* **2008**, *78*, 421–426. [CrossRef] [PubMed]
8. Indersmitten, T.; Gur, R.C. Emotion processing in chimeric faces: Hemispheric asymmetries in expression and recognition of emotions. *J. Neurosci.* **2003**, *23*, 3820–3825. [CrossRef]
9. Cohen, M.M., Jr. Perspectives on craniofacial asymmetry. I. The biology of asymmetry. *Int. J. Oral Maxillofac. Surg.* **1995**, *24*, 2–7. [CrossRef]
10. Danescu, A.; Rens, E.G.; Rehki, J.; Woo, J.; Akazawa, T.; Fu, K.; Edelstein-Keshet, L.; Richman, J.M. Symmetry and fluctuation of cell movements in neural crest-derived facial mesenchyme. *Development* **2021**, *148*, dev193755. [CrossRef]
11. Zhou, J.; Lu, Y.; Gao, X.H.; Chen, Y.C.; Lu, J.J.; Bai, Y.X.; Shen, Y.; Wang, B.K. The growth hormone receptor gene is associated with mandibular height in a Chinese population. *J. Dent. Res.* **2005**, *84*, 1052–1056. [CrossRef] [PubMed]

12. Bayram, S.; Basciftci, F.A.; Kurar, E. Relationship between P561T and C422F polymorphisms in growth hormone receptor gene and mandibular prognathism. *Angle Orthod.* **2014**, *84*, 803–809. [CrossRef] [PubMed]
13. Pawlaczyk-Kamieńska, T.; Kulczyk, T.; Pawlaczyk-Wróblewska, E.; Borysewicz-Lewicka, M.; Niedziela, M. Limited mandi-bular movements as a consequence of unilateral or asymmetrical temporomandibular joint involvement in juvenile idiopathic arthritis patients. *Clin. Med.* **2020**, *9*, 2576. [CrossRef]
14. Lin, L.Q.; Bai, S.S.; Wei, M. Application of computer-assisted navigation in treating congenital maxillomandibular syngnathia: A case report. *World J. Clin. Cases* **2019**, *7*, 650–655. [CrossRef]
15. Haskell, B.; Day, M.; Tetz, J. Computer-aided modeling in the assessment of the biomechanical determination of diverse skeletal patterns. *Am. J. Orthod.* **1986**, *89*, 363–382. [CrossRef]
16. Mizoguchi, I.; Toriya, N.; Nakao, Y. Growth of the mandible and biological characteristics of the mandibular condylar cartilage. *Jpn. Dent. Sci. Rev.* **2013**, *49*, 139–150. [CrossRef]
17. Topazian, R.G. Aetiology of temporomandibular joint ankylosis: Analysis of 44 cases. *J. Oral Surg.* **1964**, *22*, 227–233.
18. Kaban, L.B.; Bouchard, C.; Troulis, M.J. A Protocol for Management of Temporomandibular Joint Ankylosis in Children. *J. Oral Maxillofac. Surg.* **2009**, *67*, 1966–1978. [CrossRef]
19. Domarus, H.; Scheunemann, H. Congenital prearticular temporo-mandibular ankylosis in two siblings. *J. Cranio-Maxillofac. Surg.* **1990**, *18*, 299–303. [CrossRef]
20. Burket, L.W. Congenital bony temporomandibular ankylosis and facial hemiatrophy: Review of the literature and report of a case. *J. Am. Med. Assoc.* **1936**, *106*, 1719–1722. [CrossRef]
21. Dixon, J.; Trainor, P.; Dixon, M.J. Treacher Collins syndrome. *Orthod. Craniofac. Res.* **2007**, *10*, 88–95. [CrossRef]
22. Pirttiniemi, P.; Peltomäki, T.; Müller, L.; Luder, H.U. Abnormal mandibular growth and the condylar cartilage. *Eur. J. Orthod.* **2009**, *31*, 1–11. [CrossRef] [PubMed]
23. Schellhas, K.P.; Pollei, S.R.; Wilkes, C.H. Pediatric internal derangement of the temporomandibular joint: Effect on facial development. *Am. J. Orthod.* **1993**, *104*, 51–59. [CrossRef]
24. Vasconcelos, B.C.E.; Bessa-Nogueira, R.V.; Cypriano, R.V. Treatment of temporomandibular joint ankylosis by gap arthrop-lasty. *Med. Oral Patol. Oral Cir. Bucal* **2006**, *11*, E66–E69. [PubMed]
25. Ohno, K.; Michi, K.; Ueno, T. Mandibular growth following ankylosis operation in childhood. *Int. J. Oral Surg.* **1981**, *10* (Suppl. 1), 324–328. [PubMed]
26. Farmand, M.; Mommaerts, M.; Teuscher, U. Facial growth after treatment of unilateral temporomandibular joint ankylosis in childhood without growth centre transplantation. A serial cephalomorphometric study. *J. Cranio-Maxillofac. Surg.* **1989**, *17*, 260–270. [CrossRef]
27. Cheong, R.C.T.; Kassam, K.; Eccles, S.; Hensher, R. Congenital temporomandibular joint ankylosis: Case report and literature review. *Case Rep. Otolaryngol.* **2016**, 5802359. [CrossRef]
28. Dowgierd, K.; Lipowicz, A.; Kulesa-Mrowiecka, M.; Wolański, W.; Linek, P.; Myśliwiec, A. Efficacy of immediate physiotherapy after surgical release of zygomatico-coronoid ankylosis in a young child: A case report. *Physiother. Theor. Pract.* **2021**. [CrossRef]
29. Demirjian, A.; Goldstein, H.; Tanner, J.M. A new system of dental age assessment. *Hum. Biol.* **1973**, *45*, 211–227.
30. Sun, W.; Starly, B.; Nam, J.; Darling, A. Bio-CAD modelling and its applications in computer-aided tissue engineering. *Comput. Aided Des.* **2005**, *37*, 1097–1114. [CrossRef]
31. Tejszerska, D.; Wolański, W.; Larysz, D.; Gzik, M.; Sacha, E. Morphological analysis of the skull shape in craniosynostosis. *Acta Bioeng. Biomech.* **2011**, *13*, 35–40.
32. Hasan, H.A.; Alam, M.K.; Yusof, A.; Matsuda, S.; Shoumura, M.; Osuga, N. Accuracy of three dimensional CT craniofacial measurements using Mimics and In Vesalius software programs. *J. Hard Tissue Biol.* **2016**, *25*, 219–224. [CrossRef]
33. Martin, R.; Saller, K. *Lehrbuch der Anthropologie, Band 1*; Gustav Fischer Verlag: Stuttgart, Germany, 1957.
34. Habets, L.L.; Bezuur, J.N.; van Ooji, C.P.; Hansson, T.L. The orthopantomogram an aid in diagnosis of temporomandibular joint problems I. The factor of vertical magnification. *J. Oral Rehabil.* **1987**, *14*, 475–480. [CrossRef] [PubMed]
35. Malinowski, A. *Ontogeneza Żuchwy Ludzkiej*; Wydawnictwo Uniwersytetu Zielonogórskiego: Zielona Góra, Poland, 2003.
36. Kaur, N.; Singh, A.P.; Singh, Z.; Gupta, M.; Kaur, J.; Goyal, P.K. Assessment of age from early mandibular growth—Case reports. *Hum. Biol. Rev.* **2016**, *5*, 161–167.
37. Hutchinson, E.F.; L'Abbé, E.N.; Oettlé, A.C. An assessment of early mandibular growth. *Forensic Sci. Int.* **2012**, *217*, 233.e1–233.e6. [CrossRef]
38. Sousa, J.B.R.; Anselmo-Lima, W.T.; Valera, F.C.P.; Gallego, A.J.; Matsumoto, M.A.N. Cephalometric assessment of the mandibular growth pattern in mouth-breathing children. *Int. J. Pediatric Otorhinolaryngol.* **2005**, *69*, 311–317. [CrossRef]
39. Liu, Y.; Behrents, R.; Buschang, P. Mandibular growth, remodeling, and maturation during infancy and early childhood. *Angle Orthod.* **2010**, *80*, 97–105. [CrossRef] [PubMed]
40. Moss, M.L.; Rankow, R.M. The role of the functional matrix in mandibular growth. *Angle Orthod.* **1968**, *38*, 95–103. [PubMed]
41. Tutkuviene, J.; Cattaneo, C.; Obertová, Z.; Ratnayake, M.; Poppa, P.; Barkus, A.; Ritz-Timme, S. Age and sex-related growth patterns of the craniofacial complex in European children aged 3–6 years. *Ann. Hum. Biol.* **2016**, *43*, 510–519. [CrossRef] [PubMed]
42. Sella-Tunis, T.; Pokhojaev, A.; Sarig, R.; O'Higgins, P.; May, H. Human mandibular shape is associated with masticatory muscle force. *Sci. Rep.* **2018**, *8*, 6042. [CrossRef]

43. Singh, S.; Kumar, S.; Pandey, R.; Passi, D.; Mehrotra, D.; Mohammad, S. Dimensional differences in mandibular antegonial notches in temporomandibular joint ankylosis. *JOBCR* **2011**, *1*, 7–11. [CrossRef]
44. Hridaya, N.V.; Ashok, A. Catch-up growth after skeletal maturity—A case report. *J. Adv. Clin. Res. Insights* **2019**, *6*, 27–31. [CrossRef]
45. Wiechers, C.; Buchenau, W.; Arand, J.; Oertel, A.-F.; Peters, K.; Müller-Hagedorn, S.; Koos, B.; Poets, C.F. Mandibular growth in infants with Robin sequence treated with the Tübingen palatal plate. *Head Face Med.* **2019**, *15*, 17. [CrossRef]
46. Proffit, W.R.; Fields, H.W. Occlusal forces in normal and long-face children. *J. Dent. Res.* **1983**, *62*, 571–574. [CrossRef]
47. Wilson, E.M.; Green, J.R. The development of jaw motion for mastication. *Early Hum. Dev.* **2009**, *85*, 303–311. [CrossRef] [PubMed]