

Figure S1. Fundus Images of *Asrgl1*^{mut/mut} mice model: Representative fundus images obtained by autofluorescent scanning laser ophthalmoscopy (AF-SLO) imaging taken at 55° angle lens from both wildtype and *Asrgl1*^{mut/mut} mice at 4 months and 12 months.

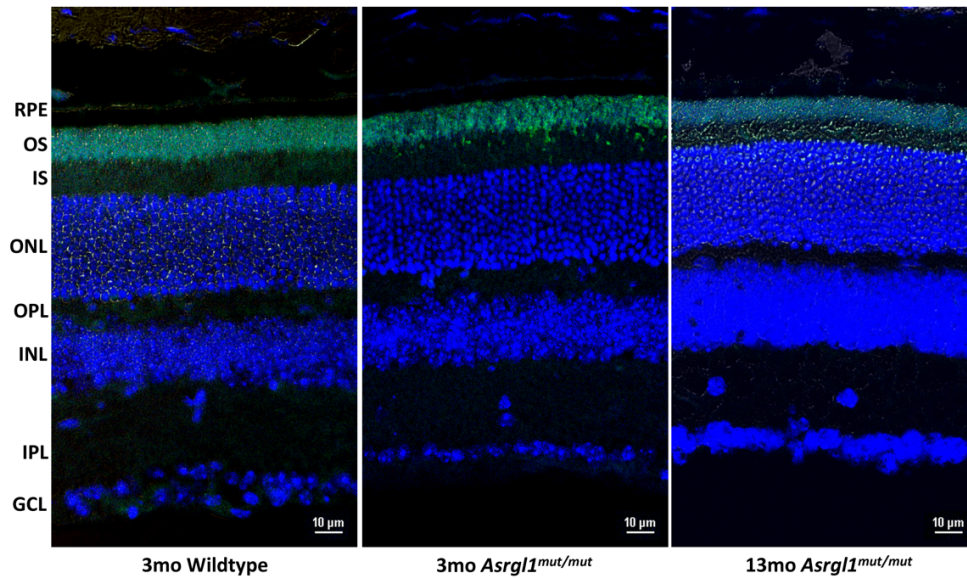


Figure S2: Rhodopsin staining of *Asrgl1*^{mut/mut} mice model: The thickness of OS length appears to be reduced in retinal sections of 3 and 13 month old *Asrgl1*^{mut/mut} mice immunostained with Rho (stained in green) show apparent. RPE: Retinal pigment epithelium; OS: Outer Segments; ONL: Outer Nuclear Layer; OPL: Outer Plexiform Layer; INL: Inner nuclear layer; IPL: Inner Plexiform Layer; GCL: Ganglion Cell Layer.