

Supplementary Materials

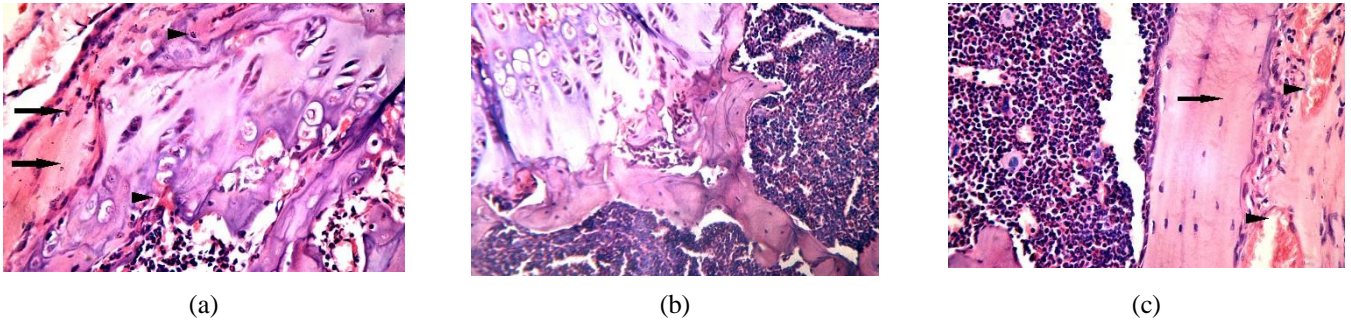


Figure S1. Histopathological changes and severity of arthritis in current CIA murine model: (a) Severe; (b) Moderate; and (c) Mild CIA in mice.