

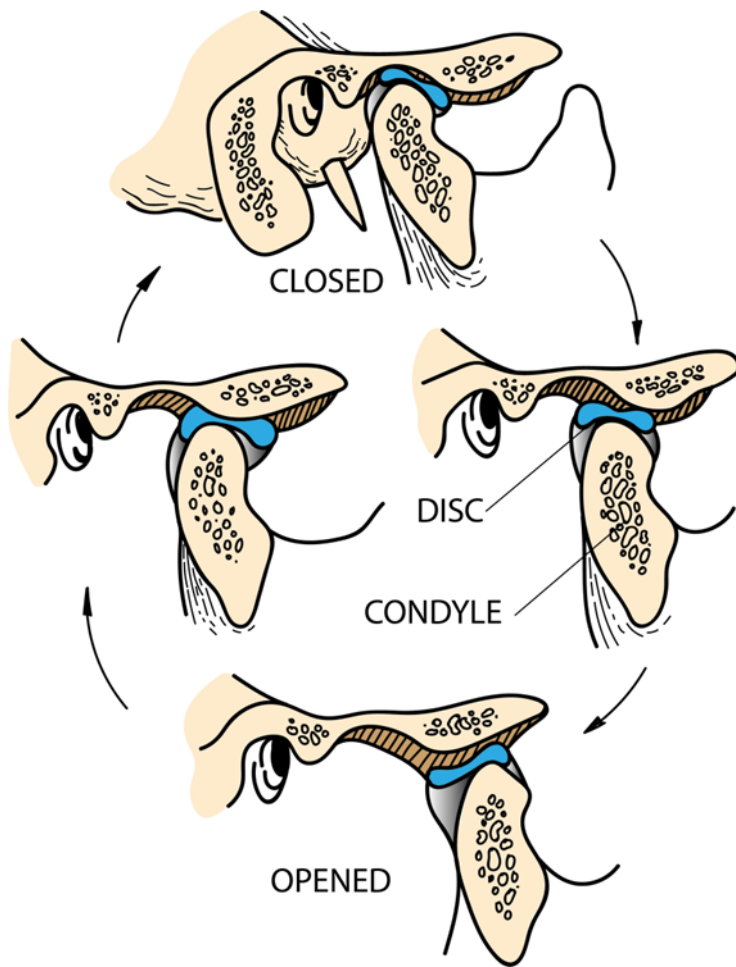Figure S1.: Relation of the TMJ condyle and the disc in closed and open position.

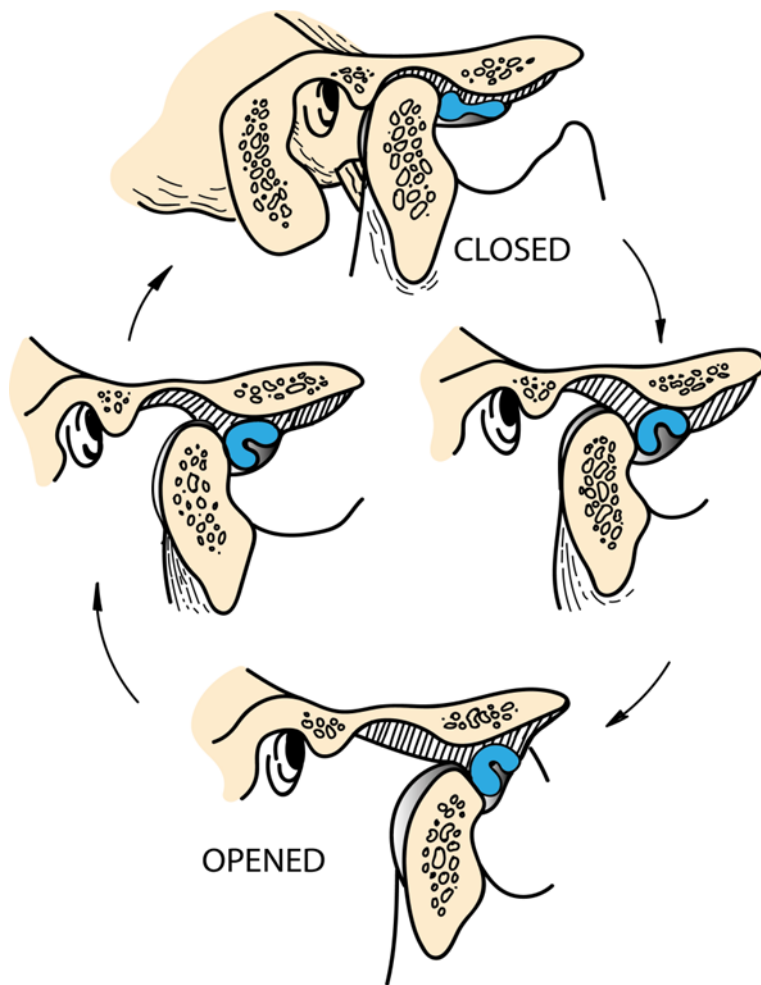


Figure S2. Anterior disc displacement without reduction - the sagittal view.