

Supplementary Material

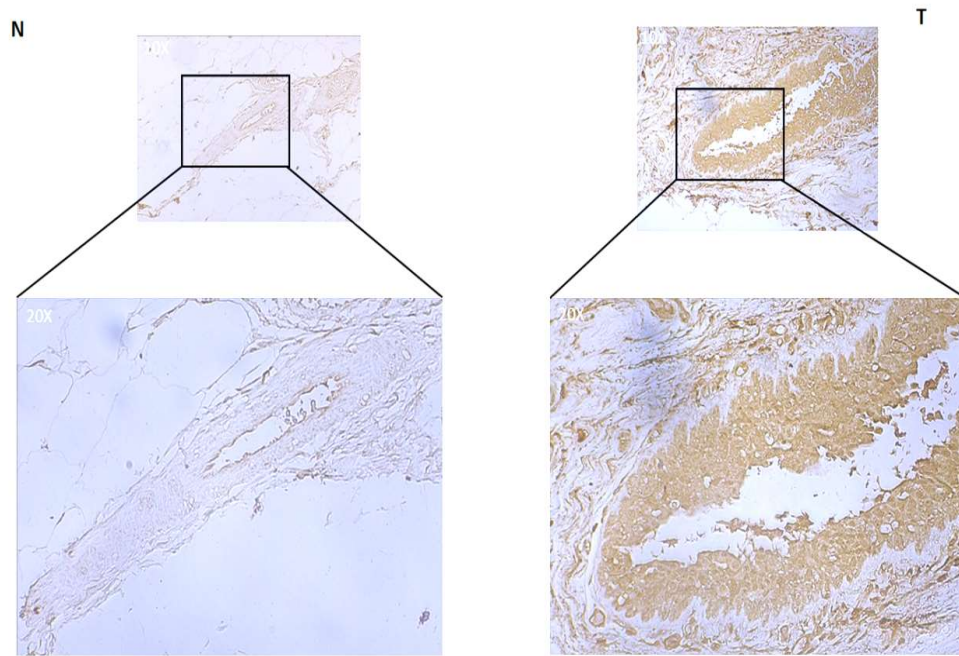


Figure S1. Representative immunohistochemical staining of NGB in 1 out of 10 breast G2 grade post-menopausal specimens of breast cancer (T) and normal counterpart (N) obtained by using a polyclonal anti-NGB antibody (FL-151, Santa Cruz). The black square refers to the below reported optical magnification.