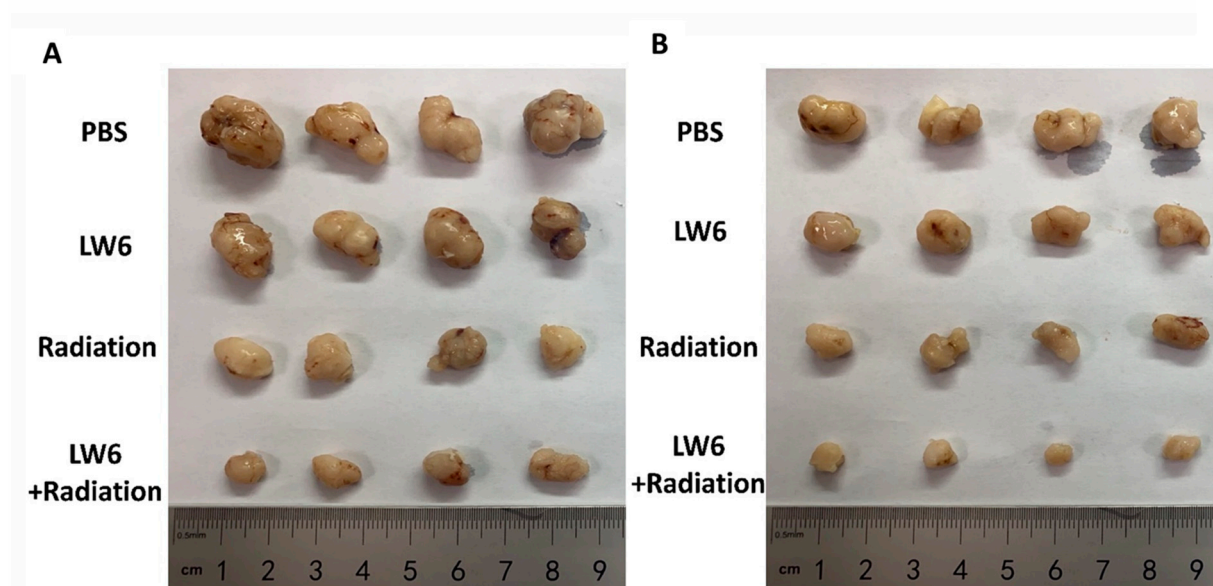


Supplemental Figure S1.



Supplemental Figure S1. The tumor picture of the effect of combined LW6 on the radiation of hyperglycemic rectal cancer. Hyperglycemic ectopic rectal cancer was treated with LW6, radiation, or combined LW6 with radiation. At day 30, the mice were sacrificed and the tumors (A, HCT116; B, SW480) were collected to observe.