

# Spontaneous hematoma of posterior mediastinum with an uncommon cause: a case report and review of the literature

Xiaowei Li,<sup>1</sup> Leilei Liu,<sup>2</sup> Dianbo Cao,<sup>2</sup> Yutian Sun<sup>3</sup>

<sup>1</sup>Cardiovascular Department, China-Japan Union Hospital, Jilin University, Changchun; <sup>2</sup>Radiology Department, The First Hospital of Jilin University, Changchun; <sup>3</sup>Pharmaceutical Department, China-Japan Union Hospital, Jilin University, Changchun, China

## Abstract

Spontaneous mediastinal hematoma is exceedingly rare. We described such a case of a 61-year-old male with a posterior mediastinal hematoma from ruptured small aneurysm, which was ascertained *via* contrast-enhanced computed tomography examination. Subsequent super-selective angiography of left gastric artery revealed a ruptured aneurysm with contrast medium leakage, feeding vessels respectively from caudal and cranial artery. The left gastric artery branch caudally feeding aneurysm was successfully occluded, while cranially feeding artery from the branch of left bronchial artery failed to embolize due to complex anatomic factor. Our management still yields to a satisfactory outcome.

## Introduction

Several causes of mediastinal hematomas, including traumatic and atraumatic factors, have been well described in the literature. Spontaneous mediastinal hematoma is exceedingly rare. Under these circumstances, underlying predisposing factors such as abnormal hemostasis, mediastinal/lower cervical neoplasms, and vasculopathies are relatively common. Severe coughing or vomiting seems to have been a major precipitating factor in the development of spontaneous mediastinal hematoma. Among the imaging modalities used for diagnosing mediastinal hematoma, chest computed tomographic (CT) scan, especially contrast-enhanced CT scan, is the most preferred modality because it can allow for a rapid and noninvasive evaluation of the mediastinum and adjacent structure. As a threat to hemodynamic stability, the patient once presents with sign of active bleeding and a prompt interven-

tion must be initiated. Therapeutic strategy includes surgery and conservative management. Presently, transcatheter arterial embolization is more and more popular in those patients from vascular anomaly. Here, we report an uncommon cause of spontaneous mediastinal hematoma, which originates from ruptured mediastinal aneurysm. This aneurysm is unique with respect to the origin of feeding vessels, respectively from the left gastric artery branch and the left bronchial artery branch. This case will broaden our insight for the cause of spontaneous mediastinal hematoma and its management.

## Case Report

A 61-year-old man presented to the cardiovascular department with a 2-day history of fatigue, excessive sweat, mild chest and epigastric pain. His chest pain did not relieve with the position change. He had no significant past medical or surgical history, except for chronic bronchitis and bronchiectasis 20 years previously. The patient denied having sustained any trauma to his chest prior to admission. He was also not taking any anticoagulant agents and had no sign of disease causing bleeding tendency. On physical examination, his vitals were pulse 120 beats/min, blood pressure 96/66 mmHg, respiratory rate 16/min, and the oxygen saturation 96% on room air. Chest examination revealed crepitations in bilateral basal lung area. A complete blood cell count indicated an elevated white blood cell count of  $16.15 \times 10^9/L$  but mild decreased hemoglobin of 103 g/L. Coagulation screen was within normal limit. Non-enhanced chest computed tomography showed a large mixed-density posterior mediastinal mass extending from the level of gastric cardia to aortic arch together with bilateral pleural effusion, measuring  $20.7 \times 9.3 \times 5.0$  cm with corresponding mass effect shifting left atrium and esophagus. Cystic bronchiectasis was also seen in both lungs, predominantly in the left lower lobe (Figure 1). Because mediastinal hematoma was visible, contrast-enhanced CT was further required for the assessment of thoracic vessels. Subsequent CT scan revealed massive mediastinal hematoma and an aneurysm mainly originating from the branch of left gastric artery (Figure 2). On day two of admission, repeated blood test demonstrated a decreased hemoglobin value from 103 g/L to 86 g/L, suggesting active bleeding. The patient's vital sign was stabilized with fluid challenge and transfusion, and was transferred to the angiographic room in an attempt to control active bleeding. Firstly, super-selective angiography of left gastric artery revealed an aneurysm measuring 10 mm in diameter located in the inferior-posterior mediastinum with contrast medium leakage, feeding

Correspondence: Yutian Sun, Pharmaceutical Department, China-Japan Union Hospital, Jilin University, Changchun 130033, China.  
Tel.: 86184995836.  
E-mail: yutian1970112@163.com

Key words: Mediastinal hematoma; computed tomography; left gastric artery aneurysm; treatment.

Contributions: all authors reviewed and contributed to the text. XL and YS collected the patient's data and drafted this manuscript; LL and DC help prepare images of this manuscript. All authors read and gave final approval for the version to be published.

Conflict of interest: the authors declare no potential conflict of interest.

Received for publication: 13 January 2016.  
Revision received: 24 February 2016.  
Accepted for publication: 13 March 2016.

This work is licensed under a Creative Commons Attribution NonCommercial 4.0 License (CC BY-NC 4.0).

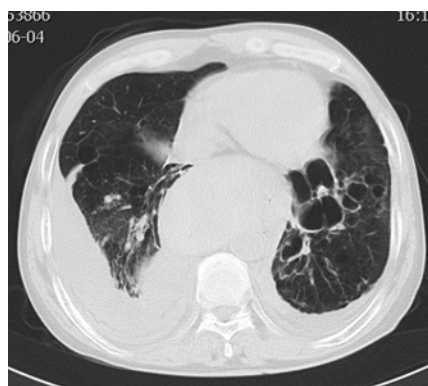©Copyright X. Li et al., 2016  
Licensee PAGEPress, Italy  
Clinics and Practice 2016; 6:838  
doi:10.4081/cp.2016.838

vessels respectively from caudal and cranial artery (Figure 3). Transcatheter arterial embolization was performed *via* a coaxial catheter technique, and a long segment of the left gastric artery branch feeding aneurysm was successfully occluded with five micro-coils and gelatin sponge particles by an interventional radiologist. Then, cranial feeding artery of mediastinal aneurysm was completely searched and the branch of the left bronchial artery was suspected to be the culprit. Left bronchial artery originated from the concave side of proximal left subclavian artery and coursed tortuously. The embolization was cancelled because coaxial catheter failed to be introduced. After the procedure of transcatheter embolization, the patient immediately recovered from hemodynamic instability without any drop at his hemoglobin level on consecutive 5 days and was discharged home on the 7<sup>th</sup> day. At the 1-month follow-up period, contrast-enhanced CT showed decreased size of mediastinal hematoma measuring  $18.1 \times 7.4 \times 3.6$  cm. At 1-year telephone follow-up, he recovered to normal condition and refused any examination.

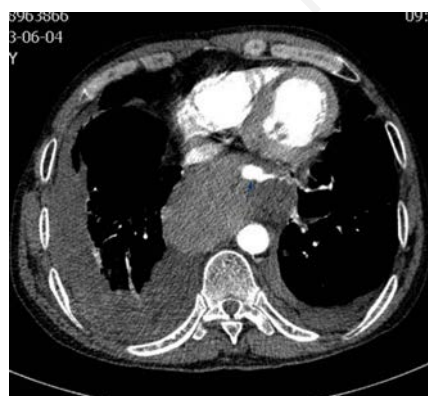## Discussion and Conclusions

Posterior mediastinal hematoma almost always follows chest trauma like vertebral body

fractures. Invasive procedures to the neck and chest can induce the occurrence of mediastinal hematomas, such as central line placement, open-heart surgery, cardiac catheterization (in particular, associated with transradial approach), transbronchial biopsies, and thyroid surgery.<sup>1</sup> Spontaneous mediastinal hematoma is defined as mediastinal hematoma occurring without apparent external cause. In those patients, underlying predisposing factors such as abnormal hemostasis, mediastinal/lower cervical neoplasms, and vasculopathies are frequently common.<sup>2,3</sup> A sudden increase in intrathoracic pressure such as coughing, sneezing, or vomiting can cause mediastinal hematoma. Severe coughing seems to have been a major precipitating factor in the development of the hematoma in the reported literature.<sup>4</sup> Based on the fact above, uncontrolled cough from bronchiectasis may facilitate mediastinal small aneurysm rupture in our patient. Mediastinal hematoma is a rare event with an indistinct clinical presentation.



**Figure 1.** Chest computed tomography scan showed remarked cystic bronchiectasis in the lower lobe of left lung with mediastinal mass and bilateral pleural effusion.



**Figure 2.** Contrast-enhanced computed tomography image showed posterior mediastinal aneurysm with feeding vessel and adjacent hematoma.

The most common presenting symptoms among patients who are hemodynamically stable are shortness of breath and chest pain. Additional presenting symptoms may include respiratory distress, hypotension, tachycardia, chest wall ecchymosis, and dysphagia secondary to the compression of the esophagus by an expanding hematoma.

The available imaging modalities used for diagnosing mediastinal hematoma include sonography, chest radiography, chest CT and magnetic resonance imaging. Appropriate imaging examination and meticulous observation of key imaging features are important for determining the bleeding origin. Currently, chest CT scan is the most frequently used modality in evaluating those suspected patients with mediastinal hematoma because it can allow for a rapid and noninvasive evaluation of the mediastinum and adjacent structure.<sup>5</sup> Contrast-enhanced CT, especially CT angiography, allows better images with respect to the depiction of ectopic bronchial arteries and non-bronchial systemic collateral arteries.<sup>6</sup> To our knowledge, mediastinal hematoma from ruptured aneurysm of the branch of left gastric artery is not documented in the literature. Given this patient's history and findings on CT imaging, it is likely that his aneurysm occurrence was related to long-term bronchiectasis. As known, chronic infectious lung diseases including bronchiectasis frequently result in well-developed collateral circulation of bronchial and non-bronchial systemic arteries. The branch of left bronchial artery likely communicates the branch of left gastric artery resulting in the formation of aneurysm in this case. CT investigation plays an important role in establishing the diagnosis and guiding further treatment.

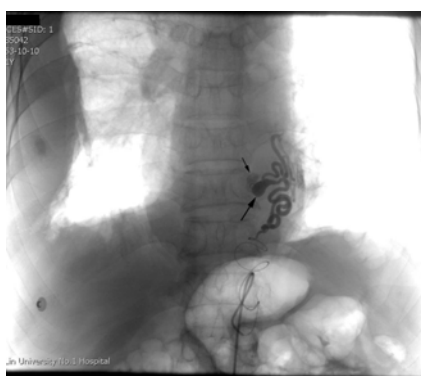
Mediastinal hematoma can be a threat to hemodynamic stability, not only as a source of blood loss, but also as a potential source of compression to vascular structures such as the heart and pulmonary arteries.<sup>7</sup> Diligent moni-

toring of the patient's vital signs and hematologic indices were paramount. Once the patient's hemoglobin continues to decrease, a prompt intervention must be initiated. Management of mediastinal hematoma centers on surgery and conservative management. It is treated conventionally by complete resection via open thoracotomy, but now minimal invasive port-access thoracoscopy is more popular.<sup>8</sup> Hemodynamic control can also be accomplished via embolization after identifying the bleeding site through angiography. As benign clinical course and spontaneous resolution make conservative management feasible for those patients with asymptomatic hematoma, less-invasive embolization is more and more preferred in those patients with vascular lesions.<sup>9,10</sup> In our patient, one side artery supplying aneurysm was embolized and yielded to a satisfactory outcome, while the branch of left bronchial artery failed to be embolized and remained untreated. According to our speculation, circular passage of aneurysm was cut off and the decrease of aneurysm pressure was not enough to facilitate blood extravasation.

In conclusion, our case is unique with respect to the origin of bleeding vessels. Collateral circulation of bronchial and non-bronchial systemic arteries is possibly responsible for the occurrence of mediastinal aneurysm and consequent bleeding. Transcatheter embolization is a feasible and effective treatment option under these circumstances.

## References

1. Doi A, Iida H, Saitoh Y, et al. A posterior mediastinal hematoma causing tracheal obstruction after internal jugular cannulation for cardiac surgery. *J Cardiothorac Vasc Anesth* 2009;23:682-83.
2. Jette LA, Niven AS, Nieves-Robbins N. Spontaneous mediastinal haematoma: a rare complication of warfarin therapy. *BMJ Case Rep* 2011; 2011:bcr0920103316.
3. Gomelsky A, Barry MJ, Wagner RB. Spontaneous mediastinal hemorrhage: a case report with a review of the literature. *Md Med J* 1997;46:83-7.
4. Park KW, Chun JW, Chang SA, et al. Two cases of mediastinal hematoma after cardiac catheterization: A rare but real complication of the transradial approach. *Int J Cardiol* 2008;130:e89-92.
5. Rojas CA, Restrepo CS. Mediastinal hematomas: aortic injury and beyond. *J Comput Assist Tomogr* 2009;33:218-24.
6. Chung MJ, Lee JH, Lee KS, et al. Bronchial and nonbronchial systemic arteries in patients with hemoptysis: depiction on MDCT angiography. *AJR Am J Roentgenol*



**Figure 3.** Selective left gastric arteriogram showed ruptured small aneurysm with cranial and caudal feeding arteries.

- 2006;186:649-55.
7. Nagata T, Hirai Y, Nigara T. Acute diastolic heart dysfunction caused by ruptured descending thoracic aortic aneurysm with posterior mediastinal hematoma. *J Card Surg* 2015;30:589-90.
8. Tanaka T, Ueda K, Hayashi M, et al. Minimally invasive treatment for spontaneous mediastinal hematoma. *Surgery* 2009;145:248-9.
9. Song J, Hindawi RK, Deshpande AS, et al. Spontaneous atraumatic mediastinal hematoma. *Hosp Physician* 2002;38:37-9.
10. Kim HJ, Son HS, Cho SB, et al. Development of a life-threatening mediastinal hematoma from a ruptured bronchial artery aneurysm. *J Thorac Cardiovasc Surg* 2013;146:e47-9.

Non commercial use only