

Two cases of the laryngeal cystic lesions

Takeshi Kusunoki,¹ Ryo Wada,^{2,3}

Hiroto Homma,¹ Yoshinobu Kidokoro,¹
Aya Yanai,¹ Katsuhisa Ikeda²

¹Department of Otorhinolaryngology,
Juntendo University of Medicine,
Shizuoka Hospital; ²Department of
Pathology, Juntendo University of
Medicine, Shizuoka Hospital;

³Department of Otorhinolaryngology,
Juntendo University of Medicine, Faculty
of Medicine, Shizuoka, Japan

Abstract

We experienced two rare cases with laryngeal cystic lesions (laryngocele and laryngeal cyst). In the first case, the laryngocele case was removed by laryngomicrosurgery using an oral approach under general anesthesia. In the second case, the magnetic resonance imaging demonstrated a dumbbell-type cyst with mucus widely extending from the laryngeal lumen to the neck through the thyroid cartilage. The patient had undergone chemotherapy for renal carcinoma with multiple lung and bone metastases. Therefore, we performed only fine needle aspiration rather than aggressive surgery for extirpation of the cyst using an external approach. This fine needle aspiration could improve the quality of life by decreasing both the left laryngeal swelling and the resulting pain, which were the chief complaints.

Introduction

DeSanto¹ studied 238 cases with laryngeal cystic lesions and mainly classified them into two types as follows. The first type, laryngocele, contains air in the cyst, and the second, laryngeal cyst, has mucus. Since both laryngoceles and laryngeal cysts are rare in Japan,^{2,3} we present the results of physical examination, image findings and treatment.

Case Reports

Case #1: Laryngocele

The patient was a 64-year-old Japanese man who underwent digestive endoscopy at a clinic, where a laryngeal mass was pointed out. He was then referred to our hospital. However, he had no symptom of throat and neck. Laryngeal

fiberscope revealed a swelling of the left false cord (Figure 1) that we diagnosed as a laryngocele. Under general anesthesia, the laryngocele was removed by laryngomicrosurgery using an oral approach and the content of the specimen was confirmed to be air. Histopathological examination showed a cystic lesion without malignant cells (Figure 1). The postoperative course was good.

Case #2: Laryngeal cyst

A 57-year-old Japanese man presented with a one-month history of left laryngeal swelling with pain. He had previously undergone chemotherapy for renal carcinoma with multiple lung and bone metastases. Laryngeal fiberscope revealed a swelling of the left false cord and laryngeal ventricle. Magnetic resonance imaging demonstrated a dumbbell-type cyst with mucus widely extending from the laryngeal lumen to the neck through the thyroid cartilage (Figure 2). We performed fine needle aspiration and confirmed the presence of mucus (Figure 3). Cytologic examination showed no malignant cells. This fine needle aspiration caused decreases in both the left laryngeal swelling and pain.

Correspondence: Takeshi Kusunoki, Department of Otorhinolaryngology, Juntendo University of Medicine, Shizuoka Hospital, 1129 Nagaoka Izunokuni-shi, Shizuoka 410-2295, Japan.
Fax: +81.55.948.5088.
E-mail: ttkusunoki001@aol.com

Key words: Laryngocele; laryngeal cyst; fine needle aspiration.

Contributions: TK, diagnosis and therapy, composition of this case report; HH, YK, AY therapy; RW, pathological diagnosis; KI, composition of this case report.

Conflict of interest: the authors declare no potential conflict of interest.

Received for publication: 30 October 2015.

Accepted for publication: 15 February 2015.

This work is licensed under a Creative Commons Attribution NonCommercial 4.0 License (CC BY-NC 4.0).

©Copyright T. Kusunoki et al., 2016
Licensee PAGEPress, Italy
Clinics and Practice 2016; 6:822
doi:10.4081/cp.2016.822

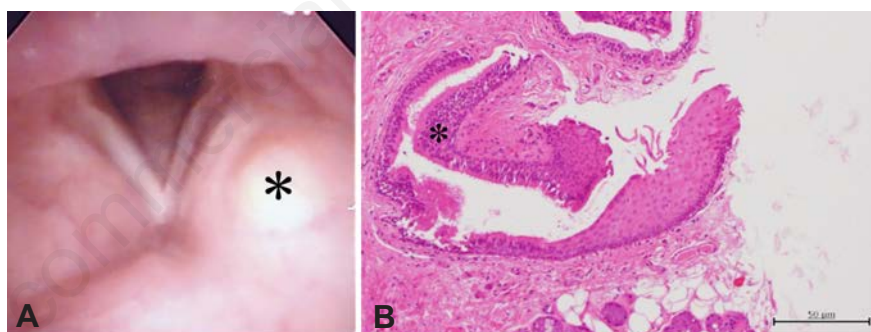


Figure 1. A) A mass (asterisk) at the left false cord showed a smooth surface. B) Histopathological findings showed pseudostratified epithelia (asterisk) in the lumen cyst (H&E staining).

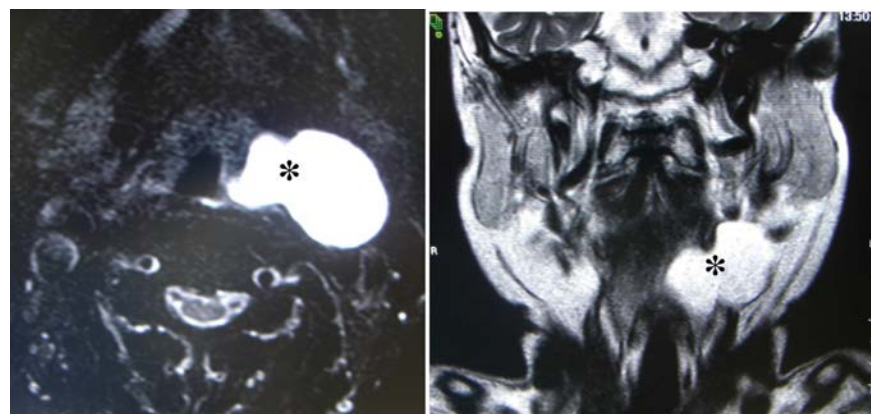


Figure 2. In magnetic resonance imaging, a dumbbell-type cyst with mucus (asterisks) could be observed from the laryngeal lumen through the thyroid cartilage to the neck.

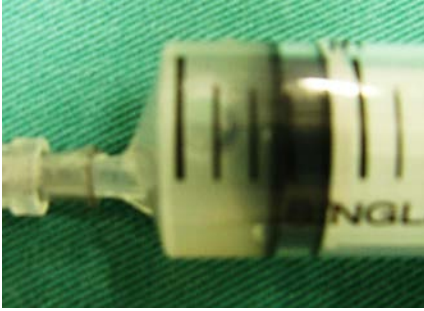

Figure 3. A specimen obtained by fine needle aspiration revealed mucus.

Discussion and Conclusions

Surgical methods for laryngeal cystic lesions include intraoral and external

approaches.^{2,4} Small lesions localized at the laryngeal lumen are generally treated by laryngeal microsurgery using an oral approach.

Large cysts growing from the laryngeal lumen to the neck through the thyroid cartilage require extirpation by an external approach, often adding tracheotomy to maintain the air way. It has also been reported that fine needle aspiration is useful for infant cases.⁵ Our Case #2 with a laryngeal cyst was under chemotherapy for advanced renal carcinoma with multiple metastases of both lung and bone. Therefore, we performed only fine needle aspiration rather than aggressive surgery for extirpation of the cyst using an external approach. This fine needle aspiration could improve the quality of life by decreasing both the laryngeal swelling and pain.

References

1. DeSanto LW, Devine KD, Weiland LH. Cysts of the larynx-classification. *Laryngoscope* 1970;80:145-76.
2. Endo Y. A case of combined laryngocele. *Pract Otol* 2010;103:563-7.
3. Nogaki T, Kushihashi Y, Kadokura Y. A case of laryngeal saccular cyst. *Pract Otol* 2009;102:373-7.
4. Ueha R, Nito T, Sakamoto T, et al. Supra-thyroid alar cartilage approach for the complete resection of laryngeal submucosal tumors and postoperative voice quality. *Eur Arch Otorhinolaryngol* 2015;272:2907-13.
5. Van de Water FW. Laryngeal cyst: their surgical management. *Laryngoscope* 1973; 83:1185-94.