

A rare case of intratonsillar abscess in an adult

Gautam Bir Singh,¹ Deepak Kumar,²
Rubeena Arora,¹ Sunil Garg,³
Shruti Ranjan¹

¹Department of Otorhinolaryngology, Lady Hardinge Medical College & Associated Hospitals, Shaheed Bhagat Singh Marg, New Delhi; ²Department of Otorhinolaryngology, ESI Hospital, Rohini, New Delhi; ³Department of Otorhinolaryngology, Baba Saheb Ambedkar Medical College & Hospital, Rohini, New Delhi, India

Abstract

A rare case of intratonsillar abscess is presented in a 25-year old healthy adult male, where the clinical presentation was found to be unique hitherto unreported in the medical literature. The clinical record also highlights the importance of incision and drainage in the management of such cases. With this case, we illustrate a rare entity that present in an extremely rare manner.

Introduction

Tonsillitis is a common pharyngeal infection affecting children and young adults, however *intratonsillar abscess* is a rare complication associated with it.^{1,2} There is not much in the medical literature on ITA. In a massive internet search using Pubmed/Medline services we could find only 24 cases reported in the medical literature; most of these are in children.¹⁻⁵ We present one such rare case in an adult where the clinical presentation and management was found to be interesting.

Case Report

A 25-year old adult healthy male reported to the ENT outpatient department with the complaint of swelling in the left tonsillar region for the last 3 months following an episode of acute tonsillitis. On detailed history taking the patient revealed that at times he did have odynophagia and bouts of acute jabs of pain in the left tonsillar region. On examination a pale yellow swelling was seen in the region of left tonsil, which had a soft and cystic feel and was tender on palpation (Figure 1). It would be prudent to note that patient had no fever, trismus,

and pain in throat or any signs of inflammation in the tonsillar region. Jugulodigastric lymphnodes were also not palpable. A differential diagnosis of tonsillar cyst, any benign lesion like lymphoma and malignancy was made. However, the needle aspiration revealed pus.

A computed tomography with contrast enhancement (CECT) scan was done which revealed: a well defined thick walled abscess in the left tonsillar region measuring 1.7x1.8 cm in cross section and 2.2 cm in cranio caudal extent (Figure 2). Thus a final diagnosis of left intratonsillar abscess was made. The patient was treated with needle aspiration of the abscess and antibiotics for 7 days: amoxicillin + clavulanic acid and metronidazole (the culture sensitivity report for pus was sterile).¹ But the abscess did not resolve and hence finally incision and drainage (I & D) of the abscess was done under general anesthesia. The said lesion resolved. Post-operative period was uneventful (Figure 3). The patient is in regular follow-up with us for the past 3 months with no untoward incident to report.

Discussion

The exact etiology of ITA is obscure. It is believed that inflammation of the tonsils, especially acute follicular tonsillitis leads to accumulation of pus within the tonsillar crypts and thus an ITA is formed.^{4,6} This could well be the pathophysiology in our case; however it would be prudent to note that our patient had no fol-

Correspondence: Gautam Bir Singh, House no: 1433 / Sector: 15, Faridabad -121007 (National Capital Region), Haryana, India.
Tel.: +91.0129.4012368/4007550 -
Mobile: +91.9818836242.
E-mail: gbsnit@yahoo.co.in

Key words: Intratonsillar abscess.

Received for publication: 2 July 2015.

Revision received: 25 November 2015.

Accepted for publication: 17 December 2015.

This work is licensed under a Creative Commons Attribution NonCommercial 3.0 License (CC BY-NC 3.0).

©Copyright G.B. Singh et al., 2015
Licensee PAGEPress, Italy
Clinics and Practice 2015; 5:804
doi:10.4081/cp.2015.804

licular tonsillitis, but acute tonsillitis. However, ITA can also be caused by bacterial tonsillar seeding from the blood stream or lymphatics.^{4,6} In this context it would be interesting to note that rapid lymphatic transport from palatine tonsils and the absence of lymphatic valves prior to the capsule may not allow aggregation of bacteria within the tonsillar parenchyma.¹ This may account for minimal cases of ITA (and more peritonsillar abscess). Thus factors which compromise the lymphatics and lymphatic flow may thus be important predisposing factors for ITA: dehydration, inflammatory swelling of tonsillar follicles and previous history of peritonsillar abscess.¹

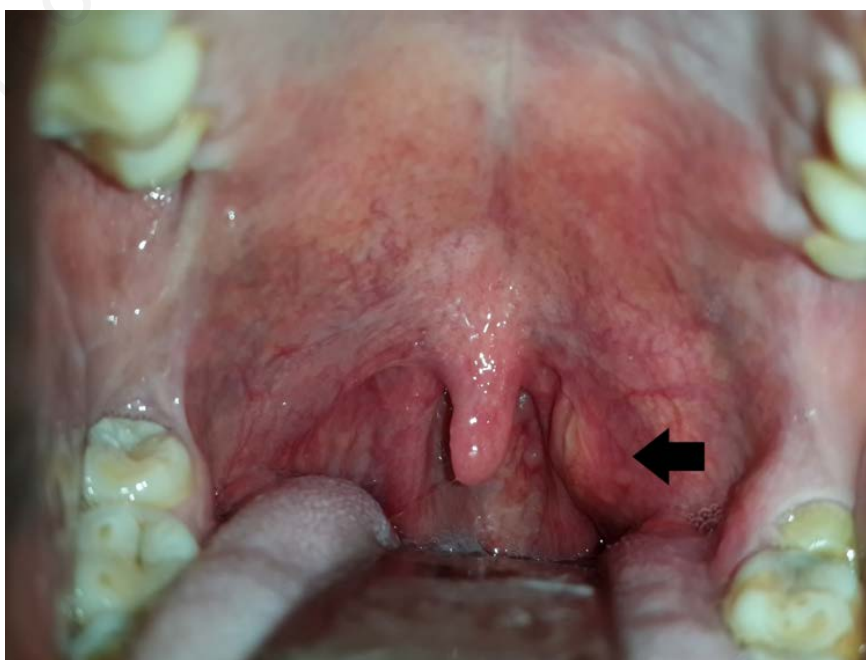


Figure 1. Showing the intratonsillar abscess in the left tonsillar region.

Usually, it is difficult to diagnose ITA as its clinical features are quite similar to peritonsillar abscess; this is probably an important reason for under-reporting of the said lesion in the medical literature. However, two important clinical features distinguish it from peritonsillar abscess: enlargement of tonsils with no significant swelling and absence of muffled voice.^{6,7} The case in focus however had no clinical features of peritonsillar abscess. The patient was harboring sub clinical infection for a long time and hence presented to us with a swelling in the tonsillar region.

A CT scan usually clinches the diagnosis.^{3,4,5}

The treatment protocol for the said lesion is debatable. A recent case series on the cited subject in children by Ulualp et al has highlighted the role of antibiotics in treatment of ITA with no surgical intervention at all.² In this era of minimally invasive surgery, others have suggested that patients should undergo needle aspiration under antibiotic cover.^{3,8,9} However, we found no improvement in our case with needle aspiration and thus I & D was done. Needle aspiration probably leaves residual impacted infective nidus in the deeper inaccessible parts of the crypts of tonsils. This might have caused the non resolution of ITA in

our case. Moreover, needle aspiration requires repeated sittings and patient cooperation, which make this procedure difficult, especially in children. Further, it is interesting to note that none of the previous case reports have defined the role of tonsillectomy in such cases. Review of medical literature reveals that some pediatric patients of ITA after initial treatment finally underwent tonsillectomy.³ However, authors could find no literature in accordance with evidence based medicine in favor of tonsillectomy for ITA. In this context, it would be imperative to note that even in peritonsillar abscess; tonsillectomy is no longer regarded as an absolute indication and is recommended for recurrent abscess only.¹⁰ We thus recommend I & D as a primary modality of treatment for ITA, with tonsillectomy being reserved only for recurrent lesion.

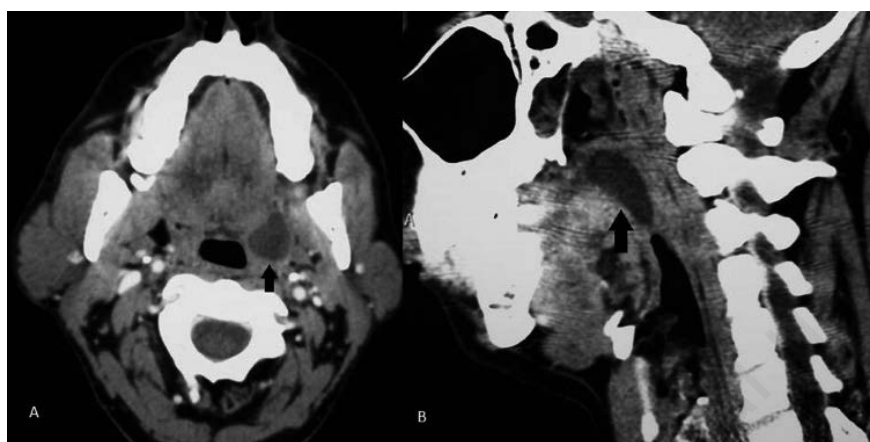


Figure 2. Computed tomography scan neck with contrast enhancement showing well delineated abscess in the left tonsil in axial (A) and coronal cuts (B).

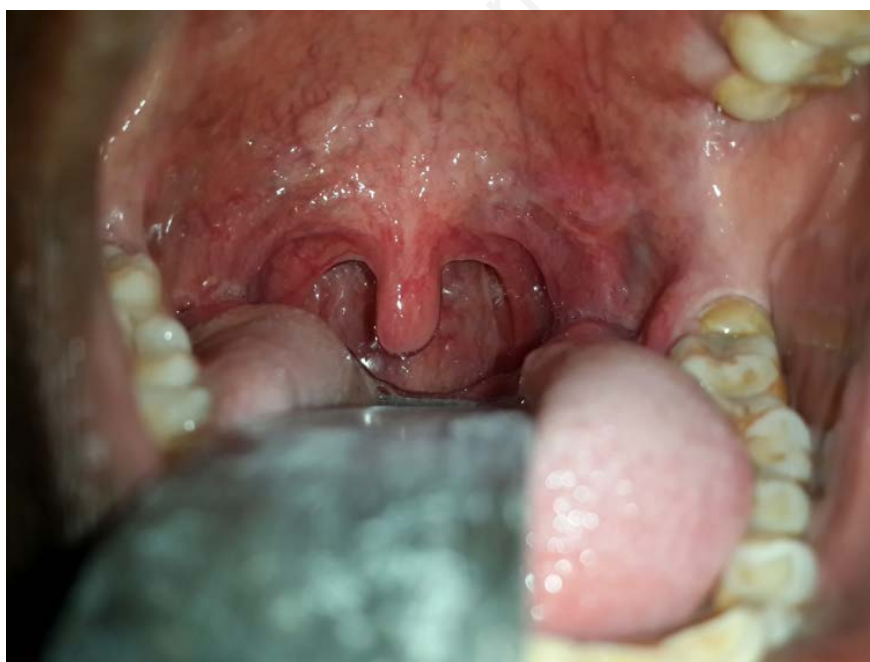

Figure 3. The post-operative clinical image of the patient at the end of 3 weeks.

Conclusions

In summary, this case reports highlights two important features of ITA *i.e.* one that it can present as an asymptomatic swelling and secondly the definitive role of I & D in management of such cases. Both these factors can be attributed to the deep infection nidus in the crypts of tonsils. The case also merits mention on account of the rarity of ITA and its underreporting in the medical literature, which limits conclusions to be drawn on the treatment of ITA in accordance with evidence based medicine.

References

1. Blair AB, Booth R, Baugh R. A unifying theory of tonsillitis, intratonsillar abscess and peritonsillar abscess. *Am J Otolaryngol* 2015;36:517-20.
2. Ulualp SO, Koral K, Margraf L, Deskin R. Management of intratonsillar abscess in children. *Pediatr Int* 2013;55:455-60.
3. Wang AS, Stater BJ, Kacker A. Intratonsillar abscess: 3 case reports and a review of literature. *Int J Paediatr Otorhinolaryngol* 2013;77:605-7.
4. Hsu CH, Lin YS, Lee JC. Intratonsillar abscess. *Otolaryngol Head Neck Surg* 2008;139:861-2.
5. Gan EC, Ng YH, Hwang SY, Lu PF. Intratonsillar abscess: a rare cause for a common clinical presentation. *Ear Nose Throat J* 2008;87: E9.
6. Childs EW, Baugh RF, Diaz JA. Tonsillar abscess. *J Natl Med Assoc* 1991;83:333-6.
7. Ben-Yaakaov A, Weinberger J, Gross M. Intratonsillar abscess in children: management with needle aspiration. *Int J*

- Paediatr Otorhinolaryngol Extra 2006;1: 253-5.
8. Weinberg E, Brodsky L, Stanievich J, Volk M. Needle aspiration of peritonsillar abscess in children. Arch Otolaryngol Head Neck Surg 1993;119:169-72.
9. Johnson RF, Stewart MG, Wright CC. An evidence based review of the treatment of peritonsillar abscess. Otolaryngol Head Neck Surg 2003;1128:332-43.
10. Macnamara M. Acute and chronic pharyngeal infection. In: Gleeson M, ed. Scott-Brown's otorhinolaryngology, head and neck surgery. London: Hodder-Arnold; 2008. pp 1998.

Non commercial use only