Tuberculous osteomyelitis of sternum secondary to primary tuberculous mastitis

Girish D. Bakhshi, Sachin S. Shenoy, Kavita V. Jadhav, Mukund B. Tayade, Suhaib S. Rawoot, Kavitha Jain

Department of General Surgery, Grant Government Medical College & Sir J J group of Hospitals, Byculla, Mumbai, India

Abstract

Sternal tuberculosis secondary to tuberculous mastitis is uncommon. The invasion of the sternum following a primary focus in the breast has not been reported. This may be due to the resistance offered by pectoral fascia and periosteum to the spread of infection into the bone. We present a case of tubercular sternal osteomtyelitis following tubercular mastitis in a 40-year old female. A brief case report and a review of literature are presented.

Introduction

Tuberculosis (TB) is the most widespread human infection worldwide affecting over one billion people. Amongst the extrapulmonary sites, breast and bones are infrequent sites of TB, with less than 1 percent of reported cases.[1] It is more frequently encountered in developing countries like Africa and Asia where the disease is found to be endemic. However the disease is assuming significance even in developed countries due to preponderance of AIDS.[2] Primary mycobacterial infection of the sternum, leading to osteomyelitis, is an extremely rare condition.[3] Tuberculosis of bones and joints accounts for 1-3% of patients with the disease. Isolated tuberculosis of the sternum constitutes less than 1% of cases of tubercular osteomyelitis.[4,5] Only a few cases of primary sternal tuberculosis have been reported in the literature.[3,6] However, no case of tuberculous osteomyelitis of sternum following primary TB mastitis has been reported in literature so far to the best of our knowledge.

Case Report

A 40-year old married female presented with lump in the upper and inner aspect of left breast present since one month. There was associated low-grade fever with night sweats and evening rise of temperature. There was no history of cough or kochs contact. On examination there was a soft fluctuant swelling in the upper inner quadrant of breast. There was no associated axillary or cervical lymph adenopathy. Respiratory system was unremarkable. Fine needle aspiration cytology (FNAC) of the swelling revealed it to be a tubercular cold abscess (Figure 1). The pus sent for Ziel Nielsen (ZN) staining was positive for acid fast bacilli (AFB). Chest X-ray was normal and sputum for AFB was negative. Serostatus for retro viral disease was negative. Nondependent aspiration of the abscess was carried out and patient was started on four drug first line anti-kochs therapy (AKT) *viz*.: isoniazid (H), ethambutol (E), rifampicin (R) and pyrazinamide (Z).

The patient presented a month later with a sinus and swelling over the anterior chest wall overlying the sternum. FNAC revealed a cold abscess and ZN stain of the pus showed AFB. Culture of pus was suggestive of sensitivity to first line AKT. X-ray chest with contrast injected through the sinus (Sinogram) showed osteomyelitic changes in the sternum with a cavity (Figure 2). Incision along with debridement and curettage of osteomyelitic bone was performed leaving an ulcer (Figure 3). The ulcer healed with daily dressings by secondary intention. Patient completed 12 months of AKT, which included 3 months of HERZ and 9 months of HR along with pyridoxine and antacids. Patient is now asymptomatic at 6 months of follow up.

Discussion

Tuberculosis of the sternum is uncommon. It usually results either as an extension from hilar lymph nodes or as part of hematogenous or lymphatic dissemination of the disease from other sites. Sternal tuberculosis has also been reported after Bacillus Calmette-Guérin vaccination in the pediatric age group.[3,5] However sternal tuberculosis following a primary foci in the breast is rarely reported.

Sir Astley Cooper in 1829 first described breast TB as a scrofulous swelling at the bosom of young women suffering from enlargement of cervical glands. The incidence of tuberculosis of breast is less than 1%. The resistance to survival and multiplication of *Mycobacterium tuberculosis* offered by the breast tissue might be a contributory factor in low incidence of TB mastitis reported in literature. It comprises of two types, primary being confined only to the breast, and secondary with coexisting tuberculous lesion elsewhere in the body.[7] Recently it has been reclassified into three categories namely nodular, disseminated and abscess varieties.[8] The major routes of spread are lymphatic, contiguous and hematogenous. It occurs more frequently in women predominantly in the reproductive age group (17-42 years). Risk factors include multiparity, trauma, lactation and past history of suppurative mastitis.[8] Various ways of manifestation include painless unilateral breast mass, generalized breast edema and localized abscess with or without axillary involvement. Tenderness and erythema may also be present. Although any area of breast can be involved but due to proximity of axillary nodes, upper outer quadrant is the most frequently site involved.[9] Very rarely the primary foci of tuberculosis from the breast may invade the pectoral fascia and involve the sternum leading to sternal tubercular osteomyelitis as seen in the present case report.

Clinical manifestations of sternal tuberculosis and pyogenic sternal infections are different. Sternal tuberculosis presents with an insidious swelling and pain over the sternum and constitutional symptoms are usually fewer,[6] whereas patients with pyogenic sternal infections will have a fulminant clinical course with severe systemic upset.

FNAC or trephine biopsy with histological and microbiological examination of sternal tissue for caseating granulomas and acid-fast bacilli are the methods of choice for a definite diagnosis. FNAC can diagnose TB

Correspondence: Girish. D. Bakhshi, "Devneeti" Plot-61, Sector-7, Koper Khairane, Navi Mumbai-400709, Maharashtra, India.
Mobile: +91.9820218198.
E-mail: gdbakhshi@yahoo.com

Key words: primary tuberculous mastitis, Koch's sternal.

Acknowledgements: we would like to thank our Dean Padmashree Dr. T P Lahane for permitting us to publish this article.

Contributions: GDB, concept, design and final approval; SSS, KVJ, MBT, draft preparation and revision; SSR, KJ, acquisition and analysis of data.

Conflict of interests: the authors declare no potential conflict of interests.

Received for publication: 14 May 2014.
Revision received: 6 July 2014.
Accepted for publication: 8 July 2014.

This work is licensed under a Creative Commons Attribution NonCommercial 3.0 License (CC BY-NC 3.0).

©Copyright G.D. Bakhshi et al., 2014
Licensee PAGEPress, Italy
Clinics and Practice 2014; 4:656
doi:10.4081/cp.2014.656

osteomyelitis on the basis of caseating granulomas of epitheloid histiocytes and multinucleate giant cells. Khanna *et al.* reported 100% success rate of FNAC, while Kakkar *et al.* reported a success rate of 73 percent.[10]

In a study by Fadari-Agrahi *et al.* no patient had positive stain for AFB.[11] However, pus was positive for AFB in the present study. Computed tomography scans can be used to determine anatomical localization, osseous destruction, and soft tissue abnormalities.

Aspiration and anti-tuberculous chemotherapy are the treatments of choice in sternal tuberculosis. Early drainage and complete debridement of necrotic material from the lesions along with multi-drug anti-tubercular therapy has been seen to hasten recovery. Rotational tissue flaps can be employed to cover the chest wall defect due to the extensive loss of soft tissue and bone integrity after debridement.[12]

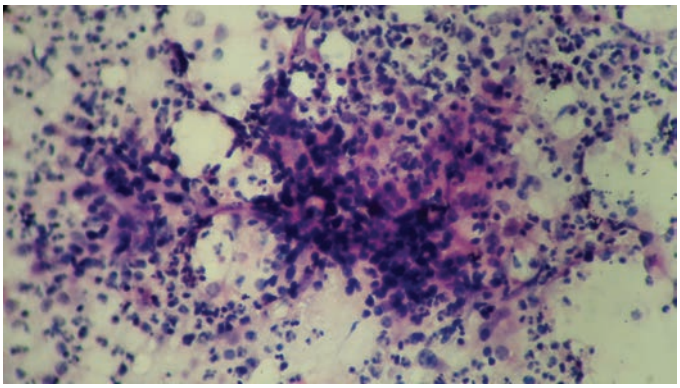

Figure 1. Fine needle aspiration cytology showing epithelioid granuloma in background of mature adipocytes suggestive of tubercular mastitis (hematoxylin & eosin stain: 100x).

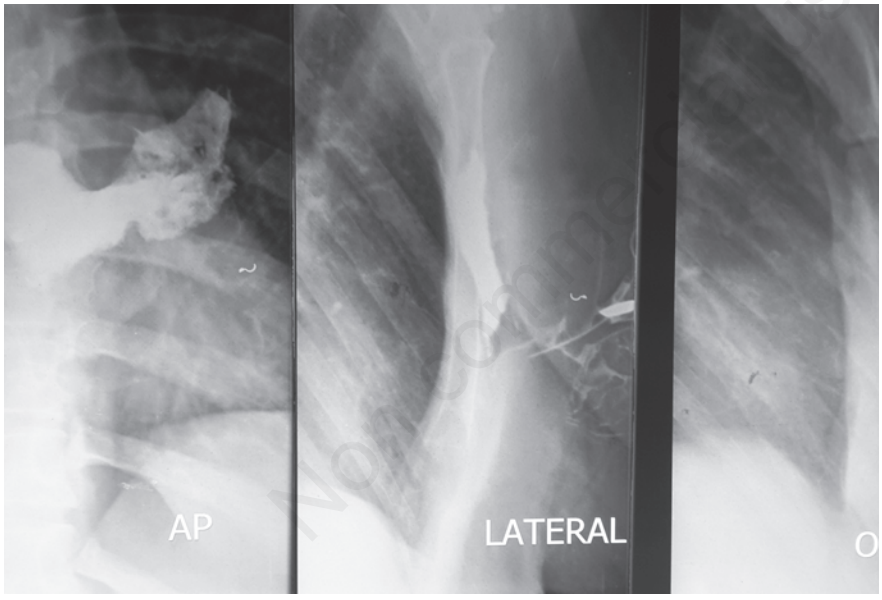

Figure 2. Sinogram showing features of bony erosion of sternum suggestive of osteomyelitis.

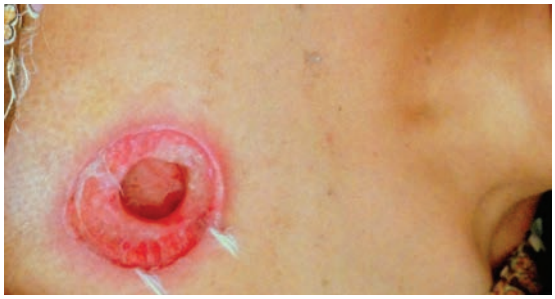

Figure 3. Showing tuberculous ulcer over the sternum.

Conclusions

Pectoral fascia provides resistance to the invasion of tubercular bacilli. However, with the resurgence of the disease, more virulent strains are seen invading this fascia giving rise to such unusual presentations. Hence more studies are required to confirm the same.

References

1. Tanrikulua AC, Ozlem AA, Kapanc AM. Breast tuberculosis in Southeast Turkey: report of 27 cases. Breast Care 2010;5:154-7.
2. Yasmeen B, Imamuddin B, Muhammad SS, et al. Is tuberculosis of breast a common problem? Med Channel 2010;16:172-4.
3. Sharma S, Juneja M, Garg A. Primary tubercular osteomyelitis of the sternum. Indian J Pediatr 2005;72:709-10.
4. Boh JA, Janner D. Mycobacterium tuberculosis sternal osteomyelitis presenting as anterior chest wall mass. Pediatr Infect Dis J 1999;18:1028-9.
5. Watts HG, Angrles L, Lifesto RM. Current concepts review: tuberculosis of bones and joints. J Bone Joint Surg Am 1996;78:288-98.
6. Choi H, Lee CJ, Lee KJ, Moon KD. Primary tuberculous osteomyelitis of the sternum. J Cardiovasc Surg 2001;42:841-3.
7. Mathur R,Vatliya MV, Chitimilla SK. Tuberculosis of breast: a case report. West London Med J 2009;1:37-41.
8. Tewari M, Shukla HS. Breast tuberculosis: diagnosis, clinical features and management. Ind J Med Res 2005;122:103-10.
9. Madhusudhan KS, Gamanagatti S. Primary breast tuberculosis masquerading as carcinoma. Singapore Med J 2008;49:3-5.
10. Kakkar S, Kapil K, Sing MK, Verma K. Tuberculosis of breast. A cytomorphologic study. Acta Cytol 2000;44:292-6.
11. Fadari-Araghi M, Geranpayeh L, Irani S, et al. Breast tuberculosis: report of eight cases. Arch Iran Med 2008;11:463-5.
12. Sarlak AY, Gundes H, Gundes S, Alp M. Primary sternal tuberculosis: a rare unhealed case treated by resection and local rotational flap. Thorac Cardiovasc Surg 2001;49:58-9.

Non-commercial use only