

# Management of a failed metatarso-phalangeal joint fusion utilizing a hemicup prosthesis

Nicola Stadler, Stefan Hofstätter,  
Klemens Trieb

Department of Orthopaedic Surgery,  
Klinikum Wels-Grieskirchen, Austria

## Abstract

We report a case of a 65-year-old man with a painful nonunion of the first metatarsophalangeal joint (MTPJ). It is one of the main severe complications of this surgery. Its prevalence is described between 5% and 10% across different operative techniques. The implantation of hemicup-prosthesis has been successfully used for the hallux rigidus treatment with very promising results. In our case report, we introduce a treatment method of converting a pseudoarthrosis of the first MTPJ, made of two crossing screws into a hemicup-prosthesis as a salvage procedure. This is to our best knowledge the first report using this device for treatment of pseudoarthrosis of the first MTPJ.

## Introduction

Painful nonunion of the first metatarsophalangeal joint (MTPJ) is one of the main severe complications of this surgery. The prevalence of nonunion is described between 5% and 10% across different operative techniques (e.g. plates, crossed screws, plate and compression screw).<sup>1-3</sup> The implantation of hemicup-prosthesis has been successfully used for the hallux rigidus treatment with very promising results.<sup>4-6</sup> To our best knowledge, we present the first case report using a hemicup-prosthesis as a salvage procedure for treatment of pseudoarthrosis of the first MTPJ.

## Case Report

We report a case about a 65-year-old male patient with pseudoarthrosis of the first MTPJ, who suffered from a nonunion 12 months after a fusion made of two crossing screws (Figure 1). Postoperative x-rays showed a correct position of the two crossing screws and a correct position of the dorsiflexion (Figure 2). The x-ray revealed a nonfusion during follow ups; we recommended the possibility of an extracorporeal shockwave therapy but the patient

refused. The blood samples which we had taken before the revision surgery didn't show any infection signs; additionally, there was no fever or any clinical sign of infection. The patient is a high demand patient, who does sport (hiking and cycling up to 20 km) and gardening quite often. Twelve months after the fusion he still had severe pain and was not satisfied at all with the result of the surgery. At this time the x-ray showed a persistent nonunion. We discussed the pros (definitive solution, a greater load-bearing capacity for our active high demand patient) and cons (a long follow-up treatment) of a revision fusion. On the other hand we informed him about the stability, function, the faster healing and mobilization of the prosthesis. Our patient refused a revision because of the previous failed MTPJ fusion; for this reason we decided to use this new device.

The two screws and the connective tissue were removed. We took care that enough resection of the bone and a capsular release of the metatarsal head was made in order to achieve a dorsiflexion of more than 90 degrees intraoperative. Afterwards a hemicup Biopro prosthesis (Biopro, Farmingdale, NY, USA) 18.5 mm was implanted. Intraoperative the final check up showed a dorsiflexion of 80 degrees and a good stability of the joint.

Immediately, the patient received postoperative-physiotherapy treatments.<sup>4</sup> During hospitalization he learned how to do exercises for mobilization of the great toe, which the patient continued at home. The patient was allowed to bear weight as tolerated with comfortable wide shoes. The suture was removed 10 days postoperatively. After 6 weeks the hemicup prosthesis was radiologically controlled. It showed a correct fitting of the prosthesis. In the clinical examination an active range of motion of 40/0/30 degrees was achieved by the patient.

Correspondence: Klemens Trieb, Department of Orthopaedic Surgery, Klinikum Wels-Grieskirchen, Wagnleithnerstraße 27, 4710 Grieskirchen, Austria.

Tel.: +43.7248.6010.

E-mail: klemens.trieb@klinikum-weg.at

Key words: metatarso-phalangeal joint fusion, hemicup prosthesis.

Received for publication: 6 May 2014.

Revision received: 25 July 2014.

Accepted for publication: 4 August 2014.

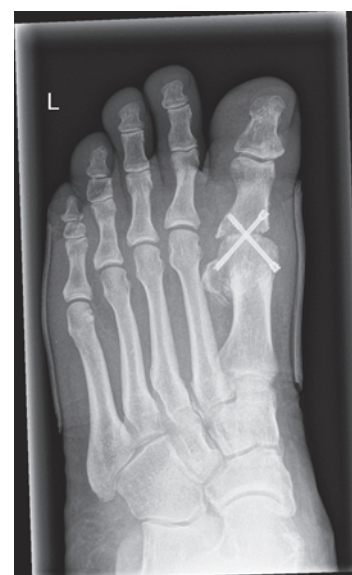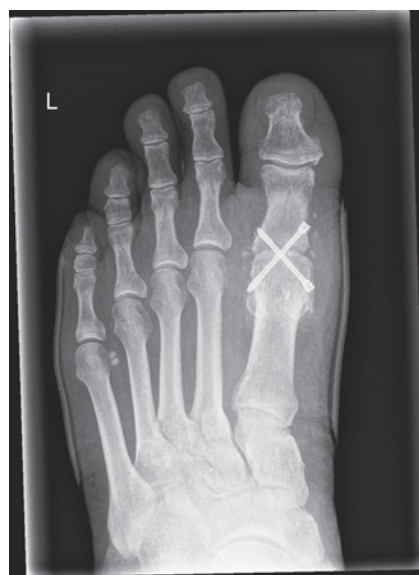This work is licensed under a Creative Commons Attribution NonCommercial 3.0 License (CC BY-NC 3.0).

©Copyright N. Stadler et al., 2014

Licensee PAGEPress, Italy

Clinics and Practice 2014; 4:646

doi:10.4081/cp.2014.646



**Figure 1. Radiographs showing a non-union 12 months after the fusion with 2 crossing screws in appropriate alignment.**

was scored -5 points because of a range of motion of the first metatarso-phalangeal joint of 60 degrees (40/0/20 degrees). Our patient was very satisfied with the postoperative result of the procedure and would undergo the surgery again (Figure 3).

## Discussion

The arthritis of the first metatarsophalangeal joint is the most common disease of patients with forefoot arthritis and has a prevalence of 2-10% in the adulthood. As main factors in the development of the hallux rigidus are trauma, repeated microtrauma, osteoarthritis, abnormal long first metatarsal and osteochondral fractures blamed. Patients with a degenerative arthrosis commonly suffer from pain in the first MTPJ, limited dorsiflexion and increasing stiffness in the first toe.

The hallux rigidus is commonly found in middle-aged patients. It can be radiographically divided into 3 grades: grade 1 (mild), grade 2 (middle) and grade 3 (severe). Commonly grade 1 and 2 are treated with cheilectomy and grade 3 with arthrodesis or Keller resection arthroplasty.<sup>7</sup> The arthrodesis is the first choice for high demand patients. There are a variety of possibilities of the arthrodesis of the first MTPJ, but most commonly screws or a plating system are used.<sup>3</sup> As main complications of the arthrodesis pseudoarthrosis, incorrect positioning of the dorsiflexion and arthrosis of the interphalangeal joint are considered. Fusion rates were described from 90-100% across different operative techniques.<sup>1</sup>

Unfortunately, little data are available about the results of revision surgery in hallux rigidus patients. In case of failed fusion, the literature reveals several revision surgeries with innovative devices (e.g. plates, crossed screws, plate and compression screw) and interposition of an iliac bone graft.<sup>2</sup> Although not documented in literature, these techniques also show a high prevalence of complications, e.g. nonunion, shortening of the great toe and donor side morbidity after interposition of an iliac bone graft.

We already use BIOPRO First MPJ (Biopro) prosthesis for hallux rigidus treatment for many years. This hemicup prosthesis reveals good clinical and radiological long term results.<sup>6,8,9</sup> The results of these studies on primary implantation are comparable to our regarding range of motion and AOFAS score.

The prosthesis is used for resurfacing the phalangeal base. Non-porous coated and porous-coated implants in 5 sizes (17 mm, 18.5 mm, 20 mm, 21.5 mm, 23 mm) are available. A small plane must be removed with the oscillating saw. An excessive joint tension should be avoided, so it is important to remove enough of

the bone. Furthermore the resection must be parallel to the concavity of the phalangeal articular surface.

Osteophytes should be removed to avoid an impingement and allow a normal movement of the joint. A sizer guide is used as next step in order to select the size of the implant. After finding the correct size of the implant, the implant is inserted. Finally, it is important to check if the patient has a normal range of motion.

Postoperatively, the patient should achieve

early weight bearing and should get a prompt access to physiotherapy.

## Teaching points

We conclude that the hemicup prosthesis is a new technique and option of the management of the pseudoarthrosis of the first MTPJ after arthrodesis.

This early result of this salvage procedure is

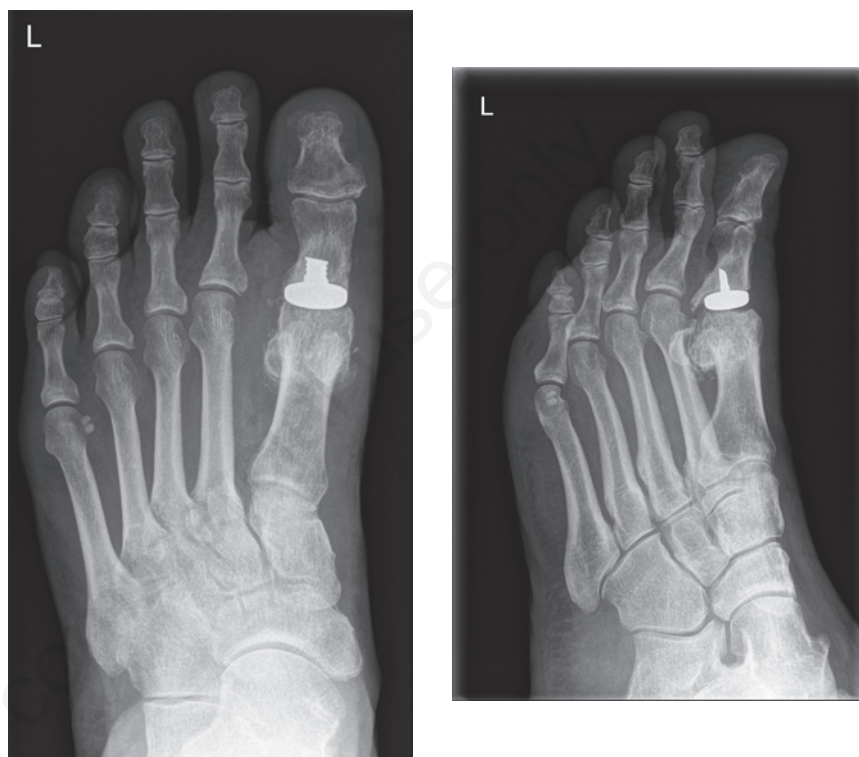


Figure 2. Postoperative radiographs showing a correct prosthetic fitting.

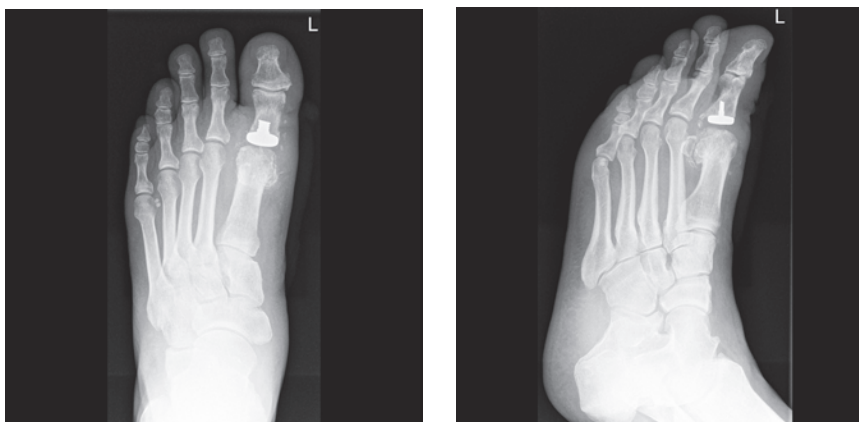

Figure 3. Radiographs 17 months postoperative.

very promising. However, there must be longer follow ups and more patients would be beneficial to review the stability and long-term range of motion.

## References

1. Yee G, Lau J. Current concepts review: hallux rigidus. *Foot Ankle Int* 2008;29:637-46.
2. Hamilton GA, Ford LA, Patel S. First metatarsophalangeal joint arthrodesis and revision arthrodesis. *Clin Podiatr Med Surg* 2009; 26:459-73.
3. Brage ME, Ball ST. Surgical options for salvage of end-stage hallux rigidus. *Foot Ankle Clin N Am* 2002;7:49-73.
4. Schuh R, Adams S, Hofstaetter SG, et al. Plantar loading after chevron osteotomy combined with postoperative physical therapy. *Foot Ankle Int* 2010;31:980-6.
5. Kitaoka HB, Alexander IJ, Adelaar RS, et al. Clinical rating systems for the ankle-hindfoot, midfoot, hallux, and lesser toes. *Foot Ankle Int* 1994;15:349-53.6.
6. Salonga CC, Novicki DC, Pressman MM, Malay DS. A retrospective cohort study of the BioPro hemiarthroplasty prosthesis. *J Foot Ankle Surg* 2010;49:331-9.
7. Deland JT, Williams BR. Surgical treatment of hallux rigidus. *Am Acad Orthop Surg* 2012;20:347-58.
8. Kissel CG, Husain ZS, Wooley PH, et al. A prospective investigation of the BioPro hemi-arthroplasty for the first metatarsophalangeal joint. *J Foot Ankle Surg* 2008;47:505-9.
9. Roukis TS, Townley CO. BIOPRO resurfacing endoprosthesis versus periarticular osteotomy for hallux rigidus: short-term follow-up and analysis. *J Foot Ankle Surg* 2003;42:350-8.

Non commercial use only