

## Osseous hamartoma arising from the Eustachian tube

Ai Kawamoto,<sup>1,2</sup> Yukio Katori,<sup>1</sup> Yohei Honkura,<sup>2</sup> Masaki Ogura,<sup>1</sup> Takeshi Oshima,<sup>2</sup> Toshimitsu Kobayashi<sup>2</sup>

<sup>1</sup>Division of Otolaryngology, Sendai Municipal Hospital; <sup>2</sup>Department of Otolaryngology & Head and Neck Surgery, Tohoku University Graduate School of Medicine, Japan

### Abstract

A fairly quite rare case of osseous tumor arising from the Eustachian tube (ET) is described. A 56-year-old man presented with a smooth bulky mass in the nasopharynx and secretory otitis media in the right ear. Computed tomography and magnetic resonance imaging indicated a solid tumor-like region occupying the nasopharynx with apparent extension to the right ET. Transnasal endoscopic surgery demonstrated that the tumor had originated from the ET, and the tumor was partially removed in the area where it had expanded into the nasopharynx. The pathological diagnosis was an osseous hamartoma consisting of bony tissue, fat cells and fibroblasts. To our knowledge, this is the first reported case of osseous hamartoma arising from the ET in the world literature. The patient presented symptoms of nasal obstruction and unilateral aural fullness. Reduction surgery and tympanostomy tube insertion were useful for accurate diagnosis and resolution of the symptoms.

### Introduction

Tumors and tumor-like lesions of the Eustachian tube (ET) are rare, and Muzzi *et al.*<sup>1</sup> have reviewed 78 cases that were reported between 1988 and 2011. The pathology of ET tumors varies, and more than five reports each have described for teratoma,<sup>2</sup> dermoid tumors,<sup>3</sup> melanin-pigmented oncocyctic metaplasia,<sup>4</sup> and chondroma<sup>5</sup> as benign tumors and also melanoma,<sup>6</sup> squamous and/or transitional cell carcinoma<sup>7,8</sup> as malignant tumors. However an osseous pathology is quite rare, and to our knowledge, only one case of osteoma has been reported at the tympanic orifice of the ET;<sup>9</sup> hamartoma with an osseous content has not been reported previously. Here we described the first reported case of osseous hamartoma arising from the ET, causing otitis media and nasal obstruction as a result of expansion into the nasopharynx.

### Case Report

A 56-year-old male patient presented with right aural fullness and nasal obstruction that had been evident for three years. He had no juvenile history of nasal disease or otitis media. At the first admission, the secretory otitis media (SOM) in the right ear was investigated, and a solid, smooth and poorly mobile tumor was detected in the posterior part of the nasal cavity and nasopharynx (Figure 1A). Initial diagnosis of a transnasal biopsy sample suggested fibroma. Computed tomography (CT) examination showed that the tumor occupied the nasopharynx, and a high-intensity shadow was evident within it (Figure 2A, C and D). Although CT was unable to reveal the origin of the tumor, the high-intensity shadow extended in the direction of the ET (Figure 2B) and thus the tumor was thought to have arisen from the ET. Magnetic resonance imaging (MRI) showed that the tumor consisted of heterogeneous components with T1 enhancement (Figure 2E), and that the inside of the tumor appeared more contrasted with T2 enhancement (Figure 2F). The T2 enhanced image showed a smooth line of the nasopharyngeal mucosa, suggesting no tumor invasion in the nasopharynx. Enhancement with intravenous contrast medium revealed no remarkable features by both CT and MRI.

Under a preoperative diagnosis of nasopharyngeal tumor possibly involving the Eustachian tube, partial resection of the nasopharyngeal tumor was performed by transnasal endoscopic surgery to obtain a definitive diagnosis and to relieve the nasal obstruction. A hard mass with a smooth surface was seen to arise from the pharyngeal ostium of the ET (Figure 1B). The mass was reduced piecemeal using scissors and sharp forceps, taking care to preserve the normal mucosa of the nasopharynx. The tumor was not attached to the nasal and pharyngeal mucosa and protruded into the ET. However, its point of origin could not be detected precisely because the surgical devices were unable to reach the inside of the ET. Part of the tumor in the ET therefore remained, and a tympanostomy tube was inserted into the right ear to resolve the SOM. Pathological examination showed that the tumor consisted of bony tissue, fat cells and proliferated fibroblasts, and was diagnosed as osseous hamartoma arising from the ET (Figure 3). Ten months after the reduction surgery, the tumor was not markedly enlarged (Figure 1C). The nasal obstruction, right aural fullness and conductive hearing loss that were evident on initial presentation were diminished after the surgery.

Correspondence: Yukio Katori, Division of Otolaryngology, Sendai Municipal Hospital, 3-1 Shimizukoji, Wakabayashi, Sendai 984-8501, Japan.

Tel: +81.22.266.7111 – Fax: +81.22.214.7706.

E-mail: entsendai@yahoo.co.jp

Key words: Eustachian tube, osseous hamartoma, secretory otitis media, endoscopic surgery.

Contributions: AK, surgery of the case, manuscript concept, design and final approval; YK, diagnosis of the case, manuscript first draft and revision; YH, MO, TO, TK, manuscript revision.

Conflict of interests: the authors declare no potential conflict of interests.

Conference presentation: a part of this paper is presented at 20th IFOS World Congress (2013, Seoul).

Received for publication: 3 April 2013.

Revision received: 28 May 2013.

Accepted for publication: 11 June 2013.

This work is licensed under a Creative Commons Attribution NonCommercial 3.0 License (CC BY-NC 3.0).

©Copyright A. Kawamoto *et al.*, 2013

Licensee PAGEPress, Italy

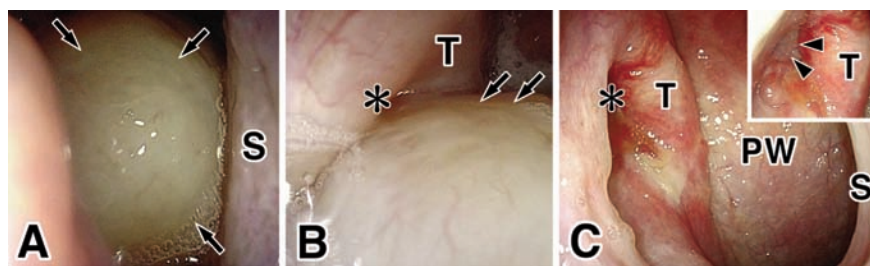
Clinics and Practice 2013; 3:e25

doi:10.4081/cp.2013.e25

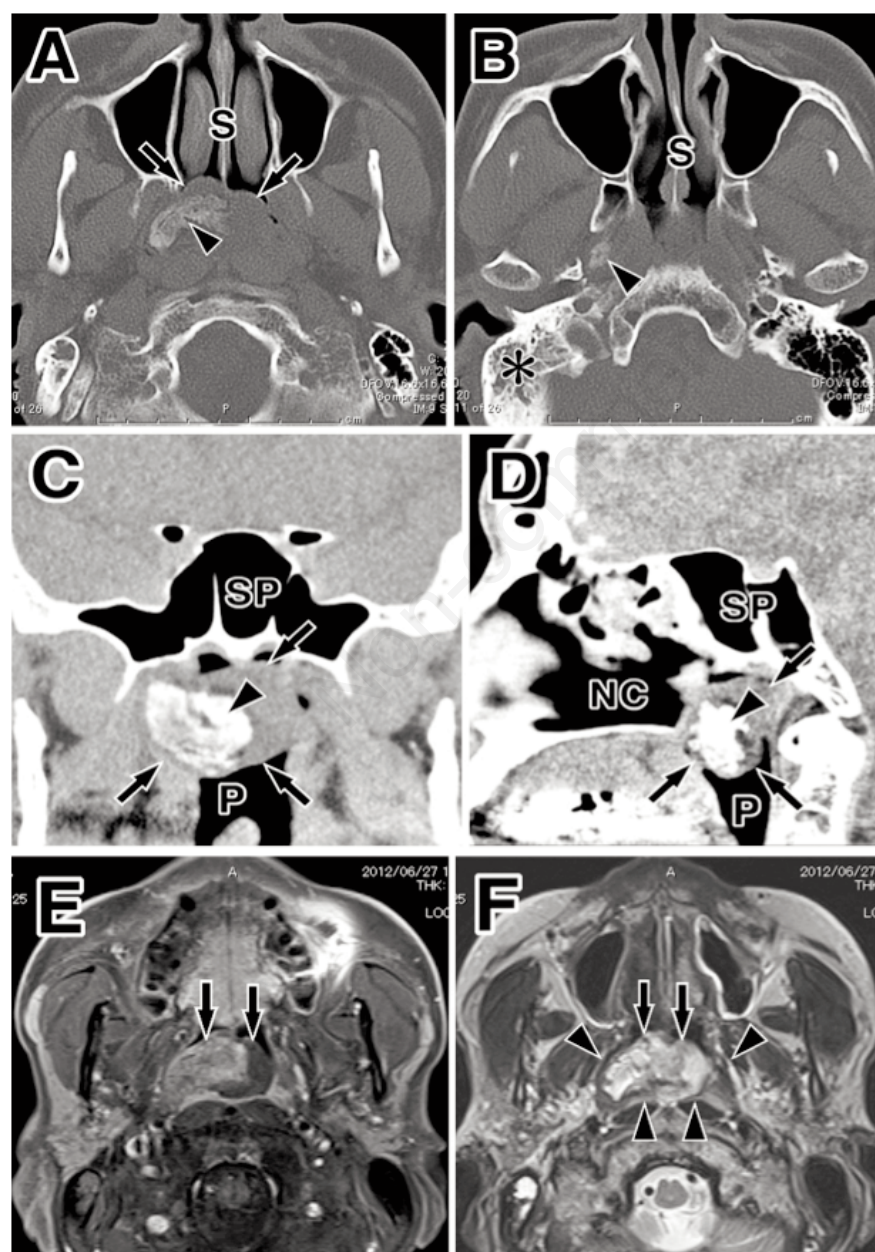
### Discussion

Tumors and tumor-like lesions in the nasopharynx cause symptoms of not only nasal obstruction but also aural fullness and/or conductive hearing loss due to insufficient of the ET. Therefore, in patients with unilateral SOM, differential diagnosis of any nasopharyngeal tumor is necessary. If tumor-like lesions are found, prompt pathological examination should be performed because malignant tumors, for example nasopharyngeal carcinoma or malignant lymphoma, can arise in this region.<sup>10</sup> Among 78 cases of tumor and tumor-like lesions in the ET reported over the last 123 years,<sup>1</sup> 29 (37%) contained malignancy, including melanoma,<sup>6</sup> carcinoma<sup>8</sup> and sarcoma.<sup>11</sup> In the present case, the patient was initially diagnosed as having a nasopharyngeal tumor at initial admission, and a biopsy examination yielded a diagnosis of fibroma.

Specific CT and MRI imaging characteristics are useful for differential diagnosis of any tumor in the nasopharyngeal region. Malignant lesions such as nasopharyngeal carcinoma frequently show bone destruction with involvement of the cavernous sinus, sphenoid sinus and/or skull base by CT, and infiltration with surrounding soft tissue by MRI.<sup>12</sup> Kim *et*



**Figure 1.** Preoperative fiberoptic appearance of the posterior nasal cavity (A), intraoperative nasopharynx (B) and postoperative nasopharynx (C; C inset is a different angle view showing the pharyngeal orifice of the Eustachian tube). Posterior nasal cavity and nasopharynx were filled with the tumor, which had a smooth surface (arrows). After the operation, most of the tumor was removed but a remnant was observed at the pharyngeal orifice of the Eustachian tube (arrowheads). S: nasal septum, T: torus tubarius, PW: posterior wall of the epipharynx, asterisk: pharyngeal orifice of the Eustachian tube.

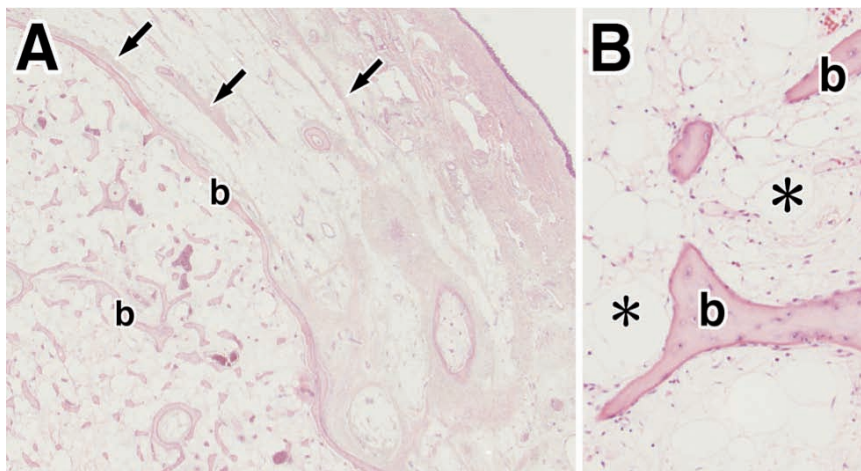


*al.*<sup>13</sup> described the imaging findings of malignant melanoma of the ET. In that report, CT revealed widening and erosion of the bony part of the ET. In the present patient, on the other hand, CT imaging demonstrated that the bulky mass occupied both the right ET and nasopharynx, but no bone destruction was evident in the surrounding palatine and sphenoid bones. MRI imaging demonstrated a smooth surface of the nasopharynx, suggesting absence of tumor infiltration, which is often seen in cases with a malignant pathology. CT and MRI imaging, however, demonstrated a heterogeneous component of the tumor with calcification, and therefore involvement of malignancy could not be completely ruled out. Endoscopic surgery for reduction of the tumor and accurate pathological diagnosis was thus indicated.

The final diagnosis of the present case was an osseous hamartoma and with no malignant features. A hamartoma is a focal malformation that resembles a neoplasm in the tissue of its origin, and the clinical manifestation of hamartoma in the head and neck region is always the same as that of a benign tumor. It is composed of tissue elements normally found at the site of origin, but which are growing in a disorganized mass, and most cases are asymptomatic. Wushou *et al.*<sup>14</sup> reported 194 patients with head and neck hamartomas, the most common affecting the oral mucosa (68.6%) and skin (27.3%). In other areas, hamartomas of the nasal septum, olfactory cleft, nasopharynx and larynx have been described, but their prevalence has been not accurately determined because the pathology varies and no statistical analysis has been carried out. Sumi *et al.*<sup>15</sup> reported that benign tumors in the nasopharynx which partially block the orifice of the ET do not influence tubal function. They also suggested that tubal function is influenced in cases of the infiltrating lesions, lesions lying in the lumen, or peritubal musculo-cartilaginous anomalies. In the present case, no symptoms were apparent until the tumor had grown to a

**Figure 2.** Computed tomography (CT) images in the axial plane (A, B; image A is 10mm caudal from image B), coronal plane (C) and sagittal plane (D), and magnetic resonance imaging (MRI) images in the axial plane (E; T1 enhanced image, F; T2 enhanced image). CT showed that a bulky mass occupied the nasopharynx (arrows) with a highly contrasted heterogeneous content (arrowheads in A, C and D) extending in the direction of the Eustachian tube (arrowhead in B). MRI showed that the tumor occupied the entire space of the nasopharynx (arrows in E and F) with a heterogeneous content that was enhanced in the T2 image. The nasopharyngeal mucosa was evident (arrowheads in F), and appeared to be preserved without tumor infiltration.





**Figure 3.** Pathological findings of the tumor using H-E staining in low- (A) and high- (B) magnification images. Bony tissue (b), fat cells (asterisks) and fibroblast (arrows) were frequently seen in the disorganized growing mass, but no invasive or dysplastic tumor cells were evident.

large, completely blocking the pharyngeal orifice or the lumen of the tube.

Because of the pathology of benign hamartoma and that the symptoms in the present case were resolved by partial resection and tympanostomy tube insertion, we have not planned total removal of the tumor at the time of writing. If the remnant tumor lying in the tube were to expand and cause neurological pain or palsy of the adjacent branches of the trigeminal nerve, additional surgery for reduction or total removal of the tumor from the ET lumen would be necessary. Endoscopic dissection from bilateral directions via the pharyngeal ostium and tympanic ostium, as described by Wang *et al.*,<sup>3</sup> or alternatively skull base surgery described by Sichel *et al.*,<sup>16</sup> should be considered according to the site and volume of the tumor.

## Conclusions

Hamartoma with osseous histology arising from the Eustachian tube is rare. CT and MRI findings were useful in the present case for showing that the tumor occupied the nasopharynx, had a smooth margin, and did not infiltrate

the mucosa of the nasopharynx, thus suggesting that it was benign in character. Because of the heterogeneous components of the tumor with calcification, however, involvement of malignancy was not completely ruled out. The final diagnosis was achieved by pathological examination. Endoscopic subtotal reduction of the tumor and tympanostomy tube insertion were useful for resolving the clinical symptoms, including nasal obstruction and aural fullness.

## References

1. Muzzi E, Cama E, Boscolo-Rizzo P, et al. Primary tumors and tumor-like lesions of the eustachian tube: a systemic review of an emerging entity. *Eur Arch Otorhinolaryngol* 2012;269:1723-32.
2. Wasinwong Y, Chaipasithikul S, Kanchanapitak P. Eustachian tube mature teratoma. *Otolaryngol Head Neck Surg* 2003;128:589-91.
3. Wang JL, Hou ZH, Chen L, et al. Combined application of oto-endoscopes and nasal endoscopes for resection of dermoid tumor in eustachian tube. *Acta Otolaryngol*

2011;131:221-4.

4. Takano K, Sato J, Shirasaki H, et al. Melanin pigmented oncocytic metaplasia of the nasopharynx. *Auris Nasus Larynx* 2004;31:161-3.
5. Ikeda K, Kikuta N, Sasaki Y, et al. Extracranial chondroma of the skull base. *Arch Otorhinolaryngol* 1987;243:424-8.
6. Tanaka H, Kohno A, Gomi N, et al. Malignant mucosal melanoma of the Eustachian tube. *Radiat Med* 2008;2:305-8.
7. Facer GW, Piepgras DG, Weiland LH, Mokri B. Unusual causes of unilateral serous otitis media. *Laryngoscope* 1980;90:1305-12.
8. Kim YH, Chae SW, Jung HH. Mucoepidermoid carcinoma arising from the Eustachian tube and middle ear. *J Laryngol Otol* 2003;117:202-4.
9. Hildyard VH, Compere WE Jr. Osteoma of the eustachian tube. *Laryngoscope* 1959;69:1524-7.
10. Weber AL, Rahemtullah A, Ferry JA. Hodgkin and non-Hodgkin lymphoma of the head and neck: clinical, pathologic, and imaging evaluation. *Neuroimaging Clin N Am* 2003;13:371-92.
11. Lin HC, Friedman M, Kuo FI, Huang HI. Synovial sarcoma of the Eustachian tube. *Head Neck* 2009;32:1245-8.
12. Chong VF, Fan YF, Khoo JB. Nasopharyngeal carcinoma with intracranial spread: CT and MR characteristics. *J Comput Assist Tomogr* 1996;20:563-9.
13. Kim HC, Jang HW, Lee HJ. Imaging finding of malignant melanoma of Eustachian Tube with extension to middle ear cavity: case report. *Korean J Radiol* 2012;13:812-5.
14. Wushou A, Liu W, Bai XF, et al. Clinical analysis of 194 cases of head and neck hamartoma. *Oral Surg Oral Med Oral Pathol Oral Radiol* 2013;115:299-303.
15. Sumi T, Tsunoda A, Shirakura S, Kishimoto S. Mechanical obstruction of the eustachian tube by the benign tumor of the parapharyngeal space does not cause otitis media with effusion. *Otol Neurotol* 2007;28:1072-5.
16. Sichel JY, Monteil JP, Elidan J. Skull base chondroma of extracranial origin. *Head Neck* 1994;16:578-81.