# Small atrial septal defect associated with heart failure in an infant with a marginal left ventricle

**Sandra D.K. Kingma,[1] Lukas A. Rammeloo,[1] Vladimir Sojak,[2] Jaroslav Hruda[1]**

**[1]Department of Pediatric Cardiology, VU University Medical Center, Amsterdam; [2]Department of Cardiothoracic Surgery, Leiden University Medical Center, the Netherlands**

## Abstract

Atrial septal defect (ASD) is usually asymptomatic in infancy, unless pulmonary hypertension or severe co-morbidity is present. We report a case of a 4-week-old infant with moderate-sized ASD, small patent ductus arteriosus (PDA), and a borderline sized left ventricle that developed heart failure. Despite the relatively small diameter of the ASD, this defect influenced the mechanism of heart failure significantly. After surgical closure of both PDA and ASD, the signs of pulmonary hypertension resolved and the patient developed a normal sized left ventricle. This report illustrates that the presence of a small ASD in combination with a marginal left ventricle may result in inadequate left ventricular filling, pulmonary hypertension and heart failure.

## Introduction

Atrial septal defect secundum (ASD) is a common cardiac malformation, with an incidence of about 2 per 100.000 live births. It is most often closed in childhood, by catheter implanted device or surgical intervention,[1] to prevent potential problems occurring later in adolescence or adulthood. Only rarely its closure needs to be undertaken already in early infancy.[2] Reasons for the need of treatment in infancy are reported to be severe symptoms associated with pulmonary hyperperfusion and hypertension,[3] often associated with pneumonia and lung hypoplasia,[4,5] prematurity with chronic lung disease or with other malformations such as omphalocele, congenital diaphragmatic hernia[6] or pulmonary vein stenosis.[5] The shunting through secundum ASD may become more obligatory if the left atrial emptying through the mitral ostium becomes obstructed as in case of enlarged coronary sinus,[7] obstructive mitral valve itself, or by impaired compliance of a borderline left ventricle.

## Case Report

A 4-week-old male infant presented to our department with tachypnea and pale cold skin. His weight was 3.2 kilograms. Except for an absent big toe and a clubfoot, no other dysmorphic features were present. The peripheral pulsations were normal. Clinical features of heart failure consisted of tachycardia and tachypnea with intercostal and subcostal retractions. The baby appeared dystrophic and pale. The second heart sound was loud; a systolic murmur grade 2/6 was audible along the left sternal border. The chest X-ray showed cardiomegaly with enlarged right atrium and right ventricle in combination with increased pulmonary vascular markings. Echocardiography demonstrated normal intracardiac anatomy; a moderate-sized central secundum ASD with a diameter of 6 mm (Figure 1). A left to right shunt through a 4 mm wide patent ductus arteriosus (PDA) was seen, with a low-pressure gradient between the aorta and pulmonary artery, suggesting pulmonary hypertension. All pulmonary veins entered the left atrium. The pulmonary venous flow was increased and preferentially pointing across the secundum ASD into the right atrium. The left ventricle was borderline, its apex being at the same level as the right ventricle (RV). Left ventricular (LV) end-diastolic dimension measured in long-axis projection appeared normal (18.7 mm, Z-score=-0.16), mitral valve annulus assessed in four-chamber view measured 10.1 mm (Z=-1.33) and was not restrictive. Aortic valve orifice measured 7.1 mm (Z=-0.93). The length of the LV was 33.8 mm, the RV length was 36.9 mm, and the LV/RV length ratio was 0.92. The right ventricle was largely dilated (Figure 2), the tricuspid valve annulus measured 13.3 mm (Z=+1.24) and pulmonary artery annulus 11.7 mm (Z=+1.75). The pulmonary artery branches were also dilated, right pulmonary artery measuring 9.8 mm (Z=+2.74).

The aortic arch appeared normal. Diuretic treatment was started and surgery was postponed. However, heart failure with pulmonary hypertension persisted for six weeks, and the baby had to undergo operation. Our echocardiographic findings were confirmed during surgery; and both PDA and secundum ASD were closed. Postoperative recovery was quick and pulmonary hypertension resolved. One year after operation, the LV had normal dimensions and both systolic and diastolic functions were normal. There were no clinical or echocardiographic signs of increased left atrial pressure. Genetic assessment revealed no abnormalities.

Correspondence: Jaroslav Hruda, Department of Pediatric Cardiology VU University Medical Center, De Boelelaan 1117, P.O. Box 7057, 1007 MB Amsterdam, The Netherlands.
Tel. +31204444444; Fax: +31204442422.
E-mail: j.hruda@vumc.nl

Key words: atrial septal defect, left ventricle size, pulmonary hypertension, infancy.

Contributions: SDKK, JH, conception and design, data acquisition, article drafting/revising, final approval; LAR, article drafting/revising; VS, article revising.

Conflict of interests: the authors declare no potential conflict of interests.

Received for publication: 11 March 2012.
Revision received: 4 June 2012.
Accepted for publication: 7 June 2012.

This work is licensed under a Creative Commons Attribution NonCommercial 3.0 License (CC BY-NC 3.0).

*©Copyright S.D.K. Kingma et al., 2012*
*Licensee PAGEPress, Italy*
*Clinics and Practice 2012; 2:e69*
*doi:10.4081/cp.2012.e69*

## Discussion

Large ASD is characterized by atrial left-to-right shunt leading to RV diastolic overload. In contrast, large PDA leads to volume overload of the left atrium and LV. In our patient with heart failure due to large PDA and a moderate-sized secundum ASD, one would expect predominant PDA hemodynamics, with an enlarged left heart, but the opposite was true. We explain this by decreased compliance of a borderline LV enabling the preferential shunting of a high volume of pulmonary venous blood across the atrial septum rather than into LV via the mitral valve. Because many small-to-moderate ASDs may close spontaneously, repair of PDA alone without cardiopulmonary bypass may be preferred. While planning the surgery in our patient it was difficult to differentiate to which extent the secundum ASD represented the primary cause of the symptoms or only being a desired decompression route from a high-pressure left atrium. This is a common situation in infants with aortic coarctation and secundum ASD, where factors influencing atrial shunt predisposing to heart failure are often present, including left ventricular, aortic or mitral valve hypoplasia. Schroeder *et al.*[8] have shown that mitral valve, but not aortic or left ventricular, size correlated with the development of heart failure and the need for ASD closure shortly

Non-commercial use only

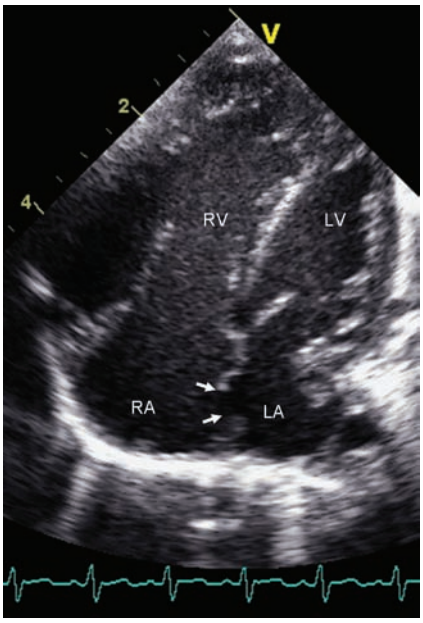


**Figure 1. Apical precordial four chamber view. Small secundum atrial septal defect (arrows), marginal left ventricle does not reach the apex. LA, left atrium; LV, left ventricle; RA, right atrium; RV right ventricle.**

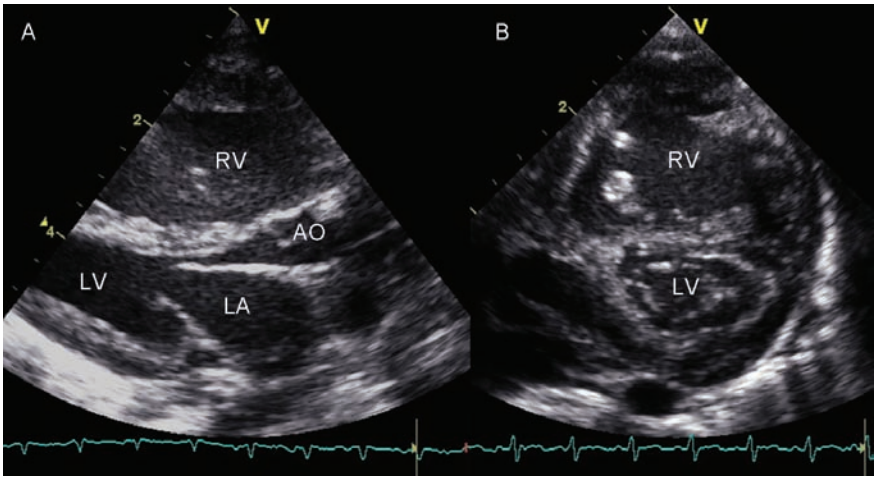


**Figure 2. Parasternal long-axis (A) and short-axis (B) view demonstrates marked right ventricular volume overload. AO, aorta; LA, left atrium; LV, left ventricle; RV, right ventricle.**

Non-commercial use only

after coarctation repair. The presence of aortic coarctation in the setting of an ASD, however, has not exactly the same hemodynamics. It represents a fixed left ventricular obstructive lesion and hence its effects may predominate. Jean-St-Michel *et al.*[9] demonstrated that eliminating the left-to-right shunt by closing the secundum ASD with a test balloon occlusion, in an infant with a marginal LV, forced blood through the mitral valve thus promoting LV filling. They observed that when blood was forced through the mitral valve, the left ventricle had the capacity to tolerate the extra volume.

## Conclusions

This report illustrates that in the patient with the major diagnosis of PDA, the presence of a moderate-sized ASD secundum in combination with a marginal LV may result in inadequate filling of this ventricle. ASD closure may contribute to a catch-up of LV growth.

## References

1. Kharouf R, Luxenberg DM, Khalid O, Abdulla R. Atrial septal defect: spectrum of care. Pediatr Cardiol 2008;29:271-80.
2. Bull C, Deanfield J, de Leval M, et al. Correction of isolated secundum atrial septal defect in infancy. Arch Dis Child 1981;56:784-6.
3. Groetschmann S, Di Bernardo S, Steinmann H, et al. Frequency of severe pulmonary hypertension complicating isolated atrial septal defect in infancy. Am J Cardiol 2008;102:340-2.
4. Dimich I, Steinfeld L, Park SC. Symptomatic atrial septal defect in infants. Am Heart J 1973;85:601-4.
5. Andrews R, Tulloh R, Magee A, Anderson D. Atrial septal defect with failure to thrive in infancy: hidden pulmonary vascular disease? Pediatr Cardiol 2002;23:528-30.
6. Lammers A, Hager A, Eicken A, et al. Need for closure of secundum atrial septal defect in infancy. J Thorac Cardiovasc Surg 2005;129:1353-7.
7. Postema P, Rammeloo LAJ, van Litsenburg R, Rothuis EGM, Hruda J. Left superior vena cava in pediatric cardiology associated with extra-cardiac anomalies. Int J Cardiol 2008;123:302-6.
8. Schroeder VA, Pearl JM, Beekman RH, et al. Usefulness of the mitral valve Z score in predicting the need to close moderate- to large-sized atrial septal defects in infants with aortic coarctation. Am J Cardiol 2003;92:480-3.
9. Jean-St-Michel E, Hosking MC, Potts JE, Sandor GG. Device closure of a secundum atrial septal defect in a 4-month-old infant with a marginal left ventricle following coarctation repair. Congenit Heart Dis 2007;2:442-5.