

A case of carcinoma of the male breast mimicking a mucinous carcinoma of the skin

Sumihisa Imakado,¹ Ryo Masuda²

¹Department of Dermatology and

²Department of Breast Surgery, Japanese Red Cross Medical Center, Tokyo, Japan

Abstract

The authors report a case of mucinous carcinoma of the male breast firstly diagnosed as a mucinous carcinoma of the skin. The immunohistochemical results of this tumor were as follows: cytokeratin7 (-), gross cystic disease fluid protein 15 (-), p63 (-), estrogen receptor (+), and progesterone receptor (+) for the primary nodule; cytokeratin7 (-), thyroid transcription factor-1 (-), gross cystic disease fluid protein 15 (-), p63 (-), cytokeratin8 (+), cytokeratin18 (+), and cytokeratin20 (+) for the recurrent nodule. The tumor cells had cytokeratin7 (-)/ cytokeratin20 (+) phenotype and it was very unusual for mucinous carcinoma of the breast.

Introduction

Histologic typing makes possible the breast carcinoma classification. There are 12 different types of breast cancer; among which infiltrating ductal carcinoma is the most common.¹ Mucinous carcinoma of the breast accounts for about 2% of breast carcinomas.¹ Since cancer of the male breast is about 100 times less common than cancer of the female breast,¹ mucinous carcinoma of the male breast should be very rare.²

The authors present a case of mucinous carcinoma of the male breast firstly diagnosed as a mucinous carcinoma of the skin.

Case Report

A 72-year-old Japanese man visited our hospital regarding a subcutaneous nodule on the left side of his chest (Figure 1) in October 2002. The nodule appeared 3 years before the visit. The nodule was excised, and pathological examination revealed a mucin-producing adenocarcinoma. In some parts, small cellular nests were floating on a pool of mucin (Figure 2). The tumor was negative for cytokeratin 7, gross cystic disease fluid protein 15 (GCDFP

Correspondence: Sumihisa Imakado, Department of Dermatology, Japanese Red Cross Medical Center, 4-1-22 Hiroo, Shibuya-ku, Tokyo, Japan. E-mail: sumihisa-imakado@triton.ocn.ne.jp

Key words: mucinous carcinoma of the skin, breast carcinoma.

Contributions: SI, manuscript preparing; RM, lymph node dissection.

Conflict of interests: the authors declare no potential conflict of interests.

Received for publication: 15 April 2012.

Revision received: 15 April 2012.

Accepted for publication: 20 May 2012.

This work is licensed under a Creative Commons Attribution NonCommercial 3.0 License (CC BY-NC 3.0).

©Copyright S. Imakado and R. Masuda, 2012

Licensee PAGEPress, Italy

Clinics and Practice 2012; 2:e61

doi:10.4081/cp.2012.e61

15), and p63, but positive for estrogen and progesterone receptors (Figure 3). The tumor did not show any evidence of apocrine-type decapitation secretion. No mammary duct

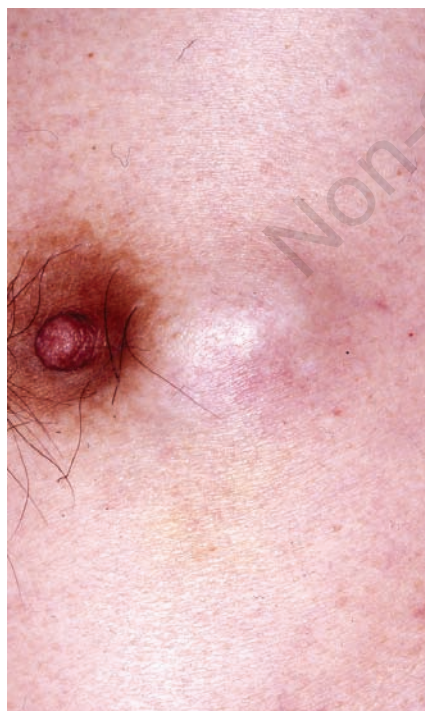

Figure 1. A subcutaneous nodule on the left side of the male patient's chest.

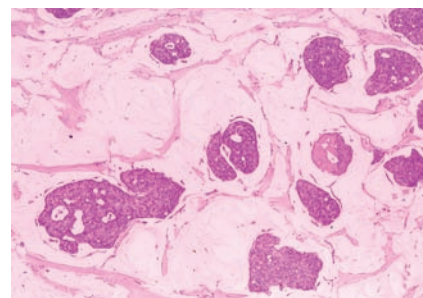
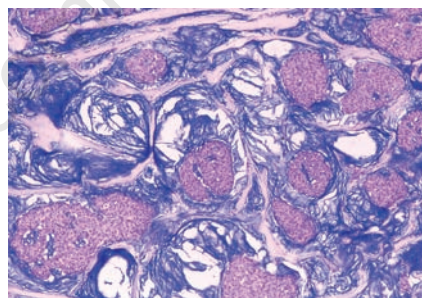


Figure 2. (Right panel) Islands of basaloid cells surrounded by amorphous materials (H&E, original magnification $\times 40$). (Left panel) Alcian blue staining of the mucin is positive ($\times 40$).

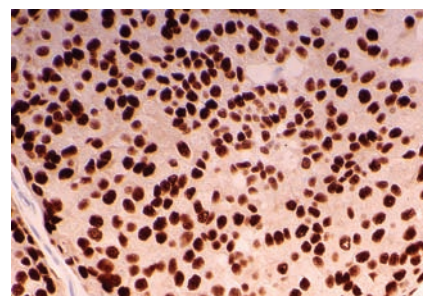
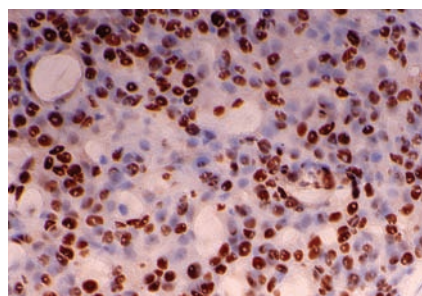


Figure 3. Tumor cells are positive for estrogen receptor (left panel, original magnification $\times 100$) and for progesterone receptor (right panel, $\times 100$).

component was observed in and around the tumor. Clinical examinations and systemic investigations including chest- and abdominal-computed tomographies failed to detect any primary lesion elsewhere. Therefore, the final pathological diagnosis was primary mucinous carcinoma of the skin. About 3 years later, the patient returned with a recurrent nodule on the left side of his chest; this time, wide local excision and skin grafting were done in July 2005. The pathological findings of the recurrent nodule were the same as the original lesion and the tumor cells were positive for cytokeratin (CK)8, CK18 and CK20, but negative for CK7, thyroid transcription factor-1 (TTF-1), GCDFP 15, and p63. Lymph node dissection was not performed, because primary mucinous carcinoma of the skin only rarely metastasizes to regional lymph nodes.³ However, two years after the wide local excision, left axillary lymph node enlargement became evident, and axillary dissection was done in June 2007. The tumor cells of the dissected lymph nodes also had mucinous stroma and were positive for estrogen and progesterone receptors. By that time, we reconsidered and diagnosed this case as a mucinous carcinoma of the male breast. The patient was started on endocrine therapy using tamoxifen and has had no evidence of metastasis to date.

Discussion

We presented here a case of mucinous carcinoma of the male breast firstly diagnosed as a mucinous carcinoma of the skin, then recurred at the primary site three years later after a simple excision, and then metastasized to the regional lymph nodes. Since the histologic and immunohistochemical features overlap between primary mucinous carcinoma of the skin and mucinous carcinoma of the breast, differential diagnosis between these tumors

can be sometimes very difficult. According to the literature, three-quarters of cases of mucinous carcinoma of the skin were found on the head, where they occurred mostly in the periorbital skin, while only 2% of mucinous carcinomas occurred on the chest.⁴ The present tumor also had to be differentiated from metastasis from mucinous adenocarcinoma of other sites. It was finally diagnosed as a primary mucinous carcinoma of the male breast based on the primary site, and because no other primary malignancy could be found even after 10-years' follow-up.

The immunohistochemical results of this tumor were as follows: CK7 (-), GCDFP 15 (-), p63 (-), estrogen receptor (+), and progesterone receptor (+) for the primary nodule (Figure 3); CK7 (-), TTF-1 (-), GCDFP 15 (-), p63 (-), CK8 (+), CK18 (+), and CK20 (+) for the recurrent nodule. CK7 expression has been extensively examined in various epithelial neoplasms.⁵ In previous studies, not only most breast carcinomas but also most mucinous carcinomas of the skin were positive for CK7.^{6,7} Since the present tumor was consistently negative for CK7, it is very unusual. Although the present tumor was weakly positive for CK20, the overall characteristics were different from Merkel cell carcinomas. A possibility of mucinous carcinoma of the intestine, usually having CK7 (-)/ CK20 (+) phenotype,⁷ was ruled out, because no abnormal mass was found by abdominal computed tomography and because only atrophic gastritis and colon polyp were found by endoscopic examinations during the follow-up period. Despite extensive immunohistochemical comparison, we concluded that the histopathologic findings were quite similar between mucinous carcinoma of the breast and primary mucinous carcinoma of the skin. Since systemic investigations conducted at our hospital failed to detect any primary carcinomas elsewhere, and the primary site of this case was just near the nipple, this case was finally diagnosed as a mucinous carcinoma of the breast.

Since clinical behavior and treatment strategy are different between mucinous carcinoma of the breast and primary mucinous carcinoma of the skin, we should be very careful to make a correct diagnosis.

References

1. Dullmann J, Wulfhekel U. Breast. In: Dullmann J, Wulfhekel U, editors. *Human Oncology. Pathology and Clinical Characteristics*. Baltimore, MD: Urban & Schwarzenberg; 1988. pp. 903-995.
2. Burga AM, Fadare O, Lininger RA, et al. Invasive carcinomas of the male breast: a morphologic study of the distribution of histologic subtypes and metastatic patterns in 778 cases. *Virchows Arch* 2006;449:507-12.
3. Breiting L, Dahlstrom K, Christensen L, et al. Primary mucinous carcinoma of the skin. *Am J Dermatopathol* 2007;29:595-6.
4. Snow SN, Reizner GT. Mucinous eccrine carcinoma of the eyelid. *Cancer* 1992;70:2099-104.
5. Chu P, Wu E, Weiss LM. Cytokeratin 7 and cytokeratin 20 expression in epithelial neoplasms: a survey of 435 cases. *Mod Pathol* 2000;13:962-72.
6. Van Dorst EBL, Van Muijen GNP, Litvinov SV, et al. The limited difference between keratin patterns of squamous cell carcinomas and adenocarcinomas is explicable by both cell lineage and state of differentiation of tumour cells. *J Clin Pathol* 1998;51:679-84.
7. Kazakov DV, Suster S, LeBoit PE, et al. Mucinous carcinoma of the skin, primary, and secondary. A clinicopathologic study of 63 cases with emphasis on the morphologic spectrum of primary cutaneous forms: homologies with mucinous lesions in the breast. *Am J Surg Pathol* 2005;29:764-82.