surgical techniques development

MDPI

Technical Note

Direct Anatomical Reconstruction of the Achilles Tendon and Its Application for Surgical Treatment of Acute Achilles Tendon Ruptures

Alessandro Pisano and Gaetano Caruso *

Department of Neurosciences and Rehabilitation, "S. Anna" University Hospital, University of Ferrara, Via Aldo Moro 8, 44124 Ferrara, Italy; alessandro.pisano@edu.unife.it
* Correspondence: crsgtn@unife.it

Abstract: Background/Objectives: Acute ruptures of the Achilles Tendon (AT) are common injuries in the active population, in particular among men aged 30 to 50. Full functional recovery after this kind of injury is long and challenging and nowadays there is no universal "gold standard" strategy when dealing with them. **Methods:** When it comes to surgical treatment, various techniques have been described: in case of a typical lesion at the midportion of the tendon (which is the most common type), the basic principle of surgical repair is the end-to-end suture of the tendon stumps. The AT ("calcaneal tendon" according to the *International Anatomical Terminology*) is the strongest tendon of the human body, it is the conjunct tendon of the two Gastrocnemii Muscles and the Soleus Muscle and has a **well-recognizable twisted structure**: the subtendon from the Medial Head of the Gastrocnemius attaches postero-laterally on the calcaneal tendon footprint, the subtendon from the Lateral Head of the Gastrocnemius attaches antero-laterally and the subtendon from the Soleus attaches medially, therefore creating a 90° twist of the tendon structure. **Results: the twisted structure of the human AT is of central importance to its biomechanics**, since it gives the tendon a higher resistance to deformation and concurs in supination of the subtalar joint during gait. **Conclusions:** given the abovementioned anatomical and biomechanical premises, we believe that the restoration of the subtendons anatomy can lead to a better functional recovery of the Triceps Surae—Achilles Tendon complex, therefore we recently decided to adopt for open surgical repair the Direct Anatomical Reconstruction of the Achilles Tendon, which we describe in the present article.

Keywords: achilles tendon; achilles tendon rupture; calcaneal tendon; open achilles tendon repair; triceps surae

check for updates

Citation: Pisano, A.; Caruso, G. Direct Anatomical Reconstruction of the Achilles Tendon and Its Application for Surgical Treatment of Acute Achilles Tendon Ruptures. *Surg. Tech. Dev.* **2024**, *13*, 382–392. https://doi.org/10.3390/std13040030

Academic Editor: Egidio Riggio

Received: 13 September 2024
Revised: 31 October 2024
Accepted: 20 November 2024
Published: 23 November 2024

Copyright: © 2024 by the authors. Licensee MDPI, Basel, Switzerland. This article is an open access article distributed under the terms and conditions of the Creative Commons Attribution (CC BY) license (https://creativecommons.org/licenses/by/4.0/).

1. Introduction

Achilles Tendon (AT) complete tears are serious injuries that hinder patients' quality of life and need proper treatment in order to restore the anatomy, mechanical properties and function of the Triceps Surae—AT complex. In the vast majority of cases, AT ruptures involve the mid-portion of the tendon: those are called "typical" ruptures; ruptures at the muscle-tendon junction or at the calcaneal tuberosity are rarer; complex rupture patterns like "Z-shaped" and "double layer" ruptures can also be found among AT ruptures [1].

It is currently of debate whether the first line of treatment should be surgical or non-surgical and there are no official guidelines nor universally recognized "gold standard" approaches [2,3], but especially in patients with high functional demand surgery reduces the re-rupture risk and allows for a better recovery of plantar flexion strength compared to non-surgical management [4,5].

Several surgical techniques have been developed throughout the years; hereby we describe an open surgical approach, the so-called "direct anatomical reconstruction" (or "lace technique" as originally described by the Swiss surgeon Bernhard Segesser [6]), its anatomical and biomechanical rationale and its application for acute AT ruptures.

2. Anatomy

2.1. The Triceps Surae—Achilles Tendon—Calcaneal Tuberosity Complex

The Achilles Tendon (or "calcaneal tendon" according to the *International Anatomical Terminology*) is the conjunct tendon of the two Gastrocnemii Muscles (the Medial Gastrocnemius, MG, and the Lateral Gastrocnemius, LG) and the Soleus Muscle (SM): this three-headed muscle complex is located in the superficial posterior compartment of the leg and is known as *Triceps Surae* (from the Latin, "*Tres capita*": *Three heads*; "*Sura, -ae*": *Calf*); the Triceps Surae is the main ankle plantarflexor muscle and contributes also to supination of the subtalar joint during gait; the AT results from the fusion of the Soleus posterior aponeurosis and the Gastrocnemius aponeurosis [7].

The AT measures about 15 cm in length (range 11–26) [8], it is flat at its origin at the level of the fusion of the SM and Gastrocnemii aponeurosis, it becomes more rounded in its midsection, where a twist of the fibers can be observed, then its fibers spread at the level of the insertion on the calcaneal tuberosity. According to the Chan classification we can divide the AT into three different portions (listed from proximal to distal) [8]:

- Intramuscular
- Free tendon (where the fibers twist)
    - o Proximal
    - o Middle (midportion or midsubstance)
    - o Distal (pre-insertional)
- Calcaneal

As already stated, **the AT has a well recognizable twisted structure**: the subtendon from the Medial Gastrocnemius (MG) attaches postero-laterally on the calcaneal tuberosity, the subtendon from the Lateral Gastrocnemius (LG) attaches antero-laterally and the subtendon from the Soleus Muscle (SM) attaches medially, therefore creating a 90° twist of the tendon structure (from a posterior view, this twist looks clockwise on the left AT calcaneal footprint and anti-clockwise on the right foot) (Figure 1) [9]. **Such twisted structure is fundamental for the biomechanics of the AT**, since it gives the tendon a higher resistance to deformation and concurs in the subtalar joint supination moment arm [10,11].

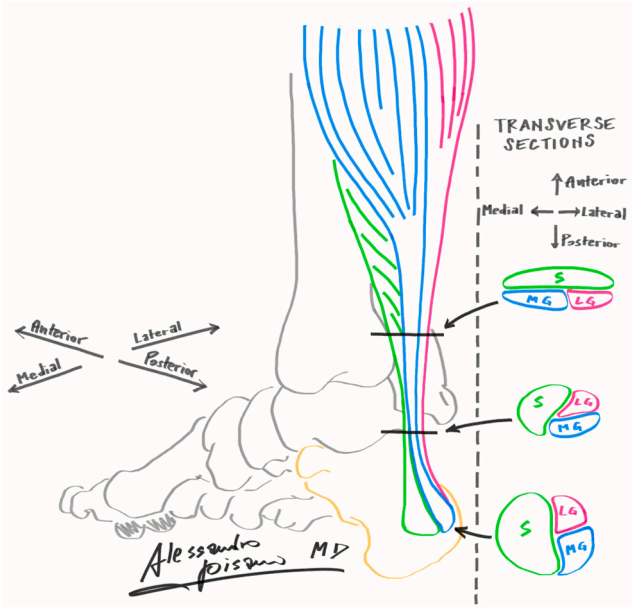

Figure 1. Original drawing from one of the authors of the article. Schematics of the 90° twist of the Achilles Tendon fibers (Soleus = Green; Medial Gastrocnemius = Blue; Lateral Gastrocnemius = Purple; Calcaneus = Yellow) with the relative contribution of each Muscle (in about 52% of the population, the Soleus alone is responsible for more than 50% of the AT fibers).

In about 90% of the population [7] the Plantaris Muscle (PM) with its long, thin tendon is present and participates to the Triceps Surae—Achilles Tendon—Calcaneal tuberosity complex: this small muscle (whose belly ranges 5 to 12 cm in length [7]) originates from the posterior aspect of the lateral femoral condyle, arising proximal and medial to the origin of the LG, runs medially crossing the posterior aspect of the knee and then, at the origin of the SM, from the PM belly arises a long, thin tendon (about 25–35 cm long) that attaches on the calcaneal tuberosity, antero-medially to the AT footprint [7]. From a surgical point of view, the PT can be used as an autograft for biological and mechanical augmentation when performing an AT repair (as we describe later is this article).

2.2. Vascularization

2.2.1. Blood Supply to the Achilles Tendon

The posterior compartment of the leg is crossed medially by the Posterior Tibial Artery (PTA) and laterally by the Peroneal Artery (PA). Vessels in the AT run longitudinally, transversely, and deeply [12]. The proximal and distal portions of the tendon are supplied by the PTA, while the PA supplies the central, twisted portion of the tendon [8,12]. Furthermore, the anterior (ventral) surface of the tendon is more vascularized than the posterior (dorsal) [12]. The blood supply to the AT decreases with aging [8]. The uneven distribution of the vascularization and the decrease of blood supply with aging are believed to be among the most important pathophysiological factors contributing to the genesis of ruptures at the midportion of the AT.

2.2.2. Blood Supply to the Skin of the Posterior Aspect of the Distal Leg

In the skin region covering the AT three vascular zones can be identified: a medial zone, a posterior (central) zone, and a lateral zone [12,13]. The medial and lateral zones have a richer vascular supply than the posterior (central) zone, which has the poorest blood supply. Therefore, it is advisable to avoid central surgical incision when performing an AT repair to avoid wound healing complications; since posterolateral incisions carry the risk of iatrogenic damage to the sural nerve, many surgeons adopt a posteromedial surgical incision when performing an open AT repair.

2.3. Innervation

The AT is innervated mainly by fibers of the Sural Nerve (SN), which also innervates the skin of the distal posterolateral leg and the lateral aspect of the foot.

The SN is formed at the middle third of the leg by the union of the medial sural nerve (a branch of the Tibial Nerve) and a branch of the Common Peroneal Nerve. At 8–10 cm proximally from the superior border of the calcaneus, the SN runs parallel to the lateral margin of the AT, thus being at risk of iatrogenic damage during percutaneous repair of the AT [7].

The Tibial Nerve (TN) innervates the Triceps Surae and gives a small contribution to the innervation of the AT [7].

3. Surgical Technique

Hereby we proceed at describing our approach for the Direct Anatomical Reconstruction of the AT.

The patient is positioned prone. We usually perform this procedure under spinal anesthesia with the use of a tourniquet on the thigh; alternatively, sciatic nerve block in the popliteal fossa or general anesthesia are two valid options.

3.1. Surgical Access and Exposure of the Lesion

A postero-medial incision about 8–12 cm long is used to expose the paratenon and the tendon lesion. The stumps of the three subtendons and the location of the lesions are identified.

3.2. Harvesting of the Plantaris Tendon

If present, the Plantaris Tendon (PT) is exposed (Figure 2) and stripped with the use of an open tendon stripper; the stripper is inserted on the distal (calcaneal) end of the PT and moved proximally to the PM muscle-tendon junction; if performed correctly, the entire PT in its full length can be harvested; **care is to be taken in maintaining the distal end of the tendon attached to the calcaneal tuberosity** and it is also recommended to perform good tissue separation by blunt dissection before stripping the PT. After stripping, the PT is rolled into a compress soaked with saline solution and left temporarily aside.

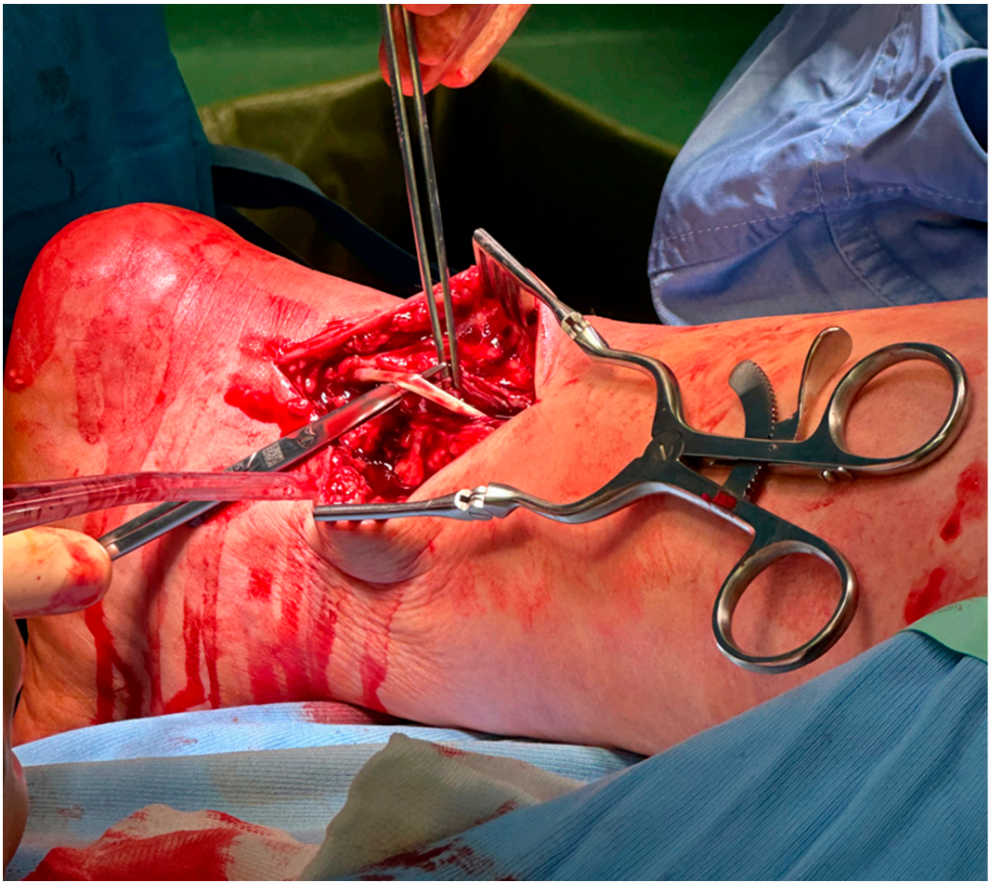

Figure 2. The Plantaris Tendon is exposed before stripping (the procedure shown in the picture is being carried out on a left foot).

3.3. End-to-End Tenorrhaphy of the Tendon Stumps

After assessment of the lesion pattern (transverse, double layer, Z-shaped, multi-stage, etc.) and identification of **the stumps** of the three subtendons (Figure 3), those **are repaired in order from the deepest to the most superficial**: the first step is the end-to-end tenorrhaphy of the SM subtendon, then we proceed to tenorrhaphy of the LG subtendon and finally we address the MG subtendon.

Non-absorbable or absorbable suture threads can be used, depending on the surgeon's preference; in our case we usually use #0 FiberWire (Arthrex). In our approach to this technique, we perform in the majority of cases a Krackow suture on the SM subtendon and on the MG subtendon (Figure 4), and a Kessler suture on the LG subtendon.

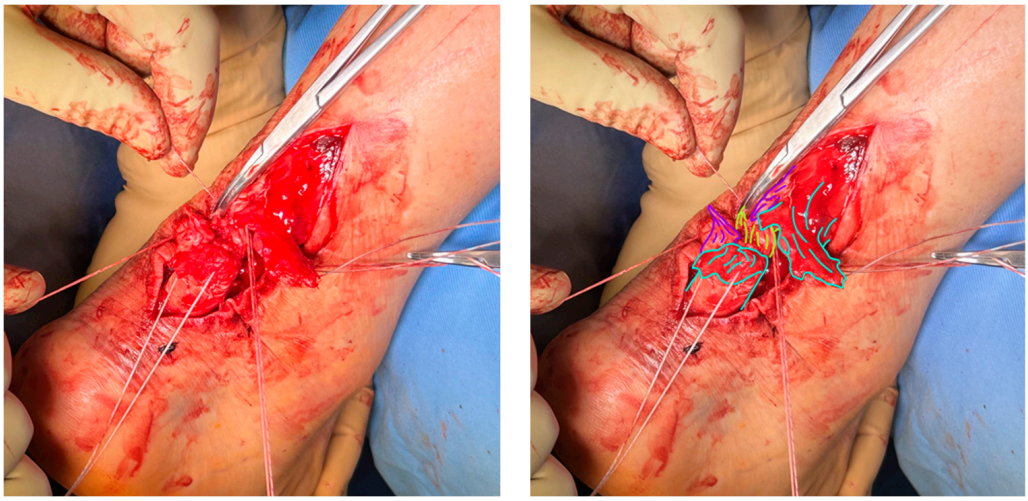

(**a**) (**b**)

Figure 3. A left AT is shown in these figures. (**a**): the three subtendons are identified and prepared with suture threads and clamps. (**b**): schematics of the three subtendons (Purple: LG; Light Green: SM; Light Blue: MG).

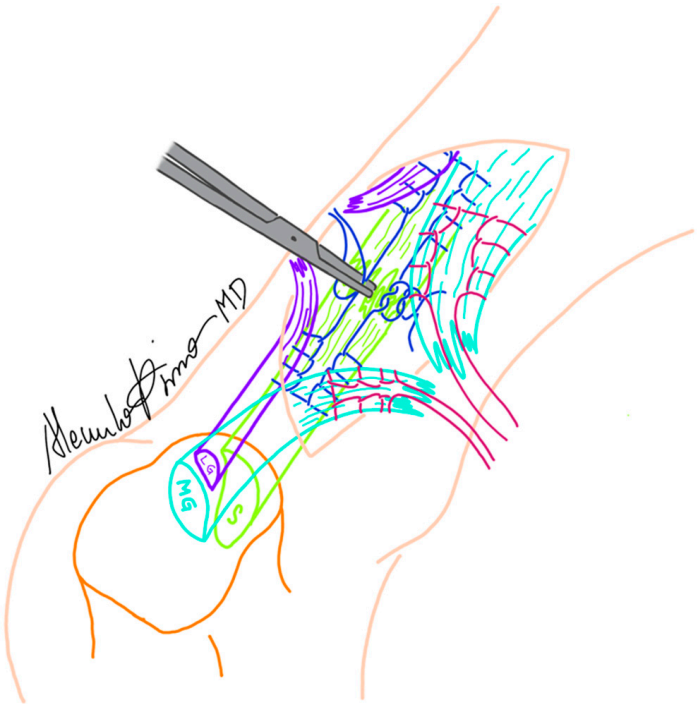

Figure 4. Original drawing from one of the authors of the article. Schematics of the tenorrhaphy seen in Figure 3: the stumps of the SM subtendon (Light Green) are being repaired, the stumps of the MG subtendon have been prepared with suture threads in a Krackow locking suture fashion. On the calcaneus is shown the twist of the three bundles at the level of the AT footprint (MG goes postero-lateral, LG goes antero-lateral, SM goes medial).

At the end of the tenorrhaphy, we test the integrity of the repair with a Thompson test, and if it results negative, we go ahead with the next step.

3.4. Mechanical and Biological Augmentation with the Autologous PT

After end-to-end tenorrhaphy of the three subtendons, the previously stripped autologous PT is passed inside the proximal AT stump with a curved mosquito clamp, the same passage is repeated in the distal stump to create a box-frame construct (Figure 5); the free end of the PT is then expanded by hand manipulation (Figure 6) and sutured with #3-0 Vycril (Ethicon) over the lesion site (Figure 6) in order to replace the paratenon, avoid adhesion formation and promote revascularization.

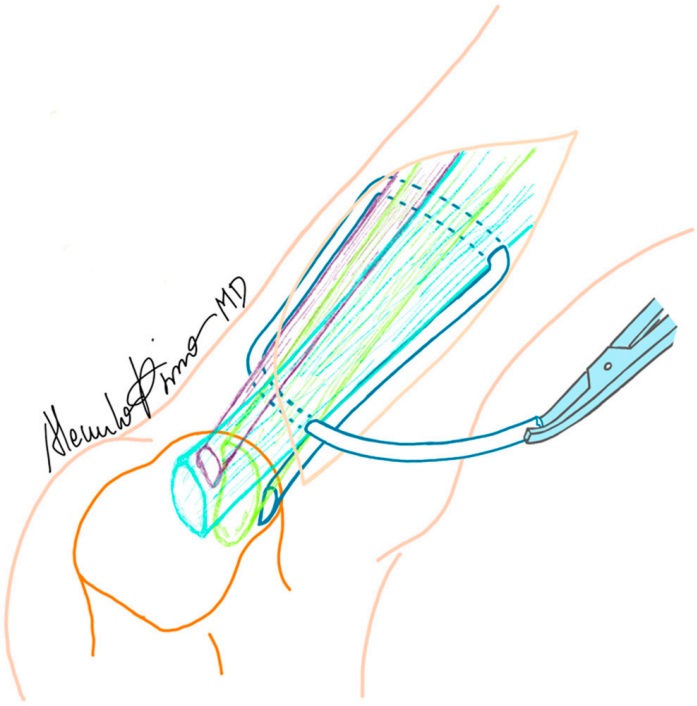

Figure 5. Original drawing from one of the authors of the article. After restoration of the native tendon twist, a box-frame augmentation with the autologous PT is carried out.

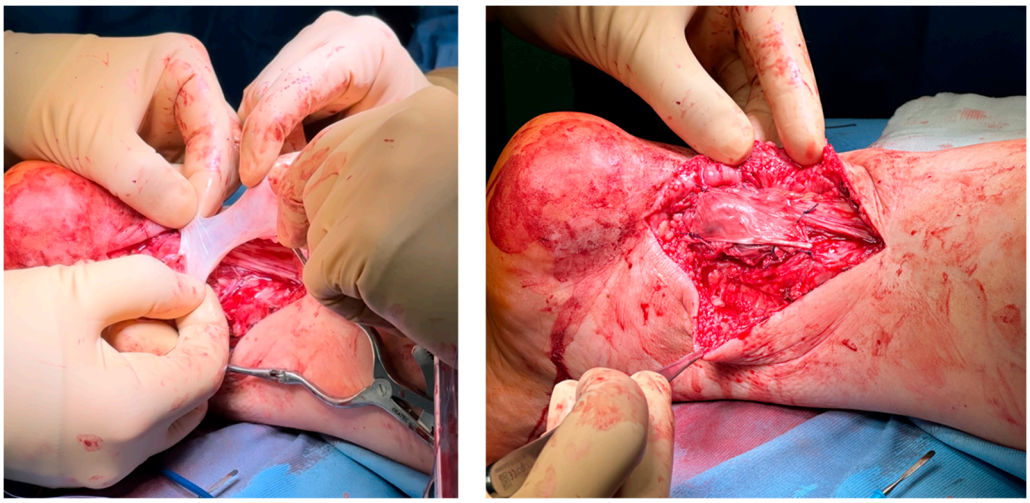

Figure 6. The free end of the PT is expanded by hand manipulation (picture on the left) and sutured over the lesion site to create a biological augmentation and enhance tendon healing (picture on the right).

3.5. Wound Closure

The subcutaneous tissue is sutured with #2-0 Vycril (Ethicon) and the skin is closed with a **running suture** with #2-0 Prolene (Ethicon) (Figure 7); steri-strips are used to cover

the skin suture, then the leg and foot are placed into a partial anterior cast in 30° of plantar flexion.



Figure 7. Running suture over the posteromedial incision.

3.6. Treatment of Complex Lesions with the Direct Anatomical Reconstruction

This surgical approach based on the native twisted anatomy of the AT is of great help in case of complex lesions. We report as an example a multi-stage lesion with distal detachment from the calcaneal tuberosity of the MG subtendon and rupture over the midsubstance of the SM and LG bundles.

In this case, we performed a Krackow suture for the SM subtendon and the LG subtendon, while the MG subtendon was reattached on its distal insertion on the calcaneal tuberosity with a 5 mm titanium anchor (Figures 8 and 9). In this patient the PT was absent (the PM and its tendon are not found in about 8–10% of patients [7]).



Figure 8. Intraoperative picture of a complex AT rupture (left AT).

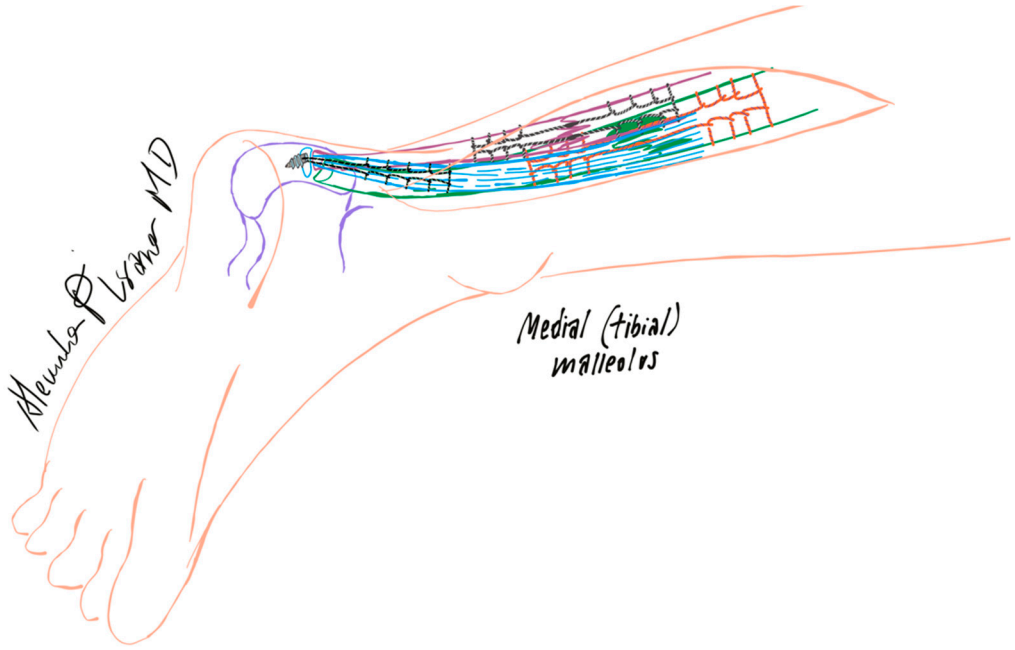

Figure 9. Original drawing from one of the authors of the article. Krackow repair of the SM (Green) and the LG (Purple) bundles and anchor reattachment on the calcaneal tuberosity of the MG subtendon (Light Blue).

4. Aftercare

Right after the procedure the leg and foot are placed in a partial anterior cast in 30° of ankle plantarflexion. Regular wound care is performed in an outpatient setting every 5–7 days and the skin suture is removed after 15–18 days from the procedure.

Every patient in our Unit who is treated for an Achilles Tendon rupture (including those who are treated with the anatomical reconstruction) receives a rehabilitation protocol based upon the patient's goals and the characteristics of the lesion: said protocol consists of a timeline with guidelines and specific goals and functional recovery criteria; using such guidelines and criteria, the sports rehabilitation team creates then a personalized rehabilitation program.

According to the basic version of our rehabilitation protocol, the patient stays non-weightbearing for the first 3 post-operative weeks (under DVT prophylaxis with LMWH if no contraindications nor previous anticoagulation therapy subsist); after 3 weeks, progressive weightbearing in a walker-type orthosis (with heel wedges to maintain the ankle in 30° of plantarflexion) is started, and the patient is encouraged to begin physical therapy as soon as possible. The orthosis is worn for a total of 7 weeks, with progressive removal of the heel wedges. After removal of the orthosis (which means 10 weeks after the procedure) the patient wears for the next 8 weeks a dedicated AT compressive bandage (e.g., AchilloTrain, Bauerfeind) with one heel cushion under both feet in sneaker-type shoes. 15 weeks after the procedure, active ankle dorsiflexion and gentle, progressive stretching of the TS—AT complex are allowed. 4 months after the procedure, functional and sports-specific rehabilitation is carried forward accordingly to the patient's goals.

We assess our patients post-operatively at 3 weeks, 7 weeks, 10 weeks, 18 weeks (4 months), 6 months and 9 months post-operatively. Among the many parameters, we take particular attention in measuring the Achilles Tendon Resting Angle (ATRA) to monitor tendon elongation [14,15] and, at 4, 6 and 9 months postoperatively, we assess the Achilles Tendon Total Rupture Score to evaluate patients' quality of life and return to their previous activities [16].

Since we adopted this technique very recently, by the time this article is being written only two patients operated with this technique have been followed up for at least 6 months. Patient #1 (male, 36 y.o., assembly line worker) showed an ATRA of 40° 25 days after the procedure and 54° by the time of the 6 months post-op control, while the ATRS was 63/100 by the 4 months post-op control and 80/100 by the 6 months post-op control. Patient #2 (male, 63 y.o., freelance event photographer) showed an ATRA of 45° 20 days after the procedure and 56° by the time of the 6 months control, while the ATRS was 60/100 by the 4 months post-op control and 81/100 by the 6 months post-op control.

The increase of the ATRA in both patients concurs with what is already described in the literature regarding a certain physiological degree of AT elongation following surgical repair [17].

5. Discussion

At the current state of knowledge, there's no universal "gold standard" strategy when dealing with complete ruptures of the Achilles Tendon. Considering the surgical management of these lesions, no technique has been proved to be significantly, uncontrovertibly better than the others.

While percutaneous techniques decrease the risk of wound-related complications, they also expose the patient to higher risk of iatrogenic injury to the Sural Nerve [7,18] and, depending on the technique, slightly higher risk ok re-rupture compared to open surgical techniques [19]. Furthermore, with a percutaneous approach it is highly difficult to assess and properly treat multi-stage and complex lesions.

The idea of a multi-bundle open repair of the AT has already been proposed by other authors under the concept of a "triple bundle repair" [20–22]; this technique has been proved of having a great resistance to load under tension, and the principle of a three-bundle repair is present as well in the technique that we described in the present article.

A retrospective study on a cohort of 25 patients from Mauch et al. assessed the functional recovery of the TS—AT complex after 18 and 26 weeks following Direct Anatomical Reconstruction of the AT, showing satisfactory functional outcomes regarding plantar flexion strength and ankle stability 6 months after the repair [23].

We suppose that the restoration of the native twist of the three subtendons plays a role in restoring the native biomechanics of the AT, since it has been proved that each one the three subtendons has different mechanical properties [24].

6. Conclusions

The Direct Anatomical Reconstruction of the Achilles Tendon is a reliable technique for open surgical treatment of AT lesions. It restores the native anatomy of the calcaneal tendon, it is suited for complex, multi-stage and asymmetrical lesions and provides, according to the preliminary results of our recent experience as well as previous literature, good clinical and functional outcomes.

We recommend therefore the adoption of this technique as a supplementary tool for the orthopedic and trauma surgeon; the post-operative rehabilitation should be, when possible, based on an early functional rehabilitation program.

Author Contributions: A.P. writing and original draft preparation, G.C. Conceptualization, review and editing. All authors have read and agreed to the published version of the manuscript.

Funding: This research received no external funding.

Institutional Review Board Statement: The study did not require ethical approval. The manuscript concerns the description of a surgical procedure (technique notes) used for reconstruction of the Achilles tendon after injury. This type of description does not require ethics committee approval because it is not a prospective or retrospective experimental study but a surgical technique that is part of normal surgical practice but perhaps not known by everyone. At my institution, it is not necessary to receive ethics committee approval to choose which surgical procedure to use to manage a clinical case. That is why that this type of study does not require ethics committee approval.

Informed Consent Statement: Written informed consent was obtained from the patient(s) for the publication and anonymous use of the intraoperative photographic images in this article.

Data Availability Statement: The data presented in this study are available on request from the corresponding author. The data are not publicly available due to ethical restrictions.

Conflicts of Interest: The authors declare no conflicts of interest.

References

1. Kage, T.; Sanada, T.; Iwaso, H.; Goto, H.; Fukai, A.; Yamagami, R.; Honda, E.; Uchiyama, E. Morphology of Acute Achilles Tendon Rupture by Intraoperative Evaluation. *J. Foot Ankle Surg.* **2021**, *60*, 1198–1203. [CrossRef] [PubMed]
2. Dams, O.C.; van den Akker-Scheek, I.; Diercks, R.L.; Wendt, K.W.; Zwerver, J.; Reininga, I.H.F. Surveying the management of Achilles tendon ruptures in the Netherlands: Lack of consensus and need for treatment guidelines. *Knee Surg. Sports Traumatol. Arthrosc.* **2019**, *27*, 2754–2764. [CrossRef] [PubMed]
3. Deng, S.; Sun, Z.; Zhang, C.; Chen, G.; Li, J. Surgical Treatment versus Conservative Management for Acute Achilles Tendon Rupture: A Systematic Review and Meta-Analysis of Randomized Controlled Trials. *J. Foot Ankle Surg.* **2017**, *56*, 1236–1243. [CrossRef] [PubMed]
4. Mullaney, M.J.; McHugh, M.P.; Tyler, T.F.; Nicholas, S.J.; Lee, S.J. Weakness in End-Range Plantar Flexion after Achilles Tendon Repair. *Am. J. Sports Med.* **2006**, *34*, 1120–1125. [CrossRef] [PubMed]
5. Möller, M.; Lind, K.; Movin, T.; Karlsson, J. Calf muscle function after Achilles tendon rupture: A prospective, randomised study comparing surgical and non-surgical treatment. *Scand. J. Med. Sci. Sports* **2002**, *12*, 9–16. [CrossRef]
6. Weisskopf, L.; Hirschmüller, A. Lace Technique Modified by Segesser and Weisskopf. In *The Achilles Tendon, an Atlas of Surgical Procedures*, 1st ed.; Thermann, H., Becher, C., Carmont, M.R., Karlsson, J., Maffulli, N., Calder, J., van Dijk, C.N., Eds.; Springer: Berlin/Heidelberg, Germany, 2017; pp. 21–25.
7. Dalmau-Pastor, M.; Fargues-Polo, B., Jr.; Casanova-Martínez, D., Jr.; Vega, J.; Golanó, P. Anatomy of the Triceps Surae: A pictorial Essay. *Foot Ankle Clin. N. Am.* **2014**, *4*, 603–635. [CrossRef]
8. Del Buono, A.; Chan, O.; Maffulli, N. Achilles Tendon: Functional anatomy and novel emerging models of imaging classification. *Int. Orthop.* **2013**, *37*, 715–721. [CrossRef]
9. Edama, M.; Kubo, M.; Onishi, H.; Takabayashi, T.; Inai, T.; Yokoyama, E.; Hiroshi, W.; Satoshi, N.; Kageyama, I. The twisted structure of the human Achilles tendon. *Scand. J. Med. Sci. Sports* **2015**, *5*, 497–503. [CrossRef]
10. Shim, V.B.; Handsfield, G.G.; Fernandez, J.W.; Lloyd, D.G.; Besier, T.F. Combining in silico and in vitro experiments to characterize the role of fascicle twist in the Achilles Tendon. *Nat. Sci. Rep.* **2018**, *8*, 13856. [CrossRef]
11. Piazza, S.J. Mechanics of the subtalar joint and its function during walking. *Foot Ankle Clin. N. Am.* **2005**, *10*, 425–442. [CrossRef]
12. Winicki, K.; Ochala-Klos, A.; Rutowicz, B.; Pekala, P.A.; Tomaszewski, K.A. Functional anatomy, histology and biomechanics of the human Achilles tendon—A comprehensive review. *Ann. Anat.* **2020**, *229*, 151461. [CrossRef] [PubMed]
13. Yepes, H.; Tang, M.; Geddes, C.; Glazebrook, M.; Morris, S.F.; Stanish, W.D. Digital Vascular Mapping of the Integument About the Achilles Tendon. *J. Bone Jt. Surg. Am.* **2010**, *92*, 1215–1220. [CrossRef] [PubMed]
14. Carmont, M.R.; Silbernagel, K.G.; Brorsson, A.; Olsson, N.; Maffulli, N.; Karlsson, J. The Achilles Tendon Resting Angle as an indirect measure of Achilles tendon length following rupture, repair and rehabilitation. *Asia-Pac. J. Sports Med. Arthrosc. Rehabil. Technol.* **2015**, *2*, 49–55. [CrossRef]
15. Zellers, J.A.; Carmont, M.R.; Silbernagel, K.G. Achilles Tendon Resting Angle relates to Tendon Length and Function. *Foot Ankle Int.* **2018**, *39*, 343–348. [CrossRef]
16. Carmont, M.R.; Silbernagel, K.G.; Edge, A.; Mei-Dan, O.; Karlsson, J.; Maffulli, N. Functional Outcome of Percutaneous Achilles Repair—Improvements in Achilles Tendon Total Rupture Score During the First Year. *Orthop. J. Sports Med.* **2013**, *1*, 2325967113494584. [CrossRef]
17. Eliasson, P.T.; Agergaard, A.S.; Couppe, C.; Svensson, R.; Hoeffner, R.; Warming, S.; Warming, N.; Holm, C.; Jensen, M.H.; Krogsgaard, M.; et al. The Ruptured Achilles Tendon Elongates for 6 Months After Surgical Repair Regardless of Early or Late Weightbearing in Combination With Ankle Mobilization: A Randomized Clinical Trial. *Am. J. Sports Med.* **2018**, *46*, 2492–2502. [CrossRef]
18. She, G.; Teng, Q.; Li, J.; Zheng, X.; Chen, L.; Hou, H. Comparing Surgical and Conservative Treatment on Achilles Tendon Rupture: A comprehensive Meta-Analysis of RCTs. *Front. Surg.* **2021**, *8*, 607743. [CrossRef] [PubMed]

19. Caruso, G.; Gambuti, E.; Saracco, A.; Spadoni, E.; Corso, E.; Pinotti, I.; Pisano, A.; Massari, L. Open vs. Percutaneous Achilles Tendon Repair: Experience of Single Orthopedic Institute with Long-Term Follow-Up. *Medicina* **2024**, *60*, 1382. [CrossRef]
20. Jakkola, J.I.; Beskin, J.L.; Griffin, L.H.; Cernansky, G. Early Ankle Motion after Triple Bundle Technique Repair vs. Casting for Acute Achilles Tendon Rupture. *Foot Ankle Int.* **2001**, *22*, 979–984. [CrossRef]
21. Bevoni, R.; Angelini, A.; D'Apote, G.; Berti, L.; Fusaro, I.; Ellis, S.; Schuh, R.; Girolami, M. Long term results of acute Achilles repair with triple-bundle technique and early rehabilitation protocol. *Injury* **2014**, *45*, 1268–1274. [CrossRef]
22. Vuurberg, G.; van Dijk, C.N. Three-Bundle Technique. In *The Achilles Tendon, an Atlas of Surgical Procedures*, 1st ed.; Thermann, H., Becher, C., Carmont, M.R., Karlsson, J., Maffulli, N., Calder, J., van Dijk, C.N., Eds.; Springer: Berlin/Heidelberg, Germany, 2017; pp. 15–20.
23. Mauch, M.; Ulrich, M.; Kaelin, X.; Segesser, B.; Paul, J. Biomechanische Evaluation des Rehabilitationsverlaufs nach operativer Versorgung der Achillessehnenruptur. *Sportverletz. Sportschaden* **2017**, *31*, 222–230. [CrossRef] [PubMed]
24. Adam, N.C.; Smith, C.R.; Herzog, W.; Amis, A.A.; Arampatzis, A.; Taylor, W.R. In Vivo Strain Patterns in the Achilles Tendon During Dynamic Activities: A Comprehensive Survey of the Literature. *Sports Med. Open* **2023**, *9*, 60. [CrossRef] [PubMed]

Disclaimer/Publisher's Note: The statements, opinions and data contained in all publications are solely those of the individual author(s) and contributor(s) and not of MDPI and/or the editor(s). MDPI and/or the editor(s) disclaim responsibility for any injury to people or property resulting from any ideas, methods, instructions or products referred to in the content.